

# Relationship of Arm Acupressure Points and Thai Traditional Massage

Boonyarat Chaleephay

**Abstract**—The purpose of this research paper was to describe the relationship of acupressure points on the anterior surface of the upper limb in accordance with Applied Thai Traditional Massage (ATTM) and the deep structures located at those acupressure points. There were 2 population groups; normal subjects and cadaver specimens. Eighteen males with age ranging from 20-40 years old and seventeen females with ages ranging from 30-97 years old were studied. This study was able to obtain a fundamental knowledge concerning acupressure point and the deep structures that related to those acupressure points. It might be used as the basic knowledge for clinically applying and planning treatment as well as teaching in ATTM.

**Keywords**—Acupressure point (AP), Applied Thai Traditional Medicine (ATTM), Paresthesia, Numbness.

## I. INTRODUCTION

COURT-TYPE Thai traditional massage is a procedure on the human body using only the fingers and hands according to the inherited art of healing in Thai traditional medicine put forward by practitioners working in the royal palace in the old days. The court-type traditional massage helps stimulate blood circulation, and the lymphatic and nervous systems. It also helps to relax the muscles and to cure diseases or abnormal conditions that cause symptoms of pain, strain or fatigue in various parts of the body [1].

There are basic acupressure points (AP) of the inner side of the arm. Begin the acupressure point by using the index, middle and ring fingers of the side opposite to that of the client's arm to find the pulse at the wrist. When the pulse is located, use the palm of the other hand to press at AP no.1, located at the middle of the inner side of the arm. If the location is correct, the pulse becomes faint. Place both thumbs at AP no.2, located at the elbow joint, and gradually move the pressing along the line to AP no.3, located at the wrist. [1], [3] Acupressure point (AP) of the signal point of the Inner side of the arm. For acupressure point1 (AP1), use the thumb on middle of axilla. The acupressure point 2 (AP2) use palm pressure on middle of anterior of arm. For acupressure point3 (AP3), use acupressure on cubital fossa (CF). For acupressure point 4 (AP4), use acupressure on meddles of forearm. The acupressure point 5 (AP5) use acupressure on wrist at area of proximal carpal crease (PC).

Many researchers are interested in the relationship between acupressure points (AP) and Applied Thai Tradition Medicine (ATTM) of the upper limbs. Of particular interest is how

ATTM theory results in acupressure points, in positions, in physical characteristics, and sensation. The expected result is information concerning Thai Traditional forearm massage and therefore be able to develop more effective treatment and teaching methods

## II. OBJECTIVES

The present study aims at describing the relationship between acupressure points of court type massage on the anterior surface of upper limb in accordance of Applied Thai Traditional Medicine and the deep structures located at five points. Therefore, two main objectives were 1) To study the location of acupressure points with the anterior surface of upper limb in Thai cadavers. 2) To study the relationship of acupressure points with the anterior surface of upper limb in Thai cadavers.

## III. MATERIALS AND METHODS

### A. Materials

#### 1. Cadaveric

All 35 Thai cadavers were dissected, 18 males and 17 females with the age ranging from 30 to 97 year.

#### 2. Sample Size

The main objective of this study was to estimate the acupressure point accuracy of court type massage in Applied Thai Traditional Medicine based on the anatomical location found in Thai cadavers. It is expected to be 90% with 95% CI (confidence interval) was  $90\% \pm 10\%$  of Thai cadavers in 35 specimens (70 arms), as to calculate following.

### B. Method

Data were collected from cadaver specimens and normal subjects in 2012 which also included age, gender, and length of upper extremities.

#### 1. Cadaveric

1. The acupressure points AP1-AP5 were measured by a health profession with more than five years experience in the acupressure point.
2. Measure the surface length from the upper extremities according to Applied Thai Traditional Medicine (Boonyarat Chaleephay) by;
  - 2.1. The arm: measure the surface length from the tip of coracoid process (CP) to acupressure point1, 2 and medial epicondyle (ME).

B. Chaleephay is with Suan Sunandha Rajapath University, Bangkok, Thailand 10300 (phone: 662-160-1166; fax: 662-160-1166; e-mail: chaleephay@hotmail.com).

- 2.2. The forearm: measure the surface length from middle of cubital fossa (Acupressure point3) to middle of proximal carpal crease.
3. Measure all the points by using a common reference line from pin to bony prominence.
4. Dissection of cadaver specimens to identify deep structures and relationship to all points. Then, record data from the positions of the muscles, nerves and blood vessels that linked with the cadaver specimens (see Fig. 1).

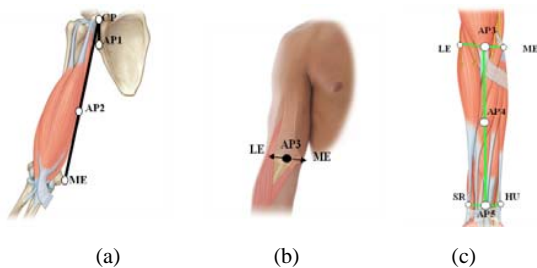


Fig. 1 The acupressure points 1-5 on the anterior surface of the upper limb (a) The length from CP-AP1, 2 and CP-ME (b) The length from ME-LE and ME-AP3 (c) The length from AP3-AP5, AP3-AP4 and HU-AP5

2. Statistical Analysis

The statistical analysis of the data was performed by using SPSS program (version 16.0 for windows). The results were presented as the mean, standard deviation (SD), percentile, paired sample t-test comparing between the mean values of right and left side of the upper extremities, independent sample t-test comparing between the mean values of females and males. The statistical significance for all analysis were at  $p < 0.05$  level.

IV. RESULTS

The result of cadaveric specimens for AP1-5:

TABLE I  
MEAN VALUE OF MEASUREMENT IN THE REFERENCE LINE OF 35 SPECIMENS COMPARE TO THE RESULT BETWEEN THE RIGHT SIDE OF FEMALE AND MALE

	Mean ± sd (cm)		P-value*
	Female	Male	
Cp-ap1	7.57±1.70	8.55±2.05	0.12
Cp-me	34.14±2.37	35.14±2.00	0.13
Cp-ap2	17.22±2.07	17.47±2.10	0.11
Me-le	16.18±2.50	16.14±1.70	0.94
Me-ap3	6.43±1.20	7.45±1.37	0.41
Ap3-ap5	23.20±1.90	24.31±1.45	0.01*
Ap3-ap4	11.45±1.84	11.54±1.50	0.30
Hu-ap5	2.57±0.43	2.52±0.30	0.14

\*P-value of independent sample t-test comparing between female and male (P < 0.05).

TABLE II  
MEAN VALUE OF MEASUREMENT IN THE REFERENCE LINE OF 35 SPECIMENS COMPARE TO THE RESULT BETWEEN THE LEFT SIDE OF FEMALE AND MALE

	Mean ± Sd (Cm)		P-Value*
	Female	Male	
Cp-Ap1	7.58±0.74	7.73±0.76	0.45
Cp-Me	28.31±1.33	29.91±2.82	0.54
Cp-Ap2	15.30±0.55	15.45±0.92	0.51
Me-Le	15.17±0.67	15.27±0.79	0.48
Me-Ap3	7.65±0.64	8.39±0.87	0.34
Ap3-Ap5	24.35±2.01	24.79±1.80	0.45
Ap3-Ap4	12.30±1.29	12.43±0.87	0.34
Hu-Ap5	3.28±0.34	3.31±0.23	0.29

\*P-value of independent sample t-test comparing between female and male (P < 0.05).

The theory of Applied Thai Traditional Medicine shows AP1 is located the in the middle of axilla, on Coracobrachialis muscle, axillary artery and median nerve. The sensation of this point is paresthesia which occurs around anterior surface of arm [1], [2]. Similar to our study, it has been found that acupressure point 1 (AP1) that locates proximal 1/5 of the length of arm is musculotendinous junction of Coracobrachialis muscle which shows more specific than the theory. And one more related structure we have found is short head of Biceps brachii muscle. However, the third part of axillary artery and median nerve are the same. For the sensation of this point feels paresthesia around the anterior surface of their arms. From our result, if the patient hurts lateral shoulder downward to dorsal surface of arm, elbow and wrist, treatment of Coracobrachialis trigger point must be considered.

From the theory of Applied Thai Traditional Medicine, the location of AP2 is on the middle of the anterior surface of arm, on brachial artery, Biceps brachii muscle and median nerve. The sensation of this point is numbness which occurs around arm, forearm and palm [1]. Similar to our study, it has been found that the acupressure point 2 (AP2) is located proximal 3/5 of the length of arm is the brachial artery in the middle of medial bicipital furrow. This location is more specific than previous theory. And one more related structure we found is the medial border of Biceps brachii muscle and median nerve crossing medially of brachial artery [4], [5]. The sensation of this point is characterized by numbness on the anterior surface of arm, forearm, and palmar surface of the hand.

From the theory of Applied Thai Traditional Medicine, the location of AP3 is in the middle of the anterior surface of cubital fossa on brachial artery and median nerve. The sensation of this point is characterized by numbness which occurs in the elbow joint [1], [6]. Similar to our study, it has been found that acupressure point 3 (AP3) is located on the midpoint of cubital fossa, a distal part of brachial artery. This location is more specific than previous theory. The related structure that we found is the brachial artery that it is in the middle of cubital fossa between the tendon or the cord of Biceps brachii muscles lies laterally and the median nerve lying medially. For the sensation point feels numbness in the elbow only. The commonest neurological problem associated

with the compression of median nerve beneath the flexor retinaculum at the wrist is carpal tunnel syndrome.

From the theory of Applied Thai Traditional Medicine, the location of AP4 is on the middle of anterior surface of forearm on Flexor carpi radialis muscle. The sensation of this point is paresthesia which occurs in wrist, hand and fingers [1], [4]. Similar to our study, it was found that acupressure point 4 (AP4) that locates proximal 3/5 of the length of forearm is musculotendinous junction of Flexor carpi radialis muscle. This location is more specific than previous theory. For related structures at intermediate layer of forearm is radial head of Flexor digitorum superficialis muscle and median nerve, deep, in the layer of forearm on the anterior surface is origin of radial half of interosseous membrane of Flexor pollicis longus and anterior surface origin of medial half of interosseous membrane of Flexor digitorum profundus muscle [4], [5]. The sensation point feels paresthesia at the wrist, hand, and fingers.

From the theory of Applied Thai Traditional Medicine, the location of AP5 is on proximal carpal crease at Flexor carpi radialis muscle. The sensation of this point is paresthesia which occurs at the wrist to the thumb [1], [2]. From our study, acupressure point 5 (AP5) is more specific than theory because this point is on the midpoint of proximal carpal crease which is the distal end of the insertion of Palmaris longus muscle. The related structure is median nerve which lies downward and laterally to Palmaris longus muscle before it passed into carpal tunnel and laterally to tendon of Flexor digitorum superficialis muscle [7]. The sensation point is characterized by paresthesia in the wrist to the thumb, index, middle, and lateral half of the ring fingers. From our result, if the patient hurts, they would feel superficial needle-like pricking pain rather than the deep aching of most other muscles. The primary location is in the palm, with spillover up the forearm. Thus, be careful if we want to compress on the median nerve it will make paresthesia in thenar muscles and medial two lumbricales muscles which is the same symptom as carpal tunnel syndrome [3], [8].

In conclusion, this study displays more fundamental knowledge of the acupressure points and the correct structures that related to these acupressure points of the upper extremity than the previous theories. It might be used as the basic knowledge for clinically applying and planning treatment as well as teaching in ATTM.

## V. DISCUSSION AND CONCLUSION

### A. The Location of the Acupressure Point (AP) with the Anterior Surface of Upper Limb

Five acupressure points were pressed on normal subjects. And the pressing sensation was also recorded when pin were used on the cadaver specimens in order to locate deep structures. The location of the acupressure points AP were proximal: (AP1) is proximal on the medial side of the arm, (AP2) is proximal 3/5 of arm at medial bicipital furrow, (AP3) is proximal on midpoint of cubital fossa, (AP4) is proximal 3/5 of anterior surface of forearm, and (AP5) is proximal on

midpoint of palmar surface of proximal carpal crease. For AP1, living humans felt paresthesia at anterior surface of arm. For AP2, subjects felt numbness of the anterior surface of arm, forearm and palmar. For AP3, subjects felt numbness around elbow only whereas AP4 paresthesia occurred at the wrist; hand and fingers. AP5 paresthesia at radial side of palm and wrist, palmar surface of thumb, index, middle and lateral half of ring fingers. In the cadaver specimen, it was found that the deep structures of AP1-5 were associated with musculotendinous junction of Coracobrachialis muscle, brachial artery in the middle of medial bicipital furrow, brachial artery in the middle of cubital fossa, musculotendinous junction of Flexor carpi radialis and distal end of Palmaris longus respectively. There was no significant difference between genders and between left and right arms.

### B. The Accuracy Sensation of Acupressure Points Compare with Thai Traditional Medicine

Acupressure point 1 (AP1) found that the sensation is paresthesia around the anterior surface of their arms.

Acupressure point 2 (AP2) found that the sensation which is numbness on the anterior surface of arm, forearm, and palmar surface of the hand.

Acupressure point 3 (AP3) found that the sensation which is numbness which occurred in the elbow only.

Acupressure point 4 (AP4) found that the sensation which is paresthesia at the wrist, hand, and fingers.

Acupressure point 5 (AP5) found that the sensation which is paresthesia in the wrist to the thumb, index, middle, and lateral half of the ring fingers.

## ACKNOWLEDGMENT

The author sincerely thanks Research and Development Institute, Suan Sunandha Rajabhat University, Bangkok, Thailand for partially financial support. The author would like to thank to students whom study in Department of Applied Thai Traditional Medicine, Faculty of Science and Technology, Suan Sunandha Rajabhat University for assisting as good volunteers to collecting samples and useful data.

## REFERENCES

- [1] Ayurved Thamrong School. Thai Traditional Medicine in the Faculty of Medicine Siriraj Hospital. Mahidol University, 2009.
- [2] Romanes GJ. Cunningham's manual of practical anatomy. 14<sup>th</sup> ed. New York: Oxford University press, 1976.
- [3] Darke RL. Gray's Anatomy for Students. 2<sup>nd</sup> ed. Philadelphia: Churchill Livingstone, 2011.
- [4] Romanes GJ. Cunningham's Textbook of anatomy. 12<sup>th</sup> ed. New York: Oxford University press, 1981.
- [5] Agur AM. Grant's Atlas of anatomy. 11<sup>th</sup> ed. Philadelphia: Williams and Wilkins, 2005.
- [6] Lumley JSP. Surface anatomy the anatomical basis of clinical examination. 1<sup>st</sup> ed. Edinburgh: Churchill Livingstone; 1993.
- [7] Basmajian JV. Grant's Method of anatomy. 11<sup>th</sup> ed. Vancouver: Williams and Wilkins, 1981.
- [8] William PM. Gray's Anatomy. 38<sup>th</sup> ed. Edinburgh: Churchill Livingstone, 1995.