

Protective Effect of Thymoquinone against Nephrotoxicity Induced by Cadmium in Rats

Amr A. Fouad, Hamed A. Alwadaani, Iyad Jresat

Abstract—The present study investigated the protective effect of thymoquinone (TQ), against cadmium-induced kidney injury in rats. Cadmium chloride (1.2 mg Cd/kg/day, s.c.), was given for nine weeks. TQ treatment (40 mg/kg/day, p.o.) started on the same day of cadmium administration and continued for nine weeks. TQ significantly decreased serum creatinine, renal malondialdehyde and nitric oxide, and significantly increased renal reduced glutathione in rats received cadmium. Histopathological examination showed that TQ markedly minimized renal tissue damage induced by cadmium. Immunohistochemical analysis revealed that TQ markedly decreased the cadmium-induced expression of inducible nitric oxide synthase, tumor necrosis factor- α , cyclooxygenase-2, and caspase-3 in renal tissue. It was concluded that TQ significantly protected against cadmium nephrotoxicity in rats, through its antioxidant, anti-inflammatory, and antiapoptotic actions.

Keywords—Thymoquinone, cadmium, kidney, rats.

I. INTRODUCTION

CADMIUM is one of the most environmentally abundant toxic metals, which adversely affects numerous body organs. Occupational exposure to cadmium occurs due to working with cadmium-containing pigments, plastics, glass, metal alloys and electrode material in batteries. Non-occupational exposure predominantly results from smoking, air pollution, and consumption of cadmium-contaminated water and sea foods [1]. The kidney is one of the critical target organs for chronic cadmium toxicity. Cadmium preferentially accumulates and persists in the kidneys (biological half-life of 10-30 years) due to lack of an active biochemical mechanism for elimination coupled with renal reabsorption [2]. Several lines of evidences indicate that oxidative stress and increased production of pro-inflammatory cytokines are incriminated in the pathogenesis of cadmium nephrotoxicity leading eventually to renal tissue damage [3]. In addition, antioxidants and anti-inflammatory agents were effective in protecting against cadmium nephrotoxicity [4], [5].

TQ is the main active ingredient isolated from the volatile oil of *Nigella sativa* or black seed. TQ has diverse pharmacological properties as antioxidant, anti-inflammatory,

antidiabetic, immunomodulatory, antimicrobial, and antineoplastic effects [6]. Recent studies showed that TQ significantly ameliorated nephrotoxicity induced by gentamicin [7], cyclosporine [8], vancomycin [9], and acetaminophen [10] in rats. In addition, TQ attenuated streptozotocin-induced diabetic nephropathy, and protected against kidney ischemia-reperfusion injury in rats [11], [12]. Therefore, TQ has the potential to protect against cadmium-induced nephrotoxicity.

II. MATERIALS AND METHODS

A. Animals

Male Sprague-Dawley rats, weighing 200-230 g were obtained from the Animal House, King Faisal University. The animals were kept at standard housing facilities ($24 \pm 1^\circ\text{C}$, $45 \pm 5\%$ humidity and 12 h light/dark cycle). They were supplied with standard laboratory chow and water *ad libitum*, and left to acclimatize for 1 week before the experiments. The experimental protocol was approved by the Research Ethics Committee, King Faisal University (approval number: 150101) and the experimental procedures were carried out in accordance with international guidelines for care and use of laboratory animals.

B. Drugs and Chemicals

Cadmium chloride powder and TQ powder were purchased from Sigma Chemical Company, USA. Cadmium chloride was dissolved in normal saline, and TQ was prepared in 0.5% carboxymethylcellulose (CMC). The doses used in the present work were selected based on previous reports [13], [14].

C. Experimental Protocol

The rats were randomly allocated to three equal groups ($n = 10$, each). The first (control) group received a daily s.c. injection of normal saline for nine weeks. The rats of the second and third groups received cadmium chloride at a dose of 1.2 mg Cd/kg/day, s.c., five days/week for nine weeks. The second group received 0.5% CMC, while the third group received TQ (40 mg/kg/day, p.o.) for nine weeks starting on the same day of cadmium administration.

D. Sample Preparation and Biochemical Analysis

The rats were euthanized 24 h following the last dose of cadmium chloride by thiopental (100 mg/kg, i.p.). Blood samples were collected, left for 1 h to clot and centrifuged for 10 min at 5000 rpm to obtain clear sera, which were stored at -20°C . Subsequently, serum creatinine was measured using

Amr A. Fouad is with the Department of Biomedical Sciences, Pharmacology Division, College of Medicine, King Faisal University, Al-Ahsa, Saudi Arabia (Primary address: Department of Pharmacology, Faculty of Medicine, Minia University, El-Minia, Egypt) (Corresponding author to provide phone: +966501776517; e-mail: amrfouad65@yahoo.com).

Hamed A. Alwadaani is with the Department of Surgery, College of Medicine, King Faisal University, Al-Ahsa, Saudi Arabia.

Iyad Jresat is with the Department of Biomedical Sciences, Pathology Division, College of Medicine, King Faisal University, Al-Ahsa, Saudi Arabia.

colorimetric assay kit according to the recommendations of the manufacturer (Stanbio Laboratory, USA).

The kidneys were isolated from each animal, the renal cortex was separated, weighed and kept at -80°C , and subsequently the right kidneys were homogenized in cold potassium phosphate buffer (0.05 M, pH 7.4). The homogenates were centrifuged at 5000 rpm for 10 min at 4°C . The resulting supernatant was used for determination of malondialdehyde (MDA), reduced glutathione (GSH), and nitric oxide (NO) levels by colorimetric assay kits according to the manufacturer's instructions (Biodiagnostic, Egypt).

E. Histopathological Examination

The left kidneys were fixed in 10% formalin solution, dehydrated in ascending grades of alcohol and embedded in paraffin. Sections at $4\ \mu\text{m}$ -thickness were taken, stained with hematoxylin and eosin (H&E) and examined under light microscope.

F. Immunohistochemical Examinations

Four μm thick sections were deparaffinised, rehydrated, and endogenous peroxidase activity was blocked with 3% H_2O_2 in methanol. Sections were pre-treated in citrate buffer (pH 6.0), and were incubated with rabbit polyclonal antibodies against inducible nitric oxide synthase (iNOS), cyclooxygenase-2 (COX-2), and caspase-3 (Thermo Scientific, USA, dilution 1:1000), and tumor necrosis factor- α (TNF- α) (US Biological, USA, dilution 1:1000). The sections were incubated with biotinylated goat anti-polyvalent, then with streptavidin peroxidase and finally with diaminobenzidine as chromogen. Slides were counterstained with hematoxylin, and were examined under light microscope.

G. Statistical Analysis

Data are expressed as mean \pm S.E.M. The results were analyzed by one-way analysis of variance (ANOVA) followed by Tukey test for post hoc comparisons using SPSS for Windows (version 18). $P < 0.05$ was selected as the criterion for statistical significance.

III. RESULTS

Cadmium administration caused significant elevations of serum creatinine, and renal MDA, and NO, and a significant decrease in renal GSH as compared to control group. Treatment with TQ resulted in significant decreases in serum creatinine, renal MDA, and NO, and a significant increase in renal GSH, as compared to the corresponding values of the cadmium group non-treated with TQ (Figs. 1 and 2).

Fig. 3 shows that cadmium caused widespread necrosis with dilatation, vacuolar degeneration, epithelial desquamation and intraluminal cast formation in the proximal convoluted tubules. However, TQ treatment markedly ameliorated the histopathological renal tissue damage induced by cadmium. In addition, cadmium caused marked increases in the expression of iNOS, COX-2, TNF- α , and caspase-3 in the renal tissue as compared to the control group. On the other hand, TQ-treated rats showed obvious reductions in the cadmium-induced

expression of iNOS, COX-2, TNF- α , and caspase-3 in the kidney tissues as compared to the cadmium group non-treated with TQ (Figs. 4-7).

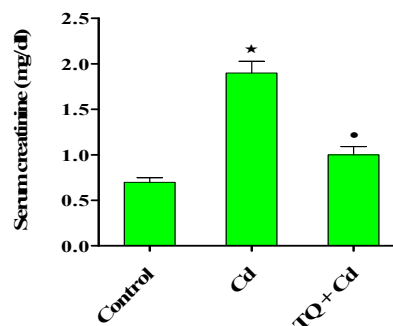


Fig. 1 Effect of TQ on serum creatinine of rats exposed to cadmium (Cd) nephrotoxicity. Data are expressed as mean \pm S.E.M., $n = 10$ in each group. * $P < 0.05$ vs. control group, * $P < 0.05$ vs. Cd group

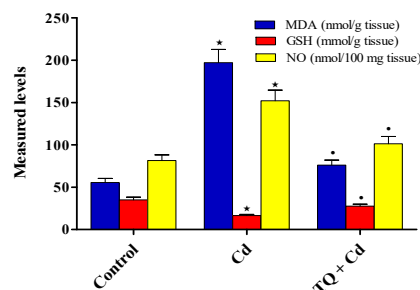


Fig. 2 Effects of TQ on renal MDA, GSH and NO levels in rats exposed to cadmium (Cd) nephrotoxicity. Data are expressed as mean \pm S.E.M., $n = 10$ in each group. * $P < 0.05$ vs. control group, * $P < 0.05$ vs. Cd group

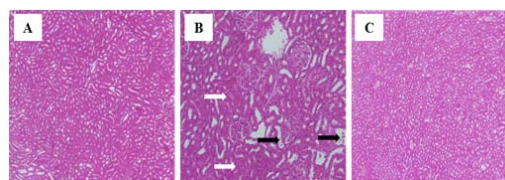


Fig. 3 Photomicrographs of rat kidney (H&E, 200 \times) from: (A) control showing normal renal histology; (B) cadmium showing widespread coagulative necrosis (white arrows), dilatation, vacuolar degeneration, epithelial desquamation and intraluminal cast formation (black arrows) in the proximal tubules; (C) TQ plus cadmium showing a histological picture comparable to the control

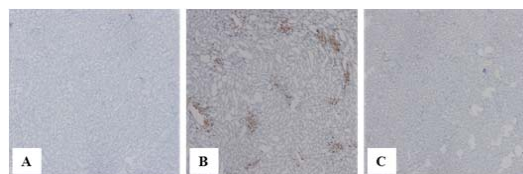


Fig. 4 Immunohistochemistry (200 \times) of iNOS in rat kidney. (A) control showing no expression; (B) cadmium showing a marked increase in immunoreactivity in brown color; (C) TQ plus cadmium showing an obvious decrease in immunostaining

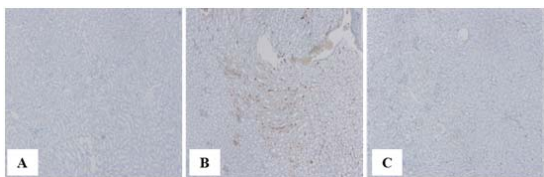


Fig. 5 Immunohistochemistry (200 \times) of COX-2 in rat kidney. (A) control showing no expression; (B) cadmium showing a marked increase in immunoreactivity in brown color; (C) TQ plus cadmium showing an obvious decrease in immunostaining

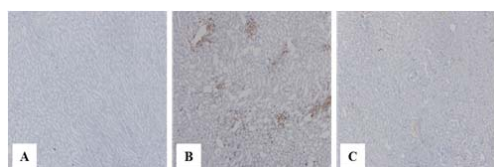


Fig. 6 Immunohistochemistry (200 \times) of TNF- α in rat kidney. (A) control showing no expression; (B) cadmium showing a marked increase in immunoreactivity in brown color; (C) TQ plus cadmium showing an obvious decrease in immunostaining

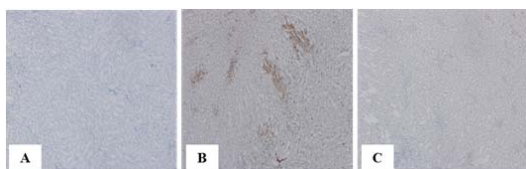


Fig. 7 Immunohistochemistry (200 \times) of caspase-3 in rat kidney. (A) control showing no expression; (B) cadmium showing a marked increase in immunoreactivity in brown color; (C) TQ plus cadmium showing an obvious decrease in immunostaining

IV. CONCLUSION

The present study showed that TQ treatment significantly protected against renal tissue injury induced by cadmium in rats. Also, the present work, in agreement with previous studies, clearly demonstrated that oxidative stress with increased lipid peroxidation, depletion of antioxidant defenses and increased release of pro-inflammatory cytokines play a crucial role in the pathogenesis of cadmium nephrotoxicity [3], [4]. In addition, it has been demonstrated that increased NO production is implicated in cadmium-mediated cytotoxicity and oxidative damage [15]. This can be explained by the ability of TNF- α to up-regulate the iNOS enzyme [16]. Excess NO reacts with superoxide anion to generate peroxynitrite radical that causes further cell damage by oxidizing and nitrating cellular macromolecules. Also, excess NO depletes intracellular GSH increasing the susceptibility to oxidative stress [17]. Cadmium also induced COX-2 expression and increased production of inflammatory prostaglandins in the kidney tissues [13].

TQ, the main active constituent isolated from *Nigella sativa* seed oil, exerts marked antioxidant activity, scavenges reactive oxygen radicals, suppresses lipid peroxidation, and maintains the antioxidant defense mechanisms during free radical reactions [8]-[12]. Also, TQ inhibits iNOS activity and

decreases NO production, and therefore prevents nitrosative tissue stress [18]. In addition, TQ exhibits significant anti-inflammatory activity because it reduces the release of inflammatory cytokines, and inhibits COX-2 the inducible form of cyclooxygenases thus decreasing the production of inflammatory prostaglandins [19]. It was also revealed that TQ decreased the cadmium-induced expression of caspase-3, an executioner of cell apoptosis in the kidney tissue. This is in agreement with previous studies, which showed that TQ provided a significant anti-apoptotic effect by inhibiting caspase-3 activity [20]. Therefore, it could be stated that TQ protected against cadmium-induced renal cell apoptosis. The reduced caspase-3 activity observed with TQ treatment may be due to its antioxidant, and anti-inflammatory activities.

The results of the present study indicate that TQ significantly ameliorated cadmium-induced kidney injury in rats. The antioxidant, anti-inflammatory, and anti-apoptotic activities of TQ can be considered the main factors responsible for the nephroprotective effect. Therefore, TQ represents a potential therapeutic option to prevent the deleterious effect of cadmium exposure on the kidney.

REFERENCES

- [1] M. Waisberg, P. Joseph, B. Hale, D. Beyersmann, "Molecular and cellular mechanisms of cadmium carcinogenesis," *Toxicology*, vol. 192, pp. 95-117, 2003.
- [2] S. Satarug, M.R. Moore, "Adverse health effects of chronic exposure to low-level cadmium in foodstuffs and cigarette smoke," *Environ. Health Perspect.*, vol. 112, pp. 1099-1103, 2004.
- [3] F. Thevenod, "Nephrotoxicity and the proximal tubules. Insights from cadmium," *Nephron Physiol.*, vol. 93, pp. 87-93, 2003.
- [4] P. Manna, M. Sinha, P.C. Sil, "Taurine plays a beneficial role against cadmium-induced oxidative renal dysfunction," *Amino Acids*, vol. 36:pp. 417-428, 2009.
- [5] J. Renugadevi, S.M. Prabu, "Quercetin protects against oxidative stress-related renal dysfunction by cadmium in rats" *Exp. Toxicol. Pathol.*, vol. 62, pp. 471-481, 2010.
- [6] S. Darakhshan, A. Bidmeshki Pour, A. Hosseinzadeh Colagar, S. Sisakhtnezhad, "Thymoquinone and its therapeutic potentials," *Pharmacol. Res.*, vol. 95-96C, pp. 138-158, 2015.
- [7] S. Samarghandian, M. Azimi-Nezhad, H. Mehrad-Majd, S.R. Mirhafez, "Thymoquinone ameliorates acute renal failure in gentamicin-treated adult male rats," *Pharmacology*, vol. 96, pp. 112-117, 2015.
- [8] M.M. Farag, G.O. Ahmed, R.R. Shehata, A.H. Kazem, "Thymoquinone improves the kidney and liver changes induced by chronic cyclosporine A treatment and acute renal ischaemia/reperfusion in rats," *J. Pharm. Pharmacol.*, vol. 67, pp. 731-739, 2015.
- [9] F. Basarslan, N. Yilmaz, S. Ates, T. Ozgur, M. Tutanc, V.K. Motor, V. Arica, C. Yilmaz, M. Inci, S. Buyukbas, "Protective effects of thymoquinone on vancomycin-induced nephrotoxicity in rats," *Hum. Exp. Toxicol.*, vol. 31, pp. 726-733, 2012.
- [10] I.O. Aycan, O. Tokgöz, A. Tüfek, U. Alabalık, O. Evliyaoglu, H. Turgut, F. Çelik, A. Güzel, "The use of thymoquinone in nephrotoxicity related to acetaminophen," *Int. J. Surg.*, vol. 13:pp. 33-37, 2015.
- [11] A.S. Awad, R. Kamel, M.A. Sherief, "Effect of thymoquinone on hepatorenal dysfunction and alteration of CYP3A1 and spermidine/spermine N-1-acetyl-transferase gene expression induced by renal ischaemia-reperfusion in rats," *J. Pharm. Pharmacol.*, vol. 63, pp. 1037-1042, 2011.
- [12] O.M. Omran, "Effects of thymoquinone on STZ-induced diabetic nephropathy: an immunohistochemical study," *Ultrastruct. Pathol.*, vol. 38, pp. 26-33, 2014.
- [13] A.I. Morales, C. Vicente-Sánchez, M. Jerkic, J.M. Santiago, P.D. Sánchez-González, F. Pérez-Barriocanal, J.M. López-Novoa, "Effect of quercetin on metallothionein, nitric oxide synthases and cyclooxygenase-2 expression on experimental chronic cadmium

- nephrotoxicity in rats," *Toxicol. Appl. Pharmacol.*, vol. 210, pp. 128-135, 2006.
- [14] L. Pari, C. Sankaranarayanan, "Beneficial effects of thymoquinone on hepatic key enzymes in streptozotocin-nicotinamide induced diabetic rats," *Life Sci.*, vol. 85, pp. 830-834, 2009.
- [15] A.A. Fouad, H.A. Qureshi, A.I. Al-Sultan, M.T. Yacoubi, A.A. Ali, "Protective effect of hemin against cadmium-induced testicular damage in rats," *Toxicology*, vol. 257, pp. 153-160, 2009.
- [16] Jr. S.M. Morris, T.R. Billiar, "New insights into the regulation of inducible nitric oxide synthesis," *Am. J. Physiol.*, vol. 266, pp. E829-E839, 1994.
- [17] R.M. Clancy, S.B. Abramson, "Nitric oxide: a novel mediator of inflammation," *Proc. Soc. Exp. Biol. Med.*, vol. 210, pp. 93-101, 1995.
- [18] A. El-Mahmoudy, H. Matsuyama, M.A. Borgan, Y. Shimizu, M.G. El-Sayed, N. Minamoto, T. Takewaki, "Thymoquinone suppresses expression of inducible nitric oxide synthase in rat macrophages," *Int. Immunopharmacol.*, vol. 2, pp. 1603-1611, 2002.
- [19] J.K. Kundu, L. Liu, J.W. Shin, Y.J. Surh, "Thymoquinone inhibits phorbol ester-induced activation of NF- κ B and expression of COX-2, and induces expression of cytoprotective enzymes in mouse skin in vivo," *Biochem. Biophys. Res. Commun.*, vol. 438, pp. 721-727, 2013.
- [20] A.A. Fouad, I. Jresat, "Thymoquinone therapy abrogates toxic effect of cadmium on rat testes," *Andrologia*, vol. 47, pp. 417-426, 2015.