

# Protective Effect of Saponin Extract from the Root of *Garcinia kola* (Bitter kola) against Paracetamol-Induced Hepatotoxicity in Albino Rats

Yemisi Rufina Alli Smith, Isaac Gbadura Adanlawo

**Abstract**—Liver disorders are one of the major problems of the world. Despite its frequent occurrence, high morbidity and high mortality, its medical management is currently inadequate. This study was designed to evaluate the hepatoprotective effect of saponin extract of the root of *Garcinia kola* on the integrity of the liver of paracetamol induced wistar albino rats. Twenty five (25) male adult wistar albino rats were divided into five (5) groups. Group I was the Control group that received distilled water only, group II was the negative control that received 2 g/kg of paracetamol on the 13th day, and group III, IV and V were pre-treated with 100, 200 and 400mg/kg of the saponin extract before inducing the liver damage on the 13th day with 2 g/kg of paracetamol. Twenty four (24) h after administration, the rats were sacrificed and blood samples were collected. The serum Alanine Transaminase (ALT), Aspartate Transaminase (AST), Alkaline Phosphatase (ALP) activities, Bilirubin and conjugated bilirubin, glucose and protein concentrations were evaluated. The liver was fixed immediately in Formalin and was processed and stained in Haematoxylin and Eosin (H&E). Administration of saponin extract from the root of *Garcinia kola* significantly decreased paracetamol induced elevated enzymes in the test group. Also histological observations showed that saponin extract of the root of *Garcinia kola* exhibited a significant liver protection against the toxicant as evident by the cells trying to return to normal. Saponin extract from the root of *Garcinia kola* indicated a protection of structural integrity of the hepatocytic cell membrane and regeneration of the damaged liver.

**Keywords**—*Garcinia kola*, Hepatoprotective, paracetamol, Saponin.

## I. INTRODUCTION

LIVER disorders are worldwide health problem. The liver is one of the largest organs in human body and has a pivotal role in regulation of physiological processes. The liver is the principle organ for maintaining the body's internal environment. There is currently no way to reimburse for the absence of liver function [1]. It is the chief site for intense metabolism and excretion. So it has a surprising role in the maintenance, performance and regulating homeostasis of the body. It is involved with almost all the biochemical pathways to growth, fight against disease, nutrient supply, energy provision and reproduction [2]. It is involved in several vital functions such as secretion of bile acids and storage of vitamins. Furthermore, detoxification of a variety of drugs and

xenobiotics occurs in liver. The bile secreted by the liver has, among other things, an important role in digestion. Thus, to maintain a healthy liver is a crucial factor for overall health and well being. Conventional, drugs used in the treatment of liver diseases are sometimes inadequate and can have serious adverse effects. Therefore, it is necessary to search for alternative drugs for the treatment of liver disease in order to replace currently used drugs of doubtful efficacy and safety [3]. Therefore, conventional medicine is now pursuing the exploitation of natural products such as herbs to provide the support that liver needs on a daily basis.

Paracetamol, a commonly used analgesic, is considered safe at therapeutic doses. However, an overdose of paracetamol causes severe hepatotoxicity and necrosis in both humans and experimental animals [4], [5]. At therapeutic levels, paracetamol is primarily metabolized in the liver by glucuronidation and sulphation; however, a small proportion undergoes cytochrome P450 CYP450-mediated bioactivation to N-acetyl-p-benzoquinimine (NAPQI), which is rapidly quenched by glutathione (GSH) [6].

After an overdose of paracetamol, elevated levels of the toxic NAPQI metabolite are generated, which extensively deplete hepatocellular GSH and covalently modify cellular proteins resulting in hepatocyte death [7].

*Garcinia kola* (Bitter kola), is a species of flowering plant in the *Clusiaceae* or *Guttiferae* family. It is found in Benin, Cameroon, Democratic Republic of Congo, Ivory Coast, Gabon, Ghana, Liberia, Nigeria, Senegal and Sierra Leone. It is given different names in Nigeria. Its natural habitat is subtropical or tropical moist low land forests. The plant has the popular acronym "wonder plant" among the South-Western Nigeria people because of its importance [8]. Saponins are glycosides with distinctive foaming characteristic. They are widely distributed plant metabolites consisting of a steroidal or a triterpenoid moiety having one or more carbohydrates side chains. Saponins have been reported to possess a wide range of biological activities. This article is aimed at investigating the protective effects of saponin extracts of roots of *Garcinia kola* on paracetamol – induced hepatotoxicity in albino rats.

## II. MATERIALS AND METHODS

### A. Plant Materials

The root of *Garcinia kola* (Bitter kola) was collected from Are-Ekiti, Ekiti state, Nigeria. The samples were thoroughly

Y.R. Alli Smith is with Biochemistry Department, Ekiti State University, Ado Ekiti, Ekiti State, Nigeria (phone: +2348061284168; e-mail: alliyemisi@gmail.com).

I.G. Adanlawo is with Biochemistry Department, Ekiti State University, Ado Ekiti, Ekiti State, Nigeria (e-mail: isowande@yahoo.com).

examined to ensure that they were diseases free before they were identified by at the Herbarium section of Plant Science Department, Ekiti State University, Ado-Ekiti, Nigeria. A voucher specimen was deposited in the Departmental Herbarium. The roots were cut into bits and air-dried at room temperature; the dried roots were then crushed into coarse Powder with a pestle and mortar and further milled into a fine power using an electric grinding machine.

#### B. Preparation of Saponin Extract

100g of the ground sample was extracted with 500ml of petroleum ether (40-60°C) in a soxhlet extractor for 12h. The air-dried defatted sample was similarly extracted with methanol (600ml) for 13h. The method of [9] was used to purify the saponin from the methanolic extract. This was partitioned between 1:1 (v/v) mixtures of n- butanol and water. After shaking very well and allowing standing, the n- butanol layer was separated as a brownish green layer. The aqueous layer was washed with n-butanol until it became colourless. The pooled butanolic layer was evaporated in vacuo to give a residue which was dissolved in 100ml of methanol and precipitated by adding a large amount of diethyl ether to obtain a solid crystalline dark brown saponin compound [10].

#### C. Animals

Adult male albino rats (190-200g) were obtained from the Animal House of the University of Ilorin, Kwara State, Nigeria. The animals were maintained in a well ventilated room under 12 h light: 12 h dark cycle and were acclimatized for 2weeks in the animal house of Biochemistry Department, Ekiti State University before the start of the experiment. Animals were allowed to freely feed on their standard pellet diet and water *ad libitum*. The authors hereby declare that "Principles of laboratory animal care" (NIH publication No. 85-23, revised 1985) were followed, as well as specific national laws where applicable. All experiments have been examined and approved by the appropriate ethics committee.

#### D. Experimental Design for Hepatotoxicity and Hepatoprotective Activity Study

Twenty (25) albino rats were divided into 5 groups of 5 rats each and subjected to different doses of saponin extract. The experiment was designed with five groups (A-E) each containing 5 rats. The experimental groups were:

Group A- Negative Control group: Rats were fed with normal rat pellets and water.

Group B- Positive Control group: Rats were injected intraperitoneally with a single dose of 2g/kg of paracetamol on the 13<sup>th</sup> day of the experiment.

Group C: Rats were pre treated with 100mg/kg body weight of saponin extract from the root of *Garcinia kola* for 14days and injected intraperitoneally with a single dose of 2g/kg of paracetamol on the 13<sup>th</sup> day of the experiment.

Group D: Rats were pretreated with 200mg/kg body weight of saponin extract from the root of *Garcinia kola* for 14days and injected intraperitoneally with a single dose of 2g/kg of paracetamol on the 13<sup>th</sup> day of the experiment.

Group E: Rats were pre treated with 400mg/kg body weight of saponin extract from the root of *Garcinia kola* for 14days and injected intraperitoneally with a single dose of 2g/kg of paracetamol on the 13<sup>th</sup> day of the experiment.

The rats were kept in fasting condition overnight before the test was performed. The animals were sacrificed 24 hours after paracetamol administration by cervical dislocation.

#### E. Assessment of Liver Functions

After sacrifice, blood samples from each group of rats were collected in centrifuge tubes, allowed to clot at room temperature and the serums were separated by centrifugation (3000rpm, 15 minutes). Serum samples were subjected to liver function tests of serum enzymes such as serum Alanine aminotransferase (ALT), Aspartate aminotransferase (AST) [11], Alkaline phosphatase (ALP), Total and Direct bilirubin by Standard enzymatic colorimetric method [12]. Liver specimens of rats were sliced (few mm thickness) and fixed in 10 % buffered formalin for days and histological study carried out as described by [13].

### III. RESULTS

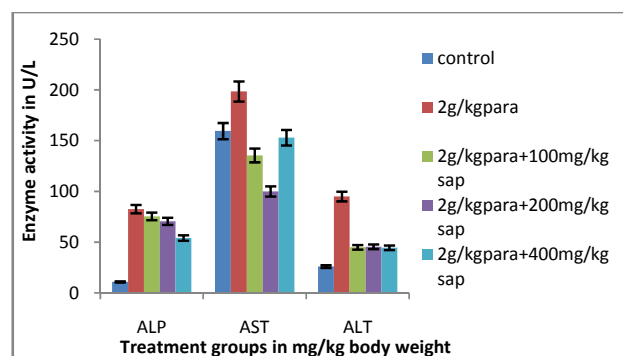


Fig. 1 Serum enzyme activity (U/L) of paracetamol induced rats treated with Saponin extract of the root of *Garcinia kola*. The results are means  $\pm$  SD

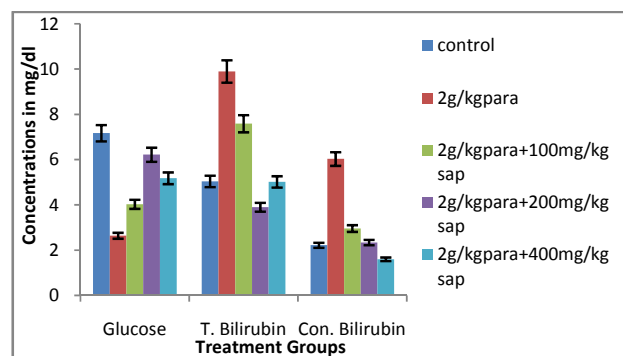


Fig. 2 Serum concentrations of Total and conjugated bilirubin, Glucose (mg/dl) of paracetamol induced rats treated with Saponin extract of the root of *Garcinia kola*. The results are means  $\pm$  SD

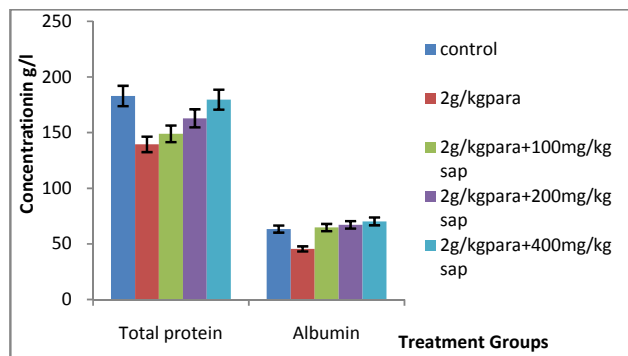


Fig. 3 Serum concentrations of Total protein and albumin (g/l) of paracetamol induced rats treated with Saponin extract of the root of *Garcinia kola*. The results are means  $\pm$  SD

The results of hepatoprotective activity Saponin extract of the root of *Garcinia kola* on paracetamol treated rats are shown in Figs. 1-3. The hepatic enzymes ALT, AST and ALP and biochemical parameters Total and conjugated bilirubin in serum was significantly increased in paracetamol treated animals when compared to control. The Saponin extract of the root of *Garcinia kola* treatments significantly reversed the levels of ALT, AST, ALP, Total bilirubin and conjugated bilirubin when compared to paracetamol alone treated rats. Also the reduction observed in the levels of Total protein, albumin and glucose in the group of rats given paracetamol only were increased in the saponin treated rats.

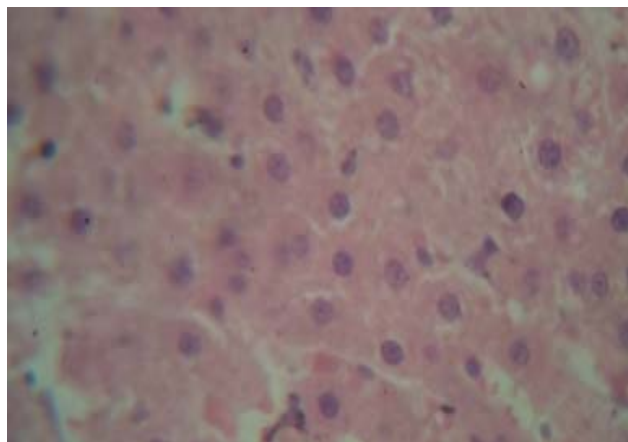


Fig. 4 Photomicrograph of the control group showing No visible lesions and normal liver architecture at x400 magnification

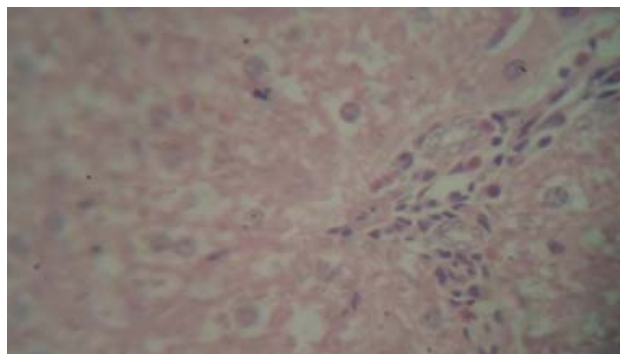


Fig. 5 Photomicrograph of the paracetamol induced group liver after 24hr of induction showing a moderate periportal neutrophilic cellular infiltration and the hepatocytes are severely vacuolated at x400 magnification

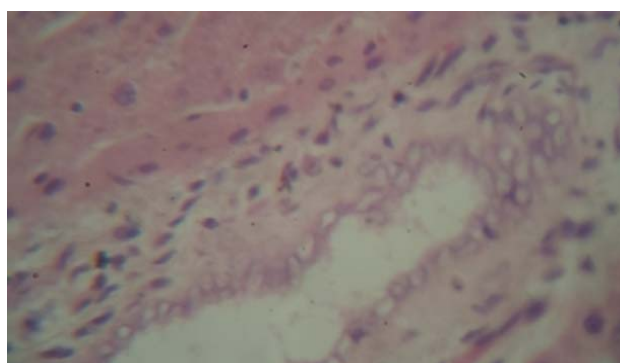


Fig. 6 Photomicrograph of the paracetamol induced group liver after 48hr of induction showing a severe portal congestion, severe periportal neutrophilic cellular infiltration and the hepatocytes are severely vacuolated. The periportal connective tissue is very prominent and there is fibroplasia and bile ductular hyperplasia at x400 magnification

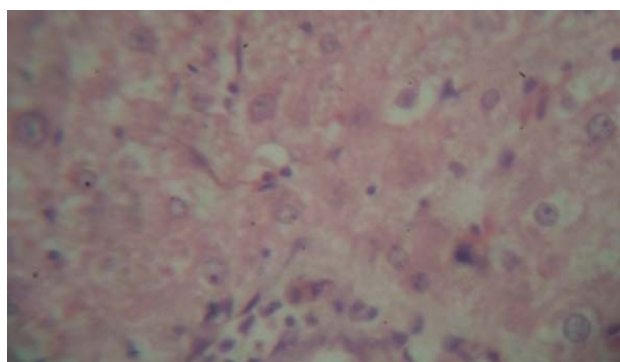


Fig. 7 Photomicrograph of the paracetamol induced group pre-treated with 100mg/kg saponin after 24hr of induction showing a moderate periportal neutrophilic cellular infiltration. The hepatocytes are mildly vacuolated at x 400 magnification

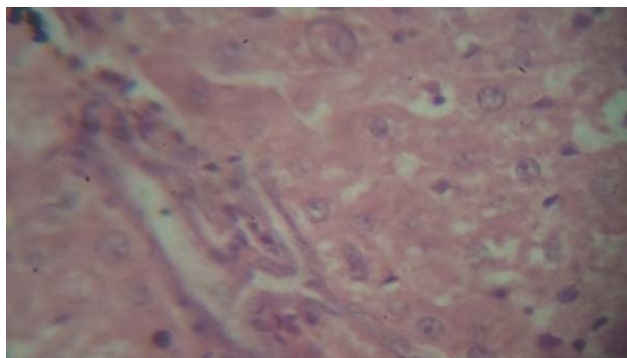


Fig. 8 Photomicrograph of the paracetamol induced group pre-treated with 100mg/kg saponin after 48hr of induction showing a very mild periportal cellular infiltration at x 400 magnification

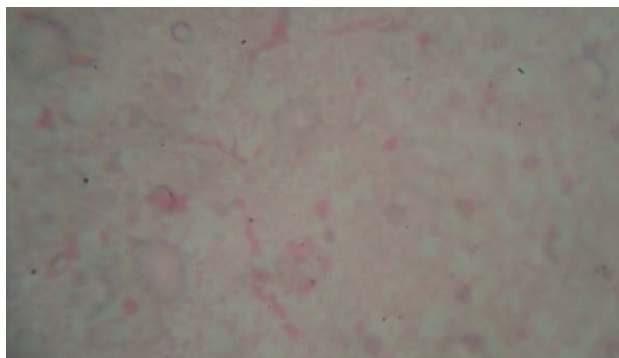


Fig. 11 Photomicrograph of the paracetamol induced group pre-treated with 400mg/kg saponin after 24hr of induction showing a moderate and diffuse vacuolation at x 400 magnification

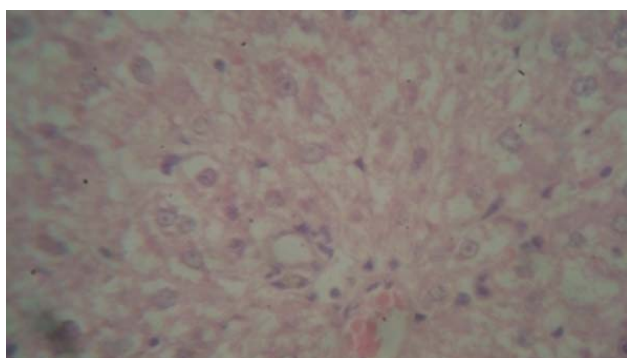


Fig. 9 Photomicrograph of the paracetamol induced group pre-treated with 200mg/kg saponin after 24hr of induction showing a mild to moderate diffuse vacuolar degeneration of the hepatocytes at x 400 magnification

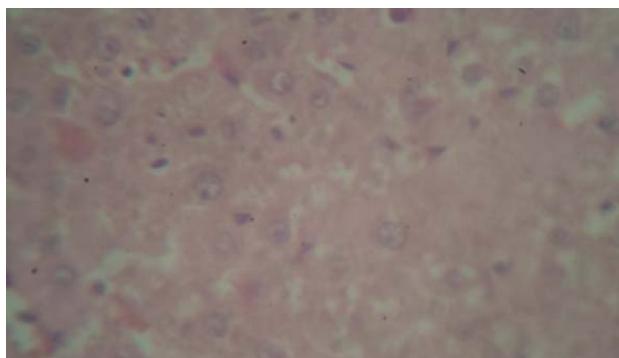


Fig. 12 Photomicrograph of the paracetamol induced group pre-treated with 400mg/kg saponin after 48hr of induction showing a very mild diffuse vacuolar degeneration of the hepatocytes. at x 400 magnification

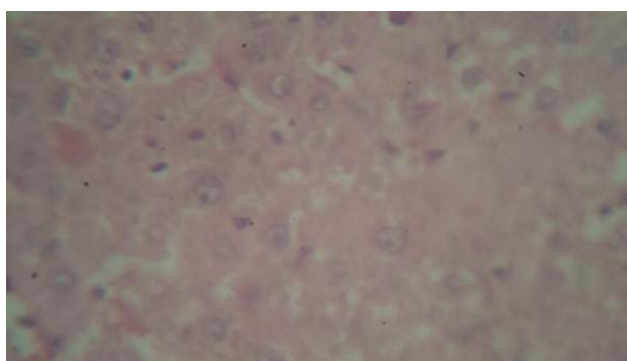


Fig. 10 Photomicrograph of the paracetamol induced group pre-treated with 200mg/kg saponin after 48hr of induction showing a very mild diffuse vacuolar degeneration of the hepatocytes at x 400 magnification

#### IV. DISCUSSION

The liver is the key organ regulating homeostasis in the body. It is involved with almost all the biochemical pathways related to growth, fight against disease, nutrient supply, energy provision and reproduction [14]. The ability of the liver to perform these functions is often compromised by numerous substances we are exposed to on a daily basis; these substances include certain medicinal agents which when taken in over doses and sometimes when introduced within therapeutic ranges injures the organ [15]. In spite of tremendous scientific advancement in the field of hepatology in recent years, liver problems are on the rise. Liver disease is a worldwide problem. Conventional, drugs used in the treatment of liver diseases are sometimes inadequate and can have serious adverse effects. Therefore, it is necessary to search for alternative drugs for the treatment of liver disease in order to replace currently used drugs of doubtful efficacy and safety [3].

Paracetamol is a well known anti-pyretic and analgesic agent, which is safe in therapeutic doses but can produce fatal hepatic necrosis in man, rats and mice with toxic doses [5]-[16]. At therapeutic levels, paracetamol is primarily metabolized in the liver by glucuronidation and sulphation;

however, a small proportion undergoes cytochrome P450 (CYP450)-mediated bioactivation to N-acetyl-p-benzoquinimine (NAPQI), which is rapidly quenched by glutathione (GSH) [6]. After an overdose of paracetamol, elevated levels of the toxic NAPQI metabolite are generated, which extensively deplete hepatocellular GSH and covalently modify cellular proteins resulting in hepatocyte death [7]. Most of the hepatotoxic chemicals including paracetamol damaged liver mainly by inducing lipid peroxidation directly or indirectly [17]. In higher animals, lipid peroxidation was known to cause destabilization and disintegration of the cell membrane, leading to liver injury, arteriosclerosis and kidney damage [5]. Peroxy radicals are important agents that mediate lipid peroxidation thereby damaging cell membrane. The paracetamol has been used as a tool to induce hepatotoxicity in experimental animals [18].

Generally, when liver plasma cell is damaged, due to the disturbance caused in transport functions of hepatocytes, a variety of enzymes located normally in cytosol is released into the blood which causes increased enzyme levels in the serum. This study shows that administration of paracetamol caused a significant ( $P < 0.05$ ) elevation of enzyme levels such as AST, ALT, ALP, and parameters such as Total Bilirubin and conjugated bilirubin, and a decrease in total protein, albumin and glucose when compared to control. There was a significant ( $P < 0.05$ ) restoration of these enzyme levels on administration of the saponin extract of the root of *Garcinia kola* at different doses of 100, 200 and 400 mg/kg. The reversal of increased serum enzymes in paracetamol-induced liver damage by the saponin extract may be due to the prevention of the leakage of intracellular enzymes by its membrane stabilizing activity. This is in agreement with the commonly accepted view that serum levels of transaminases return to normal with the healing of hepatic parenchyma and the regeneration of hepatocytes [14]. Effective control of ALP, bilirubin and total protein levels points towards an early improvement in the secretory mechanism of the hepatic cells.

Damage to hepatocytes and blood cells exacerbate the release and metabolism of haem and its metabolites including bilirubin and its excretory products. Thus, the serum level of bilirubin and its conjugate metabolites would be expected to rise. This observation was made by [19]. in rats and agrees with the outcome of the present study. The section of liver taken from animals pre-treated with saponin extract from the root of *Garcinia kola* exhibited a significant liver protection against the toxicant as evident by the cells trying to return to normal with presence of a mild to moderate diffuse vacuolar degeneration of the hepatocytes and very mild vacuolar degeneration of the hepatocytes.

The efficacy of any hepatoprotective drug is dependent on its capacity of either reducing the harmful effect or restoring the normal hepatic physiology that has been distributed by a hepatotoxin. The saponin extract of the root of *Garcinia kola* decreased paracetamol -induced elevated enzyme levels in tested groups, indicating the protection of structural integrity of hepatocytic cell membrane or regeneration of damaged liver.

## V. CONCLUSION

Saponin extract from the root of *Garcinia kola* exhibited a reasonable hepatoprotective ability against paracetamol induced hepatotoxicity. It could be explored in the synthesis of drugs for the treatment of liver disorders.

## REFERENCES

- [1] P. Aashish, S. Tarun, B. Pallavi, "Drug-Induced Hepatotoxicity", *J. App. Pharm. Sci.* 2012, 02 (05): 233-243.
- [2] Y. Virendra, D. Brijesh, P. Pratibha, L. S. Dhaleshwari, "Treatment of Liver Diseases: By Doing Survey in Government Hospitals and Private Clinics of Delhi (Shahdara) Area", *Acad. J. Pharm.* 2014, 3(3):313-316.
- [3] H.S.I. Ozbek, I.U. Ugras, E. Bayram, and E. Erdogan, "Hepatoprotective effect *Foeniculum vulgare* essential oil: A carbon tetrachloride induced liver fibrosis model in rats", *Scand. J. Anim. Sci.*, 2004, 31: 9-17.
- [4] N. Kaplowitz, "Idiosyncratic drug hepatotoxicity", *Nat Rev Drug Discov.*, 2005, 4: 489 – 499.
- [5] H. Jaeschke, C. D. Williams, M.R. McGill, A. Farhood, "Herbal extracts as hepatoprotectants against acetaminophen hepatotoxicity", *World J Gastroenterol.*, 2010, 16: 2448 – 2450.
- [6] L.P. James, P.R. Mayeux, J.A. Hinson, "Acetaminophen-induced hepatotoxicity", *Drug Metab Dispos.*, 2003, 31: 1499 – 1506.
- [7] B.K. Tiwari, R.L. Khosa, "Hepatoprotective and antioxidant effect of *Sphaeranthus indicus* against acetaminophen-induced hepatotoxicity in rats", *The Internet Journal of Tropical Medicine*, 2010 6: 1540 – 2681.
- [8] E.A. Sofowora, "Medicinal plant and traditional medicine in Africa", John Wiley and sons LTD, 2008, Pp.1-10.
- [9] J. I. Kitagawa, M. Saito, and M. Yoshihawa, "Structure of soyaponin A, a bisdesmoside of soya sapogenol A from soyabean, the seeds of *Glycine max* Merrill", *Chem. Pharm. Bull.*, 1985, 33: 1069-1072.
- [10] A.H. Khalil, and T.A. El-Adawy, "Isolation, Identification and toxicity of Saponin from different legumes", *Food Chem.*, 1994, 50: 197-201.
- [11] S. Reitman, and S. Frankel, "Determination of serum glutamate oxaloacetate and glutamic pyruvic acid transaminases", *Am. J. Clin. Pathol.* 1957, 28: 56-66.
- [12] L. Jendrassik, L. and P. Grof, "Serum Bilirubin", *J. Biochem.* 1983, 2: 297
- [13] D.M. John, S. Alan, R.T. David, "Standard haematoxyline and eosin stain for paraffin sections. Theory and practice of histological technique", Churchill Livingstone, London, 3<sup>rd</sup> Ed, 1990, p. 112.
- [14] G.P. Muthu, B. Rajkapoor, R.S. Kumar, J.W. Einstein, E.P. kumar, M.R. Kumar, K. Kavitha, P.K. Mohanraj, B. Jayakar, "Hepatoprotective and Antioxidant Effect of *Pisonia aculeata* L. against CCl<sub>4</sub>- Induced Hepatic Damage in Rats", *Sci Pharm.* 2008, 76: 203–215.
- [15] N. Gagliano, F. Grizzi, and G. Annoni, "Mechanism of aging and liver functions" *Digest. Dis. Sci.*, 2007, 25: 118-123.
- [16] S. Tamanna, R.M. Abdur, A.M. Ahad and S.F. Mahmood, "Hepatoprotective and Antibacterial Activity of Ursolic Acid Extracted from *Hedyotis corymbosa* L", *Bangladesh J. Sci. Ind. Res.*, 2010, 45(1): 27-34.
- [17] S. Sadasivan, P.G. Latha, J.M. Sasikumar, S. Rajashekar, S. Shyamal, and V.J. Shine, "Hepato-protective studies on *Hedyotis corymbosa* (L.) Lam", *J. Ethnopharmacol.* 2006, 106: 245-249.
- [18] N.B. Chaudhari, K.P. Chittam, V.R. Patil, "Hepatoprotective Activity of *Cassia Fistula* Seeds against Paracetamol-Induced Hepatic Injury in rats", *Arch Pharm Sci & Res.*, 2009, Vol 1 (2): 218 – 221.
- [19] O.J. Uko, A. Usma, M.A. Ataja, "Some biological activities of *Garcinia kola* in growing rats", *Vatarnarski Archive.* 2001, 7(5): 287 – 297.