

Performance of Compound Enhancement Algorithms on Dental Radiograph Images

S.A.Ahmad, M.N.Taib, N.E.A.Khalid, R.Ahmad and H.Taib

Abstract—The purpose of this research is to compare the original intra-oral digital dental radiograph images with images that are enhanced using a combination of image processing algorithms. Intra-oral digital dental radiograph images are often noisy, blur edges and low in contrast. A combination of sharpening and enhancement method are used to overcome these problems. Three types of proposed compound algorithms used are Sharp Adaptive Histogram Equalization (SAHE), Sharp Median Adaptive Histogram Equalization (SMAHE) and Sharp Contrast adaptive histogram equalization (SCLAHE). This paper presents an initial study of the perception of six dentists on the details of abnormal pathologies and improvement of image quality in ten intra-oral radiographs. The research focus on the detection of only three types of pathology which is periapical radiolucency, widen periodontal ligament space and loss of lamina dura. The overall result shows that SCLAHE's slightly improve the appearance of dental abnormalities' over the original image and also outperform the other two proposed compound algorithms.

Keywords—intra-oral dental radiograph, histogram equalization, sharpening, CLAHE.

I. INTRODUCTION

PRESENTLY abnormal pathologies in intra-oral dental images are not easily detected [1]. The application of image processing techniques on digital dental radiograph image has proven to improve diagnostic accuracy [2-3]. Contrast based enhancement methods such as histogram equalization in recent decades has evolved into Adaptive Histogram Equalization (AHE) and CLAHE (contrast limited adaptive histogram equalization) which has become useful tool for many clinical assessments in medical imaging modalities [2-7]. However AHE and CLAHE techniques also enhanced noise [8] and increase background inhomogeneities [9] respectively. These can be overcome by combining AHE and CLAHE with other algorithms which are successful in various applications [8, 10-11]. To best of our knowledge these techniques have not been applied to detect abnormalities in intra-oral radiograph images. Therefore based on this fact, the purpose of this study is to compare intra-oral radiograph

images pre and post processing with the sharp adaptive Histogram Equalization (SAHE), sharp median adaptive Histogram Equalization (SMAHE) and sharp contrast limited adaptive histogram equalization (SCLAHE). The comparison focuses on detecting the effectiveness of these contrast enhancement methods (CEM).

The goals of this research are; to enhance dental intra-oral radiographs by applying compound contrast enhancement methods (CEM) and to evaluate the dentists' visibility on detecting the abnormality on the dental intra-oral radiography.

This paper is organized as follows: Section 2 is about the background of this work, section 3 is the methodologies, section 4 is the results, section 5 is discussion and finally section 6 is the conclusion and future work.

II. RESEARCH BACKGROUND

Detecting accurate abnormalities in dental radiograph images are very important in assisting dentists in deciding the appropriate treatment for patients [2].

The abnormalities pathologies that are selected for this research are periapical radiolucency, widen periodontal ligament space (PDLs) and loss of lamina dura. Periapical radiolucency refers to black or dark gray areas around the apices of the teeth in the radiograph [12] as shown in Fig. 1 (a) and (b) [13].

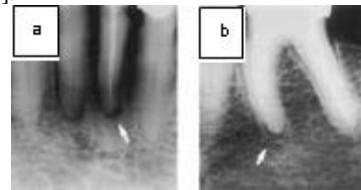


Fig. 1 Example of Periapical Radiolucency [13]

Widen periodontal ligament space (PDLs) refer to the widened of the pathology because of tooth mobility of the present of the disease as shown in Fig. 2 and label as 1. Loss or absence of lamina dura, is the indicator of the disease such as fibrous, dysplasia, hyperparathyroidism and Paget's disease and labeled as 5 in Fig. 2. A better picture can be seen in Fig.3 as a white line (arrows) that can be traced around the apical ends of all normal teeth. A widen lamina dura at the apical region of a developing tooth is a sign of tooth eruption [12].

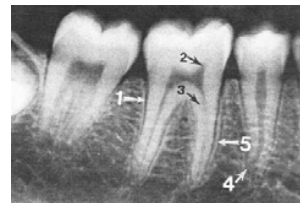


Fig. 2 Widen PDLs and loss of lamina dura [12]

S.A.Ahmad and M.N.Taib is with Advanced Signal Processing Group (ASP Group), Faculty of Electrical Engineering, UiTM Shah Alam, Malaysia (phone: 60-3-55211103; fax: 60 -03-5543 5077; e-mail: arpah@tmsk.uitm.edu.my, dr.nasir@ieee.org).

N.E.M.Khalid is with Faculty of Computer and Mathematical Sciences, University Teknologi MARA, Shah Alam, Malaysia (e-mail: elaiza@tmsk.uitm.edu.my).

R.Ahmad is with Faculty of Dentistry, University Teknologi MARA, Shah Alam, Malaysia (e-mail: drrohana@salam.uitm.edu.my).

H.Taib is with School of Dental Sciences, Universiti Sains Malaysia, Health Campus, Kubang Kerian, Malaysia, (haslina.haslina@kck.usm.my).

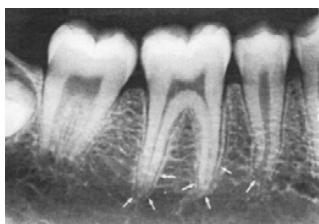

Fig. 3 Lamina Dura [12]

III. METHODS

This work consists of two phases. The first phase is applying the CEM method to all the ten images. Second phase involves dentists' evaluation of the non-processed image and images enhanced with SAHE, SMAHE and SCLAHE.

Ten intra-oral digital radiograph images are selected from Planmeca ProMax 3D machine in Faculty of Dentistry UiTM Shah Alam, Malaysia. The image technology is Cone Beam Volumetric Tomography (CBVT) with an image matrix of 1516 X 1900 pixels and pixel size is 127 μ . The image from the x-ray machine is originally in Digital Imaging and Communications in Medicine (DICOM) format and then converted to Bitmap format (bmp) for easy manipulation. The images were enhanced using SAHE and SMAHE filters developed on C++ platform. As for SCLAHE the enhancement was using ImageJ [14].

A. Applying CEM methods

The CEM techniques used in this work are based on pre processing images with sharpening algorithm prior to AHE. The first algorithm combines sharpening algorithm combined with AHE to produced SAHE. The second algorithm involves pre processing the image with sharpening algorithm prior to median filter which is later processes with AHE to produced SMAHE. The last CEM is called SCLAHE that is derived from the combination of sharpening algorithm with CLAHE.

Sharpening algorithm is used to enhance the boundaries of the periapical features. The sharpening algorithm used is Laplacian filter. The Laplacian mask used in this research is shown in Fig. 4 [15].

| | | | |
|----|----|----|--|
| | | -1 | |
| -1 | 4 | -1 | |
| | -1 | | |

Fig. 4 Laplacian Edge Detection

The median filter used in SMAHE smoothen the pixel values by sorting the pixels values in the 3 x 3 neighborhood in ascending order. Median filters are suitable due to its properties of reducing noise without compromising the edges [10].

The CLAHE algorithm reduces noise by limiting the slope associated with the pixel range to prevent saturation [16]. The saturation is prevented by calculating the slope of cumulative distribution obtained from the bin/histogram counts. The larger the bin/histogram counts the more slopes are produced.

Thresholding (clipping) helps to ensure a limit on the slope of the maximum bin/histogram count [17].

B. Dentists' Evaluation

Evaluations are done by six dentists consisting of 3 male and 3 female. The dentists' experiences are range from 6 to 20 years. This study was approved by University Teknologi MARA Ethical Committee (reference No: 600-RMI (5/1/6).

Images were viewed by the dentists on the 30 cm laptop monitor in the office room environment. The softcopy of the images were viewed using windows photo gallery software. The dentist had the freedom to zoom in and out of the images as they wish. They were also given printed copy of the images. All the images were tabulated into a table consisting of the original images, image processed with SAHE, SMAHE and SCLAHE as shown in Table 1.

TABLE I TABULATED ORIGINAL IMAGE, SAHE, SMAHE AND SCLAHE

| Image id | Original | SAHE | SMAHE | SCLAHE |
|----------|----------|------|-------|--------|
| img1 | | | | |

The evaluation was conducted in four stages. In stage 1, the quality of the dental x-ray images were evaluated. The dentist was asked to rate the quality of the dental images on scale of 1(very poor) to 5(very good) with reference to Table 2. This quality grade is based on his/her opinion or experience.

TABLE II RATING OF DENTAL X-RAY IMAGE QUALITY

| Grade | Quality Scale |
|-------|---------------|
| 1 | Very poor |
| 2 | Poor |
| 3 | Acceptable |
| 4 | Good |
| 5 | Very good |

Next, the dentist had to grade the present of the periapical radiolucency of the dental images based on the specification in Table 3.

TABLE III RATING TO DETECT THE PRESENCE OF PERIAPICAL RADIO LUCENCY

| Class | Description |
|-------|--|
| 1 | Periapical radiolucency clearly detected |
| 2 | No periapical radiolucency detected but other abnormality detected |
| 3 | No periapical radiolucency detected and no abnormality detected |

Then, in the third phase, the images were evaluated for the presence of widen periodontal ligament space as in Table 4.

TABLE IV RATING TO DETECT THE PRESENCE OF WIDEN PERIODONTAL LIGAMENT SPACE

| Class | Description |
|-------|---|
| 1 | Widen periodontal ligament space clearly detected |
| 2 | No widen periodontal ligament space detected but other abnormality detected |
| 3 | No widen periodontal ligament space detected and no abnormality detected |

Lastly, the images were evaluated for the condition attributed for loss of lamina dura based on grade presented in Table 5.

TABLE V RATING TO DETECT THE PRESENCE OF LOSS OF LAMINA DURA

| Class | Description |
|-------|--|
| 1 | loss of lamina dura clearly detected |
| 2 | No loss of lamina dura detected but other abnormality detected |
| 3 | No loss of lamina dura detected and no abnormality detected |

The classes are classified as 1 if the pathology clearly detected. Class 2 refer to no specified pathology appear in the image but other abnormality appeared. As for class 3, both the specified pathology as well as other pathology also not appeared in the images. Class 3 reflects healthy teeth (since no lesion could be observed) or the image quality is not good at all since it cannot show any lesion clearly.

IV. RESULTS

The results are discussed in the following manner;

a) The image quality based on dentists' evaluation before and after processing with SAHE, SMAHE and SCLAHE. The analysis was based on mean and standard deviation (SD).

b) The perception between dentists in evaluating the pathologies. The analysis was also based on mean and standard deviation (SD).

c) The clearly detected of the pathologies before and after processing with SAHE, SMAHE and SCLAHE. The analysis was based on mode of data.

d) The best detected pathology before and after processing with SAHE, SMAHE and SCLAHE. This also was evaluated based on mode of data.

A. Analysis of Image Quality's perception

Table 6 show the evaluation method based the mean and standard deviation (SD) of the dentists' evaluation towards the image quality. For the 10 images sample, four is from the upper jaw and six is lower jaw. It was labeled as U1- U4 for upper jaw and L1 – L6 for lower jaw and the comparison are based on original image value.

TABLE VI COMPARISON BETWEEN ORIGINAL AND ENHANCED IMAGE FOR MEAN AND STANDARD DEVIATION (SD) OF IMAGE QUALITY FOR DENTISTS' EVALUATION

| Img. Id | Original | Mean± SD | | |
|---------|-----------|-----------|-----------|-----------|
| | | SAHE | SMAHE | SCLAHE |
| U1 | 3.50±0.55 | 1.83±0.75 | 1.83±0.75 | 3.67±0.52 |
| U2 | 3.67±0.52 | 1.83±0.75 | 1.33±0.52 | 3.33±0.82 |
| U3 | 4.17±0.41 | 1.33±0.52 | 1.83±0.75 | 4.00±0.63 |
| U4 | 3.67±0.82 | 2.33±0.52 | 1.83±1.17 | 3.50±0.55 |
| L1 | 3.50±1.05 | 2.67±0.82 | 1.33±0.52 | 3.00±0.89 |
| L2 | 3.83±0.75 | 2.33±0.82 | 2.17±1.17 | 3.50±1.22 |
| L3 | 3.67±0.82 | 1.50±0.84 | 1.33±0.82 | 4.00±1.26 |
| L4 | 2.50±1.05 | 1.83±0.75 | 1.67±0.82 | 2.67±1.03 |
| L5 | 3.67±0.82 | 2.50±1.05 | 1.67±0.82 | 3.33±0.82 |
| L6 | 3.67±0.82 | 1.33±0.82 | 1.17±0.41 | 3.67±0.52 |

SMAHE has the same SD value with original image. U3 shows all increase value in SD and for U4 only SAHE and SCLAHE show a decreasing value.

As for the lower jaw, the decrease value of SD had been shown by all except L2. L1 and L4 had the value of SD that over 1 for original images. L1 SD value for SMAHE had the lowest. As for L4, the lowest SD value is by SAHE. L3, L5 and L6 show the same SD value for the original images. For L3, SMAHE show the lowest SD value but SCLAHE SD value is over 1. L5 show that SD value of SMAHE and SCLAHE are the same as original value. As for L6, SCLAHE show the lowest SD value.

B. Analysis of evaluation the pathologies' perception

Table 7 – Table 9 show the evaluation method based the mean and standard deviation (SD) of the dentists' evaluation based on their perception for teeth pathologies.

Table 7 shows comparison between original and enhanced image for mean and standard deviation (SD) of the presence of periapical radiolucency. It shows that U1 – U3 as the value of SD is 0.00 for original image, SMAHE (U1- U3) and SCLAHE (U1 and U3). As for U4, the SD value is all the same except for SMAHE.

TABLE VII COMPARISON BETWEEN ORIGINAL AND ENHANCED IMAGE FOR MEAN AND STANDARD DEVIATION (SD) OF THE PRESENCE OF PERIAPICAL RADIOLUCENCY

| ImageID | Original | Mean± SD | | |
|---------|-----------|-----------|-----------|-----------|
| | | SAHE | SMAHE | SCLAHE |
| U1 | 1.00±0.00 | 1.33±0.52 | 1.00±0.00 | 1.00±0.00 |
| U2 | 1.00±0.00 | 2.33±1.03 | 1.00±0.00 | 1.33±0.82 |
| U3 | 1.00±0.00 | 1.33±0.82 | 1.00±0.00 | 1.00±0.00 |
| U4 | 2.33±0.82 | 2.33±0.82 | 2.50±0.84 | 2.33±0.82 |
| L1 | 2.00±0.89 | 2.67±0.52 | 2.00±0.89 | 2.00±0.63 |
| L2 | 1.00±0.00 | 1.83±0.98 | 1.00±0.00 | 1.00±0.00 |
| L3 | 1.00±0.00 | 2.83±0.41 | 1.83±0.75 | 1.00±0.00 |
| L4 | 1.00±0.00 | 1.83±0.98 | 1.00±0.00 | 1.00±0.00 |
| L5 | 1.00±0.00 | 1.83±0.75 | 1.00±0.00 | 1.00±0.00 |
| L6 | 1.83±0.98 | 3.00±0.00 | 2.17±0.98 | 1.67±1.03 |

For the lower jaw, L2-L5 shows SD value of 0.00 for the original images. As for L2, L4 and L5, the SD also 0.00 for SMAHE and SCLAHE and for L3, only SCLAHE had value of 0.00. L6 had the value of SD decrease for SAHE and SMAHE only.

Table 8 shows comparison between original and enhanced image for mean and standard deviation (SD) of the presence of presence of widen periodontal ligament space. It shows that only U1 (original) and U2 (SCLAHE) had the SD value of 0.00. U3 shows that the SD value were the same for all except for SMAHE. U4 shows that all the SD is over 1.

As for lower jaw, L2 (original and SMAHE), L3 (original and SCLAHE), L4 (SCLAHE) and L6 (SCLAHE) had 0.00 SD values. As for L5, SCLAHE had the same SD value with original.

TABLE VIII COMPARISON BETWEEN ORIGINAL AND ENHANCED IMAGE FOR MEAN AND STANDARD DEVIATION (SD) OF THE PRESENCE OF THE PRESENCE OF WIDEN PERIODONTAL LIGAMENT SPACE

| ImageID | Original | Mean± SD | | |
|---------|-----------|-----------|-----------|-----------|
| | | SAHE | SMAHE | SCLAHE |
| U1 | 1.00±0.00 | 1.17±0.41 | 1.50±0.84 | 1.33±0.82 |
| U2 | 1.17±0.41 | 2.00±1.10 | 1.83±0.75 | 1.00±0.00 |
| U3 | 1.33±0.82 | 2.33±0.82 | 2.17±0.75 | 1.33±0.82 |
| U4 | 2.33±1.03 | 2.00±1.10 | 2.83±0.41 | 2.00±1.10 |
| L1 | 1.83±0.98 | 1.83±0.98 | 2.17±0.75 | 1.67±0.82 |
| L2 | 1.00±0.00 | 1.83±0.98 | 1.00±0.00 | 1.33±0.82 |
| L3 | 1.00±0.00 | 2.00±1.10 | 1.33±0.82 | 1.00±0.00 |
| L4 | 1.17±0.41 | 1.33±0.82 | 1.17±0.41 | 1.00±0.00 |
| L5 | 1.33±0.52 | 1.83±0.98 | 1.50±0.55 | 1.33±0.52 |
| L6 | 1.33±0.52 | 2.83±0.41 | 2.00±0.89 | 1.00±0.00 |

Table 9 shows comparison between original and enhanced image for mean and standard deviation (SD) of the presence of loss of lamina dura. The upper jaw shows that none of the SD value is 0.00 and U4 had an increased value of SD compared to the original. As for U1-U3 all SD were decreased.

TABLE IX COMPARISON BETWEEN ORIGINAL AND ENHANCED IMAGE FOR MEAN AND STANDARD DEVIATION (SD) OF THE PRESENCE OF LOSS OF LAMINA DURA

| ImageID | Original | Mean± SD | | |
|---------|-----------|-----------|-----------|-----------|
| | | SAHE | SMAHE | SCLAHE |
| U1 | 1.50±0.84 | 1.17±0.41 | 1.17±0.41 | 1.33±0.82 |
| U2 | 2.00±0.89 | 1.83±0.98 | 1.33±0.52 | 1.50±0.84 |
| U3 | 1.33±0.52 | 1.50±0.84 | 1.33±0.52 | 1.17±0.41 |
| U4 | 2.33±0.82 | 1.83±0.98 | 1.83±0.98 | 2.17±0.98 |
| L1 | 1.50±0.84 | 1.67±1.03 | 1.33±0.52 | 1.33±0.82 |
| L2 | 1.50±0.84 | 1.33±0.82 | 1.17±0.41 | 1.17±0.41 |
| L3 | 1.33±0.52 | 2.33±1.03 | 1.83±0.98 | 1.33±0.52 |
| L4 | 1.17±0.41 | 2.17±0.98 | 1.50±0.55 | 1.33±0.52 |
| L5 | 1.33±0.52 | 1.83±0.98 | 1.33±0.52 | 1.33±0.52 |
| L6 | 2.17±0.98 | 2.33±1.03 | 2.17±0.98 | 2.00±1.10 |

The lower jaw shows that L1 had a decrease for SMAHE and SCLAHE only. As for L2 all show decrease as SMAHE and SCLAHE had the same value. As for L3 – L4 all the SD value showed and increasing value.

C. Analysis of clearly detected pathologies

Fig.5-7 show graphs that based on the rating of the detected pathologies. No 1, stands for clearly detected pathologies, no.2 for no pathologies detected but other abnormality detected and no. 3 stands for no pathologies detected and no abnormality detected. This phase focus on no 1(pathology is clearly detected).

Fig.5 shows that for detecting periapical radiolucency, original image had 48 images compared to others.

As for Fig.5 and Fig. 7, it shows that SCLAHE had been chosen by the dentists to clearly detected the widen PDLs (49) and loss of lamina dura (41).

Periapical radiolucency

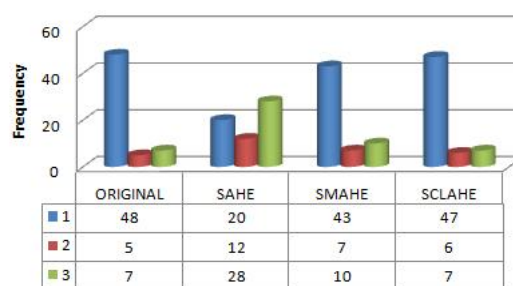


Fig.5 Periapical Radiolucency pathology's detecting rate

Widen Periodontal Ligamen Space

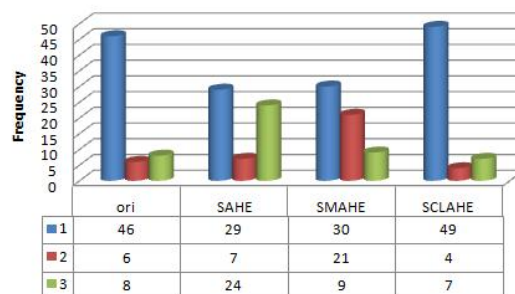


Fig.6 Widen Periodontal Ligament Space (PDLs) pathology's detecting rate

Loss of Lamina Dura

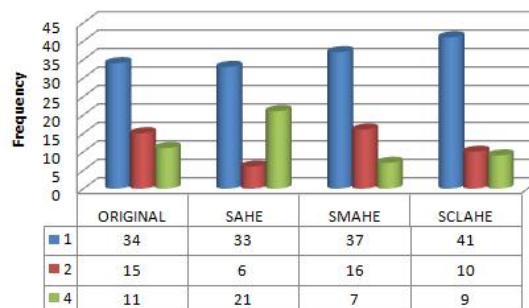


Fig. 7 Loss of Lamina Dura pathology's detecting rate

D. The detected pathology before and after processing with SAHE, SMAHE and SCLAHE.

Table 10 – Table 12 shows the results of detected pathology by six dentists on the ten images. Due to that the images involved were 60.

Table 10 is the comparison of the CEM that had been graded as 1 (clearly detected). It shows that out of 60 observations, original image can clearly detected 48 of periapical radiolucency pathology. As for SAHE it can detect only 20, SMAHE can detected 43 and SCLAHE can detected 47. For widen PDLs, original image can detect 46, SAHE 29, SMAHE 30 and SCLAHE is 49. As for Loss of lamina dura, original image can detect 34, SAHE 33, SMAHE 37 and SCLAHE 41.

TABLE X COMPARISON BETWEEN CEM FOR CLASS =1 (CLEARLY DETECTED)

| Pathologies | Original | SAHE | SMAHE | SCLAHE |
|-------------------------|----------|------|-------|--------|
| Peraipical Radiolucency | 48 | 20 | 43 | 47 |
| Widen PDLs | 46 | 29 | 30 | 49 |
| Loss of lamina dura | 34 | 33 | 37 | 41 |

Table 11 is the comparison of the CEM that had been graded as 2 (No pathologies detected but other abnormality detected).

The first row shows that out of 60 observations no periapical radiolucency detected but other abnormalities exist. The total images that have the criteria are as follows: original images have 5, SAHE has 12, SMAHE has 7 and SCLAHE has 6.

The second row shows that no widen PDLs detected but there are other abnormalities in original images (6), enhanced image by SAHE (7), SMAHE (21) and SCLAHE (4).

Lastly in third row, there is no loss of lamina dura detected but other abnormality exists. 15 other abnormalities are detected in original images, 6 in SAHE, 16 in SMAHE and 10 in SCLAHE.

TABLE XI COMPARISON BETWEEN CEM FOR CLASS = 2 (NO PATHOLOGIES DETECTED BUT OTHER ABNORMALITY DETECTED)

| Pathologies | Original | SAHE | SMAHE | SCLAHE |
|-------------------------|----------|------|-------|--------|
| Peraipical Radiolucency | 5 | 12 | 7 | 6 |
| Widen PDLs | 6 | 7 | 21 | 4 |
| Loss of lamina dura | 15 | 6 | 16 | 10 |

Table 12 is the comparison of the CEM that had been graded as 3 (No pathologies detected and no abnormality detected). This grade may reflect that the CEM method is not good because it cannot detect anything or the image is a healthy tooth so no abnormality detected.

No periapical radiolucency is detected as well as no abnormality is detected in original (7), SAHE (28), SMAHE(10) and SCLAHE (7) images.

No widen PDLs detected as well as no other abnormality is found in original (8), SAHE (24), SMAHE (9) and SCLAHE (7) images.

No Loss of lamina dura is detected as well as no other abnormality detected in original (11), SAHE (21), SMAHE(7) and SCLAHE (9) images .

TABLE XII COMPARISON BETWEEN CEM FOR CLASS = 3 (NO PATHOLOGIES DETECTED AND NO ABNORMALITY DETECTED)

| Pathologies | Original | SAHE | SMAHE | SCLAHE |
|-------------------------|----------|------|-------|--------|
| Peraipical Radiolucency | 7 | 28 | 10 | 7 |
| Widen PLS | 8 | 24 | 9 | 7 |
| Loss of lamina dura | 11 | 21 | 7 | 9 |

V.DISCUSSION

Table 6 is about the evaluation method based the mean and standard deviation (SD) of the dentists' evaluation towards the image quality. It shows that for upper jaw (U1-U4), all the dentists have the similar opinion (SD below 1.00). As for lower jaw, all the SD value is below 1.00 except for L1 and L4, dentists' opinion were not consistent as the SD value is over 1.

Table 7 – Table 9 show the evaluation method based the mean and standard deviation (SD) of the dentists' evaluation based on their perception for teeth pathologies.

Table 7 shows that for upper jaw, all the dentists have the same opinion for the presence of periapical radiolucency as U1-U3 had the SD value of 0.00. This also the same for lower jaw as majority of the jaw shows SD of 0.00 for original images as well as enhanced image by SMAHE and SCLAHE. By looking at all 40 SD values, it shows that 45% SD had the value of 0.00 for the presence of periapical radiolucency.

Table 8, shows comparison between original and enhanced image for mean and standard deviation (SD) of the presence of presence of widen periodontal ligament space (PLDs). Based on the 40 SD values only 18% shows SD value of 0.00 however the decreases value of SD compared to original image is 13% (out of 30 SD values of enhanced image only).

Table 9 shows comparison between original and enhanced image for mean and standard deviation (SD) of the presence of loss of lamina dura. It shows that none of SD value achieved 0.00 however the decrease value of SD compared to original is 30% (out of 30 SD values of enhanced image only).

Fig.5-7 show graphs that based on the rating of clearly detected pathologies. Overall it shows that SCLAHE is best to detect the presence of widen PDLs and loss of lamina dura compared to others. The percentage for detection rate of SCLAHE for periapical radiolucency is 78%, for widen PDLs is 81% and for loss of lamina dura is 68%. As for periapical radiolucency, original image is best to describe its existence. The percentage detection rate of original image for periapical radiolucency is 80%, for widen PDLs is 77% and for loss of lamina dura is 57%. The performance of SMAHE in clearly detecting the pathologies also good as follows: It able to clearly detect periapical radiolucency with 72%, for widen PDLs with 50% and loss of lamina dura with 62%. As for SAHE, it's performance is the lowest as only able the detect the pathologies below 60%.

Table 10 -12 describe the overall image population in this research. Table 10 shows that the sample had all the pathologies. An interesting finding had been discovered for widen PDLs and loss of lamina dura, SCLAHE performed better in discovering these pathologies rather than original image. It shows that out of 60 observations, all dentists agree that SCLAHE able to clearly detect 49 of widen PDLs abnormality and 41 of loss of lamina dura abnormality. As for table 11, other abnormality may exist in the images, SAHE overcome original image in detecting periapical radiolucency. SMAHE also leading in detecting widen PDLs and loss of lamina dura. Lastly table 12, shows that SAHE is leading which may reflect that it is cannot detect anything or the image is a healthy tooth so no abnormality detected.

VI. CONCLUSION AND FUTURE WORK

This work shows some interesting preliminary research on the effectiveness of CEM methods on diagnostic ability of intra-oral dental x-ray images in detecting certain pathologies. SCLAHE performs on par with the original images in detecting periapical radiolucency. However it can detect widen PDLs and loss of lamina dura better than original. This will provide dentists' with more information for better diagnosis. Future work will be further investigation on methodology of dentists' evaluation as well as data acquisition.

REFERENCES

- [1] B.Kullendorff and M.Nilsson, "Diagnostic accuracy of direct digital dental radiograph for the detection of periapical bone lesions", *Oral. Surg.Oral. Med. Oral. Pathol. Oral Radiol Endod*, vol:82,pp:585-589, 1996
- [2] M.Mehdizadeh and S.Dolatyar, "Study of Effect of Adaptive Histogram Equalization on Image Quality in Digital Preapical Image in Pre Apex Area", research *Journal of Biological Science*, pp: 922 – 924, vol: 4, issue: 8, 2009
- [3] W.E.G.W.Alves,E.Ono,J.L.O.Tanaka,E.M.Filho,L.C.Moraes,M.E.L.Mor aes and J.C.M.Castilho, "Influence of image filters on the reproducibility of measurements of aveolar bone loss", *Journal of Applied Oral Science*, Vol. 4(6), pp: 415 – 420, 2006.
- [4] N.M.Noor, N.E.A.Khalid M.H.Ali and A.D.A.Numpang,"Enhancement of Soft Tissue Lateral Neck Radiograph with Fish Bone Impaction Using Adaptive Histogram Equalization(AHE),*The 2nd International Conference on Computer Research and Development*,2010.
- [5] N.R.S.Praveen, M.Phil, and M.Sathik, "Enhancement of Bone Fracture Images by Equalization Methods", *International Conference on Computer Technology and Development*, pp: 391-394, 2009.
- [6] N.E.A.Khalid, N. E., Manaf, M., Aziz, M. E., & Ali, M. H. (2007, Nov. 25-28). CR images of metacarpel cortical edge detection-bone profile histogram approximation method. *Intelligent and Advanced Systems,. ICIAS* .pp: 702-708, 2007
- [7] T.Kitasaka, K.Mori, J.Hasegawa and J.Toriwaki,"A Method for Extraction of Bronchus Regions from 3D Chest X-ray CT Images by Analyzing Structural Features of the Bronchus",*FORMA*, Vol:17,No. 4, pp: 321- 338, 2002.
- [8] H.Yoon,Y.Han, and H.Hahn,"Image Contrast Enhancement based on Sub-histogram Equalization Techniques without Over-equalization Noise", *International Journal of Computer Science and Engineering* 3:2,2009.
- [9] P.Rahmati,G.Hamarneh, D.Nussbaum and A.Adler, " A New Preprocessing Filter for Digital Mammograms, *Lecture Notes in Computer Science*,vol: 6134, pp: 585-592, 2010.
- [10] P.Jagatheeswari, S.S.Kumar and M.Rajaram, " A Novel Approach for Contrast Enhancement Based on Histogram Equalization Followed By Median Filter", *ARPJN Journal of Engineering and Applied Sciences*, Vol. 4, No.7, 2009
- [11] W.Zhiming and T.Jianhua, "A fast implementation of Adaptive Histogram Equalization", *8th International Conference on Signal Processing (ICSP)*, 2006
- [12] O.E.Langland, R.P.Langlais and J.W.Preece, "Principles of Dental Imaging", Lippincott Williams & Wilkins, 2002.
- [13] O.Molven, A.Halse, I.Fristad and M.Jankowski, " Periapical changes following root-canal treatment observed 20-27 years postoperatively", *International Journal of Endodontic Research*, vol: 35(9), pp: 784-90, 2002
- [14] ImageJ , Image Processing and Analysis in Java official website <http://rsbweb.nih.gov/ij/>.
- [15] Allen, B. Wilkinson M. Parallel Programming, Techniques and Applications Using Networked Workstations and Parallel Computers, Pearson,2005.
- [16] J.Poulist and M.Aubin, "Contrast Limited Adaptive Histogram Equalization(CLAHE),http://radonc.ucsf.edu/research_group/jpoulist/Tutorial/HU/Lesson7.htm, accessed on 4th June 2010.
- [17] E.Pisano et al,"Contrast Limited Adaptive Histogram Equalization Image Processing to Improve the Detection of Simulated Spiculations in Dense Mammograms", *Journal of Digital Imaging*", Vol 11, pp: 193-200, 1998