

Morpho-histological Study of the Bursa of Fabricius of Broiler Chickens during Post-hatching Age

T. Khenenou, M. Melizi, and H. Benzaoui

Abstract—The study of morphometric and histologic evolutions of the Bursa of Fabricius during 27 weeks of post-hatching age, realized on 88 subjects of broiler chicken they permitted to collect information about the morpho-histological aspect according to their post-hatching age; showed the size and the weight of the Bursa of Fabricius which reach their maximum between the 10th and the 11th week of age and the physiologic involution phenomena. These variations are in close relationship to the sexual maturity. These results can be used in the diagnosis of viral disease such as the Gumboro disease, Marek disease.

Keywords—Broiler chicken, bursa of Fabricius, Morpho-histology, post-hatching evolution.

I. INTRODUCTION

BURSA of Fabricius is an epithelial and lymphoid organ that is found only in birds. The bursa develops as a dorsal diverticulum of the proctodaeal region of the cloaca. The luminal (interior) surface of the bursa is plicated with as many as 15 primary and 7 secondary plicae or folds.

These plicae have hundreds of bursal follicles containing follicle-associated epithelial cells, lymphocytes, macrophages, and plasma cells. Lymphoid stem cells migrate from the fetal liver to the bursa during ontogeny. In the bursa, these stem cells acquire the characteristics of mature, immunocompetent B cells. The bursa is active in young birds. It atrophies after about six months, reaches its maximum size at 8–10 weeks of age then, like the thymus, it undergoes involution. By 6–7 months most bursae are heavily involuted [1].

The bursa is surrounded by a thick, smooth muscle layer like other hollow organs; an immunological organ that plays a primordial role in the poultry immunity [2].

II. MATERIALS AND METHODS

A. Chickens

The experimental study was carried out on 88 subjects of Broiler chickens. At each age a sample of 4 subjects was taken randomly among a band of 2000 subjects of only one poultry

T. Khenenou is with the National Institute of, Agroveterinary, Souk ahres, Algeria (phone: 033880067; fax: 033880067; e-mail: tarekkhenenou@yahoo.fr).

M. Melizi, Jr., was with Batna University, Algeria (e-mail: Mohamed.melizi@yahoo.fr).

H. Benzaoui is with the EPH Batna, Algeria (e-mail: benzaouihassina@gmail.com).

race, it is ISA 15 (chicken with fast growth). The animals are high on the ground, on litter heap of sheaves in a building into hard with windows non-ventilated and not air-conditioned.

The chicks are high first day of the blossoming until the 27 weeks age under the same conditions of breeding, during the period from January to July 2008. The birds had no detectable developmental disorders and diseases that may cause any problem in the abnormalities of the histological architecture of lymphoid tissues.

B. Tissue Processing for Morphohistological Study

The birds were killed by cervical dislocation method and the bursa of Fabricius, collected through ventral abdominal dissection, which is free from pathological lesions as can be seen in Fig. 1.

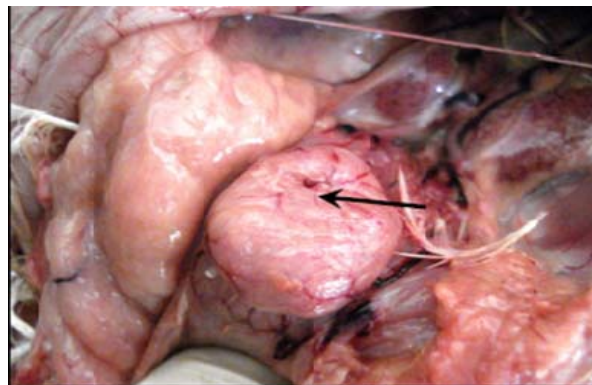


Fig. 1 Bursa of Fabricius (arrow) in its normal position

Bursa of Fabricius were carefully removed and their diameters were measured using a bursameter and their average and relative weights are recorded. The Bursa obtained from chickens were fixed in Bouin's fluid [3] for 24 hours and were dehydrated in the series of ascending grade of alcohol followed by clearing in two changes in xylene, and the tissues then infiltrated with different grades of melted paraffin in the oven.

The tissues were then embedded in paraffin and finally the sections were cut at 5 μ thickness using sliding microtome [4].

After cutting, the sections were floated on Luke-warm water in a 3 floatation bath at 38° C for stretching and then the sections were mounted on clean slides using egg albumin and

dried on a slide warmer at 38° C [5]. The sections were stained using Mayer's Hematoxylin and Eosin (H & E).

The histological structures of the bursa of Fabricius were observed using light microscope under low ($\times 10$) and high ($\times 40$) magnification. Photographs from the selected specimens were taken for better illustration of the results then the measurements of length and the width averages of the follicles of Bursa of Fabricius according to the age.

III. RESULTS AND DISCUSSION

The study of the evolution of the Bursa of Fabricius according to the age, during the postnatal life was realized on a sample of 88 subjects, cut down and dissected, from the first week to the 27th week.

Morpho-histological study of the Bursa of Fabricius

A. Morphometric Study

The results of growth of the Bursa of Fabricius expressed in Fig. 2, showed three different phases: the first is characterized by an accelerated growth; this phase begins from the first week of age and continues until the 10th week of age where it reaches its maximum size (6 mm). The second phase begins from the 10th week and finishes on the 20th week of age. From the 20th, we notice a fast involution of the Bursa characterized by one reduction in the bursa diameter which passes from 05 to 0.62 at the 27th week. These results are close to the studies of [6], [7] realized on chicken with the observation of a physiological involution which coincides with sexual maturity of chickens. This involution may be the result of the sexual hormones actions. Fig. 3 shows the results relating to the evolution of the average weight of the Bursa of Fabricius of broiler chicken.

The average weight of this body passes from 0.09g to the first postnatal week to reach an average of 1.95 ± 1.217 g at the 10th week of age and to arrive at 1.725 ± 0.694 g at the 11th week, at the 23rd week it starts a slow anatomical involution to reach 0.01g and a total regression about the 27th week.

According to studies carried out [6], [7] more the chicken grows; more the Bursa of Fabricius increase in volume, its weight is proportional to the age and with the weight of the subject, Until sexual maturity, then it enters a physiological phase of regression; these results are very close to our study. "Reference [8], [9] show similar results".

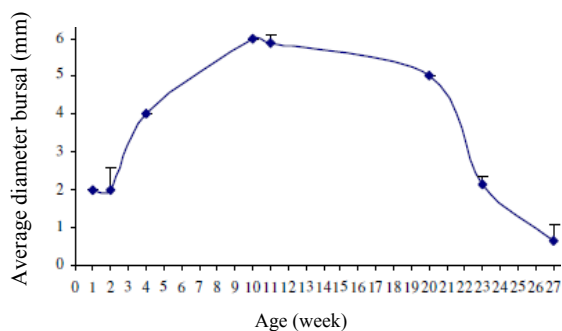


Fig. 2 Evolution of the average diameter of the Bursa of Fabricius

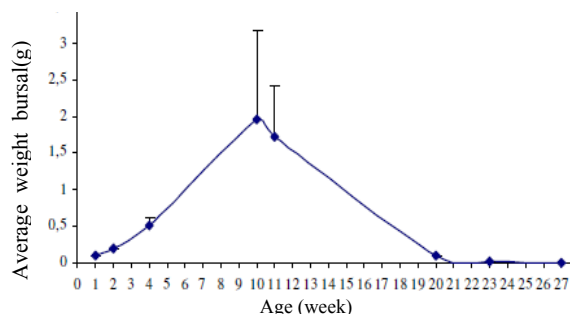


Fig. 3 Evolution of the average weight of the Bursa of Fabricius

The Bursa of Fabricius, reached the peak of development enters 10th and 11th week of age. "Reference [10] shows that in chicken the Bursa of Fabricius reached its peak of development between the 4th and the 12th week".

This can be due to the chicken stock used in work and also to antigenic stimulations (breeding conditions, vaccination, disease...).

B. Histological Changes of the Bursa of Fabricius According to the Age

The morphometric and macroscopic changes of the bursa were accompanied by histological modifications. The first week is characterized by fringes appearances that represent lymphoepithelial follicles; and formed later the bursal folds; bordered by an epithelium that separates them from the bursal lumen. Most of the bursal layers were readily observed during the first week of age, these layers are serosa; the most external layer and is the site of blood and lymphatic vessels route. This layer is followed deeply by the muscularis and mucosa.

While the fourth week is marked by the development of bursal follicles; these follicles are well defined and their zones are well separated and the interstitial connective tissue is quite visible as can be seen in Fig. 4.

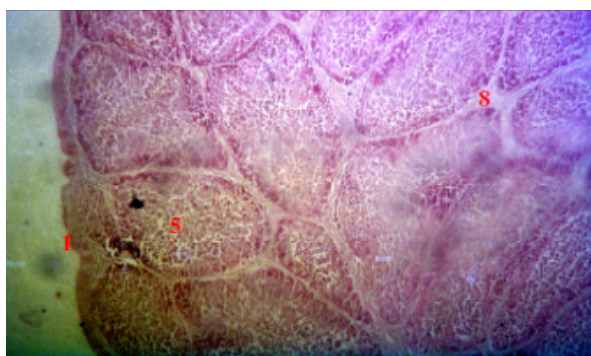


Fig. 4 Follicles of the bursa of Fabricius at the 4th week (H&E, X100)
1: Capsule, 5: bursal follicle, 8: la lamina propria.

At ten (10) weeks the lymphoid follicles continue their development and increase in size to reach the maximum; the length is $756.55 \mu\text{m}$ and the width is about $396.25 \mu\text{m}$ (Fig. 5).

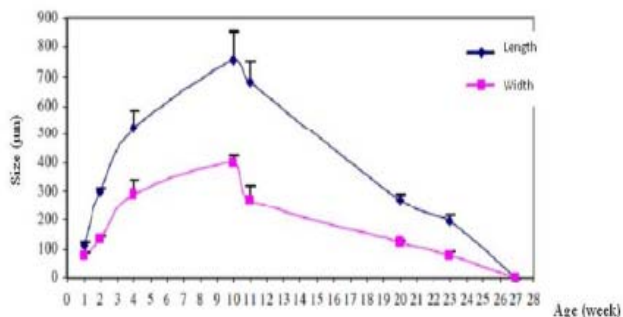


Fig. 5 Size of the follicles (µm)

The cortex and medulla are well demarcated, the lamina propria is well developed (Fig. 6), the atrophy of the lymphoid follicles of the bursa starts at the 11th week due to connective tissue infiltration of the interfollicular spaces and the follicular lymphoid tissue is gradually replaced.

At the 23rd week, a very significant interstitial fibrosis and degeneration of the lymphoid follicles was noticed, the bursal follicles lose their lymphoid characteristics and zones (Fig. 7). The follicular structure of the bursa is hardly visible and the interstitial fibrosis is very significant at the 27th week.

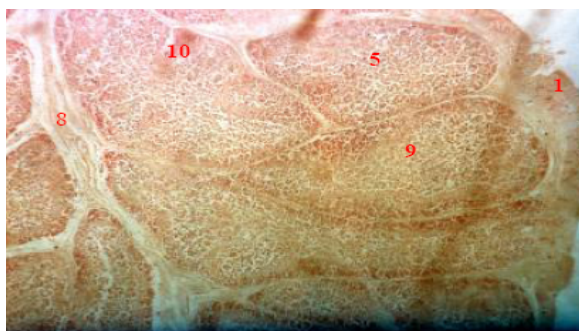


Fig. 6 Bursal fold at the 10th week (H&E x100)

1: Capsule, 5: Follicule, 8: lamina propria, 9: medulla, 10: cortex.

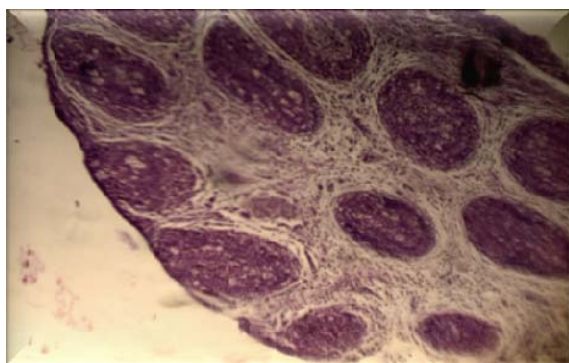


Fig. 7 Follicular atrophy of the bursa of Fabricius (H&E x100)

Our results are in complete agreement with the works of Brugere-Picoux and Silim (1992) who mentioned that Bursa of Fabricius undergoes a slow anatomical involution from the 10th week of age with atrophy of the follicles. The regression

of the Bursa is in relation to the increase in the rate of the sex hormones at the time of puberty.

IV. CONCLUSION

The morphometric and histological study of the Bursa of Fabricius according to the age during the postnatal life showed that the size and the weight of the Bursa of Fabricius reach their maximum between the 10th and the 11th week.

After ten weeks of growth, the Bursa of Fabricius starts slow morpho-histological involution that consists of an exhaustion of the follicles. The complete regression of the Bursa appears clearly to the 27th week and remains in the fibrous state in adult broilers.

The results showed that histological modifications are well correlated with the morphometrical changes. These variations are in close relationship to the sexual maturity.

REFERENCES

- [1] E. Ciriaco, P.P. Pinera, B. Diaz-Esnal, B. and R. Laura, "Age-related changes in the avian primary lymphoid organs thymus and bursa of Fabricius", 2003, pp. 482-487.
- [2] P. Toivanen, H. Naukkarinene H., and O. Vannino, "Avian Immunology", Vol.,1: 79-92, 1987.
- [3] E. Ciriaco, P.P. Pinera, B. Diaz-Esnal, B. and R. Laura, "Age-related changes in the avian primary lymphoid organs thymus and bursa of Fabricius", 2003, pp. 482-487.
- [4] R. Darboux, "Réalisation de coupe histologique pour le microscope optique". Faculté des sciences de la Santé de l'Université d'Abomey-Calavi Bénin". 1994.
- [5] L. Luna, "Manuel of Histology, Staining methods of armed forces," 3rd ed. vol. 3, J. Peters, Ed. New York: McGraw-Hill, 1968, pp. 43.
- [6] J.R. Hupaya, "Evaluacion de la bursa de fabricio en pollos broilers", *Estudio anatomohistologico*. Thesis .Peru. 1995.
- [7] Kuney, "Bursametre a tool for measuring the size of the bursa of Fabricius," *Solvay animal health*. USA, 2000.
- [8] J. Alamorgot, "Manuel d'anatomie et d'autopsie aviaire". <http://www.Point-vet.fr>. 2005.
- [9] J. Brugère-Picoux, and A. Silim, "Manuel de pathologie aviaire". ed. vol. Ed.france, 1992.
- [10] H.S. Lillehoj, and J. Trout, Coccidia: A review of recent advances in immunity and vaccine development avian pathology," 1993, pp. 22-23.