

# Monitoring the Effect of Doxorubicin Liposomal in VX2 Tumor Using Magnetic Resonance Imaging

Ren-Jy Ben, Jo-Chi Jao, Chiu-Ya Liao, Ya-Ru Tsai, Lain-Chyr Hwang, Po-Chou Chen

**Abstract**—Cancer is still one of the serious diseases threatening the lives of human beings. How to have an early diagnosis and effective treatment for tumors is a very important issue. The animal carcinoma model can provide a simulation tool for the studies of pathogenesis, biological characteristics, and therapeutic effects. Recently, drug delivery systems have been rapidly developed to effectively improve the therapeutic effects. Liposome plays an increasingly important role in clinical diagnosis and therapy for delivering a pharmaceutical or contrast agent to the targeted sites. Liposome can be absorbed and excreted by the human body, and is well known that no harm to the human body. This study aimed to compare the therapeutic effects between encapsulated (doxorubicin liposomal, Lipodox) and un-encapsulated (doxorubicin, Dox) anti-tumor drugs using magnetic resonance imaging (MRI). Twenty-four New Zealand rabbits implanted with VX2 carcinoma at left thighs were classified into three groups: control group (untreated), Dox-treated group, and LipoDox-treated group, 8 rabbits for each group. MRI scans were performed three days after tumor implantation. A 1.5T GE Signa HDxt whole body MRI scanner with a high resolution knee coil was used in this study. After a 3-plane localizer scan was performed, three-dimensional (3D) fast spin echo (FSE) T2-weighted Images (T2WI) was used for tumor volumetric quantification. Afterwards, two-dimensional (2D) spoiled gradient recalled echo (SPGR) dynamic contrast-enhanced (DCE) MRI was used for tumor perfusion evaluation. DCE-MRI was designed to acquire four baseline images, followed by contrast agent Gd-DOTA injection through the ear vein of rabbit. A series of 32 images were acquired to observe the signals change over time in the tumor and muscle. The MRI scanning was scheduled on a weekly basis for a period of four weeks to observe the tumor progression longitudinally. The Dox and LipoDox treatments were prescribed 3 times in the first week immediately after the first MRI scan; i.e. 3 days after VX2 tumor implantation. ImageJ was used to quantitate tumor volume and time course signal enhancement on DCE images. The changes of tumor size showed that the growth of VX2 tumors was effectively inhibited for both LipoDox-treated and Dox-treated groups. Furthermore, the tumor volume of LipoDox-treated group was significantly lower than that of Dox-treated group, which implies that LipoDox has better therapeutic

effect than Dox. The signal intensity of LipoDox-treated group is significantly lower than that of the other two groups, which implies that targeted therapeutic drug remained in the tumor tissue. This study provides a radiation-free and non-invasive MRI method for therapeutic monitoring of targeted liposome on an animal tumor model.

**Keywords**—Doxorubicin, dynamic contrast-enhanced MRI, lipodox, magnetic resonance imaging, VX2 tumor model.

## I. INTRODUCTION

**D**RUG targeting to specific tumors with minimum toxicity and superior therapy efficacy is one of the important goals for cancer treatment pharmaceuticals [1]. Liposome is one of the hottest carriers in drug delivery system for years. It can be absorbed and discharged by the human body, and is well known that no harm to the human body clinically. Clinical-Grade Vasculature-Targeted Liposomal Doxorubicin has been shown that it can be enhanced antitumor efficacy [2]. It has been shown that Liposomal doxorubicin has a lower cardiologic toxicity than doxorubicin [3]. Lipodox has been demonstrated that it can improve radiotherapy response in hypoxic prostate cancer xenografts [4]. Recently, thermosensitive liposomal drug delivery system becomes a hot topic in the area of drug delivery systems [5], [6]. Importantly, the effective inhibition of in vivo tumor growth was proved using Lipodox. Hence, we proposed to investigate the treatment efficacy of free Dox and Lipodox for muscle VX2 tumor in an animal model. The aim of this proposal was to compare the differences in treatment efficacy between encapsulated and un-encapsulated anti-tumor drugs. The discrepancy among untreated, encapsulated and un-encapsulated drug treatment was investigated.

## II. MATERIALS AND METHODS

This study intended to set up a New Zealand White (NZW) Rabbit VX2 tumor model to longitudinally observe the development of the tumor after drug therapy using MRI techniques.

### A. Animal Model

VX2 carcinoma tumor was implemented at left thighs of NZW rabbits, while right thighs were referred as the normal tissue. Three days after tumor implantation, magnetic resonance imaging scan was performed.

### B. Imaging Protocol

1.5T GE Signa HDxt whole body magnetic resonance scanner and 8-channel high resolution knee coils was used in this study. NZW rabbit was anesthetized with an intramuscular

Ren-Jy Ben is with the Department of Internal Medicine, Division of Infectious Diseases, Kaohsiung Armed Forces General Hospital, Kaohsiung, Taiwan, R.O.C.; the Department of Biomedical Engineering, I-SHOU University, Kaohsiung, Taiwan, R.O.C.; the Department of Electrical engineering, I-Shou University Taiwan, R.O.C. (e-mail: benrjbridge@gmail.com).

Jo-Chi Jao is with the Department of Medical Imaging and Radiological Sciences, Kaohsiung Medical University, Kaohsiung, Taiwan, R.O.C. (e-mail: jochja@kmu.edu.tw).

Chiu-Ya Liao, Ya-Ru Tsai are with the Department of Biomedical Engineering, I-SHOU University, Kaohsiung, Taiwan, R.O.C. (e-mail: j69278059@gmail.com).

Lain-Chyr Hwang is with the Department of Electrical engineering, I-SHOU University, Kaohsiung, Taiwan, R.O.C. (e-mail: lain@isu.edu.tw).

Po-Chou Chen is with the Department of Biomedical Engineering, I-SHOU University, Kaohsiung, Taiwan, R.O.C. (corresponding author, phone: 886-7-6151100; fax: 886-7-6155150; e-mail: pccchen@isu.edu.tw).

injection using Zoltil 50 and Rompun 2% mix solution before MRI scanning. The VX2 tumor site was landmarked at the center of the knee coil. The scanning protocol was listed as follows: (1) 2D fast spoiled gradient recalled echo (FSPGR) pulse sequence was scanned to obtain multi-slice localizer images for subsequent scanning, (2) T2-weighted (T2W) spin echo (SE) pulse sequence was performed to obtain axial images, (3) 3D fast spin echo (FSE) pulse sequence was performed to achieve 3-D axial images on tumor sites, and finally (4) 2D spoiled gradient recalled echo (SPGR) was used to assess the signal changes over time before and after Gd-DOTA contrast agent injection. Dynamic contrast enhanced (DCE) MRI scanning was arranged to obtain 4 reference images first. After Gd-DOTA was bolus injected into the ear vein of a NZW rabbit, 32 consecutive images were acquired to evaluate the signal intensity changes and enhancement pattern over time.

Twenty four NZW rabbits were classified into three groups with 8 rabbits in each group: the control group (without treatment), Dox treatment group (free doxorubicin) and Lipodox (doxorubicin liposomal) treatment group. After magnetic resonance imaging scanning protocol was performed to obtain VX2 tumor images, Dox or Lipodox was injected via the ear vein of NZW Rabbit for chemotherapy. Totally, three times chemotherapy and four times MRI scans were performed on a weekly basis for longitudinal investigation.

3D FSE images were used for quantitating tumor volume changes over time using ImageJ software. The region of interest (ROI) was segmented and the ROI values were measured on VX2 tumor in DCE MRI images. Then, the dynamic signal intensity changes of tumor over time were obtained. Furthermore, the treatment efficacy between Lipodox, and Dox treatment was compared.




Fig. 1 The time course tumor DCE MR images (Pre-treatment) show contrast enhanced signal intensity changes with time after Gd-DOTA injection

The scanning parameters for FSE were TR = 2000 ms, TE = 72.36 ms, FA = 90°, FOV = 16 × 16 cm<sup>2</sup>, BW = 25 kHz, matrix = 256 × 128, NEX = 1, number of slice = 8 and slice thickness = 5 mm. And the scanning parameters for DCE-MRI were TR = 80 ms, TE = 1.32 ms, FA = 60°, FOV = 16 × 16 cm<sup>2</sup>, BW =

31.25 kHz, matrix = 256 × 256, NEX = 1, number of slice = 8 and slice thickness = 5 mm.

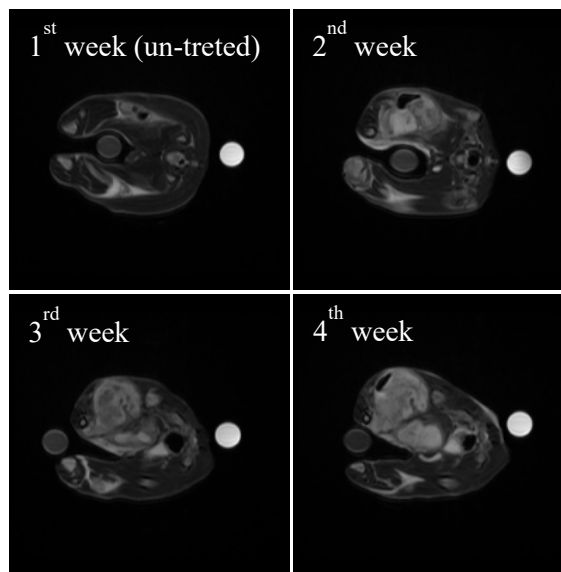


Fig. 2 The time course tumor DCE MR images of control group

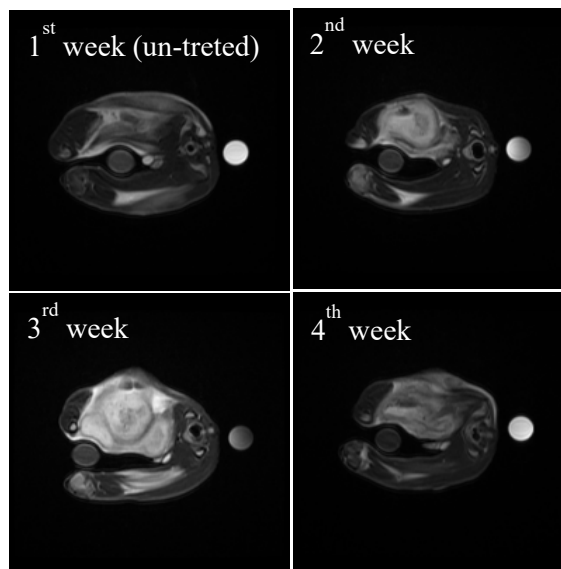


Fig. 3 The time course tumor DCE MR images of Dox treatment group

### III. RESULTS

The time series tumor DCE-MR images are shown in Fig. 1. It was found that the signal intensity increased with time, i.e. contrast enhancement. The tumor rim was clearly shown. Fig. 2 shows the time course tumor DCE-MR images of control group with larger and larger tumor size with time. Figs. 3 and 4 show the time course tumor DCE-MR images of Dox treatment and Lipodox treatment groups, respectively. Figs. 5-8 show the time varying intensity curve of tumor on DCE images at subsequent weeks, respectively. It is found that MR signal

intensity of tumor for Lipodox treatment group was the lowest for all weeks. However, the MR signal intensity of Dox treatment group was lower than untreated group at the first week, and higher than untreated group at the 2<sup>nd</sup> and the 3<sup>rd</sup> week, and became lower again at the 4<sup>th</sup> week. The time varying tumor volume measured from FSE images is listed in Table I.

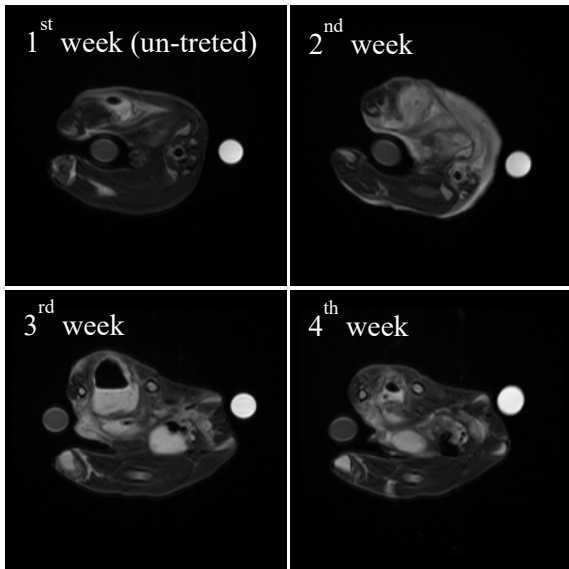


Fig. 4 The time course tumor DCE MR images of Lipo-Dox treatment group

TABLE I  
THE TIME VARYING TUMOR VOLUME

Week	1 <sup>st</sup> (cm <sup>3</sup> )	2 <sup>nd</sup> (cm <sup>3</sup> )	3 <sup>rd</sup> (cm <sup>3</sup> )	4 <sup>th</sup> (cm <sup>3</sup> )
Untreated	10.2	28.2	58.3	80.8
DOX	31.8	32.9	55.9	36.2
LIPODOX	15.4	55.4	48.4	34.2

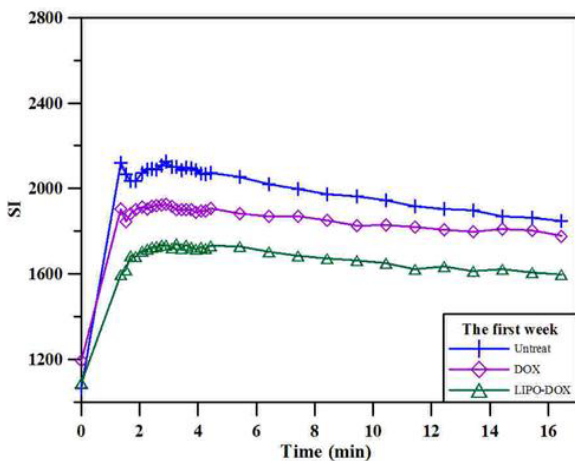


Fig. 5 The time varying intensity of tumor on DCE images at first week (Pre-treatment)

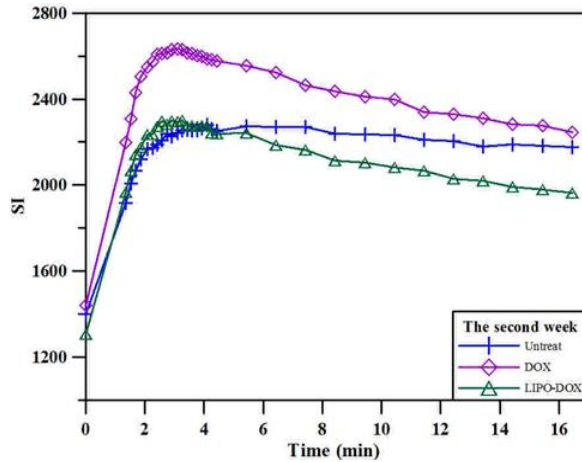


Fig. 6 The time varying intensity of tumor on DCE images at second week

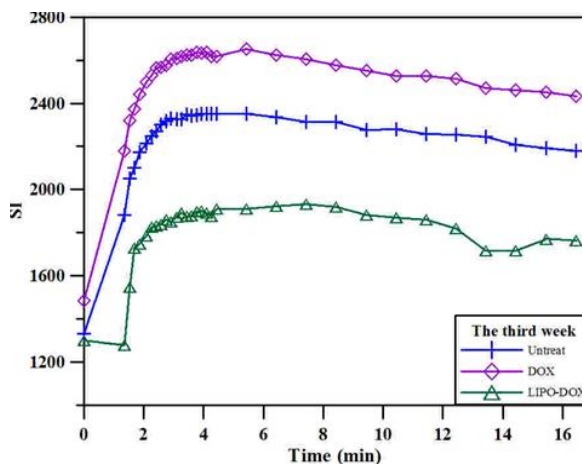


Fig. 7 The time varying intensity of tumor on DCE images at third week

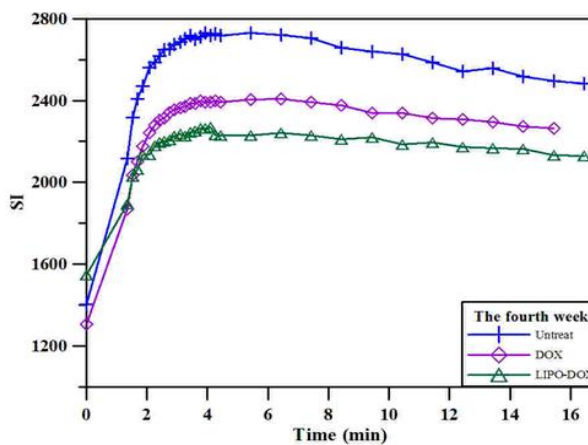


Fig. 8 The time varying intensity of tumor on DCE images at fourth week

## IV. DISCUSSION AND CONCLUSIONS

The results found that both encapsulated treatment group and unencapsulated treatment group can effectively inhibit the growth of tumors. DCE MRI found the signal intensity in the encapsulated treatment group was significantly lower than the other two groups which implied that the encapsulated anti-cancer drugs targetedly remained in tumor tissue. T2W MRI found the tumor volume of the encapsulated treatment group was significantly lower than the other two groups. It was an evidence to show encapsulated treatment group is superior to unencapsulated treatment group. In conclusion, the treatment efficacy of Lipodox is superior to Dox treatment due to its targeted characteristics.

## REFERENCES

- [1] J. Choi, H.Y. Kim, E.J. Ju, J. Jung, J. Park, H.K. Chung, J.S. Lee, H.J. Park, S.Y. Song, S.Y. Jeong, E.K. Choi, "Use of macrophages to deliver therapeutic and imaging contrast agents to tumors," *Biomaterials*, vol. 33, no. 16, pp. 4195-203, June 2012.
- [2] F. Pastorino, D.D. Paolo, F. Piccardi, B. Nico, D. Ribatti, A. Daga, G. Baio, C. E. Neumaier, C. Brignole, M. Loi, D. Marimpietri, G. Pagnan, M. Cilli, E. A. Lepekkin, S.V. Garde, R. Longhi, A. Corti, T. M. Allen, J. J. Wu, M. Ponzoni, "Enhanced Antitumor Efficacy of Clinical-Grade Vasculature-Targeted Liposomal Doxorubicin," *Clin Cancer Res.*, vol. 14, no. 22, pp. 7320-9, Nov. 2008.
- [3] G. Balbi, S. Visconti, A. Monteverde, M.A. Manganaro, A. Cardone, "Liposomal doxorubicin: a phase II trial," *Acta Biomed.*, Vol. 78, no. 3, pp. 210-3, Dec. 2007.
- [4] E. Hagtvet, K. Røe, D.R. Olsen, "Liposomal doxorubicin improves radiotherapy response in hypoxic prostate cancer xenografts," *Radiat Oncol.*, vol. 6, pp. 135, Oct. 2011.
- [5] R.M. Staruch, K. Hynynen, R. Chopra, "Hyperthermia-mediated doxorubicin release from thermosensitive liposomes using MR-HIFU: therapeutic effect in rabbit Vx2 tumours," *Int J Hyperthermia*, Vol. 31, no. 2, pp. 118-33, Mar. 2015.
- [6] B. Kneidl, M. Peller, G. Winter, L.H. Lindner, M. Hossann, "Thermosensitive liposomal drug delivery systems: state of the art review," *Int J Nanomedicine*, vol. 9, pp. 4387-98, Sep. 2014.