

Level Set and Morphological Operation Techniques in Application of Dental Image Segmentation

Abdolvahab Ehsani Rad, Mohd Shafry Mohd Rahim, Alireza Norouzi

Abstract—Medical image analysis is one of the great effects of computer image processing. There are several processes to analysis the medical images which the segmentation process is one of the challenging and most important step. In this paper the segmentation method proposed in order to segment the dental radiograph images. Thresholding method has been applied to simplify the images and to morphologically open binary image technique performed to eliminate the unnecessary regions on images. Furthermore, horizontal and vertical integral projection techniques used to extract the each individual tooth from radiograph images. Segmentation process has been done by applying the level set method on each extracted images. Nevertheless, the experiments results by 90% accuracy demonstrate that proposed method achieves high accuracy and promising result.

Keywords—Integral production, level set method, morphological operation, segmentation.

I. INTRODUCTION

ANALYSIS of such medical images focuses on particular region on the images and the other regions of image which is useless for analysis must be eliminate, because it might cause the wrong result in analysis. Hereby, segmentation is one of the essential processes in medical image analysis applications. Segmentation subdivides an image and extracts its constituent particular regions or object” [1]. In dental radiograph image viewpoint, segmentation is to identify and classify individual tooth in image or parts of the tooth such as crown or pulp. Dental radiographs can be utilizes in applications such as human identification systems or assisting in clinical aspects like dental diagnosis systems and dental treatment systems. However to achieve the suitable result with high accuracy it is necessary to use appropriate methods in segmentation process.

Image segmentation methods have been improved in the past several decades but it remains a complex and difficult process due to differences in the images. There are many researches which have been done on dental radiograph segmentation. Analysis of dental images has some difficulty in compare with other medical images. The difficulties are such as: artifacts used in treatment process; impacted teeth; different variation of teeth and space of missing teeth. Due to these problems still finding the accurate and proper method in the segmentation of dental x-ray images is challenging

A. E. R. is with UTMViCubeLab in Faculty of Computing, University Technology Malaysia (UTM), 81310 Malaysia (corresponding author; phone: +60177033485; e-mail: erabdolvahab2@live.utm.my).

M. S. M. R. and A. N. are with UTMViCubeLab in Faculty of Computing, University Technology Malaysia (UTM), 81310 Malaysia (e-mail: shafry@utm.my, nsalireza2@live.utm.my).

process.

The goal of this study is extract the each individual tooth from radiograph images and apply the segmentation process on each extracted region. In order to achieve this goal, we need to automate the process of segmenting the dental x-ray images and distinguish the teeth from background and other tissues.

Anil K. [2] proposed a semi-automatic contour extraction method for tooth segmentation by using integral projection and Bayes rule, in which the integral projection is semi-automatically applied for tooth isolation since an initial valley gap point is required. Jindan Zhou and Mohamed Abdel-Mottaleb [3] presented a segmentation method that consists of three steps: image enhancement, region of interest localization, and tooth segmentation by using morphological operations and Snake method. Omaira Nomir, and Mohamed Abdel-Mottaleb [4] developed a fully automated approach based on iterative thresholding and adaptive thresholding for dental X-ray image segmentation. Keshtkar and Gueaieb [5] introduced a swarm-intelligence based and a cellular-automata model approach for segmenting dental radiographs. Eyad Haj Said et al. [6] offered a mathematical morphology approach to the problem of teeth segmentation, which used a series of morphology filtering operations to improve the segmentation, and then analyzed the connected components to obtain the desired region of interests (ROIs). Li et al. [7] proposed a semi-automatic lesion detection framework by using two coupled level set functions in which initial contour are derived from a trained support vector machine to detect areas of lesions from dental X-ray images.

In this paper we present a method to extract each individual tooth following; the use of global thresholding and obtain the integration of intensity in vertical and horizontal direction to distinguish the area of each tooth in image. Subsequently level set method performed to extract the exact regions of tooth and eliminate the unnecessary areas to complete the segmentation process as demonstrated in Fig. 1.

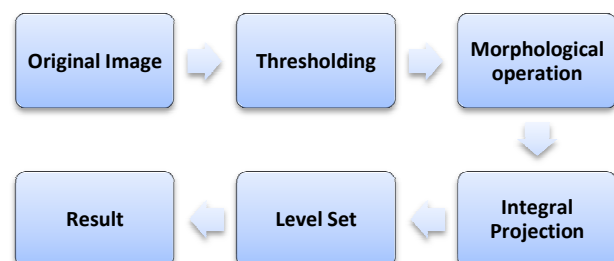


Fig. 1 Framework of segmentation process

II. RADIOGRAPH SEGMENTATION AND TOOTH EXTRACTION

The first step of the segmentation process eliminates the teeth from the background applying a thresholding technique; this step is described in Section II A. The next step extracts the each individual tooth area using integral projection; this step is described in Section II B. The next eliminates the extra pixels which is unnecessary and refines the extracted tooth area; this step is described in Section II C. The last step segments the exact shape and boundary of each extracted tooth; this step is described in Section II D. Fig. 1 illustrates a framework of the main steps of the segmentation algorithm.

A. Thresholding

Dental radiographs images which known as X-ray images have many variations of intensity distribution in regions from image to another image due to difficulties which mentioned before. There are three different regions according to intensity distribution: The lowest intensity regions, corresponds to the background or soft tissues. The average intensity regions, corresponds to bone area and the highest intensity regions which corresponds to the teeth area [8]. There are regions with over exposes intensity on teeth area which corresponds to the filling tooth with artifacts. But in some images the intensity of the teeth area is quite close to the bone area, which makes the segmentation process with more difficulty.

Thresholding is the simplest and fastest pixel-based method. There are many techniques in thresholding. The simplest technique in thresholding is to partitioning the image histogram into two areas and assigning the single global threshold "T". In this case Otsu's thresholding method performed which chooses the threshold to minimize the intraclass variance of the black and white pixels and labeling each pixel as the foreground or background. Labeling is based on value of pixel in gray level, whether it is greater than "T" value or lesser than it [1].

$$g(x) = \begin{cases} r_0 & \text{iff } (x) \geq T \\ r_1 & \text{otherwise} \end{cases} \quad (1)$$

Thresholding produces the binary image which simplifies the image analysis for next step.

B. Morphological Operation

The aim of this step is to analysis the connected components based on geometric properties (area and dimension) and then remove the unnecessary objects. After thresholding process the images still contain some regions which must remove. The morphologically open binary image technique applied to remove the all connected components (objects) that has fewer than predefined certain pixels and produce another binary image. The small areas which contain lesser pixels are definitely not teeth area and it might be the gum area or some noises on radiograph images. Fig. 2 shows the refinement process using morphologically open binary image technique.

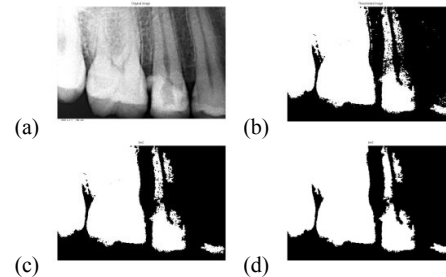


Fig. 2 (a) Original image (b) Thresholded image (c) Eliminate the unnecessary objects (d) Refill the necessary objects

C. Integral Projection

The different of intensities in regions on radiographs in most of the images gives the advantage of separating the individual region of each tooth. The horizontal line can separate the region of tooth from top to bottom. This can be achieved by using the horizontal projection as follows:

Let $g(i,j)$ be the $m \times n$ binary image obtained from the thresholding step, the horizontal integral projection is:

$$H(i) = \sum_{j=1}^n g(i, j) \quad (2)$$

To separate the upper and lower regions in the teeth by straight line, the minimum value of accumulated points in horizontal direction of image considered as top of the tooth and the maximum value of accumulated points in horizontal direction of image considered as the bottom line of teeth.

Separation of individual tooth regions has been done using same integral projection process. The aim is to find the lines that separate the adjacent tooth. This achieved by using the vertical integral projection method. If $g(i,j)$ be the $m \times n$ binary image obtained from the thresholding step, the horizontal integral projection is:

$$V(j) = \sum_{i=1}^m g(i, j) \quad (3)$$

Locating the area between teeth is possible because of different intensity value of teeth area and other area. To separate the vertical lines between the each tooth the image divided into the 5 areas and process will be done by finding the valleys in the result of vertical projection. The reason of dividing the image in 5 areas is the type of radiographs which is periapical dental radiograph and mostly the numbers of teeth in this type are under 4 teeth. The extraction of each individual tooth has some conditions such as the a) width of each region to eliminate the extraction of non-completed tooth or teeth which located in the contours of radiographs and not clear or not completed as one tooth. b) Eliminate the extraction of missing tooth places. Fig. 3 shows the individual tooth separation lines in vertical and horizontal status.

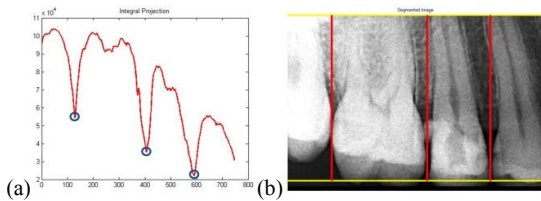


Fig. 3 (a) vertical integral projection with selected points for vertical lines (b) straight lines to separate each tooth

D. Level Set Method

The level set method Proposed by Osher and J. Sethian for “front propagation, being applied to models of ocean waves and burning flames” [9]. And Malladi applied it for medical imaging purposes [10]. Level set methods have attracted more and more attention of researchers from different areas [11], [12]. The concept of the level set method is to enclose a curve within a surface. Because of robust detection in image characteristics such as corners and topological changes, the level set method has been used extensively. The segmentation boundary can be defined as a part of the surface where the contour level is 0, i.e., the zero level set. Let ϕ represent the implicit surface such that

$$\phi(X,t) = \pm d$$

where x is a position in our domain (the image), t is time, and d is the distance between position x and the zero level set. The sign in front of d is positive if x is outside the zero level set. Otherwise, the sign is negative.

$$\phi(x, y, 0) = \begin{cases} -d(x, y, \gamma) & \text{if } (x, y) \text{ insid the front} \\ 0 & \\ d(x, y, \gamma) & \text{if } (x, y) \text{ outsid the front} \end{cases} \quad (4)$$

To move the level set surface, let define velocity field F , that specifies how contour points move in time. Based on application-specific physics such as time, position, normal, curvature, image gradient magnitude will be specifies. Then the initial value for the level set function, $\phi(x,y,t)$, based on initial contour will be computed. The value of ϕ will be adjust over the times and current contour defined by $\phi(x(t),y(t))=0$. Then the iteration will be repeated until the convergence on the boundary of curve. The last obtained curve is the segmented area and final level in level set calculation. The algorithm of level set segmentation method is described as below:

- Initialize the front $\gamma(0)$
- Compute $\phi(x,y,0)$
- Iterate:
 - $\phi(x,y,t+1) = \phi(x,y,t) + \Delta\phi(x,y,t)$
 - until convergence
- Mark the front $\gamma(\text{tend})$

The definition of initial contour is important to segmentation with level set, which the wrong selection will

result the wrong segmentation result. As the input images for segmentation is the extracted individual tooth so the initial contour selection can be easily done by selection the predefined area for all the images. Fig. 4 demonstrates the correct and wrong initial contour selection boundary for some images.

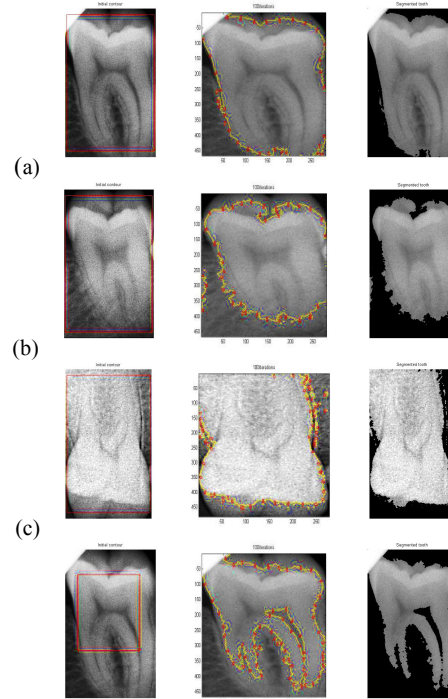


Fig. 4 Level set segmentation results. (a)(b)(c) Correct initial contour and correct segmentation result. (d) Wrong initial contour and wrong result

III. RESULT AND DISCUSSIONS

The proposed method have been applied on the dataset of 32 gray level digital periapical dental radiograph which collected form medical center of university technology Malaysia (UTM). Each radiograph images is in dimension of 512x748, the last 12 pixel in vertical direction contains the details of each image which has been removed during the processing steps. The Otsu’s Thresholding method result is quite satisfactory to eliminate the background of images to use in extraction of individual tooth. But some images which contain more noises or contain over exposes will appear white in result of thresholding even it belongs to the background. However the thresholding result is fair enough to next step which is for extraction of tooth regions. The extractions of individual tooth in horizontal and vertical directions have been done. For locating the vertical lines the image divided into 5 equal column sections (150 pixels) and scanning process applied within these sections by conditions which mentioned in Section II C. In some cases the radiographs have many problems which mentioned before and due to these difficulties the tooth extraction may give wrong result. Fig. 5 shows the

wrong results of some false positive tooth extractions.

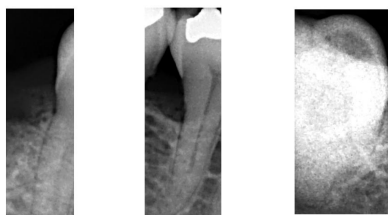


Fig. 5 Some wrong false positive segmentations

The extracted individual tooth considered as input for the level set method, level set method with predefined initial contour (20 pixels space from bottom and top and 5 pixels space from left and right) applied. Because that the images in this step are extracted tooth with different dimensions there is not exact boundary for initial contour. The experiment of proposed method shows that the segmentation of extracted tooth is quite robust. The problem may occur during segmentation with level set when the selected initial contour is wrong or radiograph image has more noise.

IV. CONCLUSION

In this paper an accurate method for segmenting of periapical dental radiographs was described. And result obtained 65 segmented teeth form 32 images which were contain 72 individual teeth. The process following by applying thresholding method and morphologically open binary image technique for remove the unnecessary objects on image and then integral projection technique was applied for locate the horizontal and vertical straight lines for each tooth on the image. The extracted individual tooth images segmented using level set method and exact tooth region was segmented. Result shows the proposed method is promising and accurate method. For future work, due to the difficulties on radiograph images it is necessary to improve the method by consideration on variation of teeth and missing tooth space.

REFERENCES

- [1] R.C. Gonzales and R. E. Woods, "Digital Image Processing", Prentice Hall, Inc, New Jersey, 2008.
- [2] Anil K. Jain, Hong Chen, "Matching of dental X-ray images for human identification", Pattern Recognition 37, pp. 1519 – 1532, 2004.
- [3] Jindan Zhou, Mohamed Abdel-Mottaleb, "A content-based system for human identification based on bitewing dental X-ray images", Pattern Recognition 38, pp. 2132 – 2142, 2005.
- [4] OmairaNomir, and Mohamed Abdel-Mottaleb, "Human Identification from Dental X-Ray Images Based on the Shape and Appearance of the Teeth" IEEE transactions on information forensics and security, vol. 2, no. 2, June 2007.
- [5] Keshtkar, F., Gueaieb, W. "Segmentation of Dental Radiographs Using a Swarm Intelligence Approach", IEEE Canadian Conference on Electrical and Computer Engineering, pp. 328–331, 2006.
- [6] Eyad Haj Said, DiaaEldin M. Nassar, GamalFahmy, and Hany H. Ammar, "Teeth Segmentation in Digitized Dental X-Ray Films Using Mathematical Morphology" IEEE transactions on information forensics and security, vol. 1, no. 2, june 2006
- [7] Li, S., Fevens, T., Krzyzak, A., Jin, C., Li, S. "Semi-automatic Computer Aided Lesion Detection in Dental X-rays Using Variational Level Set", Pattern Recognition 40, 2861– 2873, 2007.
- [8] O. Nomir and M. Abdel-Mottaleb, "A system for human identification from X-ray dental radiographs", Pattern Recognition 38, 2005.
- [9] Malladi, R., Sethian, J. A., and Vemuri, B. Shape modeling with front propagation: A level set approach. IEEE Transactions on Pattern Analysis and Machine Intelligence 17, 2, 158 – 175, 1995
- [10] Deng J, Tsui HT. A fast level set method for segmentation of low contrast noisy biomedical images. Pattern Recogn Lett , 161–9, 2002.
- [11] Nilsson B, Heyden A. A fast algorithm for level set-like active contours. Pattern Recogn Lett;24:1331–7, 2002.
- [12] Malladi, R., Sethian, J. A., and Vemuri, B. Shape modeling with front propagation: A level set approach. IEEE Transactions on Pattern Analysis and Machine Intelligence 17, 2, 158 – 175, 1995.