

Investigation of the Tattooed Skin by OCT

Young Geun Kim, Tae Woo Lee, Changmin Yeo, Jung min Yoo,
Yeo Jin Kang, Tack-Joong Kim, Byungjo Jung, Ji Hun Cha, Chan Hoi Hur,
Dong-Sup Kim, Ki Jung Park and Han Sung Kim*

Abstract—The intention of this lessons is to assess the probability of optical coherence tomography (OCT) for biometric recognition. The OCT is the foundation on an optical signal acquisition and processing method and has the micrometer-resolution. In this study, we used the porcine skin for verifying the abovementioned means. The porcine tissue was sound acknowledged for structural and immunohistochemical similarity with human skin, so it could be suitable for pre-clinical trial as investigational specimen. For this reason, it was tattooed by the tattoo machine with the tattoo-pigment. We detected the pattern of the tattooed skin by the OCT according to needle speed. The result was consistent with the histology images. This result showed that the OCT was effective to examine the tattooed skin section noninvasively. It might be available to identify morphological changes inside the skin.

Keywords—mechanical skin damage, optical coherence tomography, tattooed skin

I. INTRODUCTION

TATTOO is a mark created by popping pigment into the dermis of the skin [1]. In recent years the interest of tattoo is increased for decorative function. As tattoo is prevalent among the nations, the safety of tattoos related to the harmful side effects (infection and wound) gets to be important issue [2-6]. The reason for infection is not still clear, but there are some factors. For example, needle pricks and other dangerous behaviors can be related to direct transmission of disease or a transmissible agent. Also, tattooing is an invasive procedure typically involving a solid vibrating needle that repeatedly punctures into the dermis, wounding both the epidermis and the upper dermis in the process. Currently, considerable researches were performed to investigate an adverse reaction of the tattooing. An animal experiment conducted for the safety test of the tattooing [7] is essential to recognize materials which can use into tattoo without immunochemical reaction. Current statuses of skin irritation test are limited in immunochemical aspects by chemical reaction, but the physical stimulation which

can cause inflammation and drive the secondary reaction on the skin should be considered in the experiment. Also the conventional skin damage is evaluated by naked eye recognition on the skin such as primary irritation index (PII) [8]. However, PII is essential to evaluate the tattooed skin irritation (edema and erythema), but it has the limitation to measure the mechanical damage quantitatively. Therefore, we utilized the optical coherence tomography (OCT) to compare the skin damage. The OCT, a non-invasive imaging method in high-resolution biomedical imaging for skin structural analysis, it is a new and promising diagnostic technique for the investigation of the tattooed skin.

The aim of the present study is to evaluate the feasibility of OCT to investigate the changes of the tattooed porcine skin.

II. METHODS

A. Sample Preparation & Needle stimulation

The porcine skin was used to be sample for tattooing (Fig 1 (a)). The needle stimulation was performed by tattoo machine with minimum speed rpm and maximum speed rpm. The minimum speed was 6000 rpm, and the maximum speed was 11400 rpm. Needle depth and needle stimulation duration were controlled to investigate the mechanical changes of the tattooed porcine skin, as referred to the 1mm needle length within 30 seconds (tattoo needle diameter: 0.4mm). We tattooed on the porcine skin and observed the skin by the microscope (Olympus, Japan). The Fig. 1 (b) is the microscopy image of 80 magnifications. The pigment was inserted in the needle hole after tattooing.

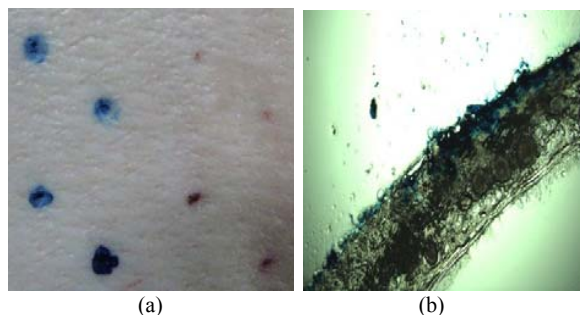


Fig. 1 (a) porcine skin CCD image, (b) porcine skin microscopic image

B. Optical coherence tomography

A rapid non-invasive technique that could be used prior to biopsy for tissue characterization seems to be useful in

Young Geun Kim, Tae Woo Lee, Changmin Yeo, Byungjo Jung and Han Sung Kim are with the Department of Biomedical Engineering, Yonsei University, Wonju, Gangwondo, Korea (corresponding author to provide phone:82-33-760-2913; fax: 82-33-760-2913; e-mail: hanskim@yonsei.ac.kr).

Jung min Yoo, Yeo Jin Kang and Tack-Joong Kim are with Department of Biological Science and Technology, Yonsei University, Wonju, Gangwondo, Korea.

Ji Hun Cha, Chan Hoi Hur, Dong Sup Kim and Ki Jung Park are with the National Institute of Food and Drug Safety Evaluation, Chungcheongbuk-do, Korea.

cosmetic dermatology [9-10]. OCT imaging is based on the light scattering, so the pigment smudges can be a main factor of light absorption (Fig 2). An imaging depth up to 1.5mm (a spatial resolution: 6 μ m) was sufficient to examine the epidermis and papillary dermis. We obtained two-dimensional (2D) data within a region of interest by using Spectral Radar OCT (THORLABS, USA) (Fig 2). Signal accuracy was given priority over spatial resolution. The geometrical field of view along the depth was limited to 1.6 mm, approximately. The lateral field of view was always 2.0 mm.

C. Histological images

The cryostat used in a process called frozen section histology is essentially an ultrafine "deli-slicer", called a microtome, placed in a freezer (Fig 4). Specimen slides are fixed with a thickness of about 10 micrometers. Specimens that are soft at room temperature are mounted on a cutting medium on a metal and frozen to cutting at -20 degrees Celsius. Once frozen, the specimen is mounted on the microtome [11].

Fig. 4 (a) was cryostat machine, and Fig. 4 (b) was histology image. Epidermis and upper dermis was pigmented, hemorrhage was revealed in the local area of the lower dermis.

Fig. 5 (a) was a microscopic image of needle stimulated skin without pigment. We found the epidermis shown in the OCT and histological images were worn out. The worn out area has hemorrhage. Even though the surgical operation was conducted in vitro, the hemorrhage was observed. Fig. 5(b) was a microscopic image of the tattooed skin with blue pigment. The tattooed area is even, but there is difference of pigment density. The detection of difference is not easy to see with naked eye. The pigment prohibits the identification of tattooed area (Fig. 5 (b)).




Fig. 2 Optical tomography system

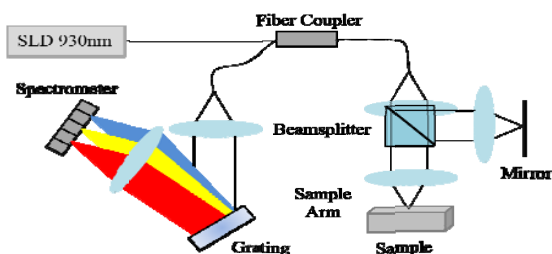


Fig. 3 Optical tomography diagram




Fig. 4 Histologic images on the tattooed porcine skin

III. RESULTS & DISCUSSION

Fig. 6 (a) and (b) are OCT images of the normal and tattooed skin tissue. We can distinguish the normal epidermis from the damaged tissue by top of the bright area. Also, we found the needle stimulation makes irregular pattern in the dermis area and the epidermis has the discontinuous pattern. Dermis of the tattooed skin was dark with vertical line on the Fig. 6 (b). The needle stimulation affects to the dermis with the vertical line pattern. It might be shown by needle stimulation with pigment smudges. The combination effect of hemorrhage and pigment cannot distinguish by OCT.

Fig. 7 (a) and (b) showed the comparison of skin irritation in OCT images are dependent to the needle speed of the tattoo machine. Fig. 7 (a) was obtained from 6000 rpm needle stimulation and Fig. 7 (b) was obtained from 11400rpm. Epidermis in the 6000 rpm was worn out more than 11400 rpm. Dermis was not clear difference between 6000 rpm and 11400 rpm. The skin irritation along the depth axis was also observed by OCT. The reaction was performed simultaneously, but it was not clear changes. Epidermis of the Fig. 7 (b) was continuous and smooth. Considering the surgical operation, needle movement was also continuous and smooth. On the other hand the epidermis of the 6000 rpm needle stimulation was discontinuous and rough. It is inferred that the skin could be ripped by slow needle stimulation. Dermis of the high needle stimulation was brighter than slow needle stimulation. The first reason for this result were needle movement on the epidermis was faster than needle vertical stimulation on the on the epidermis. Because skin has elasticity property, the skin barrier could not break without enough needle stimulation. If the needle movement on the epidermis was same in the figure 4, the skin elasticity was strong locally. It means that the pigment could not spread out enough.

This study has several development possibilities. First, the application of animal skin was founded in the tattoo by measuring noninvasively. The parameter study will be followed with changing operation condition. Second, quantitative data of skin was obtained by OCT in physical depth. The parameter study was limited to tattoo existence, needle speed, but the dominant component of tattooing could be revealed in the future.




Fig. 5 Microscopic images (a) without pigment (b) with pigment skin




Fig. 6 Comparison of (a) the normal tissue and (b) the tattooed tissue




Fig. 7 OCT images by needle speed (a) 6000rpm, (b) 11400rpm

IV. CONCLUSION

The tattooing process divided into the mechanical needle stimulation and chemical pigment reaction in the tissue, the present study importantly dealt with the mechanical problem of the tattooing. The result of OCT was consistent with that of the histology. We supposed the dermis (bottom of the bright area) could be weakening by needle injection. OCT was effective to examine the tattooed skin section noninvasively. It might be available to identify morphological changes inside the skin, but pigment effect needs to be studied further. The aim of this study was to evaluate the mechanical skin damages by OCT. The structure of epidermal thickness was slightly deviated by tissue deformation. However, we could prove similar tissue structures in both methods. This method could be used to measure the skin condition qualitatively after mechanical skin irritation. We

developed that OCT can be applied to measure the mechanical skin damages.

ACKNOWLEDGMENT

This research was support by a grant (1072KFDA416) from Korea Food & Drug Administration in 2010.

REFERENCES

- [1] <http://en.wikipedia.org/wiki/Tattoo>
- [2] A. E. Laumann and A. J. Derick, "Tattoos and body piercings in the United States: a national data set," *Journal of the American Academy of Dermatology*, vol. 55, pp. 413-421, 2006.
- [3] <http://www.newspoll.org>. Accessed May 16, 2006.
- [4] M. L. Armstrong, "Tattooing, Body Piercing, and Permanent Cosmetics: A Historical and Current View of State Regulations, with Continuing Concerns," *Journal of Environmental Health*, vol. 67, p. 38, 2005.
- [5] A. Stirn, A. Hinz, and E. Brähler, "Prevalence of tattooing and body piercing in Germany and perception of health, mental disorders, and sensation seeking among tattooed and body-pierced individuals," *Journal of Psychosomatic Research*, vol. 60, pp. 531-534, 2006.
- [6] J. Worp, A. Boonstra, R. A. Coutinho, and J. A. R. van den Hoek, "Tattooing, permanent makeup and piercing in Amsterdam; guidelines, legislation and monitoring," *Euro surveillance*, vol. 11, pp. 34-36, 2006.
- [7] Papameletiou, D., A. Zenie, D. Schwela and W. Baumler. "Risks and health effects of tattoos, body piercing and related practices," Report of the European Commission (EC), the Joint Research Centre (JRC), the World Health Organization (WHO), 2004.
- [8] ISO 10993-5:2009(E)
- [9] F. G. Bechara, T. Gambichler, M. Stecker, A. Orlikov, S. Rotterdam, P. Altmeyer, and K. Hoffmann, "Histomorphologic correlation with routine histology and optical coherence tomography," *Skin research and technology*, vol. 10, pp. 169-173, 2004.
- [10] H. Morsy, M. Mogensen, L. Thrane, and G. B. Jemec, "Imaging of intradermal tattoos by optical coherence tomography," *Skin research and technology*, vol. 13, pp. 444-448, 2007.
- [11] <http://en.wikipedia.org/wiki/Cryostat>