

Effect of Hormonal Manipulations on the Pattern of the Vaginal Tissue Structure

Fatahian Dehkordi RF., Parchami A.

Abstract—Design of experiments made for correlated the hormonal activity of steroids and their effect on the vaginal structure properties. Vaginal wall consists of distinct layers of cells which strongly differ regarding growth in answer to steroid hormones. The presence study carried out for functional evaluation and sustained replacement effect of the reproductive hormones on the vaginal morphometry in the rabbit. Rabbits were maintained control (Co) or ovariectomized (Ovz) and continuously treated with estradiol (Ovz E) and estradiol mixture with testosterone (Ovz ET). Relative to control rabbits with the distinct tissue distribution pattern, ovariectomized animals displayed declined epithelial thickness and atrophy of the muscularis layer that cause the vaginal wall thinning. Estradiol treatment of Ovz rabbits inverted these changes to status of the preovariectomy. Histometric measurements in Ovz ET group completely including of thickness of the epithelial and muscular layers was greater in comparison to that of control animals.

Keywords—Vagina, Ovariectomy, Rabbit, Morphometry

I. INTRODUCTION

THE vagina is a musculomembranous tube extending from the cervix to the vestibule and includes a wall of three layers, i.e. the mucosa, muscularis and adventitia. Vaginal structure undergoes morphological changes during the estrous cycle and these changes dependent upon the serum levels of the steroid hormones that are critical for maintaining the integrity of female genital tissue structure [10, 12]. It were been revealed that gender steroid hormones and their substantial moderators change the physiological and structural properties of the vaginal wall [1-4]. Surgical procedures and factors that cause absent of menstruation are known to induce structural changes in the vagina [2, 4, 10]. With the beginning of menopause were denoted the number of layers reduce in the vaginal epithelium including a loss of intermediate cells, which results in an overall reduction in epithelial height [13]. In ovariectomized nonhuman Primates were found that significantly vaginal epithelial height and smooth muscle tissue decrease in the laboratory condition (Robinson). Most investigations of periodical changes in the vagina structure have concentrated upon the epithelium [3]. The vaginal mucosa is a target organ for gender steroid hormones. The vaginal epithelium undergoes cyclic and age-dependent morphological and functional changes. Already were defined that rat vaginal epithelium comprise of distinct layers of cells and profoundly response to steroids and differences in the layers growth provide separately patterns in the vaginal mucosa, consist of mucification, keratinization, and stratification [4]. Cellular layer components of the vaginal structure were controlled by gender steroid hormones in the clear physiological pathways. Though these functions has been surveyed on the vaginal wall, but combinatory effects of sex hormones have received limited attention and this study has been undertaken to investigate the effect of androgen compositions and hormonal manipulations on the vaginal tissue structure in rabbit.

II. MATERIALS AND METHODS

Adult female New Zealand White rabbits (3.1-3.5 kg wt) were used in this investigation. Animals had free approach for rabbit food pellets and normal tap water ad libitum. They were randomly divided into four groups of 5 animals each. One group was kept intact (Co) and the other groups had undergone bilateral ovariectomized (Ovz) under condition anesthesia. At 4 weeks postovariectomy, one group was administered intramuscular injections of estradiol valerate (5 mg) (Ovz E) and estradiol in combination with testosterone propionate (0.5 ml) (Ovz ET) for eight weeks. Also the control group rabbits underwent injection of 1mL distilled water per kg body weight, and then at the finish of the investigation, all of them were sacrificed under ketamin anesthesia. Vaginal tissues were removed from its anterior and posterior regions and ranged from 10 to 12mm in length. Specimens immediately immersed in 10% neutral buffered formalin and maintained at 4 C, 24–72 h for histological study. Tissue sections were carefully processed in paraffin and cut at 5-6 μ m by a rotary microtome and stained with a sequence of iron haematoxylin and eosin.

Statistical analyses of result were carried out by SPSS software package v.13.0 and data were expressed as mean \pm SEM. Statistical variation into groups were conducted by one way analysis ANOVA with LSD test followed by post-hoc to comparison the means. An expectancy value less than 0.05 were measured statistically significant.

III. RESULTS

Histological results of the vaginal tissue in intact group (Co) showed the epithelium was distinctly included by layer of uniform; lengthened columnar cells that were retained over the vaginal nourishing stroma containing mucosa and submucosal connective tissue (lamina propria). Epithelial cells densely packed with a little eosinophilic cytoplasm surrounded by submucosal connective tissue including a distinct muscle layer. Muscular tunic of the vagina comprises smooth muscle bundles which widely distributed overall the tissue stroma compartments. Considerations showed that only a part of the inner circular muscle layer was dispersedly apparent in vaginal tissue at the intact, cycling rabbits (Figure 1).

In the animals of Ovz group, vaginal wall revealed a throughout thinning and its luminal epithelium was significantly atrophy relative to that of Co group animals. The tunica mucosa consists of non-keratinizing epithelium layer were keep by a thin, loose connective tissue layer. Epithelial cells were considerably smaller than those observed in control group with least possible cytoplasmic content. Muscle fibers packed were more noticeable scattered and decreased in comparison to intact rabbits. Vaginal smooth muscle contents were most decreased in samples from ovariectomized animals (Figure 2).

Micrometric results showed that androgen treatment of Ovz group almost reversed the morphometric changes observed in Ovz group. Experiment of the vaginal tissue sections displays irregular changes in Ovz E group for morphology of the vaginal tissue structure in comparison with Ovz ET group. Changes at the layer of the muscular were more obvious in Ovz ET group and consisted of compact muscle bundles than those observed in Ovz E group. A significantly increased in the epithelium was distinguished in vaginal tissue in Ovz ET group that of Ovz E animals. Increased of the epithelial thicknesses after hormonal infused were attributable in Ovz ET group due to increased extension of the tunica epithelium cells in comparison to Ovz E rabbits. The microscopic results showed that there were not significantly differences between Ovz group and two hormonal-infused groups regarding morphometric values.

IV. DISCUSSION

The presence study data revealed not only vaginal structure affected by ovariectomy, which resulted in decrease thickness of vaginal tissue wall, but also hormonal administration included of estradiol and estradiol in combination with testosterone infused caused reverse changes in its mural components. Kim et. al. (2004) determined ovariectomized animals infused with supraphysiological levels of testosterone demonstrated significant atrophy of the muscularis layer and epithelial height decrease and this variations result in thinning of the vaginal wall. They showed that estradiol infusion increased epithelial height, but only partially restored the muscularis layer and in contrast, testosterone infusion completely restored the muscularis layer, but only partially restored the epithelial height. While in this study were showed that changes including the epithelial increase and muscular layers were observed in whole wall in the both Ovz E, Ovz ET groups; although thickness of the tissue layers in Ovz ET group were significantly greater in comparison to the Ovz E groups. The changes which were observed in the vaginal tissue structure after ovariectomy and androgen administration could be invert effect of sex steroids on the vaginal tissue layers.

Because of abundance estrogenic receptors in the vaginal tissues, estrogen can induce vaginal epithelial alterations and vascular changing [1, 2, 6, 9]. The vaginal mucosa plays a role in phagocytic activities that were performed via macrophages. Estrogens stimulate some appearances of macrophage activity and could be a positive agent in cell resistance to infections [2]. It was concluded that reduction in estrogen hormonal level due to menopause or surgical procedure, probably causes an apparent decrease in cell resistance. These exchanges including histomorphometrical parameters involved in the experiment are completely reversible following administration of estrogen or testosterone and or both mixtures. On the other hand, like the presence study, the combined effects of estrogen and testosterone are remarkably greater than that seen in using estrogen or testosterone individually.

Despite estrogens famous effects on the vaginal mucosal development and extension of the tissue instauration, but their

effects on the tunica muscularis of the vagina has been stayed unknown. Estrogenic derivatives have an atheroprotective effect involving inhibition of vascular smooth-muscle cells proliferation [8]. From the other point of view, Mariotti and Mawhinney (1983) revealed estrogen have regulation obligation expanding proliferation of the smooth muscle cells in the accessory sexual organ. Therefore estrogens could be control additive or decreasing action of the smooth muscle cells and possess specific property for each tissue separately. In this study, were determined that estradiol hormone and chiefly mixture of both estradiol and testosterone hormones promote vaginal smooth muscle proliferation. It appears as though effect of estradiol on the vagina structural properties adapt with that of testosterone administration and when used both hormones together exerted individual physiological effects on the vagina.

ACKNOWLEDGMENT

This work was financially supported by the University of Shahrekord, Iran.

REFERENCES

- [1] D. L. Buchanan, T. Kurita, J. A. Taylor, D. B. Lubahn, G. R. Cunha, and P.S. Cooke, "Role of stromal and epithelial estrogen receptors in vaginal epithelial proliferation, stratification, and cornification," *Endocrinology*, vol. 139, pp. 4345–4352, 1998.
- [2] J. G. Forsberg, "A morphologist's approach to the vagina—age-related changes and estrogen sensitivity," *Maturitas*, vol. 22, pp. S7–S15, 1995.
- [3] J. G. Forsberg, "Short-term and long-term effects of estrogen on lymphoid tissues and lymphoid cells with some remarks on the significance for carcinogenesis," *Arch. Toxicol.*, vol. 55, pp. 79–90, 1984.
- [4] M. Hilliges, C. Falconer, G. Ekman-Ordeberg, and O. Johansson, "Innervation of the human vaginal mucosa as revealed by PGP 9.5 immunohistochemistry," *Acta. Anat. (Basel)*, vol. 153, pp. 119–126, 1995.
- [5] C. Huggins, E. V. Jensen, and A. S. Cleveland, "Chemical structure of steroids in relation to promotion of growth of the vagina and uterus of the hypophysectomized rat," *J. Exp. Med.*, vol. 100, pp. 225–240, 1954.
- [6] N. N. Kim, K. Min, M. A. Pessina, R. Munarriz, I. Goldstein, and A. M. Traish, "Effects of ovariectomy and steroid hormones on vaginal smooth muscle contractility," *Int. J. Impot. Res.*, vol. 16, pp. 43–50, 2004.
- [7] A. B. MacLean, L. A. Nicol, and M. B. Hodgins, "Immunohistochemical localization of estrogen receptors in the vulva and vagina," *J. Reprod. Med.*, vol. 35, pp. 1015–1016, 1990.
- [8] A. Mariotti, and M. Mawhinney, "Androgenic regulation of estrogenic action on accessory sex organ smooth muscle," *J. Urol.*, vol. 129, pp. 180–185, 1983.
- [9] M. E. Mendelsohn, and R. H. Karas, "Estrogen and the blood vessel wall," *Curr. Opin. Cardiol.*, vol. 9, pp. 619–626, 1994.
- [10] C. N. Mowa, and T. Iwanaga, "Differential distribution of oestrogen receptor alpha and -beta mRNAs in the female reproductive organ of rats as revealed by in situ hybridization," *J. Endocrinol.*, vol. 165, pp. 59–66, 2000.
- [11] K. Park, K. Ahn, S. Lee, S. Ryu, Y. Park, and K. M. Azadzi, "Decreased circulating levels of estrogen alter vaginal and clitoral blood flow and structure in the rabbit," *Int. J. Impot. Res.*, vol. 13, pp. 116–124, 2001.
- [12] D. Robinson, R. O. Rainer, S. A. Washburn, and T. B. Clarkson, "Effects of estrogen and progestin replacement on the urogenital tract of the ovariectomized cynomolgus monkey," *Neuroendocrinology*, vol. 15, pp. 215–221, 1996.
- [13] P. M. Sarrel, "Psychosexual effects of menopause: role of androgens," *Am. J. Obstet. Gynecol.*, vol. 180, pp. S319–S324, 1999.
- [14] R. Zaino, "Diseases of the vagina. In: R. J. Kurman, ed. *Blaustein's pathology of the female genital tract*. New York: Springer-Verlag, 2002, pp. 132–136.

TABLE I
THE MEAN HISTOMETRIC PARAMETERS OF VAGINAL TISSUE LAYERS

Group \ Parameter	Epithelium	Muscular
Co	46.47±0.45	401±0.74
Ovz	26.68±0.42	188±0.12
Ovz E	39.33±0.32	320±0.65
Ovz ET	50.12±1.03	522±1.12

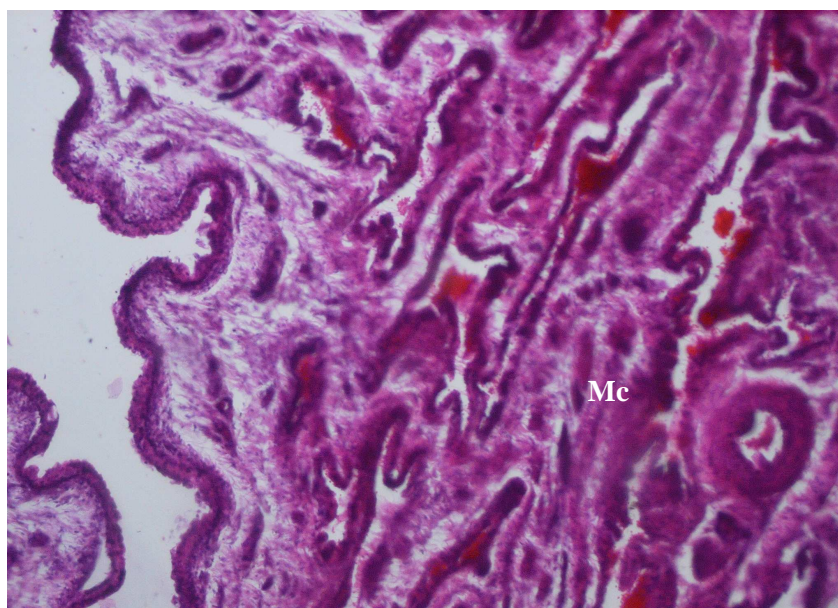

Fig. 1 Light microscopic structure of the vaginal structure in intact rabbits. Note to the extension of the muscular cells (Mc)

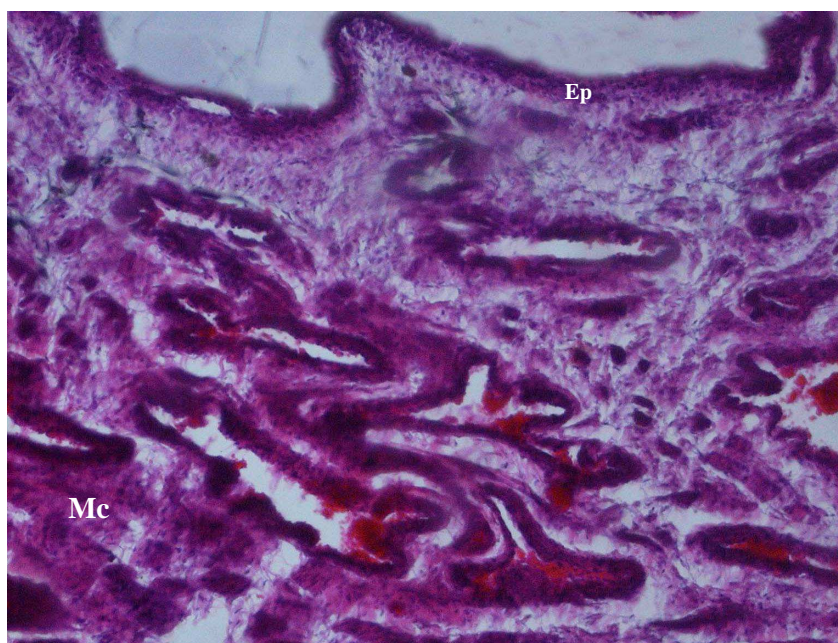


Fig. 2 Light microscopic structure of the vaginal structure in gonadectomized rabbits. Note to the decrease the epithelial (Ep) and muscular cells (Mc)