

Contrast-Enhanced Magnetic Resonance Angiography in Rats with Gadobenate Dimeglumine at 3T

Jo-Chi Jao, Yen-Ku Chen, Twei-Shiun Jaw, Po-Chou Chen

Abstract—This study aimed to investigate the magnetic resonance (MR) signal enhancement ratio (ER) of contrast-enhanced MR angiography (CE-MRA) in normal rats with gadobenate dimeglumine (Gd-BOPTA) using a clinical 3T scanner and an extremity coil. The relaxivities of Gd-BOPTA with saline only and with 4.5% human serum albumin (HSA) were also measured. Compared with Gadolinium diethylenetriaminepentaacetic acid (Gd-DTPA), Gd-BOPTA had higher relaxivities. The maximum ER of aorta (ER_a), kidney, liver and muscle with Gd-BOPTA were higher than those with Gd-DTPA. The maximum ER_a appeared at 1.2 min and decayed to half at 10 min after Gd-BOPTA injection. This information is helpful for the design of CE-MRA study of rats.

Keywords—Contrast-Enhanced Magnetic Resonance Angiography, Gd-BOPTA, Gd-DTPA, Rat.

I. INTRODUCTION

CARDIOVASCULAR diseases, one of the major cause of death and disability in the world, has to be diagnosed early and accurately for better prognosis of treatment. Magnetic resonance imaging (MRI) can demonstrate a high contrast between soft tissues and has no radiation. Therefore, MRI plays an important role in lesion detection. Contrast agents can improve the signal-to-noise ratio (SNR) and contrast-to-noise ratio (CNR) of MR images. Nowadays, contrast-enhanced magnetic resonance angiography (CE-MRA) is commonly used for the detection of vascular lesions [1]-[5].

The first MRI contrast agent approved by the United States Food and Drug Administration (FDA) is Gadolinium diethylenetriaminepentaacetic acid (Gd-DTPA) in 1988. Gd-DTPA can reduce both of the spin-lattice relaxation time (T_1) of protons and increase the signal intensity of T_1 -weighted images. Gd-DTPA is a kind of extracellular contrast agents. After intravenous injection, Gd-DTPA first stays inside blood vessels for a while, then spreads into interstitial spaces and finally is excreted by the kidney system. When the vessels contain Gd-DTPA inside, the signal intensity of blood vessels increased. The enhancement disappears after Gd-DTPA is excreted [6].

Jo-Chi Jao is with the Department of Medical Imaging and Radiological Sciences, Kaohsiung, Taiwan, ROC (e-mail: jochja@kmu.edu.tw).

Yen-Ku Chen was with Department of Medical Imaging and Radiological Sciences, Kaohsiung, Taiwan. He is now with GE Healthcare, Taipei, Taiwan, ROC (e-mail: u9251067@alummi.kmu.edu.tw).

Twei-Shiun Jaw is with the School of Medicine, Department of Medical Imaging, Kaohsiung Medical University Hospital, Kaohsiung, Taiwan, ROC (e-mail: tsjaw@cc.kmu.edu.tw)

Po-Chou Chen is with the Department of Biomedical Engineering, I-SHOU University, Kaohsiung, Taiwan, ROC (corresponding author, phone: 886-7-6151100 ext 7470; fax: 886-7-6155150; e-mail: pcchen@isu.edu.tw).

Gadobenate dimeglumine (Gd-BOPTA) and gadoxetate disodium (Gd-EOB-DTPA) are both commercially available MRI contrast agents. Gd-BOPTA and Gd-EOB-DTPA can be taken up by hepatocytes and are used in liver MRI for the detection of hepatic mass. In addition to the kidney system, Gd-BOPTA and Gd-EOB-DTPA are partially excreted by the hepatobiliary system [7]. Yoshikawa et al. demonstrated higher image quality of MRA in rats with Gd-EOB-DTPA than with Gd-DTPA using a 1.5 T MRI scanner [8].

High-field MRI is expected to show higher signal intensity of MR images than lower MRI. The aim of this study was to evaluate the enhancement of MRA both in rats with Gd-BOPTA compared with Gd-DTPA at 3T. The relaxivity values of Gd-BOPTA solution with saline or 4.5% human serum albumin (HSA) was also measured.

II. MATERIALS AND METHODS

A. Phantom MRI

This study was performed on a 3T clinical whole-body scanner (General Electric Company, Milwaukee, WI). Fifteen test tubes containing various concentrations (0-10 mM) of Gd-BOPTA (Multihance, Bracco Imaging, Milan, Italy) in saline were prepared and put into a quadrature head coil. One coronal image was acquired using a conventional spin echo (CSE) pulse sequence to evaluate longitudinal relaxation time (T_1) and transversal relaxation time (T_2). For T_1 measurement, the echo time (TE) was 14 ms fixed and the repetition time (TR) varied from 30 ms to 12000 ms. For T_2 measurement, the TR was 2000 ms fixed and the TE varied from 20 to 120 ms. Other MRI parameters for T_1 and T_2 measurements are the same: the field of view (FOV) was 20×20 cm, the matrix size was 256×128, and slice thickness was 5 mm. All the acquired images were transferred to an Advantage Windows Workstation (General Electric Company, Milwaukee, WI) and the MR signal intensity of each tube were measured. The T_1 and T_2 values of contrast agents with varied concentrations were determined by least square curve fitting the MR signal intensity (S) according to (1) and (2) respectively [9].

$$S = M[1 - 2\exp(-TR/T_1) + \exp(-TR/T_1)] \quad (1)$$

$$S = M \exp(-TE/T_2) \quad (2)$$

where M is the magnetization including electric gains.

The longitudinal and transversal relaxivity r_1 and r_2 were obtained by linear regression according to (3) and (4), respectively.

$$1/T_1 = 1/T_{10} + r_1 \cdot C \quad (3)$$

$$1/T_2 = 1/T_{20} + r_2 \cdot C \quad (4)$$

where C is the concentration of the contrast agent.

The r_1 and r_2 values of Gd-BOPTA with 4.5% HSA were obtained as the same procedure mentioned above. The r_1 and r_2 values of Gd-DTPA (Magnevist, Schering, Berlin, Germany) with saline or 4.5% HSA were obtained from the published data.

B. Animal CE-MRA

The protocol of animal use was approved by the Institutional Animal Care and Use Committee (IACUC).

Six normal male Sprague Dawley rats were divided into two groups: one for Gd-BOPTA-enhanced MRA ($n = 3$) and the other for Gd-DTPA-enhanced-MRA ($n = 3$). Each rat was anesthetized with 50 mg/kg ketamine, 10 mg/kg xylazine and 1 mg/kg atropine and underwent CE-MRA. For each scan only one rat was put inside the knee coil in a prone position. The enhanced fast gradient echo 3-dimensional (efgre3D) pulse sequence was used for the CE-MRA with flip angle (FA) = 30° , TE = 1.7 ms, TR = 5.9 ms, number of excitation (NEX) = 1, FOV = 12×10.8 cm, matrix size = 320×160 , and slice thickness = 1 mm. Each MRA took 24s. After one pre-contrast scanning, 0.1 mmol/kg Gd-BOPTA or Gd-DTPA was bolus injected through the rat's tail vein and MRA was performed sequentially for 30 min. All acquired images were transferred to the GE Advantage Windows Workstation. Regions of interest (ROIs) in the aorta, liver, kidney, muscle and background were selected. The SNR of each organ as a function of time were calculated as follows:

$$SNR_i(t) = S_i(t)/\sigma \quad (5)$$

where $S_i(t)$ is the signal intensity obtained at time t after the injection of contrast agents, and σ is the standard deviation of the background.

The signal enhancement ratio (ER) of the aorta, liver, kidney and muscle as a function of time were calculated as;

$$ER_i(t) = SNR_i(t)/SNR_0 \quad (6)$$

where $SNR(t)$ and SNR_0 is the SNR obtained at time t after and before the injection of contrast agents, respectively. The suffix i represents each organ: aorta, kidney, liver or muscle.

Nonparametric statistics and the Mann-Whitney tests were used to compare the ER and ERR of the Gd-BOPTA-enhanced MRA and Gd-DTPA-enhanced MRA, which were conducted using SPSS software (version 14.0, SPSS Inc. Chicago, IL, USA). There was a significant difference if $p < 0.05$.

III. RESULTS

A. Phantom MRI

Table I lists the r_1 and r_2 values of Gd-BOPTA and Gd-DTPA with saline or 4.5% HSA. There was good linearity between the relaxation rates ($1/T_1$ and $1/T_2$) and the concentration of each contrast agent. Both Gd-BOPTA and

Gd-DTPA with 4.5% HAS had higher relaxivities than those with plain saline. Furthermore, Gd-BOPTA had higher relaxivities than Gd-DTPA.

B. Animal CE-MRA

Figs. 1 and 2 show the representative maximum intensity projection (MIP) images of two normal rats before and after Gd-BOPTA or Gd-DTPA injection. Figs. 3-6 show the ER in aorta (ER_a), kidney (ER_k), liver (ER_l) and muscle (ER_m) before and after Gd-BOPTA or Gd-DTPA injection. After Gd-BOPTA injection, ER_a was 2.68 ± 0.83 at 0.4 min and up to maximum value 4.56 ± 1.09 at 1.2 min. Afterwards, ER_a decreased to 2.27 ± 0.52 at 10 min and to 1.40 ± 0.34 at 30 min. On the other hand, after Gd-DTPA injection, ER_a was 2.05 ± 0.26 at 0.4 min, which was lower than Gd-BOPTA group, but the difference was not significant ($p > 0.05$). The maximum value ER_a 2.47 ± 0.26 also happened at 1.2 min, and then decreased faster than Gd-BOPTA group to 1.64 ± 0.17 at 10 min and to 1.30 ± 0.17 at 30 min. There was significant difference from 1.2 to 15 min ($p < 0.05$). After 20 min, the difference was not significant ($p > 0.05$). For kidney, after Gd-BOPTA injection, clear enhancement started at 1.2 min with ER_k value 1.50 ± 0.46 , increased to maximum value 7.63 ± 1.57 at 2.4 min, and then decreased to 2.23 ± 0.59 at 30 min. For Gd-DTPA group, obvious enhancement also started at 1.2 min with ER_k value 4.74 ± 0.26 , which was lower than that of Gd-BOPTA group. The maximum ER_k value 5.73 ± 0.23 at 2.4 min and declined to 3.29 ± 0.14 , which became higher than that of Gd-BOPTA group. From 1.2 to 4.0 min and at 30 min, the ER_k values were significantly different between these two groups. For liver, right after Gd-BOPTA injection, the enhancement was not clear. But ER_l value was 4.13 ± 0.48 at 1.2 min, then decayed slowly to 3.73 ± 0.44 at 10 min and 2.00 ± 0.22 at 30 min. From 1.2 to 10 min, ER_l values were similar. For Gd-DTPA group, ER_l was 1.18 ± 0.26 at 0.4 min, which was similar to that of Gd-BOPTA group, but the maximum ER_l value 2.09 ± 0.38 happened at 1.2 min, which was much less than that of Gd-BOPTA group. Afterwards, the ER_l declined, which was only 1.21 ± 0.27 at 30 min. The ER_l values were significantly different between Gd-BOPTA and Gd-DTPA groups for 1.2 min to 30 min ($p < 0.05$). The ER_m was smaller than ER_a , ER_k and ER_l for both groups. Gd-BOPTA group had higher ER_m than that of Gd-DTPA group. The maximum ER_m were 1.79 ± 0.37 and 1.20 ± 0.20 for Gd-BOPTA and Gd-DTPA group respectively. There was significant difference between these two groups from 0.4 min to 30 min.

IV. DISCUSSION

In the phantom study, we have shown that the r_1 and r_2 relaxivities of Gd-BOPTA with 4.5% HSA were higher than those with saline only. The r_1 and r_2 relaxivities of Gd-BOPTA with 4.5% HAS were also higher than those of Gd-DTPA with 4.5% HSA or saline only. These results demonstrate that Gd-BOPTA has stronger binding with HSA than Gd-DTPA. In the animal study, the maximum of ER_a , ER_k , ER_l and ER_m with Gd-BOPTA were higher than those with Gd-DTPA.

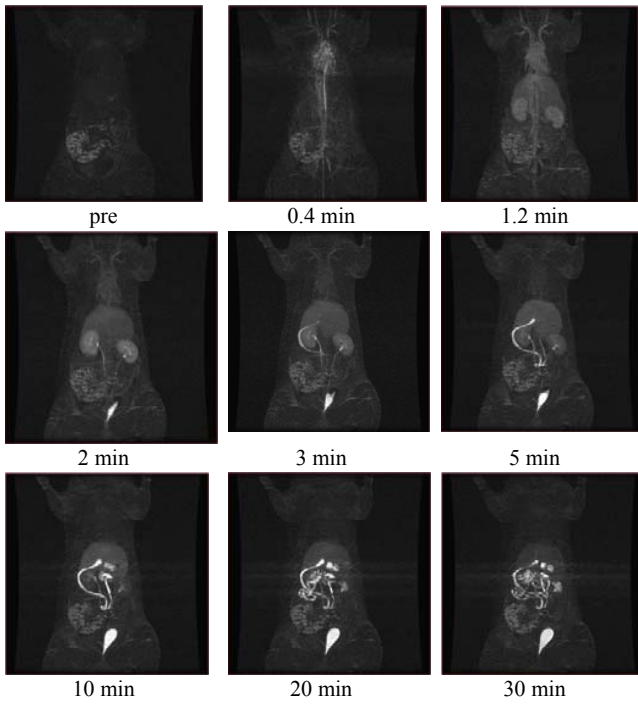


Fig. 1 Representative coronal MIP images of a normal rat before and after Gd-BOPTA

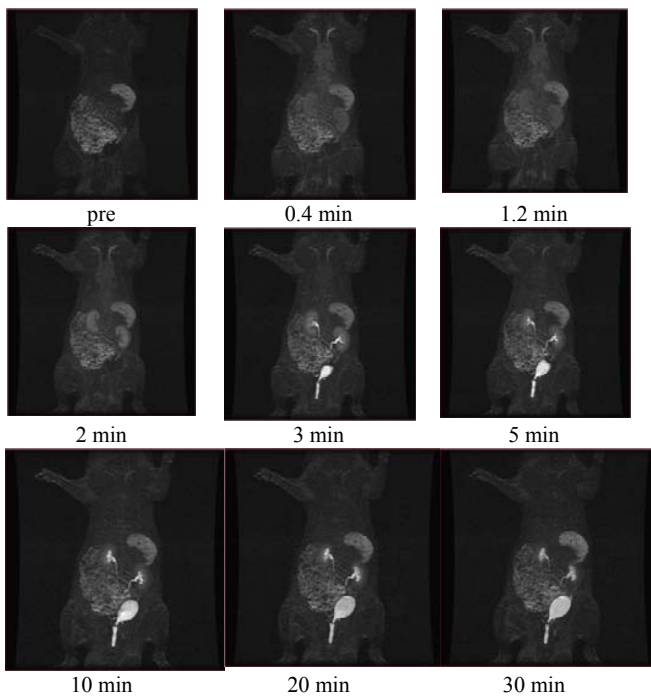


Fig. 2 Representative coronal MIP images of a normal rat before and after Gd-DTPA

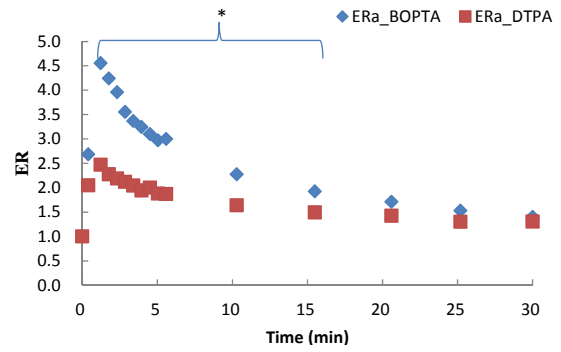


Fig. 3 ER of aorta before and after contrast agents injection

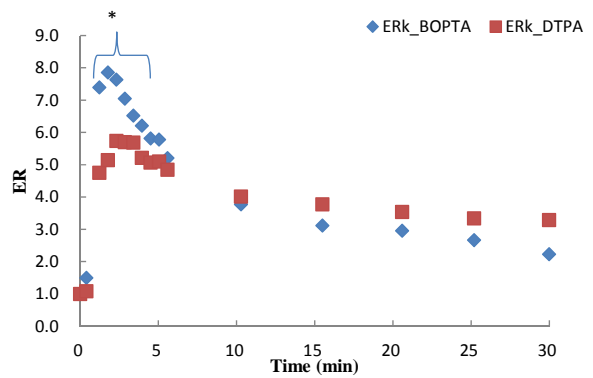


Fig. 4 ER of kidney before and after contrast agent's injection

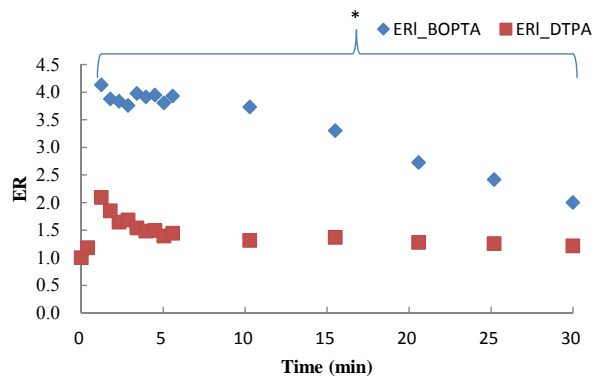


Fig. 5 ER of liver before and after contrast agents injection

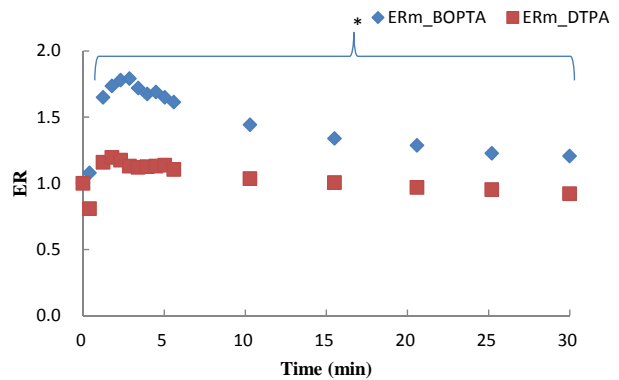


Fig. 6 ER of muscle before and after contrast agents injection

Hepatic cells can uptake Gd-BOPTA. Therefore, Gd-BOPTA is used as a hepatobiliary contrast agent. Gd-BOPTA can also be used for CE-MRA due to the high binding with HSA. After 0.1 mmole/kg Gd-BOPTA injection, the maximum ER_a appeared at 1.2 min and dropped to half at 10 min. This information suggests that the best time window to complete image acquisition is with 10 min after Gd-BOPTA injection.

The ER_a varies with species, injected Gd-BOPTA dosage, imaging acquisition time after injection, magnetic field of MR scanners, coil types, MRI pulse sequences and parameters [11]-[13]. In this study, the efgre3D pulse sequence with a commercialized extremity coil at 3T was used for rat CE-MRA. Different situations of CE-MRA may have various results and need further studies.

Rats are often used for studies of diseases causes and development of new diagnostic or therapeutic drugs. CE-MRA is helpful for monitor the vessel status longitudinally. MR scanners specific for animal studies has been developed using very high magnetic fields and can get very good quality of images. However, animal specific MR scanners are still rare for researchers. Using clinical MR scanners with optimized coils, pulse sequences, scanning parameters and contrast agents can still obtain images with high quality and be a good choice for animal studies.

TABLE I
REAXIVITIES OF Gd-BOPTA AND Gd-DTPA

Solutions	4.5% HSA		Saline	
	$r_1(\text{mM}^{-1}\text{s}^{-1})$	$r_2(\text{mM}^{-1}\text{s}^{-1})$	$r_1(\text{mM}^{-1}\text{s}^{-1})$	$r_2(\text{mM}^{-1}\text{s}^{-1})$
Gd-BOPTA	6.09±0.17 (0.9901) ^b	11.47±0.14 (0.9981) ^b	5.76±0.06 (0.9986) ^b	7.23±0.07 (0.9991) ^b
Gd-DTPA	5.12±0.08 ^a (0.9966) ^b	7.01±0.16 ^a (0.9931) ^b	4.75±0.05 ^a (0.9988) ^b	5.77±0.05 ^a (0.9992) ^b

a. From [10].

b. The value in the parentheses is square of correlation coefficient (R^2).

V. CONCLUSIONS

Gd-BOPTA can be performed as a contrast agent in CE-MRA of rats using a clinical 3T scanner and an extremity coil. The maximum ER_a appeared at 1.2 min and dropped to half at 10 min after 0.1 mmol/kg Gd-BOPTA injection. It is suggested that the best time window for image acquisition is with 10 min after Gd-BOPTA injection.

ACKNOWLEDGMENT

Ms. Yen-Yu Chiou and Fou-O Sheu are appreciated for the helpful assistance in MRI technology. This study was supported by Science Council of Taiwan, R.O.C. with the grant No. NSC99-2221-E-214-008.

REFERENCES

- [1] A. Levent, I. Yuce, S. Eren, O. Ozyigit, and M. Kantarci, "Contrast-Enhanced and Time-of-Flight MR Angiographic Assessment of Endovascular Coiled Intracranial Aneurysms at 1.5 T," *Interv Neuroradiol.*, vol. 20, pp. 686-92, Dec 2014.
- [2] S. Roujol, M. Foppa, T.A. Basha, M. Akçakaya, K.V. Kissinger, B. Goddu, S. Berg, and R. Nezafat, "Accelerated free breathing ECG triggered contrast enhanced pulmonary vein magnetic resonance

angiography using compressed sensing," *J Cardiovasc Magn Reson.*, vol. 16, pp. 91, Nov 2014.

- [3] S. Mavrogeni, G. Markousis-Mavrogenis, and G. Kolovou, "Contribution of cardiovascular magnetic resonance in the evaluation of coronary arteries," *World J Cardiol.*, vol. 6, pp. 1060-6, Oct 2014.
- [4] X. Mu, H. Wang, Q. Ma, C. Wu, and L. Ma, "Contrast-enhanced magnetic resonance angiography for the preoperative evaluation of hepatic vascular anatomy in living liver donors: a meta-analysis," *Acad Radiol.*, vol. 21, pp. 743-9, Jun 2014.
- [5] A. M. Saindane, S. R. Boddu, F. C. Tong, S. Dehkharghani, and J. E. Dion, "Contrast-enhanced time-resolved MRA for pre-angiographic evaluation of suspected spinal dural arterial venous fistulas," *J Neurointerv Surg.*, vol. 7, pp. 135-40, Feb. 2015.
- [6] H. P. Niendorf, J. C. Dinger, J. Hausteil, I. Cornelius, A. Alhassan, W. Clauss, "Tolerance data of Gd-DTPA: a review," *Eur J Radiol.*, Vol. 13, pp. 15-21, Jul-Aug 1991.
- [7] M. A. Kirchin, G. P. Pirovano, A. Spinazzi, "Gadobenedimeglumine (Gd-BOPTA). An overview," *Invest Radiol.*, Vol. 33, pp. 798-809, Nov. 1998.
- [8] K. Yoshikawa, Y. Inoue, M. Shimada, M. Akahane, S. Itoh, A. Seno, S. Hayashi, "Contrast-enhanced MRangiography in rats with hepatobiliary contrast agents," *Magn Reson Imaging.*, Vol. 22, pp. 937-42, Sep. 2004.
- [9] E. M. Haacke, R. W. Brwon, M. R. Thompson, R. Venkatesan, *Magnetic Resonance Imaging: Physical Principles and Sequence Design*, New York, NY: John Wiley and Sons Inc, 1999, pp. 128.
- [10] J. C. Jao, H.C. Lu, H. Y. Lu, Y. M. Wang, G.C. Liu, L. M. Lin, P. Y. Chu, S..H. Chen, P. C. Chen, "The Imaging Behavior of an MRI Contrast Agent (Gd(TTDA-BOM)₂- in a Mice Liver Model at 3 Tesla," *J Med Biol Eng.*, Vol. 30, pp. 139-144, Jun 2010.
- [11] X. Xing, X. Zeng, X. Li, Q. Zhao, M.A. Kirchin, G. Pirovano, X. Wang, Y. Li, R. Iezzi, and F. De Cobelli, "Contrast-enhanced MR angiography: does a higher relaxivity MR contrast agent permit a reduction of the dose administered for routine vascular imaging applications?," *Radiol Med.*, vol. 120, pp. 239-50, Feb 2015.
- [12] K.L. Nguyen, S.N. Khan, J.M. Moriarty, K. Mohajer, P. Renella, G. Satou, I. Ayad, S. Patel, M.I. Boechat, and J.P. Finn, "High-field MR imaging in pediatric congenital heart disease: initial results," *PediatrRadiol.*, vol. 45(1), pp. 42-54, Jan 2015.
- [13] S. Gaddikeri, L. Mitsumori, S. Vaidya, D.S. Hippe, P. Bhargava, and M.K. Dighe, "Comparing the diagnostic accuracy of contrast-enhanced computed tomographic angiography and gadolinium-enhanced magnetic resonance angiography for the assessment of hemodynamically significant transplant renal artery stenosis," *CurrProblDiagnRadiol.*, vol. 43, pp. 162-8, Jul. 2014.