

Clinical Factors of Quality Switched Ruby Laser Therapy for Lentigo Depigmentation

SunWoo Lee, TaeBum Lee, YoonHwa Park, YooJeong Kim

Abstract—Solar lentigines appear predominantly on chronically sun-exposed areas of skin, such as the face and the back of the hands. Among the several ways to lentigines treatment, quality-switched lasers are well-known effective treatment for removing solar lentigines. The present pilot study was therefore designed to assess the efficacy of quality-switched ruby laser treatment of such lentigines compare between pretreatment and posttreatment of skin brightness. Twenty-two adults with chronic sun-damaged skin (mean age 52.8 years, range 37–74 years) were treated at the Korean site. A 694 nm Q-switched ruby laser was used, with the energy density set from 1.4 to 12.5 J/cm², to treat solar lentigines. Average brightness of skin color before ruby laser treatment was 137.3 and its skin color was brightened after ruby laser treatment by 150.5. Also, standard deviation of skin color was decreased from 17.8 to 16.4. Regarding the multivariate model, age and energy were identified as significant factors for skin color brightness change in lentigo depigmentation by ruby laser treatment. Their respective odds ratios were 1.082 (95% CI, 1.007–1.163), and 1.431 (95% CI, 1.051–1.946). Lentigo depigmentation treatment using ruby lasers resulted in a high performance in skin color brightness. Among the relative factors involve with ruby laser treatment, age and energy were the most effective factors which skin color change to brighter than pretreatment.

Keywords—Depigmentation, lentigo, quality switched ruby laser, skin color.

I. INTRODUCTION

SOLAR lentigines are known as skin symptom by sunlight exposing and aging of skin which mainly trouble with face. Clinically, they present as irregularly shaped, faint-to-dark brown macules. In dermoscopic analyses, a faint-to-dark brown reticular pattern, often with so-called “fingerprinting”, or a homogeneous pattern of pigmentation and sharply demarcated “moth-eaten” borders, is typically seen. Clinical and dermoscopic diagnoses can be difficult. Solar lentigines, especially if regressing, may share clinical and dermoscopic features with pigmented actinic keratosis and lentigo maligna. These solar lentigines present a significant cosmetic worrying for many middle-aged and elderly patients. Generally, solar lentigines are a common sign of aging in Asians, who often asked for treatment [1], [2].

Intense Pulsed Light devices employ flash lamps that emit non-coherent light, which distinguishes them from laser devices. It has been over 15 years since the first intense pulsed light devices were introduced into the aesthetic medicine

market, and since then, a number of companies have been introducing newer devices offering improved performance and features.

There are several kinds of laser treatment methods to solar lentigo, and specific type of quality-switched laser system could be an effective method to lentigo depigmentation. [3]. But Q-switched laser treatment for pigment disorders commonly leads to post-inflammatory hyperpigmentation in Asians. And this laser-induced post-inflammatory hyperpigmentation could be a limiting factor for selecting patients appropriate for the use of ruby laser in the treatment of lentigines, especially in dark-skinned individuals [4], [5].

According to another research, Q-switched lasers are effective in the treatment of freckles and lentigines in skin, with minimal adverse effects [6]. Basically, the light is absorbed by the chromophores within the skin, principally the melanin in the pigmented lesions, and hemoglobin with its derivatives (oxy and deoxyhemoglobin) within the blood vessels. The chromophores absorb different light wavelengths, and the absorbed light is transformed into thermal energy, causing damage to the chromophores and the lesions where they are located.

Especially, quality-switched ruby laser is to be preferred conventional forms of therapy, such as cryotherapy, chemical peeling and abrasion. And the quality-switched ruby laser has been widely used for the treatment of pigmented lesions, but clinical evaluations in most studies have been conducted on skin color observation comparing the laser-treated skin with its non-treated surrounding area [7], [8].

The purpose of this study was to investigate about clinical factors which involve with solar lentigo treatment by Q-switched ruby laser system.

II. PROCEDURE

A. Subjects

For this research, twenty two subjects with solar lentigines were recruited and treated by Q-switched ruby laser system (mean age 52.8 years, range 37-74 years). Of these patients, lesion was located on the cheeks. From one to ten shot and 2 and 4 weeks after laser treatment, the lesions were again assessed clinically, and by image analyzing software. Institutional rules governing clinical investigation of humans were strictly adhered to and the study conformed to the Declaration of Helsinki. All patients gave informed consent prior to the start of the study.

B. Clinical Imaging

Baseline clinical images were captured using a digital

T.B. Lee Author is with the Bison Medical co., Ltd., Seoul, Korea (phone: 82-2-865-7121; fax: 82-2-865-7131; e-mail: tblee@bisonmedical.com).

S.W. Lee, Y.H. Park, and Y.J. Kim are with the Bison Medical co., Ltd., Seoul, Korea (e-mail: sunwoo@bisonmedical.com, researcher@bisonmedical.com researcher2@bisonmedical.com).

camera and skin brightness was measured by Image J (NIH Image, Maryland, USA.)

In 8 bit images, there are 256 intensity graduations which can be assigned to a pixel. A pixel with an intensity of 0 is black, a pixel with a value of 255 is white.

C. Ruby Laser Treatment

A 694 nm Q-switched ruby laser (RubyStar; Bison Medical, Seoul, Korea) was used, with the energy density set from 1.4 to 12.5 J/cm², to treat solar lentigines. The spot diameter was set from 2 to 4 mm, and the frequency was set from 2 to 4 Hz. The entire area of each lesion was treated from 1 to 8 times by the patients' condition.

D. Statistical Analysis

One sample Kolmogorov-Smirnov was used to compare both data between pretreatment and posttreatment in skin brightness as mean, SD, minimum value and maximum value. Binary logistic regression was used to find the relevant factors associated with depigmentation effect in ruby laser treatment

for lentigines. Statistical analyses were performed using PASW Statistics, release 20.0 (SPSS Inc., Chicago, IL, USA). A P value ≤ 0.05 was considered statistically significant.

III. RESULTS

A. Univariate Analysis of Skin Brightness Change by Ruby Laser Treatment for Lentigo Depigmentation

Pixel values for skin brightness were measured by mean, standard deviation, minimum, and maximum values as Fig. 1.

For the comparison of skin color change by ruby laser irradiation, we measured the skin color brightness in pretreatment and posttreatment. Mean brightness was increased from 137.3 to 150.5 and standard deviation of brightness were 17.8 in pretreatment and 16.4 in posttreatment.

Minimum and maximum skin color was also brightened by ruby laser treatment for lentigo depigmentation as Table I.

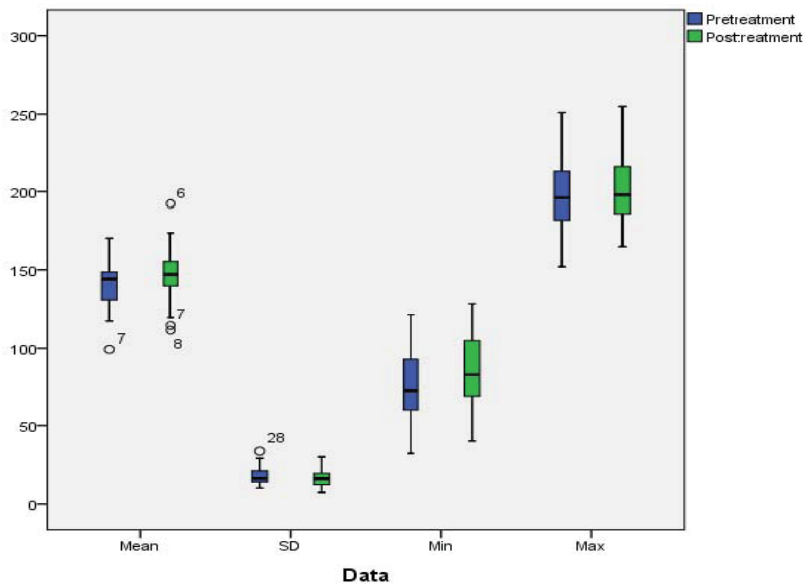


Fig. 1 Comparison of skin color brightness by ruby laser treatment for lentigo depigmentation

A. Multivariate Analysis of Skin Color Brightness Change by Ruby Laser Treatment for Lentigo Depigmentation

According to this experiment, the mean skin color difference was 13.2 by ruby laser treatment. We used this value as the control difference of skin brightness change in binary logistic regression analysis. Using this average, patients were divided into high effective group and low effective group. We defined skin color brightness change as the dependent variable. Independent variables were gender, age, energy, frequency and spot size.

Variables included in the logistic regression model were tested by significance of score statistics, and variables excluded from the logistic regression model were tested as probability of likelihood-ratio statistics by maximum partial likelihood

estimates. According to the multivariate logistic regression analysis, age and laser energy levels are the most important factors to solar lentigines treatment. Their respective odds ratios were 1.082 (95% CI, 1.007–1.163), and 1.431 (95% CI, 1.051–1.946) (Table II).

TABLE I
UNIVARIATE ANALYSIS OF SKIN BRIGHTNESS CHANGE BY RUBY LASER TREATMENT FOR LENTIGO DEPIGMENTATION

| Variables | Pretreatment | Posttreatment | P value |
|-----------|--------------|---------------|---------|
| Mean | 137.3±15.7 | 150.5±17.3 | 0.005 |
| SD | 17.8±6.3 | 16.4±4.9 | 0.005 |
| Min | 71.8±19.2 | 89.6±24.2 | 0.005 |
| Max | 197.2±25.1 | 204.9±23.6 | 0.005 |

According to Fig. 2, forty-three aged Korean male's lentigo

was almost disappeared and surrounding skin area's color was brightened than pretreatment by ruby laser treatment.

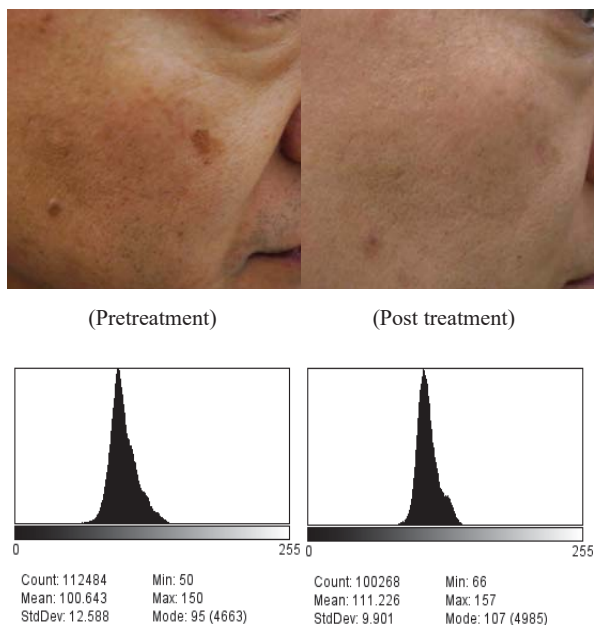


Fig. 2 Lentigo depigmentation by ruby laser treatment

TABLE II
MULTIVARIATE ANALYSIS OF SKIN BRIGHTNESS CHANGE BY RUBY LASER TREATMENT FOR LENTIGO DEPIGMENTATION

| Variables | Regression coefficient | Odds ratio | 95% CI | P value |
|-----------|------------------------|------------|-------------|---------|
| Age | 0.082 | 1.085 | 1.007-1.163 | 0.042 |
| Energy | 0.358 | 1.431 | 1.051-1.946 | 0.023 |

IV. DISCUSSION

The purpose of this report was not to discuss the place of laser surgery in the therapy of lentigo, nor the exact factors for selection of the treatment that should be depigmented. Both these issues remain the source of much controversy. As experience grows and new trials progress, more clinical factors of ruby laser treatment would be revealed such like this study. This paper deals only with clinical aspects of lentigo depigmentation access, particularly in cases where there is a treated by ruby laser. The relevant factors described here may also be used for other ruby laser treatment.

In this study, the comparison between skin color quantification on brightness images and digital analyzing program used. The analyzed images used the gray scale for brightness by 256 leveled intensity of skin color comparison. Histogram analysis of Image J shows a black and white appearance for pseudo-color image, which is consistent with the skin brightness imaging of lentigo depigmentation.

It is well established in the medical literature that multiple laser treatments are required to remove a pigment via selective photothermolysis. What has not been elucidated however is the factor of treatments that are actually required for a given patient. It is our contention that by incorporating the gray scale into the art of ruby laser treatment, medical professionals will

be able to better estimate the required factors of patient treatments.

Innovative additional manipulation of lentigo depigmentation with use of ruby laser can provide a validated method for objective assessment. Brightness of skin color is highly compatible with visual perception. Differentiation in color characteristics is useful in image analyzing. Therefore, gray scale can be used to highlight skin color changed areas of the lesion. The present study aims to present a reliable method of objective evaluation of results after laser treatment for lentigo which can be clinically applicable for surgical practice.

The mechanism of action of treatment using Q-switched ruby laser relates to selective photothermolysis that occurs by targeting a subcellular chromophore, and inducing specific thermal injuries to it without damaging surrounding structures thereby avoiding scar formation. Neighboring tissue remains undamaged because the chosen pulse width is less than or equal to the target's thermal relaxation time of 50 to 100 nsec, and therefore require lasers with very short pulse widths. Q-switching produces rapid pulse width of 20 to 50 nsec, permitting the laser to remain below the thermal relaxation time for melanosomes.

There are other kinds of laser treatment beside ruby laser. Although the alexandrite 755-nm-wavelength laser is effective in the treatment of unwanted hair, there are no published studies gauging the efficacy of the variable long-pulse alexandrite laser in the treatment of superficial pigmented lesions [9]. The 595 nm long-pulsed dye laser (LPDL) has been used for the treatment of vascular lesions and although it is well absorbed by oxyhemoglobin, it is also absorbed by melanin [10]. But according to previous researches, Q-switch ruby laser seems to be effect treatment on depigmentation. In pigmented lesions extending into the dermis, deeper pigmented melanocytic cells and nevus cells persist throughout a single course of Q-switch ruby laser exposure [11]. Also, pigmented lesions featuring a moderate amount of pigment exclusively in and around the basal cell layer, like solar actinic lentigo, can be successfully removed by a single Q-switch ruby laser exposure selectively damaging epidermal and basal pigmented structures [12].

In conclusion, the results of this study confirm that Q-switch ruby laser is an effective treatment option with skin color brightness for patients who mainly have skin surface pigmentation. Obviously, other skin symptom is uncertain directly affected from the treatment; however, the skin brightness effect provides a better appearance in lentigo tissue.

Although there exists an improvement in long-term skin color change in lentigo lesions, this is variable and unpredictable. Patients with moderate aging are more likely to display a better outcome. The clinical improvement is maintained at one year, although the results are not as remarkable as those seen at one-month follow-up. Additional treatment sessions would possibly provide an enhancement in the clinical results with longer efficacy.

V. CONCLUSION

Quality-switched ruby laser system could be an effective treatment method for solar lentigines. In terms of lentigo

depigmentation, patients' age and laser energy levels might be the important clinical factors for better prognosis.

REFERENCES

- [1] Jun HJ, Cho SH, Lee JD, Kim HS. A split-face, evaluator-blind randomized study on the early effects of Q-switched Nd:YAG laser plus Er:YAG micropeel (combined therapy) versus Q-switched Nd:YAG alone in light solar lentigines in Asians. *Lasers Med Sci.* 2014 May;29(3):1153-8.
- [2] Raziee M, Balighi K, Shabanzadeh-Dehkordi H, Robati RM. Efficacy and safety of cryotherapy vs. trichloroacetic acid in the treatment of solar lentigo. 2008 Mar;22(3):316-9.
- [3] Negishi K, Akita H, Tanaka S, Yokoyama Y, Wakamatsu S, Matsunaga K. Comparative study of treatment efficacy and the incidence of post-inflammatory hyperpigmentation with different degrees of irradiation using two different quality-switched lasers for removing solar lentigines on Asian skin. *J Eur Acad Dermatol Venereol.* 2013 Mar;27(3):307-12.
- [4] Wang CC, Chen CK. Effect of spot size and fluence on Q-switched alexandrite laser treatment for pigmentation in Asians: a randomized, double-blinded, split-face comparative trial. *J Dermatolog Treat.* 2012 Oct;23(5):333-8.
- [5] Sadighha A, Saatee S, Muhagheh-Zahed G. Efficacy and adverse effects of Q-switched ruby laser on solar lentigines: a prospective study of 91 patients with Fitzpatrick skin type II, III, and IV. *Dermatol Surg.* 2008 Nov;34(11):1465-8.
- [6] Ho SG, Yeung CK, Chan NP, Shek SY, Chan HH. A comparison of Q-switched and long-pulsed alexandrite laser for the treatment of freckles and lentigines in oriental patients. *Lasers Surg Med.* 2011 Feb;43(2):108-13.
- [7] Yamashita T, Negishi K, Hariya T, Yanai M, Iikura T, Wakamatsu S. In vivo microscopic approaches for facial melanocytic lesions after quality-switched ruby laser therapy: time-sequential imaging of melanin and melanocytes of solar lentigo in Asian skin. *Dermatol Surg.* 2010 Jul;36(7):1138-47.
- [8] Njoo MD, Westerhof W. Effective removal of certain skin pigment spots (lentigines) using the Q-switched ruby laser. *Ned Tijdschr Geneesk.* 1997 Feb 15;141(7):327-30.
- [9] Trafeli JP, Kwan JM, Meehan KJ, Domankevitz Y, Gilbert S, Malomo K, Ross EV. Use of a long-pulse alexandrite laser in the treatment of superficial pigmented lesions. *Dermatol Surg.* 2007 Dec;33(12):1477-82.
- [10] Kono T, Manstein D, Chan HH, Nozaki M, Anderson RR. Q-switched ruby versus long-pulsed dye laser delivered with compression for treatment of facial lentigines in Asians. *Lasers Surg Med.* 2006 Feb;38(2):94-7.
- [11] Kopera D, Hohenleutner U, Stolz W, Landthaler M. Ex vivo quality-switched ruby laser irradiation of cutaneous melanocytic lesions: persistence of S-100-, HMB-45- and Masson-positive cells. *Dermatology.* 1997;194(4):344-50.
- [12] Kopera D, Hohenleutner U, Landthaler M. Quality-switched ruby laser treatment of solar lentigines and Becker's nevus: a histopathological and immunohistochemical study. *Dermatology.* 1997;194(4):338-43.