

Cephalometric Changes of Patient with Class II Division 1 [Malocclusion] Post Orthodontic Treatment with Growth Stimulation: A Case Report

Pricillia Priska Sianita

Abstract—An aesthetic facial profile is one of the goals in Orthodontics treatment. However, this is not easily achieved, especially in patients with Class II Division 1 malocclusion who have the clinical characteristics of convex profile and significant skeletal discrepancy due to mandibular growth deficiency. Malocclusion with skeletal problems require proper treatment timing for growth stimulation, and it must be done in early age and in need of good cooperation from the patient. If this is not done and the patient has passed the growth period, the ideal treatment is orthognathic surgery which is more complicated and more painful. The growth stimulation of skeletal malocclusion requires a careful cephalometric evaluation ranging from diagnosis to determine the parts that require stimulation to post-treatment evaluation to see the success achieved through changes in the measurement of the skeletal parameters shown in the cephalometric analysis. This case report aims to describe skeletal changes cephalometrically that were achieved through orthodontic treatment in growing period. Material and method: Lateral Cephalograms, pre-treatment, and post-treatment of cases of Class II Division 1 malocclusion is selected from a collection of cephalometric radiographic in a private clinic. The Cephalogram is then traced and measured for the skeletal parameters. The result is noted as skeletal condition data of pre-treatment and post-treatment. Furthermore, superimposition is done to see the changes achieved. The results show that growth stimulation through orthodontic treatment can solve the skeletal problem of Class II Division 1 malocclusion and the skeletal changes that occur can be verified through cephalometric analysis. The skeletal changes have an impact on the improvement of patient's facial profile. To sum up, the treatment timing on a skeletal malocclusion is very important to obtain satisfactory results for the improvement of the aesthetic facial profile, and skeletal changes can be verified through cephalometric evaluation of pre- and post-treatment.

Keywords—Cephalometric evaluation, Class II Division 1 malocclusion, growth stimulation, skeletal changes, skeletal problems.

I. INTRODUCTION

CLASS II Division 1 malocclusions with Class II skeletal pattern due to retrognathic mandible shows a typical convex facial profile [1], [2]. This convex profile is possible to be corrected when the patient skeletal pattern is corrected to class I. The correction of a malocclusion can be done in two ways, namely growth stimulation when the patient is in the growth period or orthognathic surgery when the patient has passed the growth period. Therefore, beginning a treatment at

the right time will be critical to the success of the case [3], [4].

As known, the skeletal Class II malocclusion with dental Class II Division 1 usually occurs because patients have bad habits such as mouth breathing, thumb sucking, and lower lip biting. Patients with this malocclusion have a characteristic picture, like retrognathic mandible, increased overjet and also proclination of upper incisors [1]. Generally, parents do not realize the adverse effects of this habit because it was considered prevalent in young children. However, this dangerous habit can result in an undesirable appearance if not stopped when the child's permanent teeth begin to erupt. It is the abnormalities of skeletal patterns that can be generated by these habits which if not promptly detected and has passed the growth period, it can cause the skeletal malocclusion become difficult to be corrected and usually requires surgery. However, if this bad habit is detected early and corrective actions performed before the child past the growth period, the results obtained were satisfactory and stable and of course with the good cooperation of the patient and the parent [4].

One of the treatments / corrective action in Class II skeletal malocclusion with dental Class II Division 1 because of the bad habits in the growing period is with myofunctional appliance, which in principle is to use the orthodontic appliance that will help to get rid of the application of muscles pressure around the mouth directly to the teeth, so the teeth can reach a good arrangement [4], [5]. Experts have designed various types of myofunctional devices which have proved to be excellent in dealing with these types of skeletal problems, but most of these tools are quite complex in terms of preparation and felt uncomfortable in the mouth. Therefore, a simple and cheap enough trainer, such as the T4B, became one of the alternatives. Its proper use, as in this case, has been shown to help the correction of skeletal pattern with growth stimulation as needed. With good cooperation from patients and their parents, the use of this tool at the right time will help to achieve the correction of skeletal pattern as well as the one resulting from the use of conventional myofunctional.

II. HISTORY OF THE CASE

A female patient aged nine years and four months came with her mother for dental examination. According to her mother, the child has long complained of forwardly front teeth and wants to be treated, but several visits to the dentist said that she had to wait until all the permanent teeth erupted. Accordingly, after waiting as recommended for an examination, the mother returned to the dentist to appease the

Pricillia Priska Sianita is with the Department of Orthodontic, Faculty of Dentistry, Prof. Dr. Moesotpo University, Indonesia (e-mail: ppsianita@gmail.com).

child, who also has a bad habit of biting her lower lip.

Extra-oral examination showed a convex facial profile with retrognathic mandible and protrusive upper lip. Intra-oral examination showed a significant increase of overjet and crowding in the lower anterior region. The patient is still in mixed dentition period because only two first molars and four incisor teeth on the upper and lower jaws and two lower canines that are permanent teeth, the rest is the primary teeth (Fig. 1). Molar relationship is Class II and the incisor relation showed a significant increase in overjet, thus leading to a diagnosis of Class II Division 1.

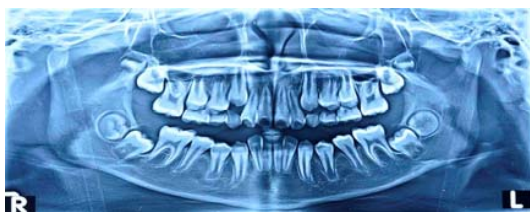

Fig. 1 Pre-treatment record of the patient in the form of panoramic radiographs showed that the patient is in the mixed dentition period and there are no pathological signs

Lateral cephalometric analysis of patients showed that the patient had a skeletal Class II malocclusion with retrognathic mandible, because of a large ANB angle obtained based on the skeletal parameters (Fig. 2, Table I). Maxillary incisor teeth inclination is proclination while inclination of mandibular incisor teeth is within range.

TABLE I

ANALYSIS OF LATERAL CEPHALOMETRIC - SKELETAL PARAMETERS			
No.	Skeletal parameter	Value	Conclusion
1	SNA angle	77°	Based on the analysis of skeletal parameters of lateral cephalometric, the patient had a skeletal Class II malocclusion with retrognathic mandible.
2	SNB angle	72°	
3	ANB angle	5°	
4	FMA angle	24°	

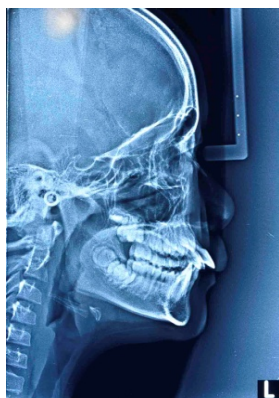


Fig. 2 Patient's lateral cephalograph pre-treatment and analysis results on skeletal parameters (Table I) shows that patients have skeletal Class II malocclusion with retrognathic mandible

III. TREATMENT PLAN

From the diagnosis of skeletal Class II malocclusion with dental Class II Division 1 and the patient still in a period of growth, the treatment plan prepared can include:

1. Education to stop the bad habit of biting her lower lip permanently.
2. Observation to perform deciduous tooth extractions at the appropriate time.
3. Begin with orthodontic treatment mechanic 2x4 on the lower jaw to relieve crowding in the anterior region.
4. Use of a T4B trainer to get rid from the lip pressure that can affect the development of the upper and lower dental arch.

IV. TREATMENT PROGRESS

Education is given to patients by involving the parents, in this case the mother. Some photos of the profile and intra oral condition of patients with skeletal and dental malocclusion of Class II Division 1 are shown to give an overview to the patient when the bad habit is not stopped permanently. Because the patient does want the treatment and is already aware of her condition, over the span of three months of observation, the patient's mother reported that the habit of lower lip biting had ceased.

Furthermore, the orthodontic treatment mechanic of 2x4 is started at the lower jaw to eliminate the crowding in that area. This elimination of crowding takes place fairly quickly, after about four months, while the patient also uses the T4B trainer to avoid pressure from the muscles around the lips and mouth. T4B, which stands for trainer for braces, is a tool designed to not only protect the mucosa of the mouth during treatment with fixed appliance but also simultaneously provide corrective action of myofunctional against bad habits that cause malocclusion (Fig. 3). Protective action provided by this tool is actually helping to keep the pressure from the muscles around the mouth off to the teeth so as to enable the better development of the teeth with a good arrangement in accordance with the ovoid shape and grooves found on the trainer [6].

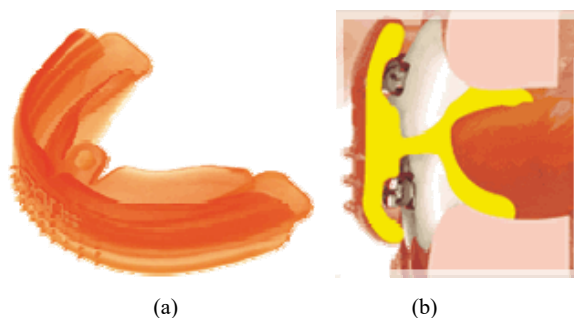


Fig. 3 (a) The T4B - trainer worn to provide protection to the oral mucosa after bracket bonding and against the pressure of the muscles around the mouth (b)

V. TREATMENT RESULT

After treatment with the use of mechanic 2x4 with a T4B to

eliminate the pressure of the muscles around the mouth and at the same time to eliminate lower anterior crowding, the patient showed significant progress (Fig. 4, Table II).

TABLE II
ANALYSIS OF LATERAL CEPHALOMETRIC - SKELETAL PARAMETERS DURING TREATMENT

No.	Skeletal parameter	Value	Conclusion
1	SNA angle	77°	Based on the analysis of skeletal parameters on lateral cephalograph, the patient had a skeletal Class I malocclusion with normal position of the mandible relative to the cranial base
2	SNB angle	74°	
3	ANB angle	3°	
4	FMA angle	25.5°	

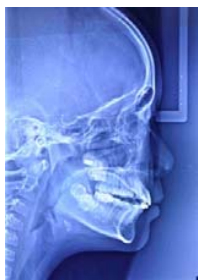

Fig. 4 Patient's lateral cephalograph during treatment and the results of analysis on skeletal parameters (Table II) showed that the patient had a skeletal Class I malocclusion with relatively normal ANB angle

After the correction of patient's skeletal problem has been successfully achieved, the bracket on the lower anterior teeth is then removed and the patient continues the treatment with the use of the trainer only. Evaluation of patient's lateral cephalograph made after a period of 10 months, showed encouraging results in term of positions of the mandible relative to the cranial base and stability as well (Fig. 5, Table III). Patient's facial profile changes from convex to straight. The overjet reduced and the incisors relation became normal.

TABLE III
ANALYSIS OF LATERAL CEPHALOGRAPH - SKELETAL PARAMETERS POST-TREATMENT

No.	Skeletal parameter	Value	Conclusion
1	SNA angle	77°	Based on the analysis of skeletal parameters on lateral cephalograph, the patient had a skeletal Class I malocclusion with normal mandibular position against cranial base.
2	SNB angle	75°	
3	ANB angle	2°	
4	FMA angle	25.5°	

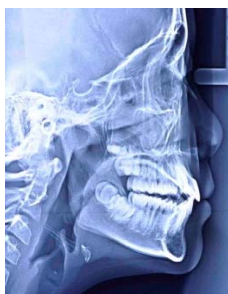

Fig. 5 Patient's lateral cephalograph during treatment and the results of analysis of skeletal parameters (Table III) showed that the patient

had a skeletal Class I malocclusion with normal ANB angle

VI.DISCUSSION

Skeletal Class II with dental Class II Division 1 malocclusion, often found in children in the period of growth and who have bad habits like biting the lower lip, as was the case with this patient. The success of skeletal correction in this case requires good cooperation from patient and their parents, as well as appropriate treatment timing which allows the stimulation of growth by utilizing the simple yet sophisticated design of a T4B and orthodontic treatment mechanic of 2x4 to eliminate crowding in the anterior region of the lower jaw [7]-[9]. Of course, all of this is made possible by a precise diagnosis of the case through the analysis of patient's lateral cephalograph to get information pertaining to classification of the malocclusion, skeletal pattern, and the position of both maxilla and mandible against the base of the cranium; thus, growth stimulation through the selection of orthodontic devices can be directed to the required section to produce esthetic facial profile. Superimposition results of the lateral cephalograph tracing done in this case showed the effectiveness of a treatment plan that was executed at the right time and in a cooperative patient (Fig. 6) [4], [10]. The value changes of skeletal parameter on lateral cephalograph pre-treatment, during and post-treatment showed success growth stimulation performed in these patients (Table IV) [11], [12].

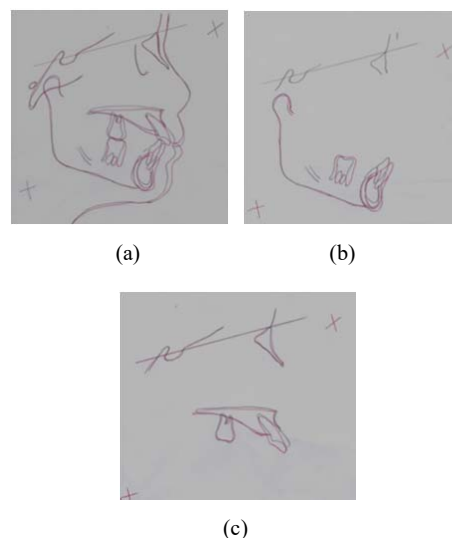


Fig. 6 (a) The overall superimposition shows correction of maxillary incisor teeth inclination, which helps to improve the patient's profile convexity. (b) The mandibular superimposition shows skeletal correction represented by the movement of B point to the front followed by the mandibular incisor tooth position to help reduce the overjet. (c) The maxilla superimposition shows the correction of incisor tooth inclination that helps to overcome the protrusion of the upper lip and thus significantly help to achieve satisfactory treatment outcomes in these patients

Overall, the patient showed good progress and good results, as shown in Table IV. The ANB angle showed significant reduction, while the SNA angle shows the fixed value so that

it can be assumed that the mandibular growth only has overcome the anterior-posterior discrepancy of maxilla to the mandible, so that the ANB angle post-treatment became normal (2°).

TABLE IV
PATIENT'S PROGRESS VALUE ON SKELETAL PARAMETER BEFORE, DURING
AND POST TREATMENT

No	Skeletal parameter	Pretreatment value	During treatment value	Post treatment value
1	SNA angle	77°	77°	77°
2	SNB angle	72°	74°	75°
3	ANB angle	5°	3°	2°
4	FMA angle	24°	25.5°	25.5°

The important lesson to be drawn from this case is that the dissemination of information about the characteristics of a skeletal pattern of malocclusion and the right treatment timing is still needed to get a satisfactory correction. The impact of a bad habit that can complicate the corrective action, if not stopped at the right time, must be well understood. The importance of a correct understanding of the orthodontic treatment, which in this connection should begin the treatment even before all the permanent teeth eruption, will help parents to bring their children for assessment as early as possible and encourage clinicians to begin early treatment of growth modification or stimulation (phase 1) as required to facilitate the treatment of the case later on, when they are needed (phase 2). Furthermore, a good understanding of the principles of myofunctional treatments can help to choose a device that is simple but effective by utilizing the existing technological developments in dentistry.

REFERENCES

- [1] McDonald, F., and Ireland, A. J. Diagnosis of the Orthodontic Patient, Oxford University Press, Toronto, 1998, p.13 – 62.
- [2] Bahreman A., Early-Age Orthodontic Treatment, Quintessence Publishing Co, Inc., Warsaw, 2013, p.46 – 69.
- [3] Patti, A., and Perrier, G., Clinical Success in Early Orthodontic Treatment, Quintessence Publishing Co, Inc., Warsaw, 2005, p.53 – 99.
- [4] McNamara, J. A., Brudon, W. L., Orthodontic and Orthopedic Treatment in the Mixed Dentition, Needham Press, Ann Arbor, 1994, p. 3 – 12, 95 – 116.
- [5] English, J. D., Peltomaki, T., Litschel, K. P., Mosby's Orthodontic Review, Mosby Elsevier, Missouri, 2009, p. 152 – 177.
- [6] Myofunctional Research co., at: <http://old.myoresearch.com/cms/index.php?t4b> Accessed on 27/02/2017
- [7] Dowsing, P., Sandler, P. J., How to effectively use a 2x4 appliance, Journal of Orthodontic, Vol 31, 2004, p. 248 – 258.
- [8] Isaacson, R. J., Lindauer, S. J., Rubenstein, L. K., Activating a 2x4 appliance, The Angle Orthodontist, Vol 63, No 1, 1993, p. 18 – 24.
- [9] McKeown, H. F., Sandler, J. The Two by Four Appliance: A Versatile Appliance, Dent.Update 2001; 28: 496 – 500.
- [10] Athanasiou, A. E., Orthodontic Cephalometry, Mosby-Wolfe. Tokyo, 1997, p. 105 – 124.
- [11] Jacobson, A., Radiographic Cephalometry from Basic to Video Imaging, Quintessence Publishing Co. Warsaw, 1995, p. 65 – 95.
- [12] Phulari, B. S., An Atlas on Cephalometry Landmark, Jaypee Brothers Medical Publishers (P) Ltd. New Delhi, 2013, p. 204 – 205.