

Can EEG Test Helps in Identifying Brain Tumor?

M. Sharanreddy, P. K. Kulkarni

Abstract—Brain tumor is inherently serious and life-threatening disease. Brain tumor builds the intracranial pressure in the brain, by shifting the brain or pushing against the skull, and also damaging nerves and healthy brain tissues. This intracranial pressure affects and interferes with normal brain functionality, which results in generation of abnormal electrical activities from brain. With recent development in the medical engineering and instruments, EEG instruments are able to record the brain electric activities with high accuracy, which establishes EEG as a primary tool for diagnosing the brain abnormalities. Research scholars and general physicians, often face difficulty in understanding EEG patterns. This paper presents the EEG patterns associated with brain tumor by combing medicine theory and neurologist experience. Paper also explains the pros-cons of the EEG based brain tumor identification.

Keywords—Brain tumor, Electroencephalogram (EEG).

I. INTRODUCTION

ACCORDING to statistical report published by the United States' Central Brain Tumor Registry (CBTRUS), every year more than 200,000 people in US are diagnosed with a primary or metastatic brain tumor. The brain made of neurons cells; these cells are responsible for brain normal functionalities. The brain normally forms new cells only when they are needed to replace old or damaged ones. Most cells repair themselves by dividing to make more cells. Normally, this turnover takes place in an orderly and controlled manner. If, for some reason, the process gets out of control, the cells will continue to divide, developing into a lump, which is called a tumor [1].

Brain tumor can be defined as an uncharacteristic growth of cells inside the brain or the skull, which can either be cancerous or non-cancerous. Brain tumors can develop at any age, but are most common in children between the ages of 3-12, and in adults aged 55-65.

A. Causes and Symptoms of Brain Tumor

The cause of brain tumors is unknown, but people who work with rubber and certain chemicals have a greater-than-average risk of developing them. There is no evidence that head injury causes brain tumors. Researchers are trying to determine the relationship, if any, between brain tumors and viruses, family history, and long-term exposure to electromagnetic fields [1].

Signs and symptoms of brain tumors mainly depend on two factors: tumor size (volume) and tumor location. Symptoms do not usually appear until the tumor grows large enough to displace, damage, or destroy delicate brain tissue.

Sharanreddy.M is research scholar in Electrical & Electronics engineering P.D.A.C.E, India (e-mail: sharanreddy.m@hotmail.com).

Dr. P. K. Kulkarni is Prof and HOD of Electrical & Electronics engineering in P.D.A.C.E, India.

Although brain tumor symptoms resemble those of many other illnesses, the presence of a brain tumor may be indicated by:

- persistent headaches with vomiting or convulsions
- progressive deterioration of sight, speech, hearing, touch; or deterioration in the ability to use an arm, hand, foot, or leg

When a patient experiences one or more of the above symptoms, a primary care physician need to perform a complete physical examination, take a detailed medical history, and conduct a basic neurologic examination to evaluate:

- balance and coordination
- abstract thinking and memory
- eye movements
- hearing, touch, and sense of smell
- reflexes
- control of facial muscles and movements of the head and tongue
- awareness

Swelling or obstruction of the passage of cerebrospinal fluid (CSF) from the brain may cause of increased intracranial pressure, which translates clinically into headaches, vomiting, or an altered state of consciousness and in children change in the diameter of the skull and bulging of the fontanelles. More complex symptoms such as endocrine dysfunctions indicate possible presence brain tumors.

Brain tumor causes bilateral temporal visual field defect (due to compression of the optic chiasm) or dilatation of the pupil, the sudden onset of focal neurologic symptoms, such as cognitive and behavioral impairment (including impaired judgment, memory loss, lack of recognition, spatial orientation disorders), personality and emotional changes, hemiparesis, hypoesthesia, aphasia, ataxia, visual field impairment, impaired sense of smell, impaired hearing, facial paralysis, double vision, or more severe symptoms such as tremors, paralysis on one side of the body hemiplegia, or (epileptic) seizures in a patient with a negative history for epilepsy.

B. Brain Tumor Classification

There are two basic kinds of brain tumors, "primary brain tumors" and "metastatic brain tumors (secondary tumors)". Primary brain tumors start, and tend to stay, in the brain. Metastatic brain tumors begin as cancer elsewhere in the body and spread to the brain [2].

Primary brain tumor is the second most common cause of cancer death between birth and the age of 34, and the fourth most common cause of cancer death in men aged 35-54. Primary tumors of the brain and central nervous system are often associated with HIV infection. Men and caucasians have

a higher risk of developing brain tumors. According to neurologist observation, occurrence of primary brain tumor is high in the children's with a history of previous radiation treatment to the head for cancer; parents with certain cancers (nervous system, salivary gland, colon); having an older father; occupational exposure to vinyl chloride, lead, and pesticides; history of epilepsy; history of certain genetic conditions (tuberous sclerosis, neurofibromatosis, von Hippel Lindau, familial polyposis, Osler-Weber-Rendu, Li-Fraumeni). The most common primary brain tumors are: Gliomas (50.3%), Meningiomas (20.9%), Pituitary adenomas (15%), Nerve sheath tumors (8%).

Secondary brain tumors or metastatic tumors begin growing elsewhere in the body and then travel to the brain form metastatic brain tumors. This means that a cancerous neoplasm has developed in another organ elsewhere in the body and that cancer cells have leaked from that primary tumor and then entered the lymphatic system and blood vessels. They then circulate through the bloodstream, and are deposited in the brain. There, these cells continue growing and dividing, becoming another invasive neoplasm of the primary cancer's tissue. Secondary tumors of the brain are very common in the terminal phases of patients with an incurable metastasized cancer; the most common types of cancers that bring about secondary tumors of the brain are lung cancer, breast cancer, malignant melanoma, kidney cancer and colon cancer. Secondary brain tumors are the most common cause of tumors in the intracranial cavity.

C. Brain Tumor Diagnosis

The brain tumor diagnosis will start with an interrogation of the patient to get a clear view of his medical antecedents, and his current symptoms. Examinations in this stage may include the eyes, otolaryngological (or ENT) and/or electrophysiological exams. Imaging clinical test plays a central role in the diagnosis of brain tumors. The most commonly used imaging methods for diagnosis are Magnetic Resonance Imaging (MRI), Computerized Tomography (CT), positron emission tomography (PET), single-photon emission computed tomography (SPECT), and functional MRI (fMRI) [3], [4].

With advance EEG instruments, brain abnormal electrical activities can be recorded with high accuracy; this establishes EEG test as an important clinical test for the diagnosis and treatment of brain diseases. EEG are up-and coming as a vital methodology to suit the increasing global demand for more affordable and effectual clinical and healthcare services, with fitting interpretation methods.

EEG test often plays an important role in the diagnosis of brain tumors. EEG test is reliable in localizing lesions involving superficial portions of the cerebral hemispheres, though it is of limited value in deep-seated lesions. Being a non-invasive low cost procedure, the EEG is a reliable tool for gliomas tumor diagnosis (since these tumors are more electrical active) and less successful in detecting brain stem tumors and meningioma series (since they usually occur in deeper brain and less electrical activity). EEG is most relevant

in assessing how the brain responds to brain tumor treatments (e.g. post operative).

The role of EEG in detecting focal cerebral disturbances has undergone a significant change since the development of CT scan and MRI with high (<1mm) spatial resolution. Today EEG is used primarily to complement these studies by evaluating functional changes in the patient's condition; it demonstrates aspects of brain physiology that are not reflected in structural neuro imaging tests. Despite limited spatial resolution, EEG continues to be a valuable tool for research and diagnosis, especially when millisecond-range temporal resolution (not possible with CT or MRI) is required.

Despite the fact that EEG is an important clinical tool for diagnosing, monitoring and managing brain tumor disorders, many researchers and physician unaware of the EEG abnormalities which indicate the presence of brain tumor. This paper highlights the major EEG changes that occur with different brain tumors.

II. DATA BASE

Scalp EEG data used in this paper are collected from varies hospitals, doctors, research centers and universities. Total 1500 samples of EEG data collected from 125 patients which are categories under grade II and grade III stage. (75 males, ages 32 - 52; and 50 females, ages 35-59), out of which 1000 EEG data from gliomas brain tumor, 250 from meningiomas brain tumors, remaining are from other type of tumors (adenomas, sheath tumor, glioneuronal and metastases).

III. EEG PATTERNS ASSOCIATED WITH BRAIN TUMOR

EEG abnormalities in brain tumors depend on the brain tumor stages. The EEG changes observed in brain tumors patients are mainly from disturbances in bordering brain parenchyma.

Brain tumors may be associated with a variety of EEG findings [5]-[9]. The following may be seen at the time of diagnosis.

- Delta wave activity
- Focal attenuation of background activity
- Localized attenuation of background activity
- Disturbance of the alpha rhythm
- Asymmetric beta activity
- Interictal epileptiform discharges
- Seizures

A. Delta Wave Activity

Delta waves useful in identifying the association between localized slow waves on EEG and tumors of the cerebral hemispheres. Focal delta activity is the classic electrographic sign of a local disturbance in cerebral function. A structural lesion is strongly suggested if the delta activity is continuously present. EEG waves show variations in amplitude, duration, morphology (polymorphic) and persists changes in physiologic states, such as sleep or alerting procedures. When focal delta is found without a corresponding imaging abnormality, it is usually in the setting of acute seizures

(especially post-ictal), nonhemorrhagic infarction or trauma. Clinical and experimental observations indicate that polymorphic delta activity (PDA) results primarily from lesions affecting cerebral. Lesions restricted to the cortical mantle generally do not produce significant delta activity.

Intermittent rhythmic delta activity (IRDA) often seen in brain tumor patients, but studies correlating with pathologic specimens suggest that IRDA also associated with diffuse gray matter disease. IRDA usually occurs at frequencies of 2-2.5 Hz with relatively sinusoidal, stereotypic, bilaterally synchronous waveforms appearing in short bursts. The ascending phase is sloped more steeply than the descent, and waves are typically bilateral and widespread with peak amplitude frontally in older individuals (FIRDA) and occipitally in children (OIRDA). These patterns attenuate with alerting or eye opening. Eye closure, drowsiness, and hyperventilation accentuate IRDA. Fig. 1 shows the EEG signal with FIRDA in a 67 year patient with subcortical gliomas. Unlike PDA, IRDA increases in drowsiness and attenuates with arousal. IRDA often is observed without structural pathology, as in metabolic encephalopathies, but it also can occur with diencephalic or other deep lesions.

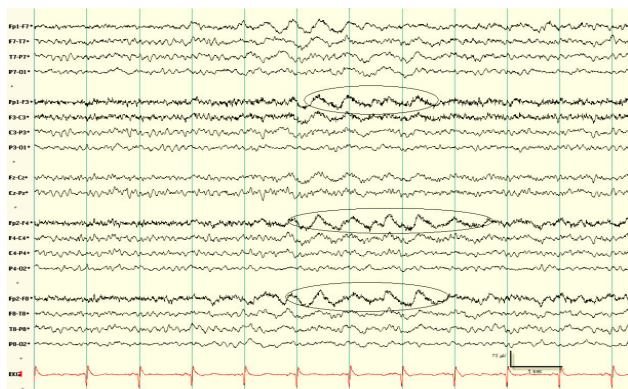

Fig. 1 FIRDA in a 67-year-old patient with subcortical gliomas, highlighted area shows high voltage, bisynchronous, and well formed delta waves

B. Focal Attenuation of Background Activity

Most tumor tissue does not generate electrical activity detectable with conventional recording techniques; hence electrical silence is the best localizing sign of a cerebral tumor. However, it is a rare finding, occurring only when the tumor involves significant cortical areas with minimal subcortical disruption. Incomplete loss of activity, especially faster normal rhythms, is observed more commonly and is diagnostically helpful.

C. Disturbance of the Alpha Rhythm

EEG of patients with focal or diffuse neurological symptoms shows disturbance of the alpha rhythm. Slowing of the alpha rhythm ipsilateral to a tumor is more common and significant observation. However, disturbance of alpha rhythm depends on the site of the tumor. The more posterior the location, the more the alpha tends to be slowed, non-persistent

or disturbed by admixed theta waves. In rare situation the alpha rhythm also may fail to block to eye opening on the side of the neoplasm (Bancaud phenomenon). Fig. 2 shows slow alpha activity observed in a 46-year-old patient with gliomas.

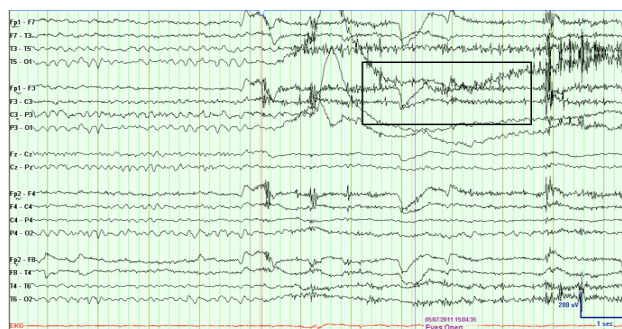


Fig. 2 EEG of slow alpha activity observed in a 46-year-old patient with gliomas. Highlighted area shows disturbed alpha rhythms

D. Asymmetric Beta Activity

Abnormalities of beta activity usually are limited to voltage asymmetries. They considered unequivocally abnormal, when a persistent amplitude difference of one third or greater (expressed as a fraction of the higher voltage) should be present. Diminished beta activity results from cortical dysfunction as in parenchymal tumors or increase in resistance of the medium-separating cortex from scalp-recording electrodes, as in meningiomas. Focally increased beta activity usually is associated with a skull defect. Fig. 3 shows slow beta activity observed in a 56-year-old patient with parenchymal tumor.

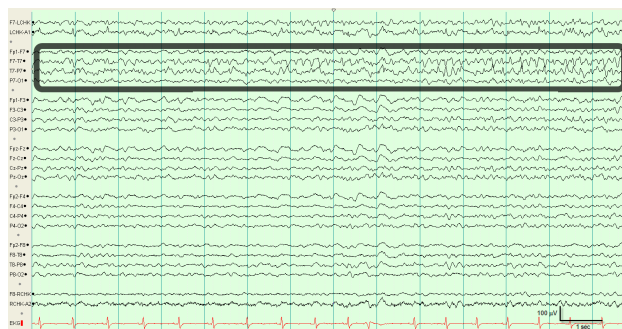


Fig. 3 EEG of slow beta activity observed in a 56-year-old patient with parenchymal tumor. Highlighted area shows abnormal beta rhythms.

E. Interictal Epileptiform Discharges

Spikes, sharp waves, or spike-wave complexes occurring with consistent localization are observed uncommonly early in the course of brain tumors. However, they are more common as early findings of slowly growing neoplasms associated with seizures. Patients with tumors may exhibit periodic lateralized epileptiform discharges (PLEDs), particularly after a series of seizures. Fig. 4 shows the PLEDs activities in gliomas tumor patient. Seizures are seen in most of brain tumor patients. If seizures are observed sufficiently closely and persistently; the

pattern likely represents a transitional state between ictal and interictal epileptiform discharges [10]-[13]. Fig. 5 shows right central spike-and-slow wave IEDs in a patient with a right frontal tumor with partial seizures.

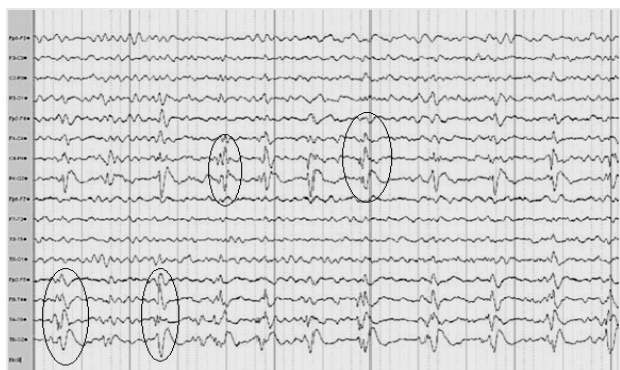


Fig. 4 EEG shows left temporal PLEDs plus in a 51 year patient with a gliomas tumor Note the rhythmic ictal discharge abutting the discharge

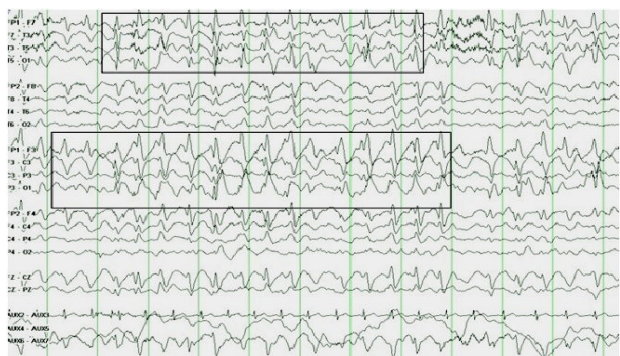

Fig. 5 EEG shows right central spike-and-slow wave IEDs and focal slowing in a patient with a right frontal tumor with partial seizures

Temporal intermittent rhythmic delta activity (TIRDA) is a unique form of intermittent rhythmic delta activity. It consists of an intermittently monomorphic burst of delta frequencies maximal typically in a unilateral temporal derivation. The presence of TIRDA has a strong association with partial seizures. It may provide localizing capabilities in patients with temporal lobe epilepsy. TIRDA is often associated with interictal epileptiform discharges (IEDs) and is abnormal. Fig. 6 shows TIRDA activities of 46 year patient with gangalimos.

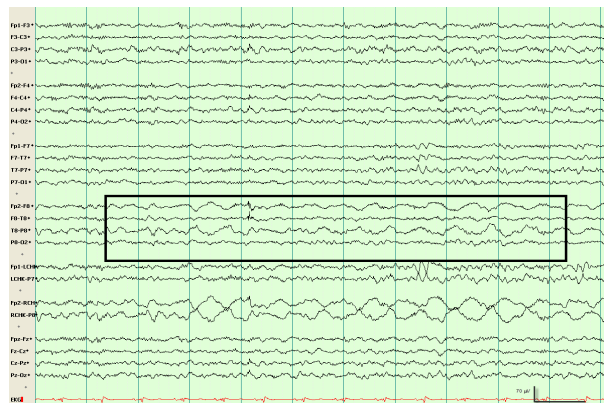


Fig. 6 EEG shows TIRDA activity observed in a 46-year-old patient with glioblastomas tumor. Highlighted area shows abnormal delta rhythms

F. Seizures

Seizures are encountered in up to 50% of patients with brain tumors. Twenty to forty percent of patients experience a seizure by the time their tumors are diagnosed, and an additional 20-45% of patients who do not initially present with seizures eventually develop them. Seizures may present with tumors that are both intra-axial or infiltrative, such as astrocytomas, and extraaxial or distortive, such as meningiomas. Low-grade, well-differentiated gliomas have the highest incidence of seizures.

Tumors located in the limbic regions, especially the temporal lobe, and in primary or secondary motor or sensory cortices, are regarded as particularly epileptogenic. The most common seizure semiology is simple partial, followed by complex partial, although specific seizure semiology is dependent on location. Approximately half of the patients also experience secondary generalized seizures. Tumor-related seizures also occur more frequently in younger patients than in older patients.

IV. LOCATION SPECIFIC EEG CHANGES

According to neurologist EEG abnormalities varies with tumor location [14]. Hence location specific EEG abnormalities are discussed in the below section.

A. Supratentorial Tumors

Supratentorial region of the brain is the area located above the tentorium cerebelli. The supratentorial region contains the cerebrum, tumor present in this area are seen mostly in adults. Tumors present in frontal lobe characteristically cause focal PDA, which accurately localizes the lesion. Especially if the lesion is close to the midline, PDA may be bilateral, but of higher amplitude and lower frequency ipsilateral to the tumor. In some cases, slowing may be IRDA rather than PDA. This occurs most often when deep structures such as the corpus callosum are involved (e.g., butterfly gliomas). The alpha rhythm is often preserved.

Temporal gliomas are generally the easiest to localize on EEG, since 80% of patients shows clear PDA over the tumor site. EEG from the contralateral hemisphere may be normal or

may show milder slowing. Temporal gliomas often are associated with seizures; they demonstrate interictal epileptiform discharges. These discharges may be identical to those associated with non-neoplastic lesions such as mesial temporal sclerosis, especially when the tumor is located medially, as is often the case with very slow-growing tumors, such as gangliogliomas and dysembryoplastic neuroepithelial tumors.

Parietal tumors less often produce localized slowing; PDA usually is lateralized but often not clearly localized. When phase reversals are present, they may be temporal or frontal rather than parietal. In centroparietal tumors, mu rhythms may be attenuated ipsilaterally, but occasionally may be more persistent and of higher amplitude.

Occipital gliomas often produce focal changes, especially PDA and alpha rhythm abnormalities. Occipital meningiomas, mainly of the tentorium, can cause more focal EEG changes.

B. Deep Hemispheric Tumors

Tumors which present in lateral, ventricles and surrounding structures (including the diencephalon, basal ganglia, and corpus callosum) are known as deep hemispheric tumors. The typical EEG finding of these tumors is IRDA. This finding classically has been associated with hydrocephalus or increased intracranial pressure, but this belief may not be valid, since IRDA is uncommon in hydrocephalus of nonneoplastic origin and is not present in benign intracranial hypertension. PDA and epileptiform discharges typically do not occur with intraventricular and sellar tumors. In hypothalamic hamartomas, ictal and interictal EEG discharges may be seen over the frontal or temporal lobe, depending on whether anterior or posterior hypothalamus is involved. In the sellar region, the EEG is usually normal, although bitemporal slowing may be seen, especially with large lesions [15].

C. Infratentorial Tumors

In brainstem and cerebellar tumors, EEG is more often abnormal in children than in adults. If present, slowing is most often posterior and bilateral. IRDA may be observed, possibly more so if hydrocephalus is present. EEG is usually normal in cerebellopontine angle tumors. Slowing is often intermittent and usually but not always ipsilateral to the lesion; it may be bilateral or even predominantly contralateral.

V. BRAIN TUMOR TYPE EEG ABNORMALITIES

EEG abnormalities vary based tumor type [16]-[20]. Some tumor specific EEG abnormalities are discussed below.

A. Meningiomas

Being extra-axial, meningiomas compress the brain but cause little destruction of brain tissue. Therefore, meningiomas of the anterior or middle cranial fossa, unless large, infrequently alter EEGs. Convexity meningiomas are more likely to cause EEG changes. Focal slowing, FIRDA, or beta asymmetry may be seen. Epileptiform discharges are observed only in a minority of patients, despite their propensity to have seizures.

B. Gliomas

Gliomas brain tumors associated with the three types of glial cells in the brain, which include astrocytes, oligodendrocytes and ependymal cells. Slowly growing gliomas such as oligodendrogliomas and fibrillary astrocytomas (excluding tumors of deep structures) often can be distinguished from the more rapidly growing anaplastic astrocytoma and glioblastoma multiforme.

With more benign tumors, which are comparatively circumscribed, the abnormalities tend to be localized and within the theta range. Indolent gliomas commonly cause seizures, and epileptiform activity may appear before significant slowing. Later, delta appears, often intermittently and at 2-3 Hz. Still later, focal PDA becomes persistent.

In rapidly growing tumors, relatively more overall abnormality is present, and the background (particularly the alpha rhythm) is more impaired and disorganized. Glioblastomas produce the most widespread, slowest (often 1 Hz or less), and largest (100-200 μ V) delta waves. These tumors cause prominent PDA, with marked alteration of background rhythms, also the high incidence of necrosis makes "flat PDA" (low-amplitude slow delta with diminished fast activity) more likely. Fig. 7 EEG shows high-frequency, mu-like arcuate waveforms.

C. Glioneuronal Tumors

Glioneuronal tumors are highly epileptogenic. Electrographically, they can be associated with continuous spike discharges and spike-bursts.

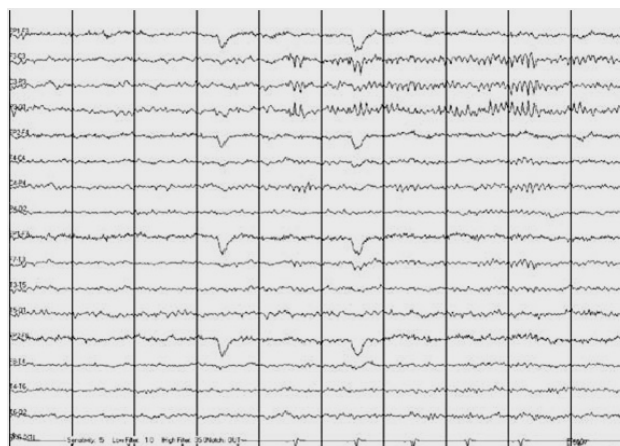


Fig. 7 EEG shows high-frequency, mu-like waveforms focally over the left parietal derivations at 10 Hz in the region of a brain tumor

D. Metastases

Metastatic tumors to the brain occur commonly with carcinomas of lung, kidney, and breast and with melanomas and chorionic carcinomas. When metastases are present bilaterally, slowing often appears diffuse, although it is often asymmetric; slowing from multiple bilateral lesions is often difficult to distinguish from a toxic-metabolic disturbance. Meningeal carcinomatosis usually causes changes that correlate with the clinical situation; when deposits are

widespread and causes an encephalopathy, slowing is usually diffuse.

Isolated metastases usually cause less prominent abnormalities than gliomas of similar size and location. Slow waves show higher frequency, lower amplitude, and less persistence than with high-grade gliomas, and normal background rhythms are more likely to be preserved.

VI. CONCLUSION

This article reviews the major EEG changes that occur with different brain tumors. Being a low cost procedure, the EEG is an attractive tumor diagnosis method; it is a reliable tool for the gliomas tumor series. The EEG is, however less successful in detecting brain stem tumors and meningioma series. By referring literature, consulting various neurologist, physician and after extensively analyzing EEG signals, authors comes to opinion that brain tumor localization, tumor type identification and tumor stage identification is not possible using EEG signals, hence EEG can't be used as primary tool for brain tumor identification.

ACKNOWLEDGMENT

Author thanks would like to thank Dr. M. R. Pujari, and staff members of M R Medical College, Gulbarga, for valuable guidance at every step in making of this paper.

REFERENCES

- [1] American Brain Tumor Association, Brain Tumor Primer – A Comprehensive Introduction to Brain Tumor, ABT Press, 9th edition, 2012
- [2] Marc K. Rosenblum, The 2007 WHO Classification of Nervous System Tumors: Newly Recognized Members of the Mixed Glioneuronal Group, International Society of Neuropathology, 2007
- [3] Lee Suan Yew and Gwee Ah Leng, The Diagnosis of brain tumour, Singapore Medical Journal, Vol 9, 1968
- [4] Bickford RG, Electroencephalographic diagnosis of brain tumors, Am J Surg, Vol 93, 1957, pp 946-51
- [5] H. L. Atwood, W. A. MacKay, Essentials of neurophysiology, Decker-Hamilton, 1989
- [6] Daly DD, Thomas JE, Sequential alterations in the electroencephalograms of patients with brain tumors, Electroencephalogram Clin Neurophysiol, Vol 10, 1958, pp 395-404
- [7] Cobb WA, Guiloff RJ, Cast J, Breach rhythm: the EEG related to skull defects, Electroencephalogram Clin Neurophysiol, Vol 47, 1979, pp 251-71
- [8] Siddiqui F, Bromfield E, Winslow N, Role of EEG in predicting post-operative seizures in brain tumor patients, Epilepsia. Vol 41, 2000
- [9] Blume WT, Girvin JP, Kaufmann JC, Childhood brain tumors presenting as chronic uncontrolled focal seizure disorders, Ann Neurol, Vol 12, 1982, pp 538-41
- [10] Hughes JR, Zak SM, EEG and clinical changes in patients with chronic seizures associated with slowly growing brain tumors, Arch Neurol, Vol 44, 1987, pp 540-543
- [11] Khan RB, Onar A, Seizure recurrence and risk factors after anti-epilepsy drug withdrawal in children with brain tumors, Epilepsia, Vol 47, 2006, pp 375-379
- [12] Zaatreh MM, Firlirk KS, Spencer DD, Spencer SS, Temporal lobe tumoral epilepsy: characteristics and predictors of surgical outcome, Neurology, Vol 61, 2003, pp 145-151
- [13] Fischer-Williams M, Dike GL, Brain tumors and other space-occupying lesions. In Electroencephalography: Basic Principles, Clinical Applications, and Related Fields. Williams & Wilkins, 3 Edition, 1993
- [14] Daly D, et al, Rhythms associated with gliomas of the cerebral hemispheres, Electroencephalogram Clin Neurophysiol, 49 Edition, 1980
- [15] Ferrier CH, Aronica E, Leijten FS, Spliet WG, van Huffelen AC, van Rijen PC, Electrocorticographic discharge patterns in glioneuronal tumors and focal cortical dysplasia, Epilepsia, Vol 47, 2006, pp 477-486
- [16] Korinthenberg R, Scheuring B, Boos J, Niemeyer C, On the origin of EEG-slowing and encephalopathy during induction treatment of acute lymphoblastic leukemia, Med Pediatr Oncol, Vol 39, 2002, pp 566-72
- [17] Young Zoon Kim, Eun Hee Lee and Kyoung Soo Lee, Clinical Analysis for Brain Tumor-Related Epilepsy during Chemotherapy for Systemic Cancer with Single Brain Metastasis, Cancer Res Treat, Vol 43, 2011, pp 160-169
- [18] M. Gelabert-González, J.M. Santín Amo, A. Arcos Algaba, R. Serramito García, Intracranial gangliogliomas. A review of a series of 20 patients, Journal of neurology, Elsevier, Vol 14, 2010
- [19] Cancer Council Australia, Adult Gliomas a guide for patients, their families and careers, Cancer Council Australia, Sydney, 2011
- [20] Atlanta, Ga, American Cancer Society: Cancer Facts and Figures 2012, American Cancer Society, 2012

Sharanreddy. M obtained his Bachelor's degree in Electronics and Communication from VTU, Karnataka, India. Then he obtained his Master's degree in Power Electronics from VTU, Karnataka, India. He published more than 10 papers in the various International Journals. Currently pursuing his Ph.D in Dept Electrical & Electronics, P.D.A. College of Engineering, Gulbarga, India. His specializations include are Signal Processing, Bio Medical Engineering, Power Electronics and Bluetooth network.

Dr. P. K. Kulkarni received his Ph.D degree from IIT Roorkee, India. He has more than 25 years of teaching Experience. He published more than 40 papers in the various International Journals. Organized and chaired international conferences. Currently working as Professor and HOD of Dept Electric and Electronics Engineering in P.D.A College of Engineering, Gulbarga, India. His research interests are in Signal Processing, Bio Medical Engineering, and Image Processing.