

# Camel Thorn Has Hepatoprotective Activity against Carbon Tetrachloride or Acetaminophen Induced Hepatotoxicity, but Enhances the Cardiac Toxicity of Adriamycin in Rodents

A. G. Abdellatif, H. M. Gargoum, A. A. Debani, M. Bengleil, S. Alshalmani, N. El Zuki, O. El Fitouri

**Abstract**—In this study the administration of 660 mg/kg of the ethanolic extract of the *Alhagigraecorum* (Camel Thorn) to mice, showed a significant decrease in the level of transaminases in animals treated with a combination of CTE plus carbon tetrachloride (CCl<sub>4</sub>) or acetaminophen as compared to animals receiving CCl<sub>4</sub> or acetaminophen alone. Histopathological investigation also confirmed that, camel thorn extract protects liver against damage-induced either by carbon tetrachloride or acetaminophen. On the other hand the cardiac toxicity produced by adriamycin was significantly increased in the presence of the ethanolic extract of camel thorn. Our study suggested that camel thorn can protect the liver against the injury produced by carbon tetrachloride or acetaminophen, with unexpected increase in the cardiac toxicity induced by adriamycin in rodents.

**Keywords**—Acetaminophen, Adriamycin, *Alhagi graecorum*, Carbon tetrachloride.

## I. INTRODUCTION

HEPATOTOXICITY implies chemical-driven liver damage. Liver plays central role in transformation and clearance of most chemicals and is susceptible to the toxicity from these agents. Certain medicinal agents, when taken in overdoses and sometime even when introduced within therapeutic ranges, may injure the organ. Chemicals that cause liver injury are called hepatotoxins [1]. Chemicals produce a wide variety of clinical and pathological hepatic injury. Biochemical markers (i.e. alanine transferase, alkaline phosphatase and bilirubin) are often used to indicate liver damage [2], [3]. Liver damage is further characterized into hepatocellular (predominantly initial Alanine transferase elevation) and cholestatic type (initial alkaline phosphatase rise). However they are not mutually exclusive and mixed type

Awad G. Abdellatif is with the Faculty of Medicine, University of Benghazi, Libya (phone: +218913822896; e-mail: awadag@hotmail.com).

Huda M. Gargoum is with the Faculty of Medicine, University of Benghazi, Libya.

Abdelkader A. Debani is with the Faculty of Medicine, University of Benghazi, Libya (phone: +218913827403; e-mail: Eldebani\_44@yahoo.com).

Mudafara Bengleil is with the Faculty of Pharmacy, University of Benghazi, Libya (phone: +218918015779; e-mail: mudaben@yahoo.co.uk).

Salmin Alshalmani is with the Faculty of Pharmacy, University of Benghazi, Libya (phone: +21891728665; e-mail: Salalshalmani2002@yahoo.com).

N. El Zuki is with the Faculty of Medicine, University of Benghazi, Libya (phone: +218913782347; e-mail: nelzouki\_1999@yahoo.com).

Omran El Fitouri is with the Faculty of Medicine, University of Benghazi, Libya (phone: +218913743226; e-mail: Elfituri1950@yahoo.com).

of injuries are often encountered. Chemicals and drugs such as Carbon tetrachloride (CCl<sub>4</sub>) and acetaminophene catabolised radicals induced lipid peroxidation; damage the membranes of liver cells and organelles, causing the swelling and necrosis of hepatocytes and result to the release of cytosolic enzymes in to the blood [4]. A large number of medicinal plants have been found to offer some hepatoprotection [5]-[9]. Flavonoids and other phenolics of plant origin have been reported to have roles as scavengers and inhibitors of lipid peroxidation [10]-[12].

The aim of this study is to evaluate hepatoprotective activity of camel thorne as one of flavonoid rich plant against the carbon tetrachloride and acetaminophene induced hepatotoxicity and against adriamycin produced cardiac toxicity.

## II. MATERIALS AND METHODS

### A. Plant Collection and Preparation of Extracts

Fresh herb of *Alhagi graecorum* (Camel thorn) was collected from Al Kofra desert-Libya. The plants was washed with tap water and left for drying in the open air place. 300 grams of the plants dried powders was gradually extracted by continuous soxhlation with petroleum ether, chloroform, ethyl acetate and ethanol (500 ml), respectively. All fractions were evaporated to dryness using rotavapour and the extractive value for each fraction was calculated as 8.1, 3.9, 1.5 and 6.0 grams, respectively for each solvent. The different fractions were reconstituted in their extraction solvent to give the required concentration needed in this study.

### B. Experimental Animals

Male Albino mice weighing 25-30g, and Wister rats weighing 180-200g were maintained in the animal house of Faculty of Medicine –University of Benghazi. They were healthy animals and housed in spacious polypropylene cages. The animal room was well ventilated and maintained under standard experimental conditions (Temperature 25±2°C and 12 hours light/dark cycle throughout the experimental period. All the animals were fed with standard pellet diet and water *ad libitum*.

### C. Methods

Male albino mice weighing 25-30g were divided into 6 different groups each of 10 mice. The 1<sup>st</sup> group (control) received normal saline i.p. The 2<sup>nd</sup> and 3<sup>rd</sup> groups received daily i.p dose (660 mg/kg) of CTE for 3 days. Immediately after this treatment, the 3<sup>rd</sup> and 4<sup>th</sup> groups were given a single oral dose of carbon tetrachloride (1 ml/kg in maize oil). The 5<sup>th</sup> and 6<sup>th</sup> groups were pretreated with CTE as 3<sup>rd</sup> and 4<sup>th</sup> groups, and then given a single dose (500mg/kg i.p) of acetaminophen respectively. 24 hours after this treatment the animals will be sacrificed, the blood will be collected and used for the determination of liver transaminases, serum Alanine aminotransferase (ALT) and serum Aspartate aminotransferase (AST) [13]. The liver will be removed, fixed in 10% formaline and used for histopathological investigation.

To investigate the effect of CTE on adriamycin induced cardiac toxicity, male Wistar rats weighting 180-200 g were divided into four groups each consisting of 6 rats. The first group (control) received normal saline. The second group received 660 mg/kg of CTE i.p. daily for 4 days. The third group received a single dose 20 mg/kg of Adriamycin i.p. in the first day. The fourth group received a single dose 20mg/kg of Adriamycin i.p in the first day, followed by 660 mg/kg of CTE i.p daily for 4 days. All animal were fasted for 18 hrs before sacrifice. The collected blood was used to measure cardiac enzymes creatinin phosphate (CPK) and lactate dehydrogenase (LDH), according to methods described by [14],[15].

### D. Statistical Analysis

The experimental results were expressed as the mean  $\pm$  S.E.M. and are accompanied by the number of observations. Data were assessed by one way analysis of variance (ANOVA). If this analysis indicated significant differences among the group means, then each group was compared by rather the LSD, or paired sample test. AP value of 0.05 was considered statistically significant, P value of 0.01 was considered statistically highly significant.

## III. RESULTS

Data in Fig. 1 indicated that the level of both ALT & AST, were significantly reduced ( $P < 0.001$ ) in groups received CTE+ CCl<sub>4</sub> as compared to CCl<sub>4</sub> treated animals. During our study the percentage of death in the acetaminophene treated group was 30% (3 out of 10 mice) whereas in in the group receiving both CTE+acetaminophene it was 10% (i.e. one out of ten).

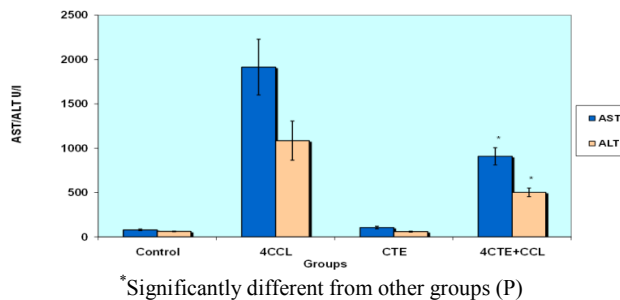


Fig. 1 Effect of CTE (660 mg/kg) on the liver transaminases of mice treated with carbon tetrachloride

Results in Fig. 2 showed that the level of AST and ALT in the group of animals treated with CTE+Acetaminophene were significantly lower ( $P < 0.01$ ) as compared to acetaminophene-treated group with regard to the effect of CTE on the adriamycin-induced cardiac toxicity.

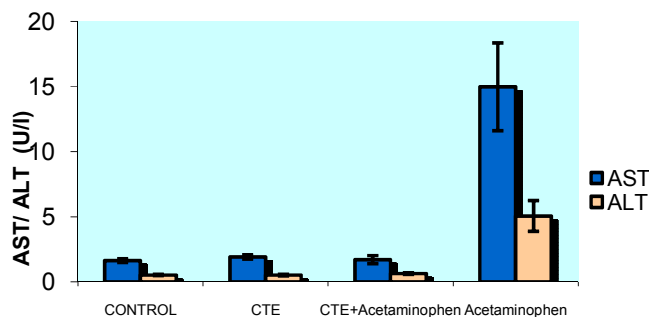


Fig. 2 Effect of CTE (660 mg/kg) on the liver transaminases of mice treated with acetaminophin

Our data presented in Fig. 3 indicated that the level of CPK and LDH were significantly increased respectively ( $P < 0.01$  or  $0.05$ ) in the group of rats treated with the combination of both CTE+adriamycin as compared to the control or other treated groups.

Histopathological studies also provided supportive evidence for the biochemical analysis. As presented in Figs. 4 and 5 the livers of control and CTE treated mice showed normal parenchymal architecture with cord of hepatocytes, portal tract and central veins without any alterations.

Whereas, Fig. 6 indicated a centrilobular necrosis accompanied by fatty changes in the hepatocytes of the livers of the CCl<sub>4</sub> treated mice.

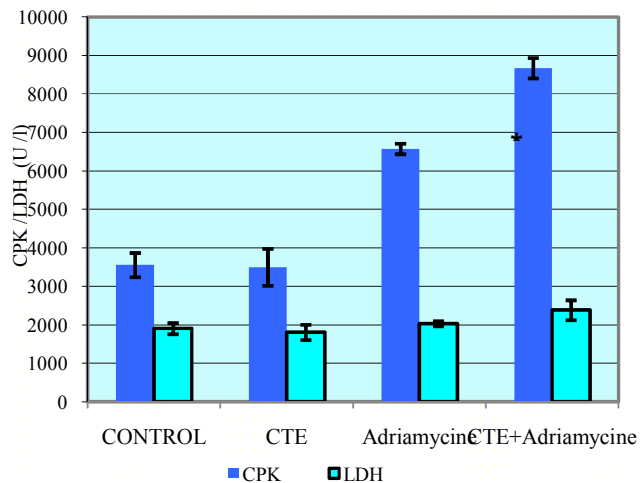


Fig. 3 Effect of CTE (660 mg/kg) on cardiacyzenesofrate treated with adriamycin

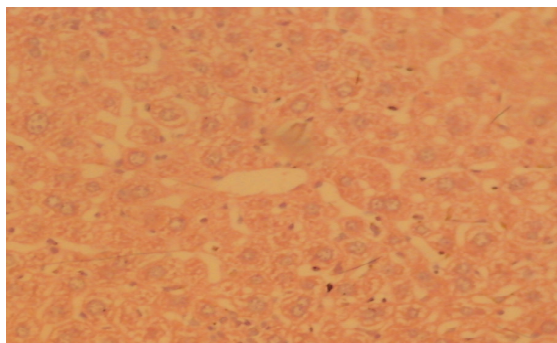


Fig. 4 Light photomicrographs (10 x magnifications) of hematoxylin and eosin–stained sections of liver of normal miceshowed normal parenchymal architecture with cords of hepatocytes, portal tracts and central veins without noticeable alterations

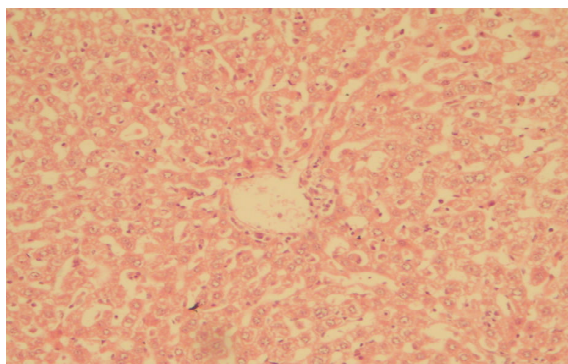


Fig. 5 Light photomicrographs (10 x magnifications) of hematoxylin and eosin–stained sections of liver of mice treated with CTE. Showed normal hepatocytes

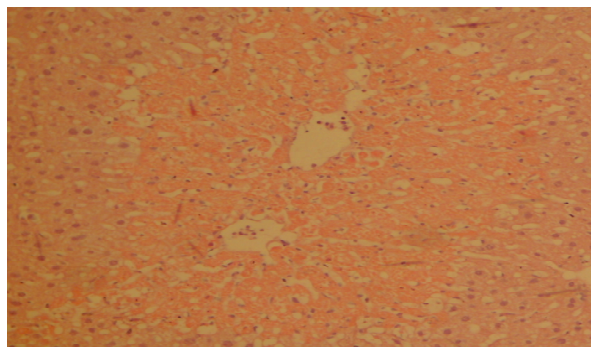


Fig. 6 Light micrographs of hematoxylin and eosin–stained sections of liver of mice treated with CCl<sub>4</sub>(C) showed severe Centrilobular necrosis accompanied by fatty changes were observed in the hepatocytes of the liver

As shown in Fig. 7 the extent of cellular necrosis was lesser in the animal treated with CTE+CCl<sub>4</sub>.

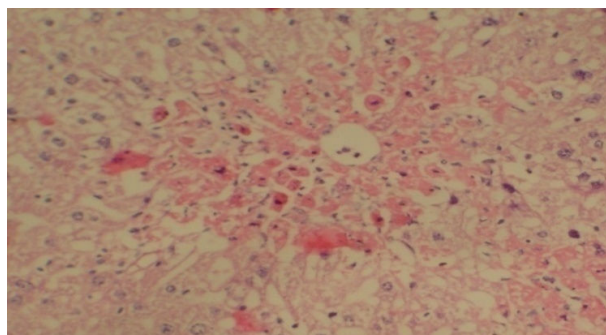


Fig. 7 Light micrographs of hematoxylin and eosin–stained sections of liver of Mice treated with CCl<sub>4</sub> + 660 mg/kg of CTE. Showed less Centrilobular necrosis

As indicated in Fig. 8 a centrilobular necrosis accompanied by fatty changes were observed in the hepatocytes in the livers of mice of the acetaminophen treated groups.

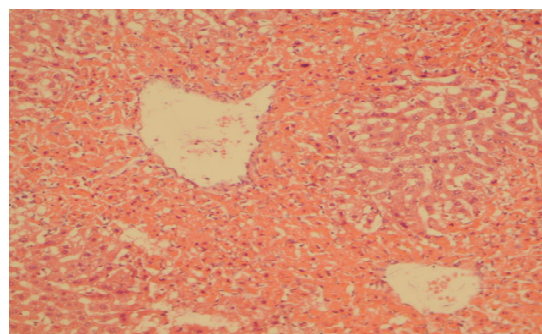


Fig. 8 Light photomicrographs (10 x magnifications) of hematoxylin and eosin–stained sections of liver of from treated with acetaminophen. Centrilobular necrosis accompanied by fatty changes

However, as presented in Fig. 9 the cellular necrosis was almost completely disappearing in the group receiving CTE+ acetaminophen.

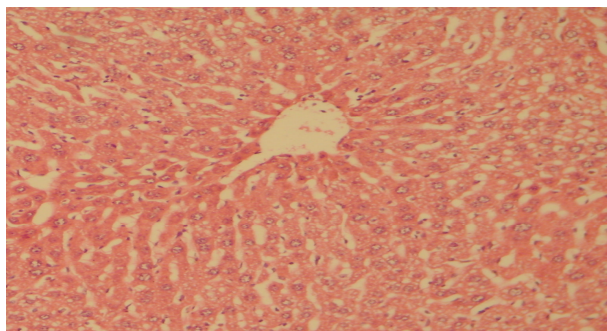


Fig. 9 Light photomicrographs (10 x magnifications) of hematoxylin and eosin-stained sections of liver of mice treated with acetaminophen plus CTE. Showed less centralized necrosis

#### IV. DISCUSSION

It is known that  $\text{CCl}_4$  and acetaminophen (at high doses) are hepatotoxic [16]. It is well established that  $\text{CCl}_4$  is metabolized in the liver to highly reactive trichloromethyl radical and this free radical leads to auto-oxidation of the fatty acids present in the cytoplasmic membrane phospholipids and cause functional and morphological changes in the cell membrane [16]. This is evidenced by an elevation of the serum AST, ALT in  $\text{CCl}_4$  treated rats [17], [18]

In the liver,  $\text{CCl}_4$  is metabolized by the cytochrome P450-dependent monooxygenase systems [19] followed by its conversion to more chemically active radical. This radical initiates the chain reaction of lipid peroxidation, which attacks and destroys polyunsaturated fatty acids [20]-[21]. This resulting in the loss of cellular calcium sequestration and homeostasis, which can contribute heavily to subsequent cell damage.

It was reported that the antioxidant activity or inhibition of the generation of free radicals is important in the protection against the  $\text{CCl}_4$  induced liver lesion [22]. In cases of acetaminophen toxicity, the sulfate and glucuronide pathways become saturated, and more acetaminophen is shunted to the cytochrome P-450 system to produce N-acetyl-p-benzoquinone imine [23], [24] resulting in widespread hepatocyte (liver cell) damage and death, clinically leading to acute hepatic necrosis [25]-[27].

Little is known about the mechanism of hepatoprotective activity of CTE against  $\text{CCl}_4$  or acetaminophen hepatotoxicity. Flavonoids group of naturally occurring benzo-g-derivatives, have been shown to possess several biological properties, many of which may related, partially at least, to their antioxidant and free radical-scavenging ability [28], [29]. In some studies the authors described the anti-oxidant activity of flavonoids from some plants like *Solanum longena* or *Licaniali caniaeflora* [30], [31]. Our results suggest that the CTE has hepatoprotective activity against both  $\text{CCl}_4$  and acetaminophen induced hepatotoxicity. The mechanism of such hepatoprotective activity may be related to the flavonoids of CTE or the CTE may alter the activity of cyp450.

Adriamycin has been postulated to induce cardiotoxicity through redox cycling and reactive oxygen species [32]. This reactive oxygen species (ROS) hypothesis, however, has been

tempered by a series of studies in which treatment with a ROS scavenger failed to prevent cardiac toxicity caused by doxorubicin [33], [34]. Thus, an alternative hypothesis is needed to explain doxorubicin-induced cardiotoxicity [35] suggested that doxorubicin-induced cardiotoxicity is not solely due to redox cycling of doxorubicin. It may be also due to Topoisomerase 2 $\beta$  (Top2 $\beta$ ) as an essential driver of doxorubicin-induced cardiotoxicity. In the presence of Top2 $\beta$ , doxorubicin activates the DNA response and apoptosis pathways and triggers a marked alteration in the transcriptome that selectively affects oxidative phosphorylation and mitochondrial biogenesis in cardiomyocytes.

It has been reported that flavonoid extract from *Camellia sinensis* did not protect the cardiac toxicity of adriamycin. Our results indicated that CTE extract has failed to inhibit the cardiac toxicity of adriamycin [36], and this may be due to interference with the metabolic pathway of adriamycin plus the other mechanism of toxicity of adriamycin that previously mentioned about the role Top2 $\beta$  in adriamycin toxicity.

From this study, we may conclude that CTE protect the liver from the injury produced by oxidative damage of carbon tetrachloride or acetaminophen due to its high contents of phenolic and flavonoids. This study also revealed that significant increase in cardiac toxicity produced by adriamycin in presence of CTE extract and further future study is needed to explain the mechanism behind this action.

#### REFERENCES

- [1] Friedman, Scott E.; Grendell, James H.; McQuaid, Kenneth R. (2003). Current Diagnosis & Treatment in Gastroenterology. New York: Lang Medical Books/McGraw-Hill, p664-679.
- [2] Béchou C (1990). "Criteria of Drug-Induced Liver Disorders. Report of an International Consensus Meeting". J. Hepatol. 11 (2): 272-6.
- [3] Mumoli N, Cei M, & Cosimi A (2006). "Drug-Related Hepatotoxicity". N. Engl. J. Med. 354 (20): 2191-3; author reply 2191-3
- [4] Singh B., Saxena A.K., Chandan B.K., Anand K.K., Suri O.P., Suri K.A. and Satti N.K., Hepatoprotective Activity of Verbenalinone Experimental Liver Damage in Rodents. Fitoterapia, 59(2), 1998, 135-140.
- [5] Sibel K. and Canan K., The Protective Effects of *Achillea* L. Species Native in Turkey against  $\text{H}_2\text{O}_2$  - Induced Oxidative Damage in Human Erythrocytes and Leucocytes. J. Ethnopharmacol., 102, 2005, 221-227.
- [6] Raju R.W., Radhika S.S., Kunal Mahesh T., Kalpana S.P., Sunil S.J., (2008). Screening of Roots of *Baliospermum montanum* for Hepatoprotective Activity against Paracetamol- Induced Liver Damage in Albino Rats. Int. J. Green Pharm. October-December, 220-223.
- [7] Singal A. and Kumar V.I., Effect of Aqueous Suspension of Dried Latex of *Calotropis procera* on Hepatorenal Functions in rat, J. Ethnopharmacol., 122, 2009, 172-174.
- [8] Sisodia S.S. and Bhatnagar M., Hepatoprotective Activity of *Eugenia jambolana* Lam. in Carbon Tetrachloride Treated Rats. Indian J. Pharmacol. 41(1), 2009, 23-27.
- [9] Pushpalatha M and Ananthi T (2012) Protective Effect of *Solanum pubescens* LINN on  $\text{CCl}_4$  Induced Hepatotoxicity in Albino Rats. Mintage Journal of Pharmaceutical and Medicinal Science, Vol 1, Issue 1, page 11-13.
- [10] Formica J.V. and Regelson W., Review of the Biology of Quercetin and Related Bioflavonoids. Food Chem. Toxicol., 33 (12), 1995, 1061-1080.
- [11] Rice-Evans, C., Miller N. and Paganga G., Antioxidant Properties of Phenolic Compounds. Trends in Plant Sci., 2 (4), 1997, 154-159.
- [12] Xiao-feng Jin, Jie Qian, and Yan-hua Lu (2011). The Role of Hepatoprotective Effect of a Flavonoid-Rich Extract of *Salvia plebeia* R.Br. on Carbon Tetrachloride Induced Acute Hepatic Injury in Mice J. Med. Plant. Res. Vol. 5(9), pp. 1558-1563
- [13] Bergmeyer HU, Herder M, and Rej R. (1986) Approved Recommendation 1985) on IFCC Method for Measurement of Catalytic

- Concentration of Enzyme. Part 2. (IFCC Method for Aspartate Aminotransferase). *J Clin Chem Biochem*;24:49
- [14] Szasz G, Gruber W, andbernt E (1976) Creatine Kinase in Serum: 1. Determination of Optimum Reaction Conditions. *Clin Chem*. 22(5):650-6
- [15] Wacker, W.E.C., Ulmer, D.D., and Valu D.D. (1956), Metalloenzymes and Myocardial Infarction. II Malic and Lactic Dehydrogenase Activities and Zinc Concentrations in Serum. *New Engl. J. Med.*, 225: 449-454
- [16] Zidek N, Hellmann J, Kramer PJ, & Hewitt PG (2007). Acute Hepatotoxicity: A Predictive Model Based On Focused Illumina Microarrays. *Toxicol Sci. Sep*; 99(1):289-302.
- [17] Bhattacharyya D, Mukherjee R, Pandit S, Das N, and Sur TK. (2003)a. Hepatoprotective Effect of Himoliv, a Polyherbal Formulation. *Indian J Pharmacol*;47:435-40.
- [18] Bhattacharyya D, Mukherjee R, Pandit S, Das N, and Sur TK. (2003)b. Prevention of Carbon Tetrachloride Induced Hepatotoxicity in Rat by Himoliv, a Polyherbal Formulation. *Indian J Pharmacol*;35:183-5.
- [19] Noguchi T, Fong KL, Lai EK, Alexander SS, King MM, Olson L, Poyer JL, & Mccay PB. (1982). Specificity of Aphenobarbital-Induced Cytochrome P450 for Metabolism of Carbontetrachlorideto the Trichloromethyl Radical. *Biochem Pharmacol.*;31: (82) 440-443.
- [20] Slater, T.F., K.H. Cheeseman and Ingold K.U. (1985). Carbon Tetrachloride Toxicity as a Model for Studying Free-Radical Mediated Liver Injury. *Philosophical Transactions of the Royal Society of London-Series B: Biol. Sci.* 311(1152): 633-645
- [21] Clawson, G.A. (1989) Mechanisms of Carbon Tetrachloride Hepatotoxicity. *Pathol. Immunopath. Res.* 8(2): 104-112.
- [22] Weber, L. W., Boll, M., and Stampfl, A. (2003). Hepatotoxicity and Mechanism of Action of Haloalkanes: Carbon Tetrachloride as a Toxicological Model. *Crit. Rev. Toxicol.* 33, 105–136.
- [23] Nelson, S.D. (1990). Molecular Mechanisms of Hepatotoxicity Caused by Acetaminophen. *Semin. Liver Dis.* 10(4): 267-278
- [24] Umack B H (2002) Acetaminophen Hepatotoxicity: The First 35 Year. *Clinical Toxicology* 40(1), 3-20.
- [25] Miller, M.G. and Jollow D.J (1987). Relationship between Sulfotransferase Activity and Susceptibility to Acetaminophen-Induced Liver Necrosis in the Hamster. *Drug Metab. Dispos.* 15(2): 143-150.
- [26] Potter, D.W. and J.A. Hinson (1989). Acetaminophen Peroxidation Reactions. *Drug Metab. Rev.* 20(2-4): 341-358.
- [27] Moffit JS, Aleksunes LM, Kardas MJ, Slitt AL, Klaassen CD, & Manautou (2007). JE Role of NAD (P) H: Quinoneoxidoreductase I in Clofibrate-Mediated Hepatoprotection from Acetaminophen. *Toxicology*. Feb 12;230(2-3):197-206
- [28] Obak J, & Gryglewski R. J. (1988). Flavonoids as Scavengers of Superoxide Anions. *Biochem. Pharmacol.* 37:837-841.
- [29] Chen Y, Zheng R, Jia Z, & Ju Y, (1990) Flavonoids as Superoxide Scavengers and Antioxidants. *Free Radical. Biol med* 9:19-21
- [30] Sudheesh S, Sandhya C, Asha S, & Vijayalakshmi N.R (1999), Anti-Oxidant Activity of Flavonoids from *Solanum melongena*. *Phytotherapy Research.* 13:393-396.
- [31] Alessandra B, Chandra S, Matteo P, Ivano M, Jeannette M. (2002) Anti-Oxidant Activity of Flavonoids from *Licanialicaniaeflora*. *Journal of Ethnopharmacology.* 79:379-381
- [32] Singal, P.K. & Iliskovic, N. Doxorubicin-Induced Cardiomyopathy *N. Engl. J. Med.* 339, 900–905 (1998).
- [33] Myers, C. Bonow R, Palmeri S, Jenkins J, Corden B, Locker G, Doroshow J, and Epstein S. (1983). A Randomized Controlled Trial Assessing the Prevention of Doxorubicin Cardiomyopathy by N-Acetylcysteine. *Semin Oncol.* 10, 53–55 (1983).
- [34] Martin E, Thougard AV, Grauslund M, Jensen PB, Bjorkling F, Hasinoff BB, (2009). Evaluation of the Topoisomerase II-Inactive Bisdioxopiperazine CRF-161 as a Protectant against Doxorubicin-Induced Cardiomyopathy. *Toxicology* 255(1-2):72-9.
- [35] Sui Z, Xiaobing L, Tasneem B, Long-Sheng L, Yi L, Leroy F & Edward T (2012). Identification of the Molecular Basis of Doxorubicin-Induced Cardiotoxicity. *Nature Medicine.* Vo, 18, No., 11:1639-1645
- [36] Maira S Oliveira, Marcos B Melo, Juliana L Carvalho, Isabela M Melo, Mario SL Lavor, Dawidson A Gomes, Alfredo M de Goes, and Marilia M Melo (2013) Doxorubicin Cardiotoxicity and Cardiac Function Improvement after Stem Cell Therapy Diagnosed by Strain Echocardiography. *J. Cancer Sci Ther.*; 5(2): 052–057.