

# Automated Optic Disc Detection in Retinal Images of Patients with Diabetic Retinopathy and Risk of Macular Edema

Arturo Aquino, Manuel Emilio Gegúndez, Diego Marín

**Abstract**—In this paper, a new automated methodology to detect the optic disc (OD) automatically in retinal images from patients with risk of being affected by Diabetic Retinopathy (DR) and Macular Edema (ME) is presented. The detection procedure comprises two independent methodologies. On one hand, a location methodology obtains a pixel that belongs to the OD using image contrast analysis and structure filtering techniques and, on the other hand, a boundary segmentation methodology estimates a circular approximation of the OD boundary by applying mathematical morphology, edge detection techniques and the Circular Hough Transform. The methodologies were tested on a set of 1200 images composed of 229 retinographies from patients affected by DR with risk of ME, 431 with DR and no risk of ME and 540 images of healthy retinas. The location methodology obtained 98.83% success rate, whereas the OD boundary segmentation methodology obtained good circular OD boundary approximation in 94.58% of cases. The average computational time measured over the total set was 1.67 seconds for OD location and 5.78 seconds for OD boundary segmentation.

**Keywords**—Diabetic retinopathy, macular edema, optic disc, automated detection, automated segmentation.

## I. INTRODUCTION

**D**IABETIC Retinopathy (DR) is a chronic disease, caused by complications of Diabetes Mellitus, which nowadays constitutes the primary cause of blindness in people of working age in the developed world [1], [2]. Laser photocoagulation can slow down the progression to blindness if DR is detected in its early stages. However, this is not an easy task because DR patients do not perceive symptoms until visual loss develops and this happens in the later stages of the disease, when treatment is less effective. To ensure that treatment is received in time, diabetic patients need to undergo a yearly eye fundus examination [3]. However, the growing incidence of diabetes increases the number of patients and as a consequence the number of images that need to be reviewed by physicians. In addition, the high cost of examinations and the lack of specialists prevent many patients from receiving effective treatment.

Due to the reasons previously mentioned, the advantages that an expert system for automated diagnosis of DR in the early stages would provide have been studied and positively assessed by specialists [4] and have inspired much research in that direction [5].

A. Aquino and D. Marín are with the Department of Electronic, Computer Science and Automatic Engineering, "La Rábida" Polytechnic School, University of Huelva, Spain (e-mail: {arturo.aquino, diego.marin}@diesia.uhu.es).

M.E. Gegúndez is with the Department of Mathematics, "La Rábida" Polytechnic School, University of Huelva, Spain (e-mail: gegundez@uhu.es).

OD segmentation is an essential step in developing automated diagnosis expert systems for DR. It is a key pre-processing component in many algorithms designed to identify other fundus features automatically. The relatively constant distance between the OD and the fovea can be used to help estimate the location of the latter [6]. On the other hand, to segment the vascular tree, an initial seed point is required using vessel tracking methods. Pixels of vessels within the OD or in its vicinity have been used for this [7], [8]. Furthermore, OD detection is important for automatic diagnosis of some diseases caused by DR. The OD region is removed before identifying retinal exudates [9], which are used to assess and grade risk of Macular Edema (ME).

In addition, OD segmentation is also relevant for automated diagnosis of other ophthalmic pathologies. One of them and maybe the most relevant is Glaucoma. It is the second most common cause of blindness worldwide [10]. This disease is identified by means of recognition of the changes in shape, color or depth that it produces in the OD [11]. Thus, its segmentation and analysis can be used to detect automatically Glaucoma evidences.

This paper presents an automated OD detection system. The detection is performed by applying two independent methodologies to digital fundus images: one of them to locate a pixel in the region and the other one to obtain a circular approximation of its boundary. The work forms part of the Project *Expert system for early automated detection of DR by analysis of digital retinal images* (<http://www.uhu.es/retinopathy>), funded by the Health Ministry of the Andalusian Regional Government (Spain) as part of a Comprehensive Plan for the Prevention of the Diabetes launched by this Administration in 2003 (*Consejería de Salud de la Junta de Andalucía, Plan Integral de Diabetes de Andalucía*, online available at <http://www.juntadeandalucia.es>).

## II. MATERIAL

The set of images used to test the developed methodologies is the publicly available MESSIDOR database, kindly provided by the Messidor program partners (see <http://messidor.crihan.fr>). It contains 1200 color eye fundus images of the posterior pole acquired by the Hôpital Lariboisière Paris, the Faculté de Médecine St. Etienne and the LaTIM - CHU de Brest (France). 800 of these images were captured with pupil dilation (one drop of Tropicamide at 10%) and 400 without dilation, using a Topcon TRC NW6

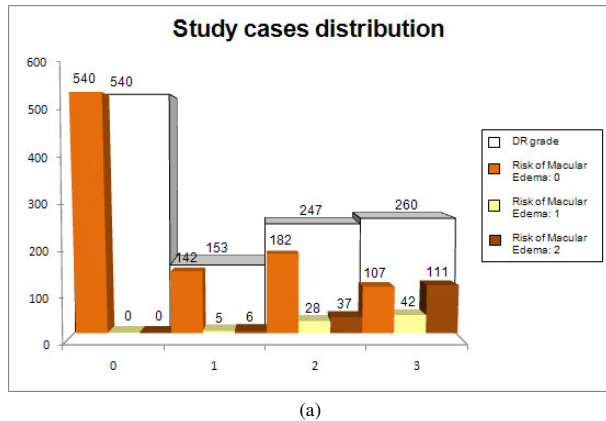


Fig. 1. Distribution of the study cases grouped by grade of DR and risk of ME.

non-mydratiac retinograph with a 45° FOV. The images are 1440x960, 2240x1488 or 2304x1536 pixels in size and 8 bits per color plane.

DR grade and risk of ME diagnoses were provided by medical experts for each image according to the following gradings (see Figure 1 for description of study case distribution):

- DR grade:
  - 0 (Normal): ( $\mu A = 0$ ) and ( $H = 0$ ).
  - 1: ( $0 < \mu A \leq 5$ ) and ( $H = 0$ ).
  - 2: ( $(5 < \mu A < 15)$  or ( $0 < H < 5$ )) and ( $NV = 0$ ).
  - 3: ( $\mu A \geq 15$ ) or ( $H \geq 5$ ) OR ( $NV = 1$ ).
- $\mu A$ : Number of microaneurysms.
- $H$ : Number of hemorrhages.
- $NV = 1$ : Neovascularization.
- $NV = 0$ : No neovascularization.
- Risk of Macular Edema:
  - 0 (No risk): No visible hard exudates.
  - 1: Shortest distance between macula and hard exudates  $>$  one papilla diameter.
  - 2: Shortest distance between macula and hard exudates  $\leq$  one papilla diameter.

These two simplified gradings were produced by experts from the recommendations provided by: Alfediam (French association for the study of diabetes and metabolic diseases) [12], [13], ETDRS (Early Treatment Diabetic Retinopathy Study). Grading recommendations used in the US [14], Diabetic Retinopathy Screening Services in Scotland: Recommendations for Implementation (online available at <http://www.scotland.gov.uk/Publications/2003/07/17638/23088>).

### III. METHODS

#### A. Methodology for Automated Location of the OD

The location methodology obtains a pixel (called Optic Disc Pixel, ODP) located within the OD. It comprises three independent detection methods. These three methods work on the green channel of the RGB color space, as this is the one that provides the best contrast [15]. A description of them,

as well as an example of their application to a low-contrast fundus image (Figure 2), is presented as follows:

- Maximum difference method: a maximum and a minimum filter are applied and the difference between the resultant maximum and minimum images is calculated. The pixel with the highest value in this difference image is the returned pixel (Figure 2, image A-1).
- Maximum variance method: The pixel selected by this method is the maximum statistical variance pixel located in a bright region (Figure 2, image A-2).
- Low-pass filter method: This method returns the highest grey level pixel in the image obtained by the application of a low pass filter (Figure 2, image A-3).

Therefore, each method obtains its own OD pixel candidate and the final ODP is selected in terms of neighborhood criteria. In Figure 2, image A-4, can be checked that the location of the ODP is the average of the locations of the pixels returned by the three methods, as they are close. If any OD pixel were far from the other two, it would be discarded and finally, if the three OD pixels obtained were separated, the ODP would be selected as the OD pixel obtained by the maximum variance method, as tests made revealed that it is the surest one.

#### B. Methodology for Automated Segmentation of the OD Boundary

The OD boundary segmentation methodology obtains a circular approximation of the OD boundary. It is performed on a RGB sub-image of the original retinography extracted using a pixel located within the OD as the central point. The coordinates of this pixel have to be provided, by means of any OD location methodology, such as those presented here or even manually if desired. The following operations are applied in sequential order, as illustrated in Figure 3 (the purpose of each operation is emphasized in *italics*) on the green and the red fields of the sub-image (Figure 3, image A):

- A modified version of the classical morphological dilation operation [16] and a mean filter for smoothing are employed to eliminate blood vessels (Figure 3, image B).
- The Prewitt operator [17] is used to obtain a gradient magnitude image (Figure 3, image C).
- Automatic Otsu thresholding method [18] is performed to generate a first binary image (Figure 3, image D).
- Morphological erosion [19] is applied to reduce noise and obtain a cleaner binary image (Figure 3, image E).
- Finally, the Circular Hough Transform [20] is used to calculate the circular approximation of the optic disc (Figure 3, image F).

In this way, two OD approximations are obtained (one from the green channel and the other from the red channel). The definitive circular OD boundary approximation is the one that has obtained the highest score in the Circular Hough Transform algorithm.

### IV. RESULTS

The two methodologies described were tested on the set of 1200 images referred to. The resulting images were checked

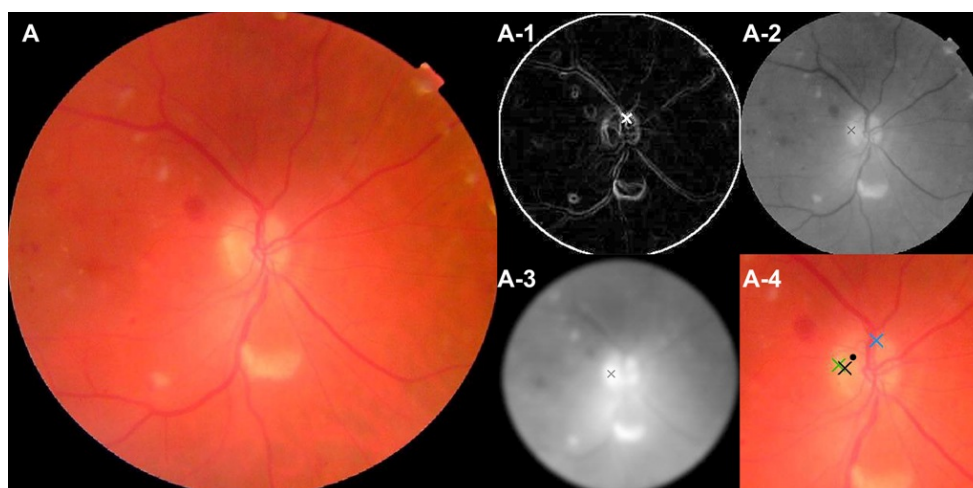


Fig. 2. Determination of the ODP: (A) Original retinography, (A-1) OD pixel returned by the maximum difference method, (A-2) OD pixel returned by the maximum variance method, (A-3) OD pixel returned by the low-pass filter method, (A-4) the three pixels are close, so the location of the final ODP (the black dot) is the average of their locations.

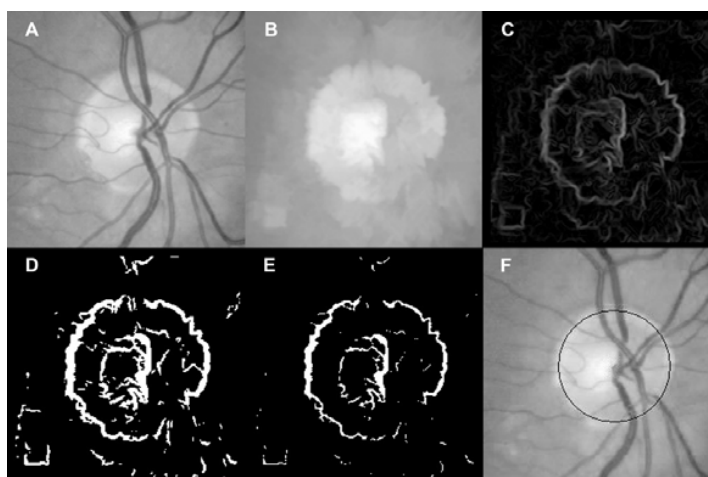


Fig. 3. By way of an example, this figure illustrates the process for calculation of the circular OD boundary approximation performed on the green channel: (A) sub-image extracted from the green channel, (B) vessel elimination and smoothing, (C) gradient magnitude image, (D) binary image, (E) cleaner version of the binary image, (F) circular OD boundary approximation.

by four ophthalmologists from the Andalusian Health Service, providing a failure-success result to every image. With regard to the location methodology, a result was denoted a “success” when the pixel found was located within the OD and otherwise, a “failure”. On the other hand, a resulting image given by the boundary segmentation methodology was labeled a “success” when the circular OD boundary approximation appropriately fitted its boundary and a “failure”, when the approximation was not representative of its contour (see examples in Figure 4).

The location methodology successfully found the OD in 1186 cases out of the whole set of 1200 analyzed images, which means a 98.83% success rate. Classifying the images by retinas affected by DR or not, achieved success rates of 98.33% and 99.44% respectively. As for images from patients affected by DR, the success rate was 96.51% for images

diagnosed with risk of ME and 99.3% for those images without this risk.

With regard to the segmentation methodology, a good OD boundary approximation was obtained in 94.58% of cases, which means segmentation success in 1135 out of 1200 images. For retinas affected by DR, the success rate was 94.34% whereas, for healthy retinas cases, the segmentation was appropriate in 95.93%. Finally, for patients affected by DR and with risk of ME, a 92.58% success rate was achieved, and for images diagnosed as affected with DR with no risk of ME this figure was 93.97%.

The experiments were obtained using a mid-range PC with an Intel Core2Duo CPU at 2.13 GHz and 2 GB of RAM. The average computational time obtained for OD location was 1.67 seconds with a standard deviation of 0.14, and for OD boundary segmentation it was 5.78 seconds with a

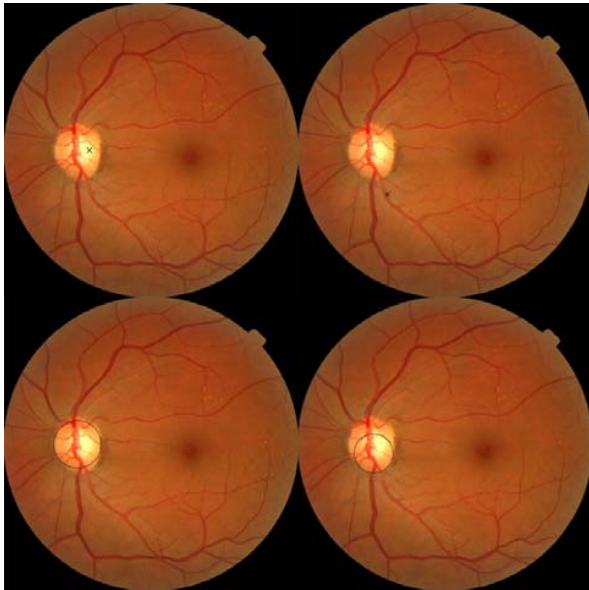


Fig. 4. The top-left image shows an OD location methodology result that would be labeled a "success" and on its right can be found an example of a "failure" case. As for OD boundary approximation, the bottom-left image corresponds to a case of a "success" result and the image on its right illustrates a "failure" result.

standard deviation of 0.3. These results are independent of image resolution as images are scaled down to 300x300 for OD location, whereas they are resized to 640x640 pixels for OD boundary segmentation.

A detailed report of the results obtained is shown in Tables I and II, as well as some application examples in Figures 5 (OD location) and 6 (circular OD boundary approximation). The complete experiment can be found at <http://www.uhu.es/retinopathy> (Results section).

## V. DISCUSSION AND CONCLUSION

Two methodologies for automatic OD exploration have been presented in this paper: one to locate the OD and another one to segment its boundary. This work forms part of a project whose purpose is to develop an automated system for the early detection of DR for the Andalusian Health System. Andalusia has a population of 8200000 inhabitants with an estimated Diabetes incidence of more than 500000 cases. The ultimate goal is to provide an automated support system for the diagnosis of DR. It could be used by non-experts in doubtful and difficult-to-diagnose cases (those not obvious to non-expert eyes), to discriminate and filtrate with greater confidence who requires referral to an ophthalmologist for further investigation and treatment and who does not, thereby reducing the workload of these specialists. With a figure of more than 500000 potential patients, the future system will have to be robust, provide high accuracy rates, and be fast to bear the high workload, which it will be submitted to, efficiently. Furthermore, it will have to be able to analyze low quality images, as the use of uncompressed images several Megabytes in size would not be acceptable due to the huge storage requirements that this

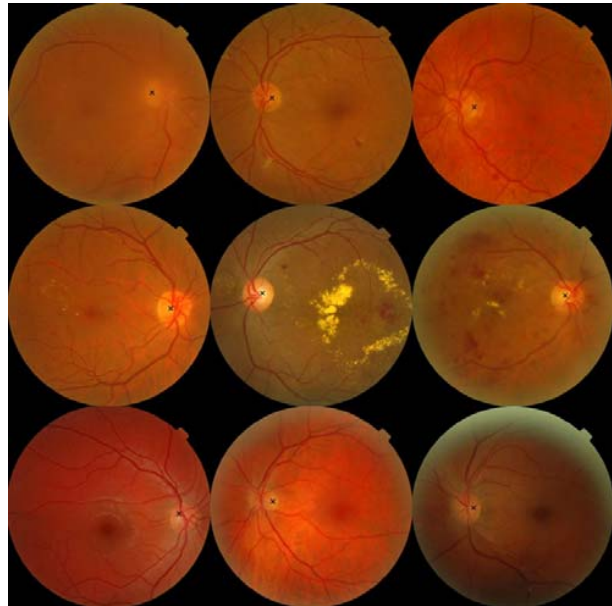


Fig. 5. Examples of results obtained with the OD location methodology. The first row shows three retinographies from patients with DR and no risk of ME, the second is composed of three retinographies from patients affected by DR and with risk of ME and the last three images are from healthy retinas.

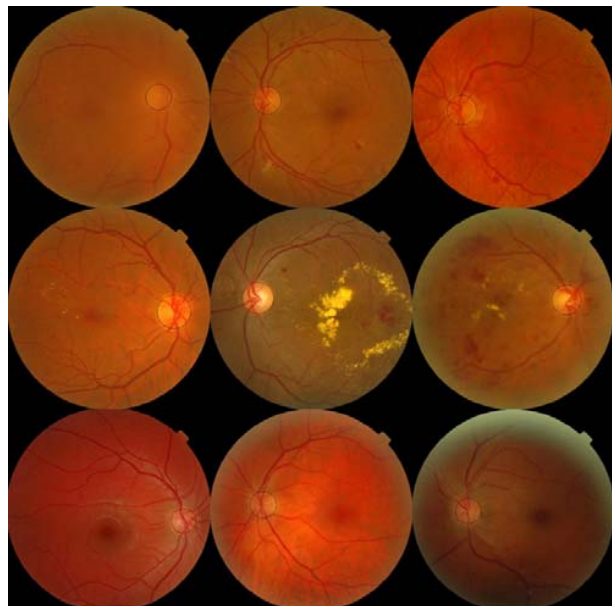


Fig. 6. Examples of results obtained with the OD boundary approximation methodology applied to the same images described in Figure 5.

would involve and, even more importantly, the waste of time exchanging large images of this kind over the internet would mean. The methodologies proposed are planned to be part of this system under development and have been designed to satisfy these features.

The OD location methodology is based on three different, very reliable methods that provide three pixels pertaining to the OD with high probability. This allows the accuracy and

TABLE I  
RESULTS OF THE LOCATION AND SEGMENTATION METHODOLOGIES

DR Grade - Risk of ME	Cases	Location Methodology	Segmentation Methodology
0-0	540	99.44%	95.93%
1-0	142	99.30%	93.66%
1-1	5	100%	100%
1-2	6	100%	100%
2-0	182	100%	95.6%
2-1	28	100%	89.29%
2-2	37	100%	94.59%
3-0	107	98.13%	91.59%
3-1	42	100%	85.71%
3-2	111	92.79%	94.59%
<b>Total</b>	1200	98.83%	94.58%

robustness of locating the OD to be increased. A sign of this is the fact that the OD was found correctly in 1186 images out of the 1200, which means a success rate of 98.83%. In addition to this, the developed methodology has been checked to be independent and stable regardless of image resolution, making it possible to work with any image at a resolution of 300x300. This provides a drastic reduction in computational time, with the OD being located in an average time of 1.67 seconds with a standard deviation of 0.14, running on a PC with an Intel Core2Duo CPU at 2.13 GHz and 2 GB of RAM at any image resolution, which means that it is an almost instantaneous process in any situation using only a cheap, current mid-range PC. For comparison with other methods proposed for locating the OD automatically, a present-day literature revision can be found in Youssif *et al.* [21]. In [21] it can be checked that, although Youssif *et al.* and others reviewed obtained good success rates, the results offered were obtained on small databases (less than 100 images), an aspect that makes it difficult to obtain definitive conclusions. On the other hand, in terms of the computational time of other methods, it should be pointed out that this methodology provides a faster solution than others proposed before. For instance, Osareh *et al.* [22] and Youssif *et al.* [21] proposed OD location methods with implementation of the former taking a computational time of around 10 minutes and the latter around 3.5 minutes.

The OD boundary approximation methodology, in contrast to other methods that attempt to extract the exact contour of the OD, obtains a circular approximation to its boundary. In this way, good contrast is not needed all around the OD, as the Circular Hough Transform needs only a portion of its contour to reconstruct a fitting circumference. In [23], Lowell *et al.* presented an OD segmentation method based on a deformable contour model to extract the OD boundary. They obtained excellent-good performance in 73% of cases and 27% of fair-poor fit, testing on a dataset composed of 100 images. The results obtained with the proposed methodology, successful segmentation in 94.58% of cases, were achieved during testing on 1200 cases with no exclusion criteria applied, so the failure cases includes images with cataracts and no discernable OD. Another important point is that other published methods for OD segmentation have frequently not taken performance

TABLE II  
RESULTS OF THE LOCATION AND SEGMENTATION METHODOLOGIES  
DETAILED PER OPHTHALMIC CENTER.

Hôpital Lariboisière Paris (images acquired with pupil dilation)			
DR Grade - Risk of ME	Cases	Location Methodology	Segmentation Methodology
0-0	151	100%	96.03%
1-0	26	100%	96.15%
1-1	2	100%	100%
1-2	2	100%	100%
2-0	49	100%	89.80%
2-1	13	100%	100%
2-2	8	100%	100%
3-0	48	95.83%	95.83%
3-1	26	100%	88.46%
3-2	75	89%	100%
<b>Total</b>	400	97.50%	95.75%

Faculté de Médecine St. Etienne (images acquired with pupil dilation)			
0-0	186	98.39%	93.55%
1-0	68	98.53%	92.65%
1-1	1	100%	100%
1-2	2	100%	100%
2-0	62	100%	96.77%
2-1	9	100%	88.89%
2-2	20	100%	95%
3-0	21	100%	90.48%
3-1	7	100%	85.71%
3-2	24	100%	79.17%
<b>Total</b>	400	99%	92.75%

LaTIM - CHU de Brest (images acquired without pupil dilation)			
0-0	203	100%	98.03%
1-0	48	100%	93.75%
1-1	2	100%	100%
1-2	2	100%	100%
2-0	71	100%	98.59%
2-1	6	100%	66.67%
2-2	9	100%	88.89%
3-0	38	100%	86.84%
3-1	9	100%	77.78%
3-2	12	100%	91.67%
<b>Total</b>	400	100%	95.25%

efficiency especially into account (efficiency measures are usually not provided) and they tend to be computationally complex. Implementation of the presented methodology takes an average time of 5.78 seconds with a standard deviation of 0.3 for the complete segmentation process, regardless of image resolution, as images are scaled to 640x640 pixels in size.

With regard to image format, in order to comply with the type of images in use at present by the Andalusian Health Service, all images were JPEG compressed at a ratio of 1:35. Although the compression of digital images makes automated detection of parts of interest in the retina difficult (Stellingwerf *et al.* [24]), and compression ratios higher than 1:20 have been

denoted as not suitable for this purpose (Basu *et al.* [25]), the methodology demonstrates excellent OD detection and segmentation behavior on 1:35 JPEG-compressed images.

Although the current approach focuses on locating and detecting the OD, the main conclusion is that the work presented represents a step forward in developing automatic diagnosis systems for DR, Macular Edema and other ophthalmic diseases such as Glaucoma. The reliability, robustness and efficiency obtained, make the tools implemented suitable for use as part of the system for automatic early detection of DR under investigation and development.

#### ACKNOWLEDGMENT

This work was carried out as part of the *Expert System for Early Automated Detection of DR by Analysis of Digital Retinal Images* Project, supported and funded by the Health Ministry of the Andalusian Regional Government (Spain). The authors would like to thank the Messidor program partners for facilitating the set of images used in this study.

#### REFERENCES

- [1] H. R. Taylor and J. E. Keefe, "World blindness: a 21st century perspective," *Br. J. Ophthalmol.*, vol. 85, pp. 261-266, 2001.
- [2] S. Wild, G. Roglic, A. Green, R. Sicree, and H. King, "Global prevalence of diabetes: estimates for the year 2000 and projections for 2030," *Diabetes Care*, vol. 27, pp. 1047-1053, 2004.
- [3] D. S. Fong, L. Aiello, T. W. Gardner, G. L. King, G. Blankenship, J. D. Cavallerano, F. L. Ferris, and R. Klein, "Diabetic retinopathy," *Diabetes Care*, vol. 26, pp. 226-229, 2003.
- [4] A. Singalavanija, J. Supokavej, P. Bamroongsuk, C. Sinthanayothin, S. Phoojaruenchanachai, and V. Kongbunkiat, "Feasibility study on computer-aided screening for diabetic retinopathy," *Jpn. J. Ophthalmol.*, vol. 50, pp. 361-366, 2006.
- [5] N. Patton, T. M. Aslam, T. MacGillivray, I. J. Deary, B. Dhillon, R. H. Eikelboom, K. Yogesan, and I. J. Constable, "Retinal image analysis: concepts, applications and potential," *Prog. Retin. Eye Res.*, vol. 25, pp. 99-127, 2006.
- [6] C. Sinthanayothin, J. F. Boyce, H. L. Cook, and T. Williamson, "Automated localisation of the optic disc, fovea, and retinal blood vessels from digital colour fundus images," *Br. J. Ophthalmol.*, vol. 83, pp. 902-910, 1999.
- [7] H. Li and O. Chutatape, "Automatic location of optic disc in retinal images," in *Proc. IEEE Int. Conf. on Image Proc.*, 2001, pp. 837-840.
- [8] L. Gagnon, M. Lalonde, M. Beaulieu, and M. -C. Boucher, "Procedure to detect anatomical structures in optical fundus images," in *Proc. Conf. Med. Imag. 2001: Image Process.*, San Diego, 2001, pp. 1218-1225.
- [9] A. Osareh, M. Mirmehdi, B. Thomas, and R. Markham, "Automated identification of diabetic retinal exudates in digital colour images," *Br. J. Ophthalmol.*, vol. 87, pp. 1220-1223, 2003.
- [10] H. A. Quigley and A. T. Broman, "The number of people with glaucoma worldwide in 2010 and 2020," *Br. J. Ophthalmol.*, vol. 90, pp. 262-267, 2006.
- [11] H. Li and O. Chutatape, "A model-based approach for automated feature extraction in fundus images," in *9th IEEE Int. Conf. Computer Vision (ICCV'03)*, 2003, vol. 1, pp. 394-399.
- [12] P. Massin, K. Angioi-Duprez, F. Bacin, B. Cathelineau, G. Cathelineau, G. Chaîne, G. Coscas, J. Flament, J. Sahel, P. Turut, P. J. Guillausseau, and A. Gaudric, "Recommandations de l'ALFEDIAM pour le dépistage et la surveillance de la rétinopathie diabétique," *Diabetes Metab.*, vol. 22, pp. 203-209, 1996.
- [13] P. Massin, K. Angioi-Duprez, F. Bacin, B. Cathelineau, G. Cathelineau, G. Chaîne, G. Coscas, J. Flament, J. Sahel, P. Turut, P. J. Guillausseau, and A. Gaudric, "Recommandations de l'ALFEDIAM pour le dépistage et la surveillance de la rétinopathie diabétique," *J. Fr. Ophthalmol.*, vol. 20, pp. 302-310, 1997.
- [14] Early Treatment Diabetic Retinopathy Study Research Group, "Grading diabetic retinopathy from stereoscopic color fundus photographs: an extension of the Modified Airlie House classification: ETDRS report number 10," *Ophthalmology*, vol. 98, pp. 786-806, 1991.
- [15] T. Walter and J. C. Klein, "Automatic analysis of color fundus photographs and its application to the diagnosis of diabetic retinopathy," in *Handbook of Biomedical Image Analysis*, vol. 2, pp. 315-368, 2005.
- [16] R. C. Gonzalez and R. E. Woods, "Morphological Image Processing," in *Digital Image Processing*, 2nd ed. Prentice-Hall, pp. 577-581, 2002.
- [17] R. C. Gonzalez and R. E. Woods, "Image Segmentation," in *Digital Image Processing*, 2nd ed. Prentice-Hall, pp. 577-581, 2002.
- [18] N. Otsu, "A threshold selection method from gray-scale histogram," *IEEE Trans. Syst. Man Cybern.*, vol. 8, pp. 62-66, 1978.
- [19] R. C. Gonzalez and R. E. Woods, "Morphological Image Processing," in *Digital Image Processing*, 2nd ed. Prentice-Hall, pp. 525, 2002.
- [20] P. V.C. Hough, *Methods and Means for Recognizing Complex Patterns*, US Patent 3 069 654, Dec. 1962.
- [21] A. A.H.A.R. Youssif, A. Z. Ghalwash, and A. R. Ghoneim, "Optic disc detection from normalized digital fundus images by means of a vessels' direction matched filter," *IEEE Trans. Med. Imag.*, vol. 27, pp. 11-18, 2008.
- [22] A. Osareh, M. Mirmehdi, B. Thomas, and R. Markham, "Comparison of colour spaces for optic disc localisation in retinal images," in *16th Int. Conf. Pattern Recognition*, 2002, pp. 743-746.
- [23] J. Lowell, A. Hunter, D. Steel, A. Basu, R. Ryder, E. Fletcher, and L. Kennedy, "Optic nerve head segmentation," *IEEE Trans. Med. Imag.*, vol. 23, no. 2, pp. 256-264, 2004.
- [24] C. Stellingwerf, P. Hardus, and J. Hooymans, "Assessing diabetic retinopathy using two-field digital photography and the influence of JPEG-compression," *Doc. Ophthalmol.*, vol. 108, pp. 203-209, 2004.
- [25] A. Basu, A. D. Kamal, W. Illahi, M. Khan, P. Stavrou, and R. E. J. Ryder, "Is digital image compression acceptable within diabetic retinopathy screening?," *Diabet. Med.*, vol. 20, pp. 766-771, 2003.



**Arturo Aquino** Engineer in Computer Sciences from the High Technical School in Computer Sciences of the University of Sevilla (Spain), in 2007, received the M.S. Degree in Computer Engineering and Networks from the University of Granada (Spain). Since 2007 he has been pursuing the Ph.D. Degree student at the University of Huelva (Spain).



**Manuel Emilio Gegúndez** received the B.S. Degree in Mathematics from the University of Sevilla (Spain), in 1992, and the Ph.D. Degree in Mathematics from the University of Sevilla in 1996. He is currently an Associate Professor at the Department of Mathematics of the University of Huelva (Spain). His current research interests include Computer Vision, Identification and Knowledge Extraction.



**Diego Marín** received the B.S. Degree in Physics from the University of Sevilla (Spain), in 1995, and the Ph. D. Degree in Physics from the University Complutense of Madrid (Spain), in 2003. Since 2003, he is a lecturer at the Department of Electronic, Computer Science and Automatic Engineering of the University of Huelva (Spain). His current research interests include Computer Vision, Digital Image Processing and System Modelling and Identification.