

A 3D Approach for Extraction of the Coronary artery and Quantification of the Stenosis

Mahdi Mazinani, S. D. Qanadli, Rahil Hosseini, Tim Ellis, Jamshid Dehmeshki

Abstract—Segmentation and quantification of stenosis is an important task in assessing coronary artery disease. One of the main challenges is measuring the real diameter of curved vessels. Moreover, uncertainty in segmentation of different tissues in the narrow vessel is an important issue that affects accuracy. This paper proposes an algorithm to extract coronary arteries and measure the degree of stenosis. Markovian fuzzy clustering method is applied to model uncertainty arises from partial volume effect problem. The algorithm employs: segmentation, centreline extraction, estimation of orthogonal plane to centreline, measurement of the degree of stenosis. To evaluate the accuracy and reproducibility, the approach has been applied to a vascular phantom and the results are compared with real diameter. The results of 10 patient datasets have been visually judged by a qualified radiologist. The results reveal the superiority of the proposed method compared to the Conventional thresholding Method (CTM) on both datasets.

Keywords—3D coronary artery tree extraction, segmentation, quantification, fuzzy clustering, and Markov random field

I. INTRODUCTION

STENOSIS is a condition related to the narrowing of a vessel or artery, which in severe cases can result in complete blockage. Diagnosis of stenosis is supported by CT angiography, which can be used to detect, localize and determine the severity of the condition. Modern digital image processing systems provide powerful tools which can help the radiologist to identify and quantify the stenosis in coronary arteries. In such a system, there are two major tasks (1) Detection of stenosis, (2) Quantification of the degree of stenosis by modelling uncertainty arises from partial volume effect. Measurement of the degree of the stenosis involves the following processes:

1. Segmentation of coronary arteries.
2. Detection of the stenosis interval.
3. Extracting the centreline in the stenosis interval.
4. Estimating the orthogonal plane to the centreline.
5. Measuring the degree of the stenosis along with modelling uncertainty.

Several semiautomatic techniques have been reported for extracting the coronary artery from other tissues with the same intensity [13]-[15]. One of the drawbacks of these methods is the need for user interaction to define the seed points to locate

the artery. We present an algorithm that automatically finds suitable seed points based region growing and extracts the coronary artery.

The radiologist defines the stenosis interval using the extracted coronary arteries. The centreline of the vessel is extracted in the stenosis interval. Centreline represents the essential characteristic of an object's shape. There are several methods for extracting the centreline [7]-[9], [15]. In some approaches the centreline is extracted directly [8] while others are based on the medial surface [7]. One of the common techniques is thinning [9]. Thinning algorithms employ a set of templates for recognizing simple points. A simple point is a 1-voxel whose removal does not change the topology (connectivity) of the image. The actual diameter is measured in the orthogonal direction to the centreline of the vessel. Several methods have been proposed for measuring actual diameter of vessels using level set techniques [13]-[14]. Although these methods find the boundary vessel which is approximately orthogonal to the centreline of the vessel [13]-[14], but they suffer from a high computational complexity associated with level set approaches. This paper develops an interpolation technique, applied to raw image of coronary arteries, for estimating the plane orthogonal to its centreline.

The degree of the stenosis is measured base on the result of the pervious steps. One of the most important challenges in the diameters measurement is consideration of the partial volume effect (PVE) problem which is the major issue in measuring the degree of stenosis. The PVE is related to low spatial resolution and motion artifact in digital CTA images. Moreover, the uncertainty arising from PVE may lead to inaccurate segmentation and measurement results because a voxel may belong to more than one tissue type but the conventional segmentation method may assign it to only one type. For tackling these uncertainty problems in image segmentation, several approaches have been presented in the literature [1]-[6]. These methods can be classified into three main categories: probabilistic methods [4]-[5], fuzzy methods [8], and a combination of both fuzzy and probabilistic approaches [1]-[3].

Fuzzy sets have been used for managing imprecision in ambiguous circumstances. The main problem with this unsupervised method is the lack of consideration of spatial information, which reduces the accuracy of voxel labelling [1]-[3].

Markov random fields (MRF) are a probabilistic modelling method which is widely used for incorporating spatial information [4]-[5]. Several attempts are reported in the literature to incorporate such spatial information into a fuzzy model [1]-[3]. For tackling the uncertainty associated with the PVE problem, in this study after detecting the location of stenosis, first orthogonal plane is estimated on raw image in stenosis location, then a hybrid Markovian fuzzy clustering

M. Mazinani, and R.Hosseini are the faculty members of Islamic Azad University, Shahryar-Shahre ghods brach, Tehran, Iran, they are also members of the Quantitative Imaging Lab (research development) in the Faculty of Computing, Information Systems and Mathematics, Kingston University, London, UK (e-mail: m.mazinani@Kingston.ac.uk).

T. Ellis, and J.Dehtmeshki (director of study) are members of the Quantitative Imaging Lab (research development) in the Faculty of Computing, Information Systems and Mathematics, Kingston University, London, UK (e-mail: j.dehtmeshki@kingston.ac.uk).

S.D. Qanadli is a member of the Quantitative Imaging Lab (clinical site) in the Departments of Radiology and Cardiology and the Intensive Care Unit, Lausanne Hospital the Departments of Radiology and Cardiology and the Intensive Care Unit, Lausanne Hospital.

approach is applied which combines the multi scale approach and the novel generalized FCM (NGFCM). The NGFCM is proposed by Li et al which applies MRF spatial constraints to the FCM using a Bayesian approach [1].

The rest of the paper is organized as follows: Section II overviews the methodology for extracting coronary arteries and measuring the stenosis. The approach for extraction and visualization of the 3D coronary artery is proposed in Section III. Section IV outlines our adapted method for modelling uncertainty in the measurement process. Experimental results of the proposed method and its comparison to CTM are presented in section V and the paper is concluded in Section VI.

II. METHODOLOGY

A sequence of processes are applied to a CTA dataset to extract and visualize the coronary arteries, measure the degree of stenosis after detection of stenosis interval by a radiologist. These steps are preceded by image smoothing and grey-level thresholding, which results in robust segmentation of the vessel regions as a consequence of the high contrast of CTA images. A search through the image slices (moving from head to toe) is used to locate the slice at which the coronary artery joins the aorta, followed by selection of appropriate seed points to initialize the region grower that extracts the coronary arteries. Next the stenosis interval is defined by a radiologist and artery centreline is extracted by thinning in defined interval. Then the resulting centreline is smoothed; the orthogonal plane to the centreline is defined.

Multi-scale Markovian fuzzy clustering (MMFC) is applied to model the uncertainty in the stenosis location. Finally, the degree of stenosis is measured, guided by the output of the MMFC algorithm and the orthogonal plane to the centreline of the coronary arteries.

The next section gives more detailed description of the proposed approach.

III. DETECTION OF THE STENOSIS

A. Segmentation of the coronary artery

Automatic segmentation of the coronary artery begins with location of the left and right coronary arteries. This uses anatomical knowledge to locate landmark features; firstly the Y-shaped bifurcation of the pulmonary trunk, then the ascending aorta from which the branching points of the coronary arteries. The steps of our proposed algorithm are described as follows:

Step1: image enhancement: a median filter is applied to reduce image noise and smooth the image, followed by thresholding on the HU value of the voxels. A 3D morphological opening operator is applied to remove small isolated objects.

Step2: identification of the ascending aorta: This step starts from the first image slice and searches through the slice dataset (moving from head to toe) to find the bifurcation of the pulmonary trunk, which is located between the two sections of the aorta below the aortic arch, as shown in Figure 1. A region labelling is applied on all constructed cubes and the three

largest objects are checked to find the biggest object which is centred between two smaller regions with a circular shape.

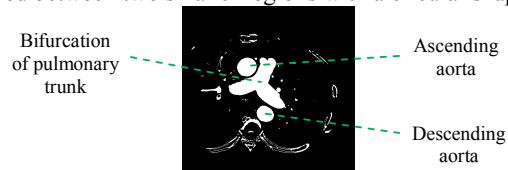


Fig. 1 Bifurcation of the pulmonary trunk

Step3: finding the branching points of the left and right coronary arteries: a region labelling is employed on the remaining slices to construct the ascending aorta and other connected objects such as the coronary arteries. In order to locate the left and right coronary arteries branch from the aorta the algorithm projects the extracted object onto the x-z and y-z planes. A 2D morphological opening operator is then applied to remove small objects (including the coronary arteries). By subtracting the result from the original image, we can estimate the location of the coronary arteries. This process starts from the top slice below the bifurcation of the pulmonary trunk and descends through the slices searching for the left coronary artery at a point located below the centroid of the ascending aorta is left coronary artery and the right coronary arteries centroid is located above the centroid of the ascending aorta

Step4: Segmenting coronary arteries: The coronary arteries are much smaller than the heart chambers, by selection of an appropriate kernel with a morphological opening and closing, we can remove these large objects to avoid region growing leakage to heart. Then the branching points of the left and right coronary arteries (from step3) are used to seed the region growing algorithm to distinguish the coronary arteries from the remaining small objects. In the next subsection the centreline of the defined stenosis interval is extracted from the results of this step.

B. Interpolating the orthogonal plane to the centreline

Accurate diameter of the vessel is measured using the orthogonal plane to the vessel centreline.

The stenosis location is defined by a radiologist in the extracted coronary artery. The algorithm needs the interval (start point and end point) of the stenosis as input. The centreline of the coronary artery is extracted in stenosis interval by employing the thinning algorithm explained in [8].

The face of triangle method estimates the plane orthogonal to the centreline [10]. In this approach the orthogonal plane is defined by using the coordinate of the considered point on the centreline and the average direction of the centreline at that point, as the normal vector of the plane. This plane is crossed with cube shape 3D image. The plane can cut at least 3 (and a maximum of 6) edges. After finding intersected points, one of them is chosen as an origin point and the plane is divided into separate triangles by connecting this origin point to other intersected points. The intersected area of the plane can be reconstructed by considering all defined triangles as the border over defined tangent space. Then the 3D coordinate is used for interpolation and estimation of the intensity of the points on the plane. Various methods can be used for 3D interpolation: nearest neighbourhood, linear interpolation, cosine interpolation and cubic interpolation [11]. Cosine interpolation

provides the better result, because nearest neighbourhood and linear interpolation have discontinuities at each point [11]. The cosine interpolation has a smoother interpolating function and transition between adjacent segments and has been focused in this paper.

IV. MEASURING THE DEGREE OF THE STENOSIS

An important problem in measuring the degree of stenosis is associated with the partial volume effect which can be particularly severed for the narrow coronary arteries. This issue may result in inaccurate measurements of the vessel diameter and the degree of the stenosis. This section presents a method for modelling the uncertainty in the measurement process.

A. Modelling uncertainty in the segmentation of stenosis

In the proposed multi-scale Markovian fuzzy clustering (MMFCM) method improves the NGFCM algorithm [1]. The average intensity of the neighbourhoods is considered as a second input series in the algorithm. In NGFCM algorithm a Markovian random field model [4] is combined with a fuzzy c-mean algorithm (FCM) to incorporate local spatial information directly into the original FCM algorithm's membership function [1]. A spatial penalty term is added to the membership function to improve the performance of the clustering [1]. This algorithm which was applied to brain segmentation, improves the robustness of the FCM to noise and artifacts. We combined the multi-scale approach with the NGFCM algorithm by considering the intensity of each voxel, and the average intensity of its neighbours.

In Markov random field, applying the prior and posterior distribution of membership functions using a logarithmic transformation maximum a posteriori (MAP), estimation of NGFCM is equivalent to minimizing the following objective function [1]:

$$J_m = \sum_{i=1}^c \sum_{k=1}^N (\mu_{ik})^m (d_{ik})^2 + \frac{\beta}{2} \sum_{i=1}^c \sum_{k=1}^N \sum_{l \in N_k} (\mu_{ik} - \mu_{il})^2 \quad (1)$$

where $d_{ik} = \|x_k - v_i\|$.

In this membership function the first part is the standard FCM function and the second part is the penalty term. The parameter β controls the effect of the penalty term and if $\beta=0$ then the function reduces to the standard FCM. The new membership function has the advantages of FCM and MRF simultaneously. The first part of equation 1 is minimized when high membership values are assigned to the voxels with intensities near to the related class and the second term is minimized if the membership values of the adjacent voxels are similar.

The proposed stenosis segmentation algorithm based on NGFCM is used for segmentation and quantification of blood vessel from other tissues such as soft plaque, in the region surrounding the coronary artery. The following algorithm is applied for all voxels on the centreline in the stenosis interval as follows:

Step1. Finding the region of interest: After estimating the orthogonal plane to the centreline in the stenosis interval, the region of interest (ROI) is located by applying a region labelling.

Step2. Identification of number of regions: The region of interest (ROI) normally contains two different regions: lumen and surrounding tissue, if the maximum intensity in ROI is more than 500 it means the ROI contains calcium as third type of tissue.

Step3. Apply the NGFCM: a 2-dimensional (2D) multi scale (2 scales) NGFCM is applied to incorporate neighbourhood information and decrease the influence of the partial volume effect in clustering of ROI into different regions. The algorithm is applied to a two dimensional input vector $X = \{X_1, X_2\}$ where $X_1 = \{x_{11}, x_{12}, \dots, x_{1N}\}$ is intensity of the raw image and $X_2 = \{x_{21}, x_{22}, \dots, x_{2N}\}$ is the average of intensities in the N_k neighbourhood.

Step4. Extracting mis-segmented regions: previous step may detect other regions which are not part of the blood vessel and have a similar intensity to it. To tackle this problem, a region growing method is applied for recognition of the blood vessel from other regions.

Step5. Region merging: isolated objects are removed in previous step; however, there may still be some misclassified voxels, specifically when more than two types of tissue are detected. The reason is the intensity (HU) of the surrounding area of soft plaque decreases gradually (due to the partial volume effect). Step 4 may misclassify these surrounding voxels as blood vessel. A morphological operation (an erosion operation followed by a dilation operation) is applied to re-classify these voxels as soft plaque. Then a thresholding method is applied to the segmented regions as follows:

$$\mu_{new_k} = \begin{cases} 1 & \mu_{res_k} > \tau_1 \\ 0 & \mu_{res_k} < \tau_2 \\ \mu_{res_k} & \text{else} \end{cases} \quad (2)$$

where μ_{new_k} is the membership value of the k th pixel after thresholding, μ_{res_k} is the membership value of the k th pixel, and the parameters τ_1, τ_2 are calculated heuristically ($\tau_1, \tau_2 \in [0, 1]$).

Step6. Measuring the area of blood vessel: For measuring the area of blood vessel the result of step 5 is used as follows:

$$Area = \sum_{k=1}^N \mu_{new_k} \times A_{pix} \quad (3)$$

where $Area$ is the quantified value for blood vessel, N is the number of pixels in the estimated orthogonal plane of the image, μ_{new_k} is the membership value of the k th pixel which was calculated in step 5 and A_{pix} is the area of one pixel.

Step7. The effective diameter of the vessel is measured as follow and added to the profile of the effective diameter:

$$diameter = 2 \times \sqrt{\frac{Area}{\pi}} \quad (4)$$

B. Quantification of the stenosis in the 3D stenosis location

The minimum vessel diameter in the profile of the effective diameter and the real diameter (without stenosis) are used to measure the degree of the stenosis as follows:

$$degree \text{ of stenosis} = \frac{diameter_{normal} - diameter_{blocked}}{diameter_{normal}} \quad (5)$$

where $diameter_{normal}$, and $diameter_{blocked}$ are diameter without stenosis and minimum diameter in stenosis interval, respectively.

V. EXPERIMENTAL RESULT

The proposed method for coronary arteries extraction and quantification of the stenosis was evaluated for extraction of the coronary artery and quantification of the degree of the stenosis. In the proposed algorithm for extraction of the coronary artery was applied to 15 patients CTA scans (real data). Because of the importance of the diameter measurement in the quantification of the degree of the stenosis, the evaluation is performed on phantom data as well as real data.

The real data was provided by Lausanne Hospital and were all scanned with the same parameters (120kV, 749 mA, slice thickness 0.6 mm).

The result of applying the proposed approach is discussed in the following subsections.

A. Coronary artery extraction

The proposed algorithm was applied to 15 CTA scans. The threshold values in step1 were selected between 280-600 HU for automatic pre-segmentation of the region with angio blood intensity (ascending aorta). The threshold value for extracting the coronary artery is automatically defined based on mean and variance of the intensity of the extracted aorta. The results of the automatic segmentation of the coronary artery are shown in Figures 2(a)-(b). The extracted vessel was visually judged as correctly by a qualified radiologist.

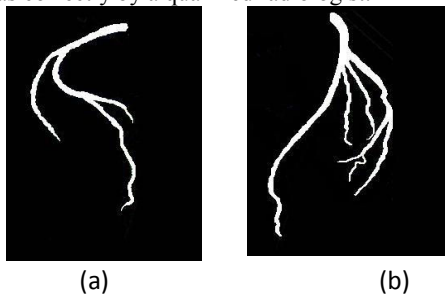


Fig. 2 The result of automatic algorithm, (a) right coronary artery, (b) left coronary artery

B. Measurement of the degree of the stenosis

The diameter measurement plays an important role in the quantification of the degree of the stenosis. We evaluate the diameter measurement (MMFC) algorithm in phantom data as well as real patients' data. The method for defining the reference point to measure diameter without stenosis is assessed using the real data. The reproducibility and accuracy of the algorithm for the diameter measurement (MMFC) is compared to CTM.

1) Vascular phantom study

The geometry of the vascular phantom is designed to mimic the complexity of real human vessels and is compatible with all imaging modalities evaluated [12]. It is also equipped with an inlet and outlet to enable a real fluid flow [12]. Its geometry of the vessel is a cylindrical channel that is positioned in the centre of a case surrounded by soft tissue equivalent material with respect to the real attenuation characteristics of X-rays in the body (Figure 3). The diameter of the vessel varies from 1-8mm along its length, so it can simulate stenosis in the vessel (Figure 3 (b)). The phantom was scanned 32 times on a 16-slice Multi-Detector Row CT

(MDCT) (a GE Light Speed Pro) using 10 different protocols with slice thicknesses from 0.625 mm to 1.725 mm and pitch from 1.3 to 1.7 and FOV 25 and 36.

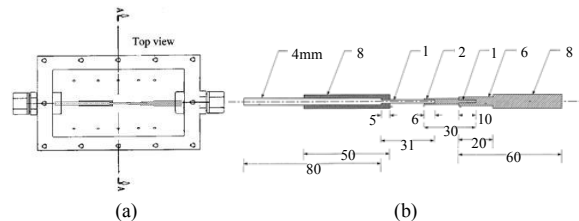


Fig. 3 Vascular Phantom (a) top view, (b) actual size of the vessel

Vessel diameters are calculated using equation 4 and the results are shown in tables I and II. Table I shows the accuracy and reproducibility of methods in study 1, where results are averaged over 21 slices of the same dataset (slice thicknesses 0.625 mm, pitch=1.3 and FOV=25) with the same diameter. It is apparent from table I that the accuracy of the measurement for our algorithm is higher than others in most of the cases and its reproducibility is higher than others in all of the cases (different diameters of the phantom). Table II shows the result of the methods for study 2 which are averaged over all 32 scans of the phantom using 10 different protocols. The results reveal that our method has superior accuracy in most of the cases and reproducibility in all the cases. As shown in table I and II, diameter measurements using our method have a low standard deviation which is most important issue when an investigation of the disease's progress is considered. Also the proposed method has a low bias or systematic error (the difference between actual value and mean value in both study 1 and 2) in most of the cases. Our method demonstrates superior performance compared with the CTM methods, with a standard deviation of 0.01-0.047mm regardless of the size of the vessel.

2) Real Clinical Data Study

In order to measure the vessel diameter in the proposed MMFC algorithm, the following parameters were selected. An 8 neighbourhood scheme is chosen for N_k , and m is considered 2 (equation 1). In this paper, the β is chosen empirically, however the cross-validation method proposed in [3] can be used to estimate β . For our application, $\beta = 2.4$ is selected. In equation 2, the thresholds values of $\tau_1 = 0.9$ and $\tau_2 = 0.3$ are used. The result of applying this algorithm is shown in Figure 4. Figure 4(d) illustrates the impact of estimating the partial membership of a voxel to the detected object. The performance is compared against thresholding (Figure 4(c)). The results have been approved visually by a qualified radiologist. The segmentation algorithm separates the blood vessel from other tissue such as soft plaque. Figure 4(a) depicts three distinct tissue regions with average HUs of 300, 1000, and 50. Comparing the results of these three methods, there are some voxels in Figure 4(b) for which the HU value is further from the average HU for a blood vessel and may belong to more than one region. This fact is not accounted in deterministic clustering (Figure 4(c)).


Therefore the MMFC diameter measurement results are more accurate than the compared method.

TABLE I
THE AVERAGE DIAMETER OF 21 SLICES OF EACH DIAMETER IN AN IMAGE
PHANTOM USING THREE DIFFERENT METHODS: CONVENTIONAL
THRESHOLDING, AND THE MMFC

Actual value of diameter		1mm	2mm	4mm	6mm	8mm
CTM	mean	0.7864	2.8162	4.8571	6.8935	8.6322
	Std	0.7140	0.3318	0.3133	0.2749	0.1552
MMFC	mean	1.3120	2.2900	4.0879	6.2412	8.0107
	Std	0.0435	0.0110	0.0025	0.0015	3.34e-4

TABLE II
THE AVERAGE DIAMETER OVER 32 SCAN OF THE PHANTOM WITH 10 DIFFERENT
PROTOCOLS USING THREE DIFFERENT METHODS CONVENTIONAL
THRESHOLDING, AND PROPOSED MARKOVIAN-FUZZY ALGORITHM

Actual value of diameter		1 mm	2 mm	4 mm	6mm	8mm
CTM	Mean	0.8498	2.8503	4.8581	6.9055	8.6396
	Std	0.8887	0.4636	0.4878	0.5202	0.4252
MMFC	Mean	1.2100	2.3839	4.2161	6.3358	8.0639
	Std	0.2167	0.1161	0.1081	0.1000	0.0500



(a)

-27	50	40	65	75	76	45	20	-16	-38
10	95	75	85	80	97	99	67	-25	-31
27	100	145	165	196	195	169	160	-16	-38
15	137	220	290	285	290	306	220	105	83
31	163	290	310	340	364	384	301	180	75
81	180	310	320	374	416	554	483	285	71
76	175	320	340	392	611	859	805	470	74
35	130	298	334	504	858	1177	1140	684	95
76	98	240	360	590	993	1281	1250	803	98
86	89	182	386	516	837	1024	1012	723	105
99	85	118	139	364	467	571	584	489	72
60	60	72	77	79	145	213	245	259	69
3	3	61	31	-53	-32	42	81	60	60

(b)

0	0	0	0	0	0	0	0	0	0
0	0	0	0	0	0	0	0	0	0
0	0	1	1	1	1	1	1	1	0
0	1	1	1	1	1	1	1	1	0
0	1	1	1	1	1	1	1	1	0
0	1	1	1	1	1	1	0	0	0
0	1	1	1	1	1	0	0	0	0
0	0	1	1	1	0	0	0	0	0
0	0	1	1	0	0	0	0	0	0
0	0	0	0	0	0	0	0	0	0
0	0	0	0	0	0	0	0	0	0
0	0	0	0	0	0	0	0	0	0

(c)

0	0	0	0	0	0	0	0	0	0
0	0	0	0	0	0	0	0	0	0
0	0	0.35	0.47	0.67	0.66	0.5	0.44	0	0
0	0.3	0.79	1	1	1	1	0.79	0	0
0	0.46	1	1	1	1	1	1	0.57	0
0	0.57	1	1	1	1	0.65	0.8	0	0
0	0.54	1	1	1	0.51	0	0	0	0
0	0	1	1	0.76	0	0	0	0	0
0	0	0.87	1	0.57	0	0	0	0	0
0	0	0.58	1	0	0	0	0	0	0
0	0	0	0.31	0	0	0	0	0	0
0	0	0	0	0	0	0	0	0	0
0	0	0	0	0	0	0	0	0	0

(d)

Fig. 4 (a) The original image (orthogonal estimated image of vessel with stenosis), (b) HU table for image, (c) table of deterministic thresholding result, (d) table of proposed segmentation algorithm result

VI. CONCLUSION

This study has developed a semi-automatic approach for 3D extraction and visualization of the coronary artery and quantification of the degree of stenosis. The orthogonal plane to the centreline was estimated on the stenosis interval of the coronary artery to measure the diameter precisely. The multi-scaled Markovian fuzzy c-mean clustering algorithm (NGFCM) models uncertainty in the segmentation of the blood vessel to increase the accuracy of the measurement.

The method was evaluated on a synthetic phantom as well as real CTA patient datasets. Results of real CTA datasets were validated by a qualified radiologist. The accuracy and reproducibility of quantification algorithm was compared to the CTM. The results reveal our approach superior performance compared to other algorithm for extraction of the coronary artery and segmentation and quantification of the degree of the stenosis in the coronary arteries.

REFERENCES

- [1] X. Li, T. ZHANG, and Z. QU, "Image Segmentation Using Fuzzy Clustering with Spatial Constraints Based on Markov Random Field via Bayesian Theory", *IEICE Trans. Fundamental*, vol. E91-A, no.3, pp. 723-729, 2008.
- [2] Y.A. Tolias and S.M. Panas, "On applying spatial constraints in fuzzy image clustering using a fuzzy rule-based system," *IEEE Signal Process. Lett.*, vol.5, no.10, pp.245-247, 1998.
- [3] D. L. Pham, "Spatial models for fuzzy clustering," *Computer Vision and Image Understanding*, vol.84, no.2, pp.285-297, 2001.
- [4] S. Z. Li, "Markov Random Field Modeling in Computer Vision", Springer-Verlag, 1995.
- [5] X. Ye, X. Lin, J. Dehmshki, G. Slabaugh, and G. Beddoe, "Shape Based Computer Aided Detection of Lung Nodules in Thoracic CT Image," *IEEE Trans. Biomedical Engineering*, vol. 56, pp. 1810 - 1820, 2009.
- [6] O. Demirkaya, M.Hakan Asyali, P. K. Sahoo, "Image Processing with MATLAB Applications in Medicine and Biology," *CRC Press*, 2009.
- [7] N. Nicolaidis, I. Pitas, *3D image processing algorithm*. London:wiley; 2001.
- [8] K. Palagyi, A. Kuba, "A 3D 6-subiteration thinning algorithm for extracting medial lines," *Pattern Recogn Lett*, vol. 19, pp. 613-627, 1998.
- [9] C. Arcelli, G. S. D. Baja, "A width-independent fast thinning algorithm," *IEEE Trans PAMI*, vol. 7(4), pp. 463-474, 1985.
- [10] P.J. Schneider, D.H. Eberly, *Geometric tools for computer graphics*, Morgan Kaufmann, 2003.
- [11] H. Triebel, *Interpolation theory, function spaces, differential operators*, North-Holland Publishing Company, 1978.
- [12] G. Soulez and S.D. Qanadli, "A multimodality vascular imaging phantom with fiducial markers visible in DSA, CTA, MRA, and ultrasound", *Medical Physics*, vol. 31, pp. 1424-1433, 2004.
- [13] H. Scherl, J. Hornegger, M. Prummer, M. Lell, "Semi-automatic level-set based segmentation and stenosis quantification of internal carotid artery in 3D CTA data sets," *Medical Image Analysis*, vol. 11, pp. 21-34, 2007.
- [14] Y. Yang, A. Tannenbaum, D. Giddens, "Knowledge-Based 3D Segmentation and Reconstruction of Coronary Arteries Using CT Images", in Proc. 26th Annu. IEEE Conf. Engineering in Medicine and Biology Society, Atlanta, GA, USA, 2004.
- [15] C. Metz, M. Schaap, A. Van Der Giessen, T. Van Walsum, W. Niessen, "semi-automatic coronary artery centerline extraction in computed tomography angiography data," in Proc. 4th IEEE Int. Symp. Biomed. Imaging, Arlington, VA, pp. 856-85, 2007.