

Reverse Twin Block with Expansion Screw for Treatment of Skeletal Class III Malocclusion in Growing Patient: Case Report

Alfrina Marwan, Erna Sulistyawati

Abstract—Class III malocclusion shows both skeletal and dentoalveolar component. Skeletal Class III malocclusion can have variants in different region, maxilla or mandibular. Skeletal Class III malocclusion during growth period is considered to treat to prevent its severity in adulthood. Orthopedics treatment of skeletal Class III malocclusion in growing patient can be treated by using reverse twin block with expansion screw to modify the growth pattern. The objective of this case report was to describe the functional correction of skeletal Class III malocclusion using reverse twin block with expansion screw in growing patient. A patient with concave profile came with a chief complaint of aesthetic problems. The cephalometric analysis showed that patient had skeletal Class III malocclusion (ANB -5° , SNA 75° , Wits appraisal -3 mm) with anterior cross bite and deep bite (overjet -3 mm, overbite 6 mm). In this case report, the patient was treated with reverse twin block appliance with expansion screw. After three months of treatment, the skeletal problems have been corrected (ANB -1°), overjet, overbite and aesthetic were improved. Reverse twin block appliance with expansion screw can be used as orthopedics treatment for skeletal Class III malocclusion in growing patient and can improve the aesthetic with great satisfaction which was the main complaint in this patient.

Keywords—Growing patient, maxilla retrognathism, reverse twin blocks, skeletal Class III malocclusion.

I. INTRODUCTION

SKELETAL Class III malocclusion is a serious challenge in dentofacial orthopedics which can be caused by maxilla retrognathism, mandibular prognathism or both. Skeletal Class III malocclusion with anterior cross bite during growth period is a condition that requires early treatment to prevent its severity in adulthood [1]-[7]. The main advantage of early treatment is to avoid surgical intervention and thus reduce the morbidity of surgery [1]. The treatment approaches for correcting a Class III malocclusion is done by growth modifications by using orthopedic appliances such as, reverse twin block, bionator, Frankel's III, eschlar appliances, chin cup, reverse twin block and facemask therapy [1]-[4], [6]-[8]. Twin block appliances can be designed with many variations depending on the nature of the malocclusion, such as reverse twin block that is used to corrected Class III malocclusion [8].

Reverse twin blocks are orthopedic functional appliances

Alfrina Marwan is with Departement of Orthodontics, Faculty of Dentistry, University of Sumatera Utara, Medan, Indonesia (e-mail: kaylarifan@gmail.com).

Erna Sulistyawati is with Departement of Orthodontics, Faculty of Dentistry, University of Sumatera Utara, Medan.

which contain of simple bite-blocks that use to correct skeletal Class III malocclusion which effectively modify the growth pattern. This appliance achieves rapid functional correction of malocclusion by transmitting favorable occlusal forces by reversing the angulation of inclined planes for maxillary advancement, and restricts mandibular development to forward position [3]-[7]. The expansion screw can be used on maxilla to expand the arch forward [7].

II. CASE REPORT

A. Diagnosis

A 10-year-old girl came to Post Graduate Orthodontic Clinic Faculty of Dentistry, University of Sumatera Utara. She had the chief complaint of unaesthetic facial which maxillary retrognathism. She had no relevant medical history or bad habit that lead to her anomaly. The extraoral examination showed that she had a concave facial profile, symmetry, competent lips and lower lip protrusion (Fig. 1). The intraoral examination revealed that she had anterior cross bite with negative overjet 4 mm and overbite 6 mm. The molar relation was Angle Class III on the left side and Class I on the right side. Maxillary and mandibular dental midlines are coincident (Fig. 2).



Fig. 1 Pretreatment extraoral photographs

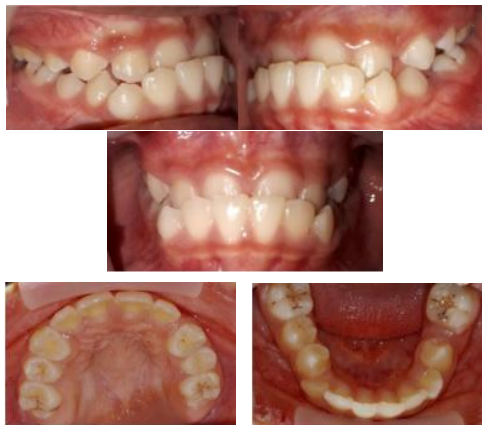

Fig. 2 Pretreatment intraoral photographs

B. Radiography Analysis

The radiography cephalometry lateral analysis showed skeletal Class III malocclusion with maxilla retrognathism (ANB - 5°; SNA 75°; Wits appraisal - 3 mm). The mandibular incisors had labial inclination (IMPA 90°) (Fig. 3 and Table. I). She had normal growth pattern and mandibular rotation. The facial convexity is concave (NAPog - 13°), soft tissue analysis showed upper and lower lip retrusion. The evaluation of cervical vertebrae maturation using the developed stage by Hassel and Farman revealed that she was in initiation stage with more than 85% of pubertal growth remains. Radiography

panoramic showed all tooth seeds is complete.

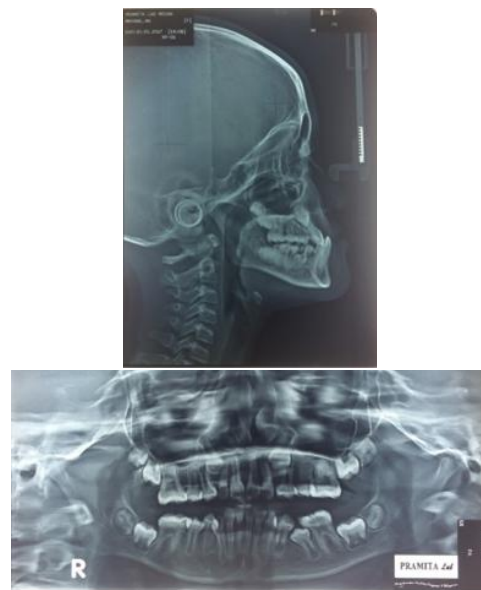


Fig. 3 Pretreatment lateral cephalogram and panoramic radiograph

TABLE I
RADIOGRAPHIC ANALYSIS OF CEPHALOMETRICS

Measurements	Mean	SD	Pre-treatment	Post-treatment
SNA (°)	82	±2	75	75
SNB (°)	80	±2	80	76
ANB (°)	2	±2	- 5	- 1
NAPog (°)	0	-8.5 to +10	- 13	- 3
MP : SN (°)	32	±2	33	36
NSGn(Y axis) (°)	65	±3	65	69
Pog : NB (mm)	2	±1	0.5	1
SGo : NMe (%)	68	±4	65/104 × 100% = 62.5	65/107.5 × 100% = 60.46
Wits appraisal	0	2	- 3	- 1.5
I : (°)	130	±2	132	116
I : SN (°)	104	±2	106	119
: MP (°)	90	±2	90	90
I : APog (mm)	4	±2	- 0.5	6
: NB (mm)	4	±2	- 2	3
E : LS (mm)	-2 to -3		- 5	- 2.5
E : LI (mm)	-1 to -2		- 0.5	- 1

C. Treatment Objective

The main objectives of the treatment were to correct skeletal Class III malocclusion, anterior cross bite, to improve her facial esthetics, and to achieve an appropriate occlusion with normal overjet and overbite.

D. Treatment Progress

The patient is still in growth period, so the treatment will be performed in two stages. In the first stage we used reverse twin blocks with expansion screw to correct the skeletal

discrepancies (Fig. 4). The second stage will be carried out to correction maxilla and mandibular interdigitation using fixed appliances.

Bite registration was taken with dental wax in maximum retrusion at least edge to edge relation with 2-3 mm inter-incisal clearance, and 6-8 mm thickness in the posterior region. Reverse twin blocks were constructed from heat-cured acrylic resin that modifies the occlusal inclined plane to induce favorably directed occlusal forces by causing a functional mandibular displacement. Upper and lower bite

blocks interlock at a 70° angle drives maxilla and restrict forward mandibular development while the expansion screw to drive forward the maxilla.

In the upper and lower anterior region were used Ball-ended clasps while Adams clasps in the posterior region (0.7 mm diameter stainless steel wire) were used to retain the appliances. Reverse twin blocks are designed for full-time wear to take advantage of all functional forces applied to the dentition including the forces of mastication.

The first recall visit was scheduled 1 week after insertion and then patient was instructed to activate the expansion screw 3 times for week each round. The lower bite block was trimmed simultaneously with each visit to allow the extrusion lower molar. Visits were scheduled at two until three weeks to monitor treatment progress [8].

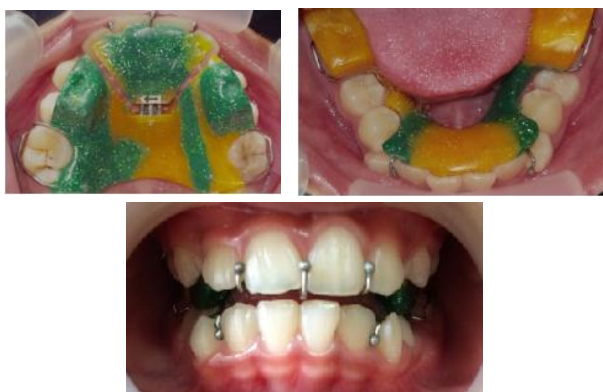

Fig. 4 Reverse twin blocks with expansion screw in maxilla and mandibular

E. Treatment Result

After using reverse twin blocks with expansion screw in three months her skeletal Class III malocclusion and anterior cross bite were corrected, facial esthetics was improved, normal overjet and overbite were achieved. We finished the first stage of treatment. From the post treatment of cephalometric analysis (Table I), it shows that skeletal relation changes have occurred, the ANB value becomes -1° showed that still the skeletal Class III, but SNB angle was decreased 4° and the value of skeletal convexity decreased 10° which make the profile improved

From the soft tissue analysis, lower lip has moved backward, and the overjet improved to normal value of 2 mm and the overbite improved to 3 mm (Figs. 5 and 6).

III. DISCUSSION

Early treatment in skeletal Class III malocclusion can be treated with orthopedic functional appliances which can modify the growth pattern, although the skeletal changes limited to slight downward and backward position of mandibular. Effect of reverse twin block in dentoskeletal is overjet and overbite reduction mostly due to dentoalveolar changes [5].

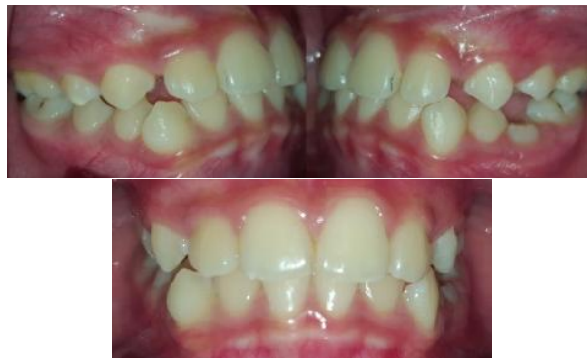

Fig. 5 Post treatment intraoral photographs

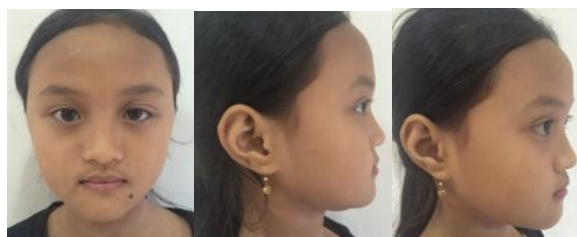


Fig. 6 Post treatment extra oral radiographs

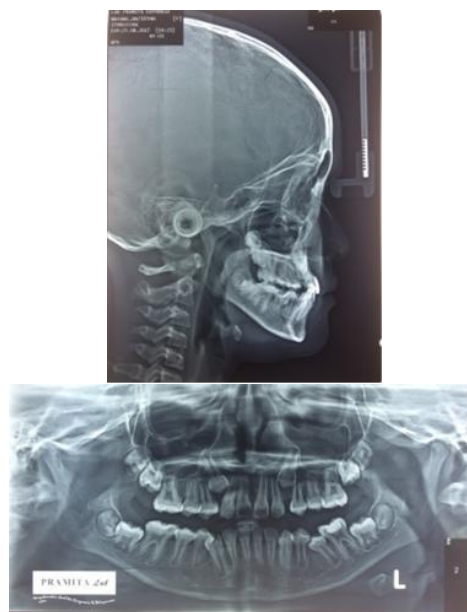

Fig. 7 Post treatment lateral cephalogram and panoramic radiograph

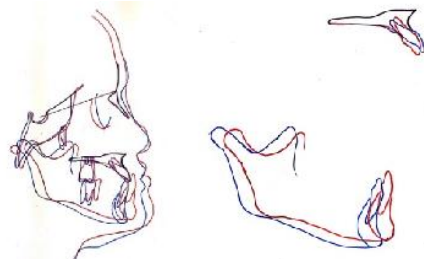


Fig. 8 Superimposition cephalometry

After treating the patient with reverse twin block with expansion screw for three months, superimposition cephalometri analysis (Fig. 8) showed that maxilla to cranium base (SNA) angle was 75° which is equal to the value before treatment. However, the mandibular to cranium base (SNB) angle decreased from 80° to 76° which reduces the skeletal relation between maxilla and mandibular to -1° , and -1.5 mm base on Wits appraisal (Ao-Bo). This reduction indicated that the movement of the mandibular to downward and backward but the maxilla remains in its position. Similar result is also shown by Seehra et al. [7] which is similar in SNA value, although greater value in SNB (Table I). In this patient occurred the side effect of reverse twin blocks with expansion screw are the changes in value on the mandibular growth rotation from normal to clockwise mandibular rotation, excessive vertical growth and increase of anterior facial height (Figs. 7, 8 and Table I).

The changes of skeletal facial profile were due to growth of mandibular which make the skeletal facial convexity decrease 10° (NAPog from -13° to -3°). Another effect was the changes inclination of maxilla incisors into proclination with value from 106° to 119° , but mandibular incisors remain in normal value 90° . From the soft tissue analysis, the value of upper lip; E line to labrale superius showed increase to normal position (from -5 to -2.5 mm) and also in lower lip; E line to labrale inferius (from -0.5 to -1 mm) that improved the facial profil.

The value of upper incisors to cranium base (I: SN) angle was increased from 106° to 119° , thus becoming procline of upper incisors. This effect occurred because of using the sagittal expansion screw in the upper appliances, however this can be corrected in the next stage by using fixed appliance.

The optimal results were achieved because patient in using the reverse twin block with expansion screw consistant throughout the day even while she is eating. In the next step the patients will plan to use fixed appliances after all of permanent teeth eruptive to correct dental malposition and obtain good and stable interdigitation.

IV. CONCLUSION

Skeletal Class III malocclusion in growing patient is a condition that must be treated immediately because if this malocclusion is not treated in growing patient, it may lead to an invasive treatment in adulthood.

The treatment of skeletal Class III malocclusion in growing patient by using reverse twin block with expansion screw had given satisfactory results which were shown in this case report. Reverse twin blocks are designed to be comfortable, aesthetic and efficient for patient. In our patient the short term of treatment strongly influenced by cooperation between patient, clinician and parents. These appliances is a simple bite blocks that can be tolerated by the patient, moreover this appliances works with adjustment by therefore very usable in growing period.

REFERENCES

[1] Woon S C, Thiruvkatachari B. Early orthodontic treatment for Class III malocclusion: A systematic review and meta-analysis. American

- Journal of Orthodontics and Dentofacial Orthopedics 2017;151:28-51.
- [2] Navarro P V P O, Almeida R R D, Conti A C D C F, Navarro R D L, Almeida M R D, Fernandes L S A F P. Early treatment protocol for skeletal Class III malocclusion. Brazilian Dental Journal 2013;24:167-173.
- [3] Sargod S S, Shetty N, Shabbir A. Early class III management in deciduous dentition using reverse twin block. J Indian Soc Ped Prev Dent 2013;31:56-60.
- [4] Chungh V K, Tandon P, Prasad V, Chungh A. Early orthopedic correction of skeletal class III malocclusion using combined reverse twin block and face mask therapy. J Indian Soc Pedod Prev Dent 2015;33:3-9.
- [5] Soni S, Prashar A, Kaur S, Bansal N, Garg V, Singh J. Versatile functional appliance-twin block. Int J Curr Res Med Sci 2017;3:115-9.
- [6] Mittal M, Singh H, Kumar A, Sharma P. Reverse twin block for interceptive management of developing Class III malocclusion. J Indian Soc Pedod Prev Dent 2017;35:86-9.
- [7] Seehra J, Fleming P S, Mandall N, DiBiase A T. A comparison of two different techniques for early correction of Class III malocclusion. Angle Orthodontist 2012;82:96-101.
- [8] Clark W. Design and management of twin blocks: reflection after 30 years of clinical use. Journal of Orthodontics 2010;37:209-16.