

Carvacrol Attenuates Lung Injury in Rats with Severe Acute Pancreatitis

Salim Cerig, Fatime Geyikoglu, Pinar Akpulat, Suat Colak, Hasan Turkez, Murat Bakir, Mirkhalil Hosseinigouzdagani, Kubra Koc

Abstract—This study was designed to evaluate whether carvacrol (CAR) could provide protection against lung injury by acute pancreatitis development. The rats were randomized into groups to receive (I) no therapy; (II) 50 µg/kg cerulein at 1h intervals by four intraperitoneal injections (i.p.); (III) 50, 100 and 200 mg/kg CAR by one i.p.; and (IV) cerulein+CAR after 2h of cerulein injection. 12h later, serum samples were obtained to assess pancreatic function the lipase and amylase values. The animals were euthanized and lung samples were excised. The specimens were stained with hematoxylin-eosin (H&E), periodic acid-Schiff (PAS), Mallory's trichrome and amyloid. Additionally, oxidative DNA damage was determined by measuring as increases in 8-hydroxy-deoxyguanosine (8-OH-dG) adducts. The results showed that the serum activity of lipase and amylase in AP rats were significantly reduced after the therapy ($p<0.05$). We also found that the 100 mg/kg dose of CAR significantly decreased 8-OH-dG levels. Moreover, the severe pathological findings in the lung such as necrosis, inflammation, congestion, fibrosis, and thickened alveolar septum were attenuated in the AP+CAR groups when compared with AP group. Finally, the magnitude of the protective effect on lung is certain, and CAR is an effective therapy for lung injury caused by AP.

Keywords—Antioxidant activity, carvacrol, experimental acute pancreatitis, lung injury, oxidative DNA damage.

I. INTRODUCTION

ACUTE PANCREATITIS (AP) can lead to a systemic inflammatory response that often results in acute lung injury and single or multiple organ failure [1]. Of the total number of patient mortalities due to AP, >50% are ascribed to acute lung injury in the early stage [2].

Previous studies have demonstrated that pulmonary inflammation following pancreatitis-associated oxidative stress causes pulmonary swelling, which consequently produces secondary micro vascular leakage, alveolar-capillary barrier disruption, and even alveolar damage and mortality [3], [4]. In AP, pulmonary congestion poses a critical problem due to its association with acute respiratory function failure. The other pathological findings are characterized as ground a significantly wider alveolar septum, alveolar epithelial injury and fibrosis [4]. Despite the fact that there have been

significant advances in the understanding of the pathogenesis of AP, the role of antioxidants in this phenomenon remain poorly understood. Antioxidant therapies are thought to improve lung morphology [5]. The lack of effective drugs to ameliorate the initiation and progression of pancreatitis-associated oxidative stress has led to increased interest in the role that antioxidants may serve in alleviating lung injury.

CAR, the most active constituent of thyme essential oils (EOs), is commonly used over a wide range of doses for various therapeutic applications [6], [7]. CAR's anti-proliferative, anti-inflammatory, and immune system modulation effects limit cancer growth and prevent leukocyte proliferation in inflammatory diseases [8]-[10]. It is also recognized as a safe food additive and used as flavoring agent in packed foods, sweets, beverages, and chewing gum [11], [12]. DNA-protective effects of CAR are assessed using different techniques. CAR shows high antioxidative effectiveness in all assays used [13].

In an effort to develop treatment modalities that reduce lung injury following AP, we studied whether CAR exerts protective effects against AP-induced oxidative lung injury in a rat model. Histological examinations were performed to determine the morphologic changes in rat lung tissues. To test oxidative DNA damage, we measured the DNA base adduct 8-hydroxy-deoxyguanosine (8-OH-dG), in the pulmonary cells. To the best of our knowledge, this is the first study that has investigated the protective effects of CAR against AP-induced pulmonary injury.

II. MATERIALS AND METHODS

A. Animals

Fifty six male Sprague-Dawley rats (weighing 200-250 g) obtained from Medical Experimental Application and Research Center, Atatürk University were used. Animals were housed inside polycarbonate cages in an air-conditioned room ($22\pm2^{\circ}\text{C}$) with 12-h light-dark cycle. Standard rat feed and water were provided ad libitum. The rats were allowed to acclimatize to the laboratory environment for 7 days before the start of the experiment. All procedures were performed in conformity with the Institutional Ethical Committee for Animal Care and Use at Atatürk University (protocol number: B.30.2.ATA.0.23.85-11) and the Guide for the Care and Use of Laboratory Animals [14].

B. Experimental Protocols

Animals were randomly divided into eight groups ($n=7$, each): (I) vehicle-treated group (control); (II) AP group; (III,

Mirkhalil Hosseinigouzdagani, Kubra Koc, Murat Bakir, Fatime Geyikoglu and Pinar Akpulat are with the Department of Biology, Atatürk University Faculty of Science, Erzurum, Turkey.

Suat Colak is with the Department of Plant and Animal Production, Erzincan University, Üzümlü Vocational, Erzincan, Turkey.

Hasan Turkez is with the Department of Molecular Biology and Genetics, Faculty of Science, Erzurum Technical University, Erzurum, Turkey.

Salim Cerig is with the Department of Biology, Atatürk University, Erzurum, Turkey (corresponding author, phone: 0 (442) 231 43 33, fax: 0 (442) 231 41 09, e-mail: salimcerig@atauni.edu.tr).

IV and V) CAR-treated groups (at three different dose); (VI, VII and VIII) CAR-treated AP groups.

AP was induced by cerulein (Sigma-Aldrich, GmbH, Stenheim, Germany) administered i.p. 4 times with 1 h intervals at a dose of 50 µg/kg b.wt. AP was assessed after last injection of cerulein by measurement of serum amylase and lipase levels. Animals without induction of AP (control) were treated i.p. with saline at the same time as animals treated with cerulein.

To evaluate the effects of CAR, animals were treated with CAR in 10 ml saline (Peptide International Inc, Japan). The CAR groups received one i.p. injection of 50, 100 and 200 mg/kg b.wt. Therapeutic treatments were administered after 2 h of cerulein injection. The rats were anesthetized with isoflurane after 12 h taking CAR and euthanized by exsanguination with blood retained for serum harvest. These investigations stem from the works of the researchers [15], [16].

C. Biochemical Analyses

Blood for serum amylase determinations was obtained from all animals when they were anesthetized. Serum amylase and lipase levels were determined spectrophotometrically using an automated analyzer (Olympus AU 600, Diamond Diagnostic, Holliston, USA). All chemicals were obtained from Sigma (Sigma, St Louis MO, USA).

Tissue specimens were obtained from all animal groups for determination of malondialdehyde (MDA), superoxide dismutase (SOD), catalase (CAT), and glutathione peroxidase (GSH-Px). SOD activity was studied on hemolysates by using commercial kits (Randox Laboratories, UK) [17]. CAT activity was measured according to Aebi's method [18]. The principle of the assay is based on determining the rate constant $[k (s^{-1})]$ of hydrogen peroxide decomposition by the catalase enzyme.

Plasma thiobarbituric acid reactive substance (TBARS) levels were determined according to Schoenberg's method [19]. Lung MDA levels were determined on erythrocyte lyte obtained after centrifugation. After the reaction of thiobarbituric acid with MDA, the reaction product was extracted in butanol and was spectrofluorometrically (excitation 532 nm, emission 553 nm, slit 10 nm) evaluated. Tetramethoxypropane solution was used as standard. TBARS levels in the lung tissue were expressed as nmol/g.

GSH-Px activity in the pulmonary tissue was measured by the method described previously [20]. The reaction mixture was 50 mmol/l tris buffer (pH 7.6) containing 1 mmol/l of Na₂EDTA, 2 mmol/l of reduced glutathione (GSH), 0.2 mmol/l of NADPH, 4 mmol/l of sodium azide, and 1000 U of glutathione reductase (GR). 50 µl of plasma and 950 µl of reaction mixture, or 20 µl of erythrocyte lysate and 980 µl of reaction mixture were mixed and incubated for 5 min at 37 °C. Then the reaction was initiated with 8.8 mmol/l H₂O₂ and the decrease in NADPH absorbance was followed at 340 nm for 3 min. Enzyme activities were expressed as U/g in the lung tissue.

D. Histopathological Examination

The lung tissues of rats were fixed in buffered 10% formalin solution for 24 h and embedded in a paraffin wax. Tissues were then sectioned at 5 µm, stained with H & E, PAS, Mallory trichrome and amyloid methods. A semiquantitative evaluation of lung tissue was accomplished by scoring the degree of severity according to the formerly published criteria [21], [22]. For each lung section, whole slide was examined for necrosis, infiltration, congestion, fibrosis and thickened alveolar septum were observed under bright field using an Olympus BX60 microscope equipped with a digital CCD. In addition, high-resolution pictures ($\times 200$) of samples were taken under the same microscope. The lung damage was scored with maximum score of 18. The maximum score for the other pathological findings was 3.

E. Determination of 8-OHdG Level

8-hydroxy-2'-deoxyguanosine assay kits were purchased from Cayman Chemical (Ann Arbor, Michigan, USA) for determining 8-OH-dG levels in the lung samples. Since it is a competitive assay that can be used for the quantification of 8-OH-dG in homogenates and recognizes both free 8-OH-dG and DNA-incorporated 8-OH-dG, many researches are being performed to use this protocol. This assay depends on the competition between 8-OHdG and 8-OHdG-acetylcholinesterase (AChE) conjugate (8-OH-Dg Tracer) for a limited amount of 8-OH-dG monoclonal antibody. All procedures were carried out in accordance with the provider manual.

F. Statistical Analysis

For statistical analysis, we used SPSS for Windows 18.0 (SPSS Inc., Chicago, USA). The experimental data were analyzed using one-way analysis of variance (ANOVA) followed by Tukey post hoc test for multiple comparisons. Results are presented as mean \pm standard deviation (SD) and values $p < 0.05$ were regarded as statistically significant.

III. RESULTS

Table I shows the effects of CAR on serum amylase and lipase levels in all experimental groups. The amylase rates in cerulein-induced AP were increased from an average 505 U/L to about 2366 U/L as compared with those of control rats. Similarly, lipase enzyme was greatly affected and increased from 23 µg/L to 126 µg/L by AP. The enzyme activation was not changed following intraperitoneal injection of CAR alone. After CAR treatments in animals with AP, positive effects on enzymes were observed and the values significantly were decreased with respect to 100mg/ kg dose of CAR ($p < 0.05$).

The SOD, CAT, and GSH-PX activities in lung of AP rats markedly decreased but MDA increased compared to those found at controls ($p < 0.05$). CAR groups alone showed the increased levels of antioxidant enzymes at both dosages (50 and 200 mg/kg, respectively). In these groups, MDA values were not changed. However, the best results were observed in a dose of 100 mg/kg of CAR. The activities of all enzymes were increased. Moreover, oxidative stress was significantly

decreased at this group and values returned to the control levels

TABLE I
THE EFFECT OF CAR TREATMENT ON SERUM AMYLASE AND LIPASE LEVELS
IN CERULEIN-INDUCED AP

Groups	Amylase (U/L) Mean±SD	Lipase (U/L) Mean±SD
Control	505.85 ± 19.98 ^a	23.52 ± 1.20 ^{a,b}
AP	2366.56 ± 443.51 ^{*d}	126.33 ± 9.38 ^{*d}
CAR 50mg/kg	517.64 ± 26.01 ^a	24.01 ± 1.67 ^{a,b}
CAR 100mg/kg	492.29 ± 35.25 ^a	22.67 ± 2.03 ^a
CAR 200mg/kg	498.38 ± 22.85 ^a	23.89 ± 0.96 ^{a,b}
AP+CAR 50mg/kg	1334.43 ± 291.25 ^{*b,c}	92.40 ± 11.40 ^{*c}
AP+CAR 100mg/kg	709.68 ± 41.69 ^{a,b}	39.14 ± 3.47 ^b
AP+CAR 200mg/kg	1739.51 ± 367.98 ^{*c,d}	110.27 ± 5.82 ^{*d}

Notes: Data are presented as means ± SD (n=7). *Symbol < 0.05 represents significant difference among the groups compared to controls. a, b, c, d The groups in the same column with different letters are statistically significant (p < 0.05). Abbreviations used: AP: Acute pancreatitis; CAR: Carvacrol

Representative images of histological examination of lung tissue in different groups of rats are presented in figures. In

H&E stains in comparison to the controls (Fig. 1), the microscopic observations of lung in AP rats showed leukocyte infiltration, hemorrhage, marked alveolar thickening, congestion, smooth muscle hypertrophy, increased fibrosis and desquamated epithelial cells in bronchial lumina (Figs. 2 (a)-(d)), (Figs. 3 (a)-(d)).

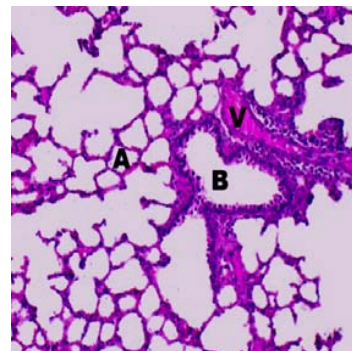


Fig. 1 Light microscopic appearances of lung from control rats. Alveoli (A), Bronchial (B), Vessel (V), (H&E)

TABLE II
EFFECT OF CAR TREATMENT ON LUNG SOD, CAT, GSH-PX ACTIVITIES AND MDA LEVELS IN CERULEIN-INDUCED AP

Groups	MDA (nmol/g) Mean±SD	SOD (U/g) Mean±SD	GSH-PX (U/mg-protein) Mean±SD	CAT (U/mg-protein) Mean±SD
Control	0.26 ± 0.08 ^a	221.40 ± 45.14 ^a	198.56 ± 32.25 ^a	2.36 ± 0.15 ^{a,b}
AP	0.82 ± 0.19 ^{*b}	102.24 ± 22.29 ^{*c}	86.79 ± 21.12 ^{*c}	0.74 ± 0.10 ^{*c}
CAR 50mg/kg	0.25 ± 0.07 ^a	207.16 ± 39.32 ^a	210.82 ± 44.31 ^a	2.43 ± 0.20 ^a
CAR 100mg/kg	0.23 ± 0.06 ^a	211.20 ± 51.22 ^a	201.53 ± 27.16 ^a	2.34 ± 0.23 ^{a,b}
CAR 200mg/kg	0.24 ± 0.09 ^a	215.21 ± 27.36 ^a	216.19 ± 35.27 ^a	2.48 ± 0.19 ^a
AP+CAR 50mg/kg	0.62 ± 0.17 ^{*b}	109.64 ± 19.51 ^{*c}	107.86 ± 22.65 ^{*b,c}	0.85 ± 0.09 ^c
AP+CAR 100mg/kg	0.27 ± 0.11 ^a	206.42 ± 31.42 ^a	194.72 ± 40.39 ^{*a,b}	2.22 ± 0.14 ^b
AP+CAR 200mg/kg	0.77 ± 0.16 ^{*b}	106.31 ± 25.54 ^{*c}	94.45 ± 19.53 ^{*c}	0.81 ± 0.11 ^{*c}

Notes: Data are presented as means ± SD (n=7). *Symbol < 0.05 represents significant difference among the groups compared to controls. a, b, c, d, e, f The groups in the same column with different letters are statistically significant (p < 0.05). For abbreviations see legend in Table I.

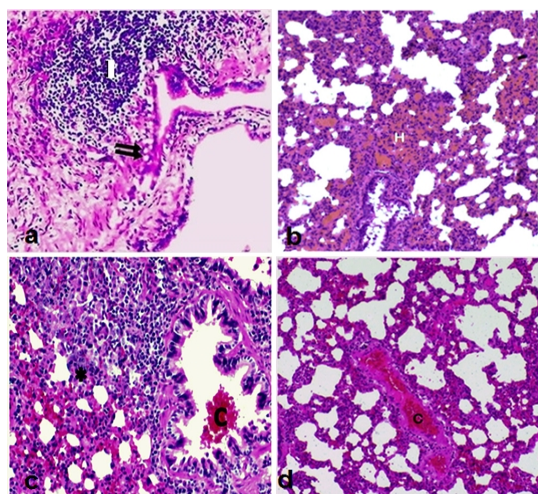


Fig. 2 The lung in the AP group (a) Vacuolisation (double arrow), Infiltration (I); (b) Diffuse haemorrhage in necrotic lung (H); (c) Congestion in bronchial (C), Prominent thickening of alveolar walls (asterisk symbol); (d) Congestion in vessel (C), (H&E)

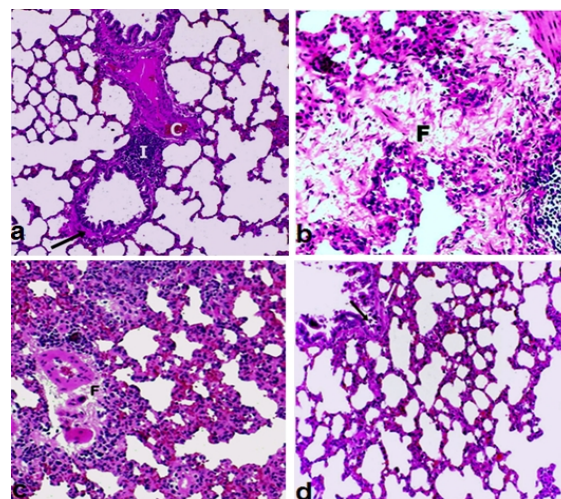


Fig. 3 The lung lesions in the AP group (a) Infiltration (I), Congestion (C), (b) Interstitial fibrosis (F), (c) Extensive fibrosis tissue around the blood vessels, (d) Desquamated epithelial cells (black arrow), Smooth muscle hypertrophy (white arrow), (H&E)

Compared with the control group, PAS staining revealed positive mucus-containing goblet cell hyperplasia and desquamated epithelial cells in bronchial sinus in lung of AP-induced rats (Figs. 4 (a)-(c)). Mallory trichrome showed increased intensity of fibrosis in bronchial and also interstitial fibrosis in animals with AP (Figs. 5 (a)-(d)). And the protein deposits in alveoli and alveolar septums were revealed by Amyloid staining method (Figs. 6 (a) and (b)).

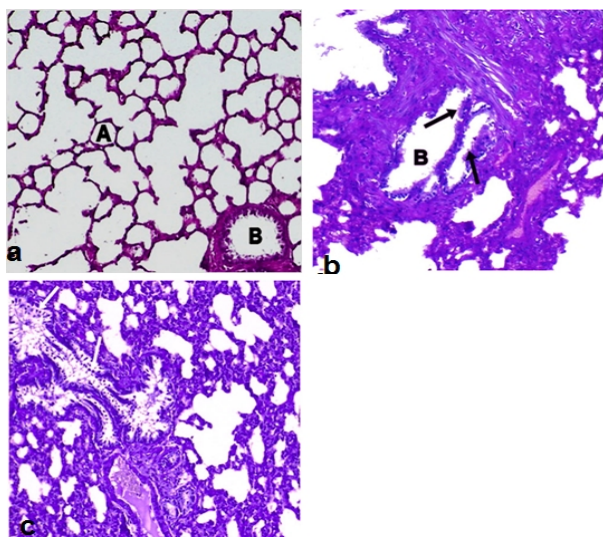


Fig. 4 The lung in control and AP rats (a) The lung in controls. The lung lesions in AP rats. Alveoli (A), (b) PAS positive mucus-containing goblet cells (black arrows), Bronchial (B), (c) Desquamated epithelial cells (white arrows), (PAS)

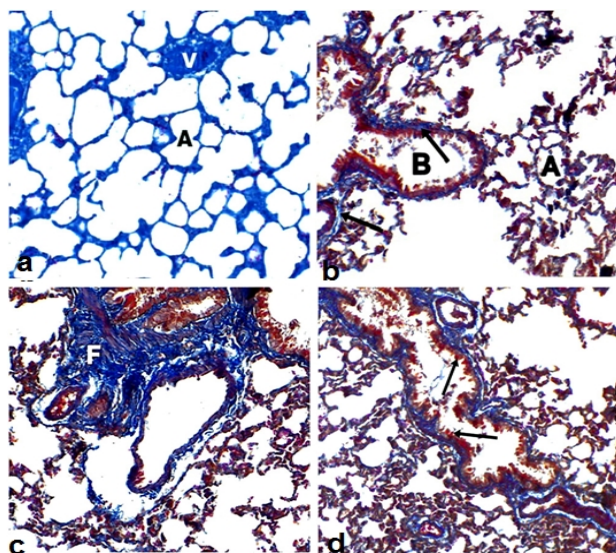


Fig. 5 The lung in control and AP rats (a) The lung in controls. The lung lesions in AP rats. Alveoli (A), Vessel (V), (b) Fibrosis tissue in bronchial walls (arrows), Bronchial (B), Alveoli (A); (c) Interstitial fibrosis (F); (d) PAS positive mucus-containing goblet cells (arrows), (Mallory trichrome)

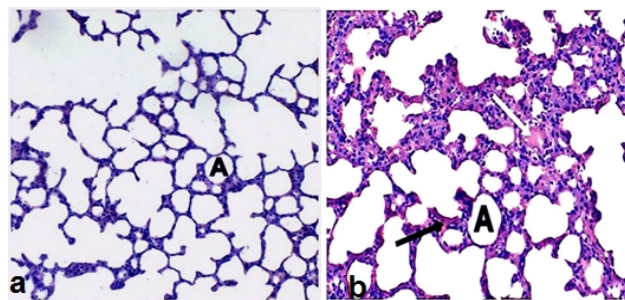


Fig. 6 The lung in control and AP rats. (a) The lung in controls. The lung lesions in AP rats. Alveoli (A), (b) The protein deposits in alveoli (white arrow) and alveoli septum (black arrow), Alveoli (A), (Amyloid)

Examination of lung sections in CAR groups revealed that the tissue retained its normal architecture (at 50, 100 and 200 mg/kg) (data not shown). In the 50 mg/kg CAR+AP groups, above-mentioned pathological findings were attenuated. There were reduction of hemorrhage and alveolar thickening. In lung of AP groups after treatment with 200 mg/kg CAR decreased congestion. However, in this group still had higher hemorrhage than those in the first. In 100 mg/kg CAR doses, the lung tissue showed a normal structure and orderly arrangement and resembled those of control rats (Figs. 7 (a)-(c)). As a matter of fact, PAS positive mucus-containing goblet cell hyperplasia and desquamated epithelial cells were not observed. Also, fibrosis and abnormal protein accumulations in tissue did not occur (Figs. 8 (a)-(c)).

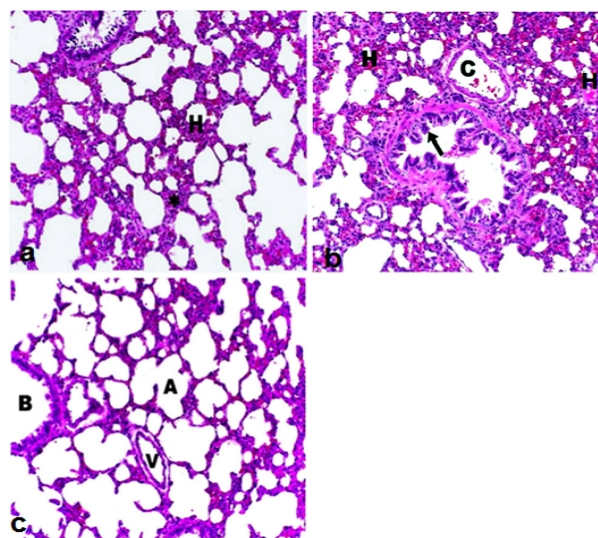


Fig. 7 The lung tissue following CAR exposure in AP rats (a) Reduction of haemorrhage and decreased alveolar thickening in AP+50 mg/kg CAR group, (b) The use of 200 mg/kg CAR decreased congestion, but AP+200 mg/kg CAR group showed more haemorrhage than AP+500 mg/kg CAR group. Branchial epithelial cells (black arrow), Diffuse haemorrhage in necrotic lung (H), Congestion in bronchial (C), (c) In AP+100 mg/kg CAR group, normal lung tissue. Alveoli (A), Bronchial (B), Vessel (V), (H&E)

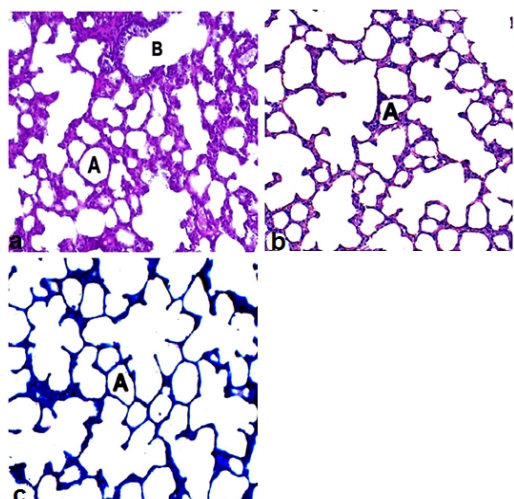


Fig. 8 The lung in AP+100 mg/kg CAR group was almost similar to that in control group (a) Alveoli (A), Bronchial (B), PAS, (b) Alveoli (A), Mallory trichrome, (c) Alveoli (A), Amyloid

Histopathological scores of the groups were summarized in Table III. The degree of pathological findings showed a significant difference between groups treated with cerulein and cerulein+CAR ($p < 0.05$).

TABLE III
HISTOPATHOLOGICAL SCORES OF LUNG IN CERULEIN-INDUCED AP

Groups	Lung necrosis (maximum score 18) Mean \pm SD	Infiltration (maximum score 3) Mean \pm SD	Alveolar Thickening (maksimum score 3) Mean \pm SD	Fibrosis (maximum score 3) Mean \pm SD	Congestion (maximum score 3) Mean \pm SD
Control	1.6 \pm 1.737 ^a	0.400 \pm 0.516 ^a	0.900 \pm 0.738 ^a	0.00 \pm 0.00 ^a	0.300 \pm 0.483 ^a
AP	5.94 \pm 0.77 ^c	1.37 \pm 0.15 ^c	1.94 \pm 0.11 ^c	0.7 \pm 0.16 ^c	0.8 \pm 0.18 ^c
CAR 50mg/kg	1.269 \pm 0.419 ^a	0.289 \pm 0.13 ^a	0.72 \pm 0.047 ^a	0.02 \pm 0.01 ^a	0.21 \pm 0.212 ^a
CAR 100mg/kg	1.444 \pm 1.4 ^a	0.364 \pm 0.42 ^a	0.80 \pm 0.548 ^a	0.01 \pm 0.01 ^a	0.27 \pm 0.412 ^a
CAR 200mg/kg	1.338 \pm 0.682 ^a	0.468 \pm 0.34 ^a	0.64 \pm 0.154 ^a	0.04 \pm 0.01 ^a	0.18 \pm 0.168 ^a
AP+CAR 50mg/kg	3.29 \pm 0.64 ^b	0.92 \pm 0.10 ^b	1.19 \pm 0.12 ^b	0.21 \pm 0.11 ^b	0.39 \pm 0.21 ^b
AP+CAR 100mg/kg	1.57 \pm 0.81 ^a	0.13 \pm 0.04 ^a	1.02 \pm 0.13 ^a	0.05 \pm 0.14 ^a	0.33 \pm 0.37 ^a
AP+CAR 200mg/kg	2.43 \pm 0.22 ^{b,c}	1.05 \pm 0.08 ^{b,c}	0.36 \pm 0.02 ^{b,c}	0.38 \pm 0.02 ^{b,c}	0.03 \pm 0.08 ^{b,c}

Notes: Data are presented as means \pm SD (n=7). *Symbol < 0.05 represents significant difference among the groups compared to controls. a, b, c The groups in the same column with different letters are statistically significant ($p < 0.05$) by Tukey's multiple range tests. For abbreviations, see legend in Table I.

TABLE IV
EFFECT OF CAR TREATMENT ON LUNG 8-OH-dG LEVELS IN CERULEIN-INDUCED AP

Groups	8-OH-dG level (as pg/ml) Mean \pm SE
Control	1.06 \pm 0.09 ^a
AP	4.26 \pm 0.21 ^{*d}
CAR 50 mg/kg	0.91 \pm 0.09 ^a
CAR 100 mg/kg	1.03 \pm 0.17 ^a
CAR 200 mg/kg	1.08 \pm 0.11 ^a
AP+CAR 50 mg/kg	2.73 \pm 0.14 ^c
AP+CAR 100 mg/kg	1.78 \pm 0.13 ^b
AP+CAR 200 mg/kg	1.14 \pm 0.12 ^a

Notes: Data are presented as means \pm SD (n=7). *Symbol < 0.05 represents significant difference among the groups compared to controls. The groups in the same column with different letters are statistically significant ($p < 0.05$). For abbreviations see legend in Table I.

In the present study, we observed for the first time that inhibition of oxidative stress by use of CAR in the lung of rat

The levels of 8-OH-dG, a hallmark of oxidative stress-DNA base damage, were measured using an 8-OH-dG detection kit. There was no significant difference between the levels of 8-OH-dG in the control and all CAR treated groups (Table IV). On the contrary, the level of 8-OH-dG was significantly higher in AP as compared to control group. But treatment of CAR decreased the 8-OH-dG levels that were increased by cerulein-induced AP in a clear dose dependent manner.

IV. DISCUSSION

The most feared complication in AP is lung failure [23]. Although the exact mechanisms remain elusive, it has been reported that oxidative stress plays an important role in promoting lung damage in AP. An improved understanding of the oxidative stress mechanism operating in the lung is necessary for the development of new therapies against tissue damage in AP [24], [25]. This study documents a fundamental role of oxidative stress in the pathophysiology of AP. Inhibition of oxidative stress decreased ROS formation, leukocyte recruitment, and tissue damage in the lung. Thus, targeting oxidative stress might protect against pathological inflammation in AP.

exposed to cerulein. As mentioned earlier, a cerulein-stimulated rat model has broadly been used as an experimental model of oxidative stress organ damage, therefore we employed an AP animal model instead of using human tissue in this study, as human tissue is extremely difficult to obtain. In this model, cerulein causes lung complications with extensive lipid peroxidation, producing some metabolites such as MDA. Hence cerulein can induce systemic diseases in organs such as the pancreas, heart, kidneys, liver, and lung as well [26], [27]. In our study, lipid peroxidation was elevated in the lung of rat after exposure to cerulein, as evidenced by increased MDA production. MDA is a highly biologically active oxidative degradation product from membrane unsaturated fatty acids. As such, MDA serves as a reliable biomarker of lipid peroxidation [28]. We also analyzed the correlation of oxidative stress with the pathological lung changes and the level of the antioxidant enzymes. Here in, we

demonstrated that administration of CAR reduced levels of MDA and the activity of antioxidant enzymes significantly increased in lung of animals exposed to cerulein. Essential oils rich in CAR possess strong antioxidant properties and also increase the activity of endogenous antioxidants [29], [30]. Antioxidants are ubiquitously expressed in mammalian cells and activation of enzymes such as SOD, CAT and GSH-PX promote cell defense [31]-[34]. A recent study reports that CAR prevents lipid peroxidation, cell damage, and protects the antioxidant system in tissue that also may support the results of the present study [35].

We also diagnosed AP by histopathological examination. The lung specimens of AP groups showed histopathological alterations such as leukocyte infiltration desquamated epithelial cells in bronchial lumina, congestion, hemorrhage, protein leakage, marked alveolar thickening and increased fibrosis [36]. We observed all of these histopathological alterations in our experimental AP model. As discussed below, we demonstrate that pathological changes are significantly attenuated by administration of CAR.

The AP-induced inflammatory response often causes acute lung injury with a mortality rate of up to 40% [37]. Considered together, our findings add AP to the growing list of inflammatory diseases in which ROS inhibition appears to be of beneficial value. In the present study, we found that cerulein enhanced the number of extravascular leukocyte in the lung. Convincing data have documented a key role of leukocytes in the induction of AP. For example, depletion of leukocytes markedly decreases tissue damage in AP [38]. Considering the tight relationship between leukocyte recruitment and tissue damage in AP, it is suggested that this potent inhibitory effect on infiltration at least partly help explain the protective effect of CAR in the inflamed lung.

Our presented data demonstrate that AP enhances amylase and lipase concentration in blood and also leads to major cell degenerations in the lung epithelium. The pulmonary inflammation causes lung injury, which is often characterized by apoptosis of lung epithelial cells [39], [40]. Also, the acute lung injury occurs as a consequence of markedly increased endothelial and epithelial permeability, with protein deposits into the vessels and interstitial tissues, leading to decreased gas exchange. Hence AP is closely associated with acute lung injury [37], [41]. In our study, CAR effectively prevents the leakage of protein in rats with pancreatitis. It is reported that CAR protects the cells against H_2O_2 -induced cytotoxicity and membrane damage [42]. On the other hand, AP causes acute thrombus formation in the vessels of rat lung as previously reported, and congestion in the vessels is the histopathological event that preceded thrombus formation. Besides, hemorrhage is observed in the interalveolar septa as extravasated erythrocytes accompanied with congestion [37], [43]. *In vitro* studies reveal that CAR possesses therapeutic characteristic, including antithrombotic property, in both lung and breast tissues [44]. Thus, CAR in the present study does not increase, but reduces the risk for congestion in animals with AP.

The excessive collagen production results in fibrosis and thickening of alveolar septa associated with poor elasticity and

exchange of respiratory gases [45]. The development of therapeutic strategies compels a better understanding of the cellular and molecular mechanisms of fibrosis, which are diverse, complex, and redundant. Although there is growing evidence that oxidative stress is related to advanced lung fibrosis, the pathophysiological mechanisms still need to be defined [46]. In this context, we think that oxidative stress mechanism in AP, by directly inducing fibrotic processes, could possibly play a significant role in the eventual outcome. It has been documented that elevated oxidative stress and diminished antioxidant defense induced pulmonary fibrosis [47]. Experimental studies on CAR have confirmed its beneficial effects on cellular immunity to oxidative stress, reduction of fibrosis, suppression of inflammation, regulation of metabolism [48]. It has been shown that CAR regulates collagen expression in fibrosis and that CAR supplementation provides significant protection against oxidative stress-mediated complications and strengthens antioxidant defenses [27], [49]. Therefore, the activation of CAR may become a therapeutic target to improve the clinical outcome of lung diseases.

Although the number of studies on genotoxic effects of CAR is still limited, the available data discussed that the use of CAR does not pose a risk to the consumer. Regarding the safety of CAR, our findings shown that 8-OH-guanine formations were not detected at all CAR concentrations tested. In previous studies, the genotoxic potential of CAR has been suggested to be weak in the DNA-repair test and the SOS-chromotest [50] and contradictory results have been reported with the Ames mutagenicity assay [51]. On the other hand, CAR seemed to protect against peroxide and mutagen-induced DNA damage in human lymphocytes [52], [53].

8-OH-guanine has been used widely for the detection of oxidative DNA base damage [54]. In our experimental study, AP induced 8-OH-guanine formations in pulmonary cells. However, CAR showed antioxidant activity and decreased 8-OH-guanine production. The effect of CAR was not concentration depended and the effects on different parameters significantly increased with 100 mg/kg concentration of CAR. The effects of higher concentration of CAR (200 mg/kg) on all measured parameters were lower than its two lower concentrations. Incubation of mammalian cells in the presence of the whole scale of concentrations of CAR led to a significant protection of the cells studied toward DNA strand breaks induced by a potent oxidant hydrogen peroxide [55]. A study indicated a lack of clastogenic activity for CAR at biologically relevant concentrations, and a moderate antioxidant activity *in vitro* [56]. However, if the use of CAR compounds is extended to other applications that may require higher doses, the increased exposure of humans to this compound is a matter of concern [57]. Hence the concentration dependent effects of CAR are discussed [45]. At this point, we think that comprehensive studies are needed before CAR is used for the clinical application.

To the best of our knowledge, this is the first study reporting that CAR is useful in preventing AP-induced lung injury by attenuating oxidative stress and inflammation. These

results are supported by biochemical and genotoxicity studies, and also histopathological observations. Our *in vivo* data show that 100 mg/kg CAR can be considered potential candidate for the treatment of lung in AP.

ACKNOWLEDGEMENTS

Atatürk University (BAP-2012/167) supported this investigation.

A. Conflict of Interest Statement

The authors declare that there is no conflict of interest.

REFERENCES

- [1] Zechner D, Spitzner M, Muller-Graff T, Vollmar B (2014) Diabetes increases pancreatitis induced systemic inflammation but has little effect on inflammation and cell death in the lung. *International Journal of Experimental Pathology* 95:411-417 doi:10.1111/iep.12103.
- [2] Bhatia M (2002) Novel therapeutic targets for acute pancreatitis and associated multiple organ dysfunction syndrome *Current Drug Targets Inflammation and Allergy* 1:343-351.
- [3] Closa D (2015) Commentary on "Pancreatic ascites hemoglobin contributes to the systemic response in acute pancreatitis". *Free Radical Biology & Medicine* 81:156-157 doi:10.1016/j.freeradbiomed.2014.09.029.
- [4] Wang G, Chen HL, Ren F, Li J, Li YQ (2010) Expression of Cav-1, AQP1 and AQP5 in lung of acute pancreatitis-associated lung injury rats and the therapeutic role of Qingyi Tang. *Zhonghua yi xue za zhi* 90:2564-2569.
- [5] Brueckl C, Kaestle S, Kerem A, Habazettl H, Krombach F, Kuppe H, Kuebler WM (2006) Hyperoxia-induced reactive oxygen species formation in pulmonary capillary endothelial cells in situ. *American Journal of Respiratory Cell and Molecular Biology* 34:453-463 doi:10.1165/rcmb.2005-0223OC.
- [6] Aydın E, Türkez H (2013) In vitro cytotoxicity, genotoxicity and antioxidant potentials of thymol on human blood cells. *Journal of Essential Oil Research* 26:133-140 doi:10.1080/10412905.2013.860411.
- [7] Türkez H, Toğar B, Çelik K (2014) In vitro study of human lymphocytes cytological and biochemical effects by zingiberene. *Journal of Essential Oil Research* 26:367-371.
- [8] Aydın E, Türkez H, Keleş MS (2014) The effect of carvacrol on healthy neurons and N2a cancer cells: some biochemical, anticarcinogenicity and genotoxicity studies. *Cytotechnology* 66:149-157.
- [9] Sobral MV, Xavier AL, Lima TC, de Sousa DP (2014) Antitumor activity of monoterpenes found in essential oils. *The Scientific World Journal* 2014.
- [10] Şen HS et al. (2014) Carvacrol and pomegranate extract in treating methotrexate-induced lung oxidative injury in rats. *Medical Science Monitor: International Medical Journal of Experimental and Clinical Research* 20:1983.
- [11] Abdollahi A, Hassani A, Ghosta Y, Bernousi I, Meshkatsadat MH, Shabani R, Ziaee SM (2012) Evaluation of essential oils for maintaining postharvest quality of Thompson seedless table grape. *Natural Product Research* 26:77-83.
- [12] Gilling D, Kitajima M, Torrey J, Bright K (2014) Antiviral efficacy and mechanisms of action of oregano essential oil and its primary component carvacrol against murine norovirus. *Journal of Applied Microbiology* 116:1149-1163.
- [13] Horvathova E et al. (2014) Assessment of antioxidative, chelating, and DNA-protective effects of selected essential oil components (Eugenol, Carvacrol, Thymol, Borneol, Eucalyptol) of Plants and Intact Rosmarinus officinalis oil. *Journal of Agricultural and Food Chemistry* 62:6632-6639.
- [14] Bhatia M, Wong FL, Fu D, Lau HY, Mochhala SM, Moore PK (2005) Role of hydrogen sulfide in acute pancreatitis and associated lung injury. *The FASEB Journal* 19:623-625.
- [15] Hagiwara S, Iwasaka H, Uchida T, Hasegawa A, Asai N, Noguchi T (2009) Danaparoid sodium prevents cerulein-induced acute pancreatitis in rats. *Shock (Augusta, Ga)* 32:94-99 doi:10.1097/SHK.0b013e31818ec2c2
- [16] Hailong Yu, Zeng-Li Zhang, Jing Chen, Aijie Pei, Fang Hua, Xuanchen Qian, Jinjiang He, Chun-Feng Liu, Xingshun Xu (2012) Carvacrol, a food-additive, provides neuroprotection on focal cerebral ischemia/reperfusion injury in mice. *PLoS One* 7:e33584
- [17] Flohe L (1984) [10] Superoxide dismutase assays *Methods in Enzymology* 105:93-104
- [18] Aebi H (1984) Catalase in vitro. *Methods Enzymol* 105:121-126
- [19] Schoenberg MH, Buchler M, Beger HG (1994) Oxygen radicals in experimental acute pancreatitis. *Hepato-Gastroenterology* 41:313-319
- [20] Schoenberg MH et al. (1990) Oxygen free radicals in acute pancreatitis of the rat. *Gut* 31:1138-1143
- [21] Alkan M et al. (2015) The effect of levosimendan on lung damage after myocardial ischemia reperfusion in rats in which experimental diabetes was induced. *The Journal of Surgical Research* 193:920-925 doi:10.1016/j.jss.2014.08.038
- [22] Ashcroft T, Simpson JM, Timbrell V (1988) Simple method of estimating severity of pulmonary fibrosis on a numerical scale. *Journal of Clinical Pathology* 41:467-470
- [23] Qu Z, Jiang Y, Wu BQ, Duan YF, Sun ZD, Luo GH (2014) Cystathionine-gamma-lyase inhibitor attenuates acute lung injury induced by acute pancreatitis in rats. *Archives of Medical Science : AMS* 10:825-829 doi:10.5114/aoms.2014.44873
- [24] Luan ZG, Zhang J, Yin XH, Ma XC, Guo RX (2013) Ethyl pyruvate significantly inhibits tumour necrosis factor- α , interleukin-1 β and high mobility group box 1 releasing and attenuates sodium taurocholate-induced severe acute pancreatitis associated with acute lung injury. *Clinical and Experimental Immunology* 172:417-426 doi:10.1111/cei.12062
- [25] Hong Zhang, Patrick Neuhöfer, Liang Song, Björn Rabe, Marina Lesina, Magdalena U. Kurkowski, Matthias Treiber, Thomas Wartmann, Sara Regnér, Henrik Thorlacius, Dieter Saur, Gregor Weirich, Akihiko Yoshimura, Walter Halangk, Joseph P. Mizgerd, Roland M. Schmid, Stefan Rose-John, and Hana Algül (2013) IL-6 trans-signaling promotes pancreatitis-associated lung injury and lethality *The Journal of Clinical Investigation* 123:1019-1031 doi:10.1172/jci64931
- [26] Korkmaz T, Kahramansoy N, Kilicgun A, Firat T (2014) The effect of erythropoietin to pulmonary injury and mast cells secondary to acute pancreatitis. *BMC Research Notes* 7:267 doi:10.1186/1756-0500-7-267
- [27] Lee JS, Owshalimpur D, Schofield C (2012) Trimethoprim/sulfamethoxazole induced multiorgan dysfunction. *BMJ Case Reports* 2012 doi:10.1136/bcr-2012-007460
- [28] Li Y, Fu J, Yuan X, Hu C (2014) Simvastatin inhibits the proliferation of A549 lung cancer cells through oxidative stress and up-regulation of SOD2. *Die Pharmazie* 69:610-614
- [29] Aeschbach R, Löliger J, Scott B, Murcia A, Butler J, Halliwell B, Aruoma O (1994) Antioxidant actions of thymol, carvacrol, 6-gingerol, zingerone and hydroxytyrosol. *Food and Chemical Toxicology* 32:31-36
- [30] Lee KG, Shibamoto T (2002) Determination of antioxidant potential of volatile extracts isolated from various herbs and spices. *Journal of Agricultural and Food Chemistry* 50:4947-4952
- [31] Geyikoglu F, Türkez H (2008) Boron compounds reduce vanadium tetroxide genotoxicity in human lymphocytes. *Environmental Toxicology and Pharmacology* 26:342-347
- [32] Geyikoglu F, Türkez H (2005) Protective effect of sodium selenite on genotoxicity to human whole blood cultures induced by aflatoxin B1. *Brazilian Archives of Biology and Technology* 48:905-910
- [33] Sies H (2015) Oxidative stress: a concept in redox biology and medicine. *Redox biology*
- [34] Türkez H, Toğar B (2010) The genotoxic and oxidative damage potential of olanzapine in vitro. *Toxicology and Industrial Health* 26:583-588
- [35] Mahtaj LG, Feizpour A, Kianmehr M, Soukhtanloo M, Boskabady MH (2015) The effect of carvacrol on systemic inflammation in guinea pigs model of COPD induced by cigarette smoke exposure. *Pharmacological Reports : PR* 67:140-145 doi:10.1016/j.pharep.2014.08.017
- [36] Weng TI, Wu HY, Chen BL, Jhuang JY, Huang KH, Chiang CK, Liu SH (2013) C/EBP homologous protein deficiency aggravates acute pancreatitis and associated lung injury. *World Journal of Gastroenterology : WJG* 19:7097-7105 doi:10.3748/wjg.v19.i41.7097
- [37] Zhou MT, Chen CS, Chen BC, Zhang QY, Andersson R (2010) Acute lung injury and ARDS in acute pancreatitis: mechanisms and potential intervention. *World Journal of Gastroenterology : WJG* 16:2094-2099
- [38] Abdulla A, Awla D, Thorlacius H, Regner S (2011) Role of neutrophils in the activation of trypsinogen in severe acute pancreatitis. *Journal of Leukocyte Biology* 90:975-982 doi:10.1189/jlb.0411195
- [39] Nakamura H, Honda H, Tashiro M, Taguchi M, Yoshikawa H, Otsuki M (2003) Increased expression of 19-kD interacting protein-3-like protein

- and the relationship to apoptosis in the lung of rats with severe acute pancreatitis. *Critical Care Medicine* 31:2527-2534
- [40] Yuan YZ, Gong ZH, Lou KX, Tu SP, Zhai ZK, Xu JY (2000) Involvement of apoptosis of alveolar epithelial cells in acute pancreatitis-associated lung injury *World Journal of Gastroenterology* 6:920-924
- [41] Shields CJ, Winter DC, Redmond HP (2002) Lung injury in acute pancreatitis: mechanisms, prevention and therapy. *Current Opinion in Critical Care* 8:158-163
- [42] Ozkan A, Erdogan A (2012) A comparative study of the antioxidant/prooxidant effects of carvacrol and thymol at various concentrations on membrane and DNA of parental and drug resistant H1299 cells. *Natural Product Communications* 7:1557-1560
- [43] Macit E et al. (2013) The protective effect of melatonin and S-methylisothiourea treatments in nitrogen mustard induced lung toxicity in rats. *Environmental Toxicology and Pharmacology* 36:1283-1290
- [44] Edris AE (2007) Pharmaceutical and therapeutic potentials of essential oils and their individual volatile constituents: a review. *Phytotherapy Research* 21:308-323
- [45] Grewal K, Sandhu G, Kaur R, Brar R, Sandhu H (2010) Toxic impacts of cypermethrin on behavior and histology of certain tissues of albino rats. *Toxicology international* 17:94
- [46] Luzina IG, Todd NW, Sundararajan S, Atamas SP (2014) The cytokines of pulmonary fibrosis: Much learned, much more to learn. *Cytokine*
- [47] Molina-Molina M et al. (2006) Losartan attenuates bleomycin induced lung fibrosis by increasing prostaglandin E2 synthesis. *Thorax* 61:604-610
- [48] Walter B, Bilkei G (2004) Immunostimulatory effect of dietary oregano etheric oils on lymphocytes from growth-retarded, low-weight growing-finishing pigs and productivity. *Tijdschrift Voor Diergeneeskunde* 129:178-181
- [49] Karkabounasli S, Metsios A, Lekkas P, Kotsis N, Skoufos I (2006) Anticarcinogenic and antiplatelet effects of carvacrol. *Experimental Oncology* 28:000-000
- [50] Stamatii A, Bonsi P, Zucco F, Moezelaar R, Alakomi H-L, Von Wright A (1999) Toxicity of selected plant volatiles in microbial and mammalian short-term assays. *Food and Chemical Toxicology* 37:813-823
- [51] Azizan A, Blevins R (1995) Mutagenicity and antimutagenicity testing of six chemicals associated with the pungent properties of specific spices as revealed by the Ames Salmonella/microsomal assay. *Archives of Environmental Contamination and Toxicology* 28:248-258
- [52] Aydin S, Basaran AA, Basaran N (2005) Modulating effects of thyme and its major ingredients on oxidative DNA damage in human lymphocytes. *Journal of Agricultural and Food Chemistry* 53:1299-1305
- [53] Aydin S, Başaran AA, Başaran N (2005) The effects of thyme volatiles on the induction of DNA damage by the heterocyclic amine IQ and mitomycin C. *Mutation Research/Genetic Toxicology and Environmental Mutagenesis* 581:43-53
- [54] Albertini RJ et al. (2000) IPCS guidelines for the monitoring of genotoxic effects of carcinogens in humans. *Mutation Research/Reviews in Mutation Research* 463:111-172
- [55] Slamenova D, Horvathova E, Sramkova M, Marsalkova L (2006) DNA-protective effects of two components of essential plant oils carvacrol and thymol on mammalian cells cultured in vitro. *Neoplasma* 54:108-112
- [56] Undeger U, Basaran A, Degen GH, Basaran N (2009) Antioxidant activities of major thyme ingredients and lack of (oxidative) DNA damage in V79 Chinese hamster lung fibroblast cells at low levels of carvacrol and thymol. *Food and Chemical Toxicology : an International Journal Published for the British Industrial Biological Research Association* 47:2037-2043 doi:10.1016/j.fct.2009.05.020
- [57] Domaracký M, Rehak P, Juhás Š, Koppel J (2007) Effects of selected plant essential oils on the growth and development of mouse preimplantation embryos in vivo. *Physiol Res* 56:97-104