

Protective Effect of L-Carnitine against Gentamicin-Induced Nephrotoxicity in Rats

Mohamed F. Ahmed, Mabruka S. Elashheb, Fatma M. Ben Rabha

Abstract—This study aimed to determine the possible protective effects of L-carnitine against gentamicin-induced nephrotoxicity. Forty male albino rats were divided into 4 groups (10 rats each); Group 1: normal control, group 2: induced nephrotoxicity (gentamicin 50 mg/kg/day S.C; 8 days), group 3: treated with L-carnitine (40 mg/kg/d SC for 12 days) and group 4: treated with L-carnitine 4 days before and for 8 days in concomitant with gentamicin. Gentamicin-induced nephrotoxicity (group 2): caused significant increase in serum urea, creatinine, urinary N-acetyl-B-D-glucosaminidase (NAG), gamma glutamyl transpeptidase (GGT), urinary total protein and kidney tissue malondialdehyde (MDA) with significant decrease in serum superoxide dismutase (SOD), serum catalase and creatinine clearance and marked tubular necrosis in the proximal convoluted tubules with interruption in the basement membrane around the necrotic tubule compared to the normal control group. L-carnitine 4 days before and for 8 days in concomitant with gentamicin (group 4) offered marked decrease in serum urea, serum creatinine, urinary NAG, urinary GGT, urinary proteins and kidney tissue MDA, with marked increase in serum SOD, serum catalase and creatinine clearance with marked improvement in the tubular damage compared to gentamicin-induced nephrotoxicity group. L-carnitine administered for 12 days produced no change in the parameters mentioned above as compared to the normal control group. In conclusion: L-carnitine could reduce most of the biochemical parameters and also improve the histopathological features of kidney associated with gentamicin induced-nephrotoxicity.

Keywords—Gentamicin, kidney disease, L-carnitine, nephrotoxicity.

I. INTRODUCTION

GENTAMICIN is an aminoglycoside antibiotic routinely used in everyday clinical practice for the treatment of gram-negative infections alone or in synergy with beta-lactam antibiotics. In addition to clinical effectiveness, a low rate of resistance and reasonable cost recommend gentamicin as the first line antibiotic for many severe and life-threatening diseases. However, its frequent use is limited by a risk of serious side-effects such as nephrotoxicity and ototoxicity. Incidence rates of gentamicin nephrotoxicity reported in some studies vary between 8% and 26% [33].

Gentamicin-induced nephrotoxicity is characterized by morphological alterations including destruction of cell organelles and necrosis, lysosomal swelling and mitochondrial vacuolation preceding functional alterations marked by proteinuria, increased levels of serum urea and creatinine, which lead to acute kidney injury. The tendency site of gentamicin nephrotoxic action is kidney cortex, especially

proximal tubules. Although the exact intracellular mechanisms of gentamicin nephrotoxicity are not fully clear, it occurs after uptake into proximal tubular cells and accumulation in lysosomes. Cellular uptake of gentamicin seems to be saturable at serum trough levels obtained with a usual regimen of dosing. Elevated serum trough levels prolong the time of gentamicin uptake thus increasing its concentration in the cell and the consequent nephrotoxicity [5], [37]. Accordingly, [40] suggested that single daily dosing, regardless of the total daily dose, reduces but not eliminates gentamicin-associated kidney damage compared to multiple dosing.

Several studies implicated involvement of reactive oxygen species (ROS) in gentamicin-induced kidney injury. ROS directly act on cell components, including lipids, proteins, and DNA, destroying their structure. Peroxidation of membrane lipids during oxidative stress induces the fragmentation of polyunsaturated fatty acids and release of various aldehydes and alkenes [15]. It is shown that gentamicin can intensify the formation and release of oxygen-derived free radicals by renal cortical mitochondria, thus, resulting in simultaneous mesangial proliferation and apoptosis in rats [25]. Produced free radicals destroy the glomerular basement membrane, disturb the tubule function, and degrade the collagen and other matrix components. Although various agents were used simultaneously with gentamicin in order to prevent or ameliorate kidney injury associated with its application [21], [29], [31], there is no specific treatment to reliably protect against gentamicin-induced nephrotoxicity.

L-Carnitine (4- N- trimethyl ammonium -3-hydroxybutyric acid), L-lysine derivative, is an endogenous mitochondrial membrane compound. The main physical function of L-carnitine in the human body is facilitating or transport of long-chain fatty acids into mitochondria to enter the B-oxidation cycle. Used as a safe and effective nutritional supplement for more than three decades, the protective effect of L-carnitine on kidney tissue has been proved in various models involving oxidative stress, such as cisplatin-induced injury of the kidney and small intestine, gentamicin-induced nephrotoxicity, ischaemia- reperfusion injury of the kidney and chronic renal failure. It has been demonstrated that L-carnitine administration inhibits both serum and kidney tissue MDA formation in response to renal ischaemia/reperfusion injury [26]. This study aimed to investigate the protective effects of L-carnitine against gentamicin-induced nephrotoxicity through biochemical markers and histopathological evaluation in rats.

II. MATERIAL AND METHODS

The drugs that are used, are listed below:

Assoc. Prof. Dr. Mabruka Elashheb is with the Tripoli University, Medical School, Libya (e-mail: m_elashheb@yahoo.com).

1. Gentamicin sulphate (Rifobacin) 40 mg/ml ampoule, Merk, Germany.
2. L-carnitine (Carnitol) 300 mg cap. (Global Napi Pharmaceuticals, Egypt), was prepared as a solution in dimethyl sulfoxide (DMSO).
3. All other chemicals were supplied from Sigma-Aldrich Company.

III. ANIMALS AND PROCEDURES

This study was carried out on 40 male albino rats weighing of (180-200 grams). They were handled in accordance with the guidelines principles in the use of animals and provided with food and water ad libitum throughout the period of the work. The rats were divided into four groups (each of 10 rats) as follows ; group 1: served as normal control group and received DMSO once daily by SC injection for 12 days with an additional daily SC injection of distilled water for the last 8 days, group 2: received gentamicin in a dose of 50 mg/kg/day SC injection for 8 days [10] and injected with DMSO for 12 days, starting 4 days before the gentamicin injection (GM group), group 3: received L-carnitine in a dose of 40 mg/kg/d by SC injection for 12 days [21] and with SC injection of distilled water for the last 8 days (L-CAR group) and group 4: received L-carnitine in a dose of 40 mg/kg/d by SC injection for 4 days before gentamicin injection and for 8 days in concomitant with gentamicin injection (GM + L-CAR group) [21].

At the end of experimental period, 24 h after the last gentamicin injection, rats were subjected to the following procedures: renal blood flow velocity and renal vascular resistance were measured by pulsed blood flowmeter (Doppler) [16]. Blood samples were collected by the retro-orbital methods for measurement of blood urea nitrogen (BUN) [13], serum creatinine [4], serum catalase (CAT) [8] and superoxide dismutase (SOD) [23].

Twenty-four hour urine samples were collected for measurement of urinary N-acetyl-B-D-glucosaminidase (NAG) [20], urinary Gamma-glutamyl transpeptidase (GGT) [41], creatinine [4] and total protein [27]. Creatinine clearance (CrCl) was measured by using serum and urinary creatinine and the collected 24 hours urine samples according to the equation of Cockcroft and Gault [9]:

$$\text{CrCl (ml/min)} = \frac{\text{urine creatinine mg/dl} \times 24 \text{ hours urine volume (ml)}}{1440 \times \text{serum creatinine mg/dl}}$$

Rats were sacrificed by decapitation and both kidneys were excised, washed with ice-cold saline. One kidney was removed and fixed in 10% of neutral buffered formalin and embedded in paraffin and was stained with hematoxylin and eosin for histopathological analysis. Light microscopy was used to evaluate tubular necrosis that was graded as follows: Mild (+): only single cell necrosis and slight degenerative changes. Moderate (++) : tubular necrosis at different foci throughout the cortex. Severe (+++) : extensive and marked tubular necrosis throughout the cortex. The other kidney was

homogenized in Tris-HCl buffer (pH 7.4) using Ultra homogenizer. The homogenates were first centrifuged at 10,000 xg for 15 min and the supernatants were then centrifuged at 100,000xg for 1 hour. Supernatant was used for the determination of malondialdehyde (MDA) production from the thiobarbituric acid reaction in kidney homogenates [15]

IV. STATISTICAL ANALYSIS

All results were expressed as the mean \pm SD from ten rats per group. One way analysis of variance (ANOVA) followed by a Tukey's test was used to determine the significance of the differences between the groups. The Statistical significance was declared when P value was equal to or less than 0.05. The statistical analysis was performed using the Sigma State Statistical Software version 3.5.

V. RESULTS

A. Biochemical Results

Regarding functional parameters of the kidney (Table I) , it was found that gentamicin-induced nephrotoxicity (group 2) caused significant elevation in serum levels of urea (mg/dl) and creatinine (mg/dl) when compared to the normal control group (group 1) ; 84.8 ± 9.1 vs 31.8 ± 3.2 and 2.41 ± 0.010 vs 0.52 ± 0.003 , respectively. Also, it caused significant increase in urinary levels of NAG (U/mmol) , GGT (U/mg), total protein (mg/24h) and kidney tissue MDA ($\mu\text{mol/g}$ tissue) when compared to the normal control group; (group 1) ; 25.59 ± 4.42 vs 0.42 ± 0.08 ; 786 ± 31.8 vs 118 ± 11.4 ; 31.2 ± 1.61 vs 18.6 ± 0.9 and 89.1 ± 4.0 vs 61.9 ± 3.7 , respectively. However, it caused significant decrease in serum CAT (U/mg), SOD (U/mg) and creatinine clearance (ml/min) when compared to the normal control group (group 1); 16.2 ± 2.1 vs 28.1 ± 3.1 , 36.6 ± 6.0 vs 138 ± 11.4 and 0.08 ± 0.001 vs 0.52 ± 0.003 , respectively when compared to rats with normal control group (group 1). Treatment with L-carnitine (group 4) resulted in significant reduction in serum urea and creatinine to 32.6 ± 4.1 vs. 84.8 ± 9.1 ; 0.83 ± 0.008 vs. 2.41 ± 0.010 , respectively. Also, it caused significant reduction in urinary levels of NAG, GGT, total protein and kidney tissue MDA to 5.27 ± 0.12 vs 25.59 ± 4.42 ; 136 ± 1.2 vs 786 ± 31.8 ; 22.4 ± 2.1 vs 31.2 ± 1.61 and 63.4 ± 3.9 vs 89.1 ± 4.0 , respectively. However, it caused a significant increase in serum CAT, SOD and creatinine clearance to 23.8 ± 3.3 vs. 16.2 ± 2.1 ; 98.2 ± 6.2 vs. 36.6 ± 6.0 , and 0.46 ± 0.003 vs. 0.08 ± 0.001 , respectively. L-carnitine (group 3) resulted in an insignificant change in all biochemical parameters when compared to the normal control group.

B. Renal Haemodynamics Results

The renal vascular resistance (RP) in GM group (group 2) showed a significant increase to 1.97 ± 0.14 vs. 0.84 ± 0.03 when compared with the normal control group (group 1). However, the renal blood flow velocity (MV) showed a significant decrease to 4.40 ± 0.29 vs. 6.12 ± 0.26 when compared with the normal control group (group 1). However, treatment with L-CAR (group 4) showed significant decrease of (RP) to 0.92

± 0.01 and significant increase of (MV) to 5.48 ± 0.31 compared with the GM group (group 2) as shown in Table II. L-carnitine (group 3) showed no changes in the RP and MV parameters.

C. Histopathological Results

Light microscopic examination of H & E stained renal sections of normal control rats (group 1) revealed normal structural pattern of the proximal convoluted tubules with distinct brush border and narrow irregular lumen lined by cubical epithelial cells with strongly eosinophilic cytoplasm with boundaries and few regularly arranged vesicular rounded central nuclei in TS section. Few tubular epithelial cells showed focal cytoplasmic vacuolation (Fig. 1 (a)). However, examination of the renal cortex of rats received gentamicin (group 2) showed marked tubular necrosis, desquamated and

degenerated epithelial cells are visible in the lumina of necrotic tubules. Some of the tubular epithelial cells have large nuclei and the swelling cytoplasm, which is a result of oedema. Also, there was an interruption in the basement membrane around the necrotic tubules and narrowing of the Bowman's space. Distal tubules appeared almost normal and apoptotic body, picnotic nuclei are visible in the proximal tubules (Figs. 1 (b), (c), (f), and (g)). L-carnitine (group 3) showed nearly the same picture as these of group 1 (Fig. 1 (a)). However, Kidney sample from GM+L-CAR group (group 4) showing a marked reduction in tubular damage. Distal tubules appear normal while some of the proximal tubules show moderate intracellular oedema. Basement membrane appears orderly and continuous and narrowing of the Bowman's space is also evident (Fig. 1 (d) and (e)).

TABLE I
THE EFFECT OF L-CARNITINE ON BIOCHEMICAL PARAMETERS IN THE STUDIED GROUPS

Groups Parameters	N. Control Group 1	GM Group 2	L-CAR Group 3	GM+ L-CAR Group 4
Blood urea nitrogen (BUN) (mg/dl)	31.8 \pm 3.2	84.8 \pm 9.1	30.6 \pm 3.1	32.6 \pm 4.1
Creatinine (mg/dl)	0.52 \pm 0.003	2.41 \pm 0.010*	0.48 \pm 0.001	0.83 \pm 0.008
Serum catalase (CAT) (U/mg)	28.1 \pm 3.1	16.2 \pm 2.1*	30.8 \pm 2.8	23.8 \pm 3.3**
Superoxid dismutase (SOD) (U/mg)	138 \pm 11.4	36.6 \pm 6.0	136 \pm 3.3	98.2 \pm 6.2
Creatinine clearance (ml/min)	0.52 \pm 0.003	0.08 \pm 0.001*	0.51 \pm 0.004	0.46 \pm 0.003*
Urinary N-acetyl-B-D-glucosaminidase (NAG)(U/mmol)	0.42 \pm 0.08	25.59 \pm 4.42 *	0.43 \pm 0.06	5.27 \pm 0.12
Gamma glutamyl transpeptidase (GGT) (U/mg)	118 \pm 11.4	786 \pm 31.8*	116 \pm 14.2	136 \pm 1.2
Urinary total protein (mg/24h)	18.6 \pm 0.9	31.2 \pm 1.61*	16.6 \pm 2.1	22.4 \pm 2.1**
Malondialdehyde (MDA) (μ mol/g tissue)	61.9 \pm 3.7	89.1 \pm 4.0*	60.3 \pm 2.3	63.4 \pm 3.9**

The results are mean \pm SD for 10 rats in each group. * Significantly different from normal control group ** Significantly different from GM group

TABLE II
THE EFFECT OF L-CARNITINE TREATMENT ON RENAL BLOOD FLOW VELOCITY AND RENAL VASCULAR RESISTANCE IN THE STUDIED GROUPS

Group Parameters	Control Group 1	GM Group 2	L-CAR Group 3	GM+ L-CAR Group 4
MV (cm/sec)	6.12 \pm 0.26	4.40 \pm 0.29 *	5.25 \pm 0.24	5.48 \pm 0.31 **
RP	0.84 \pm 0.03	1.97 \pm 0.14 *	1.86 \pm 0.03	0.92 \pm 0.01 **

Data represented as mean \pm SD *Comparing the results of GM group with that of the control group. **Comparing results of GM+L-CAR with GM group. MV: Renal Blood Flow Velocity RP: Renal Vascular Resistance

TABLE III
HISTOLOGICAL KIDNEY RESULTS ON STUDIED GROUPS (N = NUMBER OF ANIMALS)

Groups	Grade of tubular necrosis			
	-	+	++	+++
N. Control (n=10)	10	0	0	0
Gentamicin (GM) (n=10)	0	0	2	8
L-carnitin (L-CAR) (n=10)	10	0	0	0
GM+L-CAR (n=10)	0	7	3	0

Light microscopy was used to evaluate tubular necrosis and was graded as follows: mild (+): only single cell necrosis and slight degenerative changes; moderate (++): tubular necrosis at different foci throughout the cortex; severe (+++): extensive and marked tubular necrosis throughout the cortex.

A represents Glomeruli and tubules have a normal appearance in samples from the control group. Hematoxylin

and eosin stain. Bar 100 mm. Fig. 1 (b) represents s marked tubular necrosis is observed in samples from the GM group. Desquamated and degenerated epithelial cells are visible in the lumina of necrotic tubules (*). Some of the tubular epithelial cells have large nuclei (large arrows). Notice the swelling cytoplasm, which is a result of oedema (small arrows). Hematoxylin and eosin stain. Bar, 100 mm. Fig. 1 (c) represents a sample from GM group featuring interruption in the basement membrane around the necrotic tubules (*) and narrowing of the Bowman's space (arrows). Distal tubules (d) appear almost normal. Periodic acid-Schiff stain. Bar 100 mm. Fig. 1; D represents Sample from GM+ L-CAR group showing a marked reduction in tubular damage. Distal tubules (d) appear normal while some of the proximal tubules show moderate intracellular oedema (arrows). Hematoxylin and eosin stain. Bar 100 mm. Fig. 1 (e) represents Sample from GM+L-CAR group. Basement membrane appears orderly and continuous (thin arrows) and narrowing of the Bowman's space is also evident (thick arrows). Periodic acid-Schiff stain. Bar 100 mm. Fig. 1; F represents a sample from GM group. Apoptotic body (*) and picnotic nuclei (arrows) are visible in the proximal tubules. Hematoxylin and eosin stain. Bar, 250 mm. Fig. 1 (g) represents a sample from GM group. Notice the two mitotic figures (arrows). Hematoxylin and eosin stain. Bar, 100 mm.

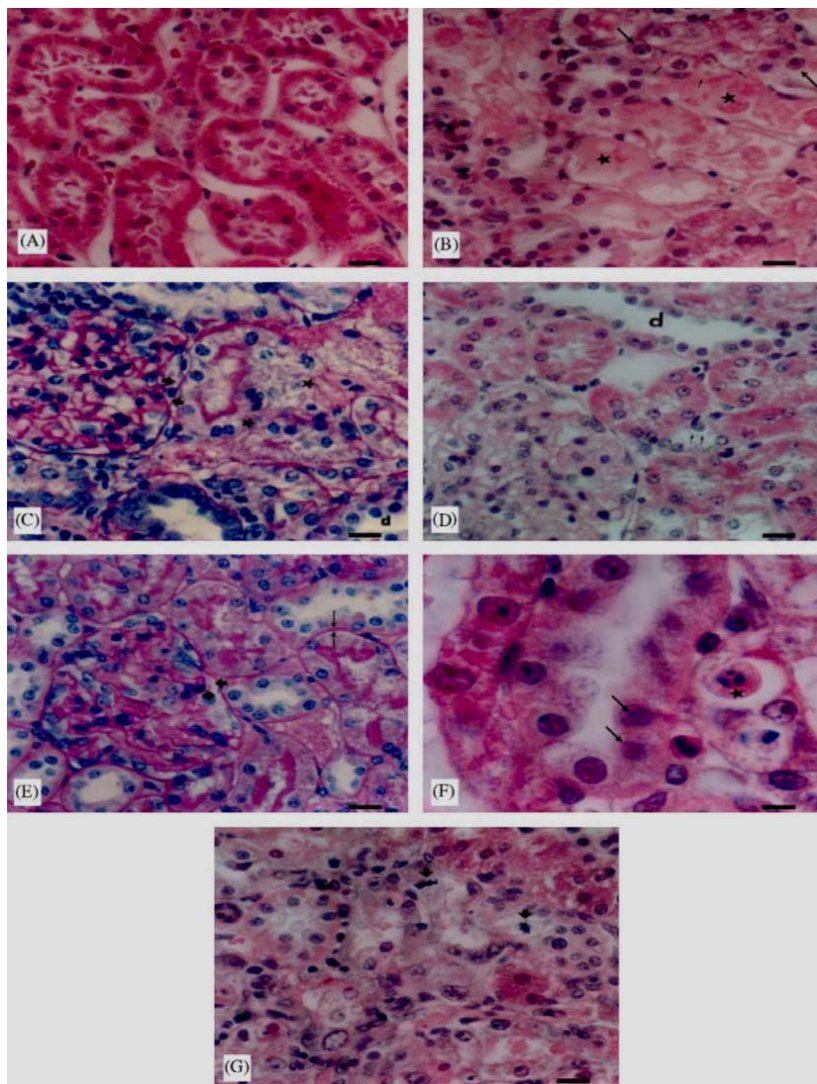


Fig. 1 Histological appearance of kidney samples

VI. DISCUSSION

Aminoglycoside antibiotics are commonly used for the treatment of severe gram-negative bacterial infections. Despite their beneficial effects, aminoglycosides have considerable nephrotoxic side effects [30]. The most widely used drug in this category is gentamicin (GM) [35]. A major complication of GM treatment is nephrotoxicity, accounting for 10–20% of all cases of acute renal failure according to experimental results [11]. Also, 30% of the patients treated with GM for more 7 days show some signs of nephrotoxicity that markedly limits its use [32]. So, GM nephrotoxicity promotes both increased morbidity and health-care costs. Although the change in GM dosing from multiple-daily to once-daily dose has reduced the risk of nephrotoxicity, the incidence of GM-induced ARF remains high [21].

The mechanisms of action by which L-carnitine may ameliorate gentamicin-induced nephrotoxicity in rats are unknown. Research suggests a number of possible

mechanisms of gentamicin nephrotoxicity. One set of potential mechanisms involve the binding of gentamicin to the structure and of the function of biological membranes [34], [17].

Gentamicin binds to anionic phospholipids [19], and may thereby alter biophysical properties and functions of cell membranes by decreasing the permeability of the glycerol moiety of phosphatidylinositol [34], decreasing membrane fluidity [24] and promoting membrane aggregation [17].

Membranous structures that can be damaged by gentamicin include plasma membrane [45], lysosomes [18], mitochondria [43], microsomes [6], and probably the Golgi Apparatus [36]. Lysis of lysosomes containing gentamicin may release both potent acid hydrolases and high concentration of the drug into the cytoplasm, disrupting critical intracellular processes including mitochondrial respiration [44], microsomal protein synthesis [6] and intracellular signaling via the phosphatidylinositol radicals [42]. All of which have been observed in experimental models of gentamicin toxicity. Thus,

ATP depletion and also generation of oxidants and free radicals may occur in kidney with gentamicin toxicity [43].

Carnitine plays an essential role in long chain fatty acid oxidation [7] and administration of L-carnitine is associated with a linear dose-dependent increase in myocardial ATP in a rat model on doxorubicin myocardial injury [38]. Carnitine may also maintain membrane stability; this has been shown most clearly in erythrocytes, which may be mediated either by its acting on membrane phospholipids fatty acids or by interacting between carnitine and cytoskeletal properties [3].

Reference [2] demonstrated that gentamicin administration significantly decreased intra mitochondrial COA-SH, an dispensable activation in most of the mitochondrial energy-providing systems (TCA cycles, fatty acid-beta oxidation and pyruvate oxidation). This effect could be explained on the basis GM-induced generation of ROS with the consequent depletion of SH-containing compound including COA-SH. It is well known that L-carnitine acts as a buffering system by removing the accumulated acetyl-CoA in mitochondria when the normal metabolic pathway of an acetyl-CoA is blocked or when an acetyl-CoA is formed and cannot be further metabolized [39].

Reference [1] reported that L-carnitine stimulates the mitochondrial efflux of acetyl-CoA in the form of acetyl-carnitine in a reaction mediated by carnitine acetyl-transferase. This could explain the increase in the intra mitochondrial COA-SH and the decrease in acetyl-CoA with subsequent improvement in substrate ATP production and mitochondrial function by L-carnitine in a study done by [2].

Although L-carnitine may itself be an antioxidant, it appears to have a strong inhibitory effect on free radical production [28]. L-carnitine was also reported to have a pronounced protective effect against renal ischemia-reperfusion injury [12]. Moreover, L-propionyl carnitine has been found to reduce cyclosporine-induced lipid peroxidation [22] and decreased intracellular ATP levels in the rat kidney [14]

VII. CONCLUSION

The beneficial effect of L-carnitine in GM toxicity implies the involvement of free radicals in the renal damage, although other destructive processes may also be involved. According to our biochemical findings, which were supported by histopathological evidence, co-administration of L-carnitine along with gentamicin attenuates the increase in lipid peroxidate damage; restores antioxidant status, markers of renal injury and urinary excretory indices. So, the present findings demonstrated that L-carnitine possesses significant therapeutic effects and is a promising candidate for chemoprevention of gentamicin-induced renal damage.

REFERENCES

- [1] Abdel-aleem S, Nada MA, Sayed-Ahmed M, Hendrickson SC, St Louis J, Walthall HP, Lowe JE. (1996): Regulation of fatty acid oxidation by acetyl-CoA generated from glucose utilization in isolated myocytes. *J Mol Cell Cardiol.* ; 28(5):825-33.
- [2] Al-Shabanah OA, Aleisa AM, Al-Yahya AA, Al-Rejaie SS, Bakheet SA, Fatani AG, Sayed-Ahmed MM. (2010): Increased urinary losses of carnitine and decreased intramitochondrial coenzyme A in gentamicin-induced acute renal failure in rats. *Nephrol. Dial. Transplant.*; 25(1):69-76.
- [3] Arduini A, Rossi M, Mancinelli O, et al. (1990): Effect of L-carnitine and acetyl L-carnitine on the human erythrocyte membrane stability and deformability. *Life Sci*; 47:2395-400.
- [4] Bartels H., Boehmer M. (1971): Micro-determination of creatinine. *Clin. Chim. Acta.* ; 32:81-85.
- [5] Begg EJ, Barclay ML, Kirkpatrick CM. (2001): The therapeutic monitoring of antimicrobial agents. *Br J Clin Pharmacol.* 52:355-43S.
- [6] Bennett WM, Mela-Riker LM, Houghton DC, Gilbert DN, Buss WC. (1988): Microsomal protein synthesis inhibition: an early manifestation of gentamicin nephrotoxicity. *Am J Physiol.*; 255: F265-9.
- [7] Bremer J. (1983): Carnitine--metabolism and functions. *Physiol Rev.*; 63(4):1420-80.
- [8] Clairborne, A. (2000): Catalase activity. In: Greenwald, E.R. (Ed.). *Handbook of Methods for Oxygen Radical Research*, CRC Press, Florida, pp: 283-284.
- [9] Cockcroft DW, Gault MH. (1976): Prediction of creatinine clearance from serum creatinine. *Nephron.* ; 16(1):31-41.
- [10] De la Cruz Rodríguez, Carmen Rosa Araujo, Sara Emilia Posleman, María Rosario Rey (2010): Attenuation of gentamicin-induced nephrotoxicity: trimetazidine versus N-acetyl cysteine. *J. Appl. Toxicol.* 30(4):343-53.
- [11] Erdem, A., Gundogan, N.U., Usubutun, A., Kilinc, K., Erdem, S.R., Kara, A., Bozkurt, A. (2000): The protective effect of taurine against gentamicin-induced acute tubular necrosis in rats. *Nephrol. Dial. Transplant.* 15, 1175-1182.
- [12] Ergün O, Ulman C, Kılıçalp AS, Ulman I. (2001): Carnitine as a preventive agent in experimental renal ischemia-reperfusion injury. *Urol Res.*; 29(3):186-9.
- [13] Fawcett JK and Scott JE (1960): A rapid and precise method for the determination of urea. *Clin Pathol.*; 13:156-9.
- [14] Giovannini L, Migliori M, De Pietro S, Taccola D, Panichi V, Bertelli AA, Bertelli A. (1999): L-propionyl carnitine reduces toxicity correlated to cyclosporine-induced intracellular ATP concentrations. *Drugs Exp Clin Res.*; 25(4):173-7.
- [15] Halliwell B, Chirico S. (1993): Lipid peroxidation: its mechanism, measurement and significance. *Am J Clin Nutr.* 57:715-25.
- [16] Haywood, J.P., Shaffer, R.A. and Fastenow, C. (1981): Regional blood flow measurement with pulsed Doppler flowmeter in conscious rats. *Am. J. Physiol.*, 241: 273-78.
- [17] Kaloyanides GJ, Ramsammy L S. (1991): Alterations of biophysical properties of liposomes predict aminoglycoside toxicity: inhibitory effect of polyaspartic acid. In: Bach PH, Delacrey L, Gregg NJ, Wilks MF, eds. *Proceedings of the Fourth International Symposium on Nephrotoxicity*. Marcel Dekker, New York; 117-126.
- [18] Kaloyanides, G. J. (1984): Aminoglycoside-Induced Functional and Biochemical Defects in the Renal Cortex. *Fundam. Appl. Toxicol.* ; 930-943.
- [19] Kirschbaum BB. (1984): Interactions between renal brush border membranes and polyamines. *J Pharmacol Exp Ther* ; 229(2):409-16.
- [20] Klein G, Geibel E. (1990): Evaluation of a new photometric assay for the kinetic determination of N-acetyl-b-D-glucosaminidase in urine samples. *Progr Med Lab*; 4/5: 450.
- [21] Kopple JD, Ding H, Letoha A, Ivanyi B, Qing DP, Dux L. (2002): L-Carnitine ameliorates gentamicin-induced renal injury in rats. *Nephrol Dial Transplant.* 17:2122-31.
- [22] Longoni B, Giovannini L, Migliori M, Bertelli AA, Bertelli A. (1999): Cyclosporine-induced lipid peroxidation and propionyl carnitine protective effect. *Int J Tissue React.* ; 21(1):7-11.
- [23] Misra, HP. (2000): Adrenochrome assay. In Greenwald, A.R. (Ed.). *Hand books of Methods for Oxygen Radical Research*. CRC Press, Florida, pp: 237-242.
- [24] Moriyama T, Nakahama H, Fukuhara Y, Horio M, Yanase M, Orita Y, Kamada T, Kanashiro M, Miyake Y. (1989): Decrease in the fluidity of brush-border membrane vesicles induced by gentamicin. A spin labeling study. *Biochem Pharmacol.* ; 38(7):1169-74.
- [25] Moudden M, Laurent G, Leclercq M, Tulkens P. (2000): Gentamicin induced apoptosis in renal cell lines and embryonic rat fibroblasts. *Toxicol Sci.* 56:229-39.
- [26] Moudden M., Laurent G. and Tulkens PM. (2010): Mechanism of Protective Effect of L-carnitine on Human Kidney Tubular Epithelial Cell Line Injury Induced by Oxidative Stress, Posted on May, 17, 2010 by China Papers.

- [27] Orsonneau JL, Douet P, Massoubre C, Lustenberger P, Bernard S. (1989) :An improved Pyrogallol Red-Molybdate Method for Determining Total Urinary Protein. *Clin Chem.*; 35:2233-6.
- [28] Packer L, Valenza M, Serbinova E, Starke-Reed P, Frost K, Kagan V. (1991): Free radical scavenging is involved in the protective effect of L-propionyl-carnitine against ischemia-reperfusion injury of the heart. *Arch Biochem Biophys.* ; 288(2):533-7.
- [29] Parlakpinar H, Tasdemir S, Polat A, Bay-Karabulut A, Vardi N, Ucar M. (2006): Protective effect of chelerythrine on gentamicin-induced nephrotoxicity. *Cell Biochem Funct.* 24(1):41–8.
- [30] Parlakpinar, H., Ozer,M.K., Sahna, E., Vardi, N., Cigremis, Y., Acet, A. (2003): Amikacin-induced acute renal injury in rats: protective role of melatonin. *J. Pineal. Res.* 35, 85–90.
- [31] Pedraza-Chaverri J, Gonzalez-Orozcoa AE, Maldonado PD, Barrera D, Medina-Campos ON, Hernandez-Pando R. (2003): Diallyl disulfide ameliorates gentamicin induced oxidative stress and nephropathy in rats. *Eur J Pharmacol.* 473: 71–8.
- [32] Pedraza-Chaverri, J., Maldonado, P.D., Mediana-Campos, O.N., Olivares-Corichi, I.M., Granados-Silvestre, M.A., Hernandez- Pando, R Ibarra-Rubio, M.E. (2000): Garlic ameliorates gentamicin nephrotoxicity: relation to antioxidant enzymes. *Free Radic. Biol. Med.* 29, 602–611.
- [33] Prins JM, Weverling GJ, de Blok K, van Ketel RJ, Speelman P. (1996): Validation and nephrotoxicity of a simplified once-daily aminoglycoside dosing schedule and guidelines for monitoring therapy. *Anti-microb Agents Chemother.* 40: 2494–9.
- [34] Ramsammy LS, Kaloyanides GJ. (1987): Effect of gentamicin on the transition temperature and permeability to glycerol of phosphatidylinositol-containing liposomes. *Biochem Pharmacol.* 36(7):1179-81.
- [35] Reiter, R.J., Tan, D., Sainz, R.M., Mayo, J.C., Lopez, B.S. (2002): Melatonin reducing the toxicity and increasing the efficacy of drugs. *J. Pharm. Pharmacol.* 5, 1299–1321.
- [36] Sandoval RM, Dunn KW, Molitoris BA. (2000): Gentamicin traffics rapidly and directly to the Golgi complex in LLC-PK (1) cells. *Am J Physiol Renal Physiol.*; 279(5):F884-90.
- [37] Selby NM, Shaw SM, Woodier N, Fluck RJ, Kohle NV. (2009): Gentamicin-associated acute kidney injury. *Q J Med.*102:873–80.
- [38] Shug AL. (1987): Protection from adriamycin-induced cardiomyopathy in rats. *Z. Kardiol.* ; 76 Suppl 5:46-52.
- [39] Steiber A, Kerner J, Hoppel CL. (2004): Carnitine: a nutritional, biosynthetic, and functional perspective. *Mol Aspects Med.*; 25(5-6):455-73.
- [40] Sweileh WM. (2009): A prospective comparative study of gentamicin- and amikacin-induced nephrotoxicity in patients with normal baseline renal function. *Fundam Clin Pharmacol.* 23(4):515–20.
- [41] Szasz, G. (1969): A kinetic photometric method for serum γ glutamyl transpeptidase. *Clin. Chem.* 15: 124–136.
- [42] Walker PD and Shah SV (1988): Evidence Suggesting a Role for Hydroxyl Radical in Gentamicin-induced acute renal failure in Rats. *J. Clin. Invest.* ; 81: 334-341.
- [43] Walker PD, Barri Y, Shah SV. (1999): Oxidant mechanisms in gentamicin nephrotoxicity. *Ren Fail.*; 21(3-4):433-42.
- [44] Weinberg JM, Humes HD (1980): Mechanisms of gentamicin-induced dysfunction of renal cortical mitochondria. I. Effects of mitochondrial respiration. *Arch Biochem Biophys*; 205:222–231.
- [45] Williams PD, Holohan PD, and Ross CR (1981): Gentamicin nephrotoxicity. II. Plasma membrane changes. *Toxicol, Appl. Pharmacol.*61:243–251.