

An Efficient Pixel Based Cervical Disc Localization

J. Preetha, S. Selvarajan

Abstract—When neck pain is associated with pain, numbness, or weakness in the arm, shoulder, or hand, further investigation is needed as these are symptoms indicating pressure on one or more nerve roots. Evaluation necessitates a neurologic examination and imaging using an MRI/CT scan. A degenerating disc loses some thickness and is less flexible, causing inter-vertebrae space to narrow. A radiologist diagnoses an Intervertebral Disc Degeneration (IDD) by localizing every inter-vertebral disc and identifying the pathology in a disc based on its geometry and appearance. Accurate localizing is necessary to diagnose IDD pathology. But, the underlying image signal is ambiguous: a disc's intensity overlaps the spinal nerve fibres. Even the structure changes from case to case, with possible spinal column bending (scoliosis). The inter-vertebral disc pathology's quantitative assessment needs accurate localization of the cervical region discs. In this work, the efficacy of multilevel set segmentation model, to segment cervical discs is investigated. The segmented images are annotated using a simple distance matrix.

Keywords—Intervertebral Disc Degeneration (IDD), Cervical Disc Localization, multilevel set segmentation.

I. INTRODUCTION

DISC hernia is a degenerative process where a gel-like center of disc cartilage called nucleus pulposus ruptures through the annulus fibrosus' tougher outer wall [1]. A common site of disc hernia is in the lumbar spine [2]. The predilection site is L4/L5 disc cartilage. Most of the 90% disc hernias occur in the lumbar spine; cervical and thoracic spine disc hernias are uncommon. Thoracic disc hernia occurrence is said to be one per million per year [3]. The symptoms are usually pain and neurological deficits related to anatomical localization of the disc herniation. Low back pain is generally caused by lumbar disc hernia.

Key first documented in 1945 the spontaneous regression of a herniated disc by myelography [4]. Teplick and Haskin, 40 years later, demonstrated the resolution of a hernia by Computer Tomography (CT) [5]. From then, many studies documented lumbosacral intervertebral disc hernias regression that correlates with lumbosacral radiculopathy. But, literature is sparse on the natural history of cervical disc hernias. Most reports in literature are isolated cases or of small series of patients, non-representative of the general population. Some reports combined cervical and lumbar herniated discs findings and evolution which were not operated upon. But, these hernias differ substantially in their anatomical, pathophysiological and biomechanical characteristics.

Cervical disc hernias are present with a radiculopathy due to compression of a cervical root or/and myelopathy caused by

spinal cord compression. Radiographic studies ensure a definitive diagnosis and reveal the magnitude and level of the hernia. Documented cervical disc extrusions are a definitive indication for surgery [6] by most neurosurgeons.

MRI spine plays an important role in diagnosing spinal diseases like slipped vertebra, herniated disk, and disk/vertebra degeneration, and evaluates treatment in patients with symptoms after spinal surgery. Osteoporosis is a disease affecting mostly old people. Vertebral fractures are its indicators. "The assessment of vertebral fracture was usually performed manually by marking six points on every vertebra at four corners and in the upper and lower surface midpoints and then measuring anterior, mid, and posterior vertebral heights" [7]. Integrating computer processing of spine MR images ensures an accurate diagnosis and save time, labor, and cost [8].

In a May 2005 North American Spine Society survey, 87% of spine care professionals agreed that obesity was a major factor in back pain. As the spine is complex and the center of many activities, it is subject to various diseases

- Osteoporosis
- Stenosis
- Disk degeneration

Degenerative and Traumatic disc changes are a broad category that comprises of Anular Tear, Herniation, and Degeneration. This group of discs characterization as Degenerative or Traumatic does not mean that trauma is a factor or that degenerative changes are pathologic as opposed to the normal aging.

Human cervical spine has 7 vertebrae, with the two upper vertebrae being the atlas (C1) and axis (C2). Many investigated different aspects of human cervical spine, e.g. anatomy, kinematics, in vivo loads, and vertebra's mechanical properties as well as of inter-vertebral discs. The cervical vertebra's anatomical dimensions which were measured are compatible with discussions on the spine's functional biomechanics.

The intervertebral disk is an articular structure, part of a component load-bearing system of disks, vertebrae, ligaments, and muscles. The disk, the most critical component absorbs loads and distributes forces on the vertebral column. The nucleus pulposus, annulus fibrosis, and cartilaginous end-plates are the structures that permit this shock-absorbing, force-distributing ability [9]. IDD traditional view was that it was a process of normal ageing and due to changes related to physical loading over a lifetime. Fundamental to any IDD's epidemiology description is the definition of a case and how to measure it. There is no standard back pain or disc degeneration definition and so comparison between studies is difficult. Disc degeneration, operationally is defined by evaluation method. Radiography or CT scan can assess disc

Preetha J and S. Selvarajan are with Muthayammal Engineering College, Namakkal, Tamilnadu, India (e-mail: preetha.oir@gmail.com, selvarajanrasipuram@rediffmail.com).

height and osteophytes while MRI better assesses disc signal and structural change like prolapse or hernia. For large population studies, MRI is the preferred method and most evaluation systems though qualitative, include disc height assessment, signal intensity, bulging or prolapse, and osteophytes [10].

In this study, the efficacy of multilevel set segmentation model to segment the cervical discs is investigated. Section II reviews some of the related works available in the literature. Section III explains the methods and techniques used in this study. Section IV presents the results, and discussion and section V concludes the study.

II. RELATED WORKS

A two-level discs localization probabilistic model from clinical MRI data that captured pixel and object level features was proposed by [11] which assumed conditional independence at the pixel-level to enhance efficiency while maintaining robustness. This paper uses a dataset with 105 MRI normal and abnormal cases for the lumbar area. The model was thoroughly tested to get encouraging results on normal/abnormal cases.

A robust localization and identification algorithm that built on supervised classification forests avoiding an explicit parametric appearance model was proposed by [12]. Evaluation was performed on a challenging dataset of 224 spine CT scans with varying pathologies including high-grade kyphosis, scoliosis, and surgical implants presence. This approach was efficient for pathological cases.

A new method combining Marginal Space Learning (MSL), a recently introduced concept for efficient discriminative object detection, with a generative anatomical network incorporating relative pose information for multiple objects detection was presented by [13]. Experiments based on 42 MR volumes reveal that the system not only ensured superior accuracy but also was the fastest of its kind in literature.

Texture-based pattern recognition system for automatic cervical IDD characterization from MRI of the spine was proposed by [14]. The generated features were used to design a pattern recognition system based on Least Squares Minimum Distance classifier. The system ensured 94% classification accuracy and is useful to physicians for assessment of MRI cervical IDD.

Desiccation diagnosis by processing localized lumbar intervertebral discs was automated by [15] using Gibbs distribution to model the appearance and intensity context for desiccated discs. It also used 55 clinical T2-weighted MRI for lumbar area, achieving over 96% accuracy on a cross-validation experiment.

A method which outputs a tight bounding box for every disc was proposed by [16]. It uses Histogram of Oriented Gradients features with SVM as classifier and combines these machine learning techniques with heuristics. Results were compared with earlier research.

An unsupervised segmentation method that automatically extracts spinal canal in the MRI sagittal plane images was

presented by [17]. Based on a saliency-driven attention model and an active contour model this method needs no human intervention or training. Experiments on 60 patients' data reveal this procedure performing segmentation robustly, achieving a Dice's similarity index of 0.71 between segmentation by proposed model and reference segmentation, compared to the Dice's similarity index of 0.90 between two observers.

An efficient method for part-based localization of anatomical structures which embed contextual shape knowledge in a probabilistic graphical model presented by [18] allows robust detection even when some part detections are missing. The application is good for spine detection and MRI images labeling.

A parametric modeling approach for computer-aided detection of vertebrae column metastases in whole-body MRI evaluated by [19] involves constructing a geometric primitive's model based on purely anatomical knowledge of organ shapes and rough variability limits. The metastases detection algorithm's evaluation is done on a separate test set and on training set via leave-one-patient-out approach.

A system designed to allow automatic quantitative analysis of progressive hernia damage to intervertebral discs under flexion/extension motions combined with a compressive load was presented by [20]. It used a new multi-scale level set approach based on Mumford–Shah energy functional in iterative bilateral scale space to segment inter-vertebral disc regions from PQCT imagery. Results show that the new system achieves mean absolute distance error below 0.8 mm compared to ground truth measurements.

A new method for automatic localization of vertebrae in arbitrary field-of-view CT scans was presented by [21]. No assumptions are made on which section of the spine is visible or to what extent. This algorithm is based on regression forests and probabilistic graphical models. The system was evaluated on 200 CT scans, the largest dataset for this purpose and obtained an overall median localization error <6 mm and an identification rate of 81%.

A new, fully automatic approach to localize lumbar intervertebral discs in MR images was proposed by [22]. The inference algorithm runs in polynomial time producing globally optimal results. The system was validated on a real spine MRI dataset with the final localization results being favorable compared to those reported in literature.

An automatic detection of disk structure and lumbar vertebrae from MR images was presented by [23]. This paper combined information from T1W sagittal, T2W sagittal, and T2W axial MR images to label disks and vertebral columns. The method coupled geometric, and tissue property information from 3 types of images with image analysis approaches achieving 98.8% accuracy.

A method for automated planning of MRI spine scans was presented by [24]. Lumbar and cervical examinations are considered, though the new method is extendible to other spine examinations, like thoracic or total spine imaging. The automated scan planning system includes an anatomy recognition part, which automatically detects and labels spine

anatomy. Validation demonstrates the proposed method's robustness and its feasibility for clinical use.

An automatic vertebra detection and segmentation method developed by [25] consists of 3 stages; namely, AdaBoost-based vertebra detection, vertebra segmentation by an iterative normalized cut algorithm, and detection refinement via robust curve fitting. They also proposed an efficient vertebra detector, trained by the improved AdaBoost algorithm, to locate initial vertebra positions. Results show that the system achieves high accuracy on 3D spinal MRI data sets.

III. METHODOLOGY

In this work multi-level set segmentation is investigated for localization of the discs and a distance based metric is used to locate the centre points. The details of each step are discussed in subsequent section.

Dataset

The dataset is obtained from <http://research.microsoft.com/en-us/projects/spine/>. The database has data on 310 patients from sagittal panoramic radiographies of the spine. Of these, 100 are volunteers without any pathology in their spines (normal patients). The remaining data is from patients operated for spondylolisthesis (150 patients) or disc hernia (60 patients). Hence, the database has 210 abnormal patients. Every patient in the database is represented as a vector with six biomechanical attributes, corresponding to the following parameters of spino-pelvic system: angle of pelvic tilt, sacral slope, angle of pelvic incidence, lordosis angle, pelvic radius, and grade of slipping [26]. A subset of the database consisting of c1 to c5 discs are selected for the investigation.

Multilevel Set Segmentation Model

The new multiphase level set a framework for image segmentation using the Mumford-Shah model for piecewise smooth optimal approximations and piecewise constant. The new method is a generalization of an active contour model without edges based 2-phase segmentation. The active contour model (based binary segmentation) segments images with more than two regions by recommending a novel multiphase level set framework for the problem. It shows that with a reduced level set functions, triple junctions, and complex topologies are represented. Also, the phases in the partition do not produce "vacuum" and "overlap."

Let $\Omega \subset \mathbb{R}^2$ be open and bounded. For illustration, a two-dimensional case is considered, but any dimension can be considered. For instance, consider one-dimensional case. Let C be a closed subset in Ω , of a finite set of smooth curves. The connected components of $\Omega \setminus C$ are denoted by Ω_i , so that $\Omega = \cup_i \Omega_i \cup C$. Also, denote $|C|$ as the length of curves making up C . $u_0: \Omega \rightarrow \mathbb{R}$ is a given bounded image-function.

Segmentation in computer vision, as formulated by [27], is defined as follows: given an observed image u_0 , find a decomposition Ω_i of Ω and an optimal piecewise smooth approximation u of u_0 , so that u varies smoothly within each Ω_i , and rapidly or discontinuously across Ω_i boundaries.

To solve this, Mumford and Shah [27] suggested the following minimization problem:

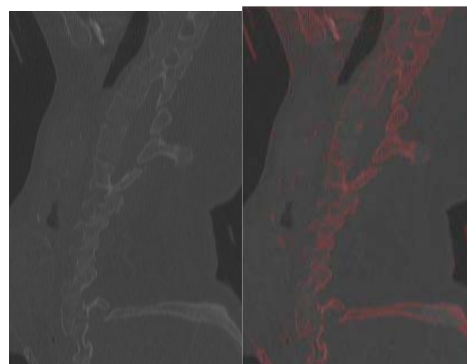
$$\inf_{u,C} \left\{ F^{MS}(u,C) = \int_{\Omega} (u-u_0)^2 dx dy + \mu \int_{\Omega \setminus C} |\nabla u|^2 dx dy + \nu |C| \right\}, \quad (1)$$

where $\mu, \nu > 0$ are fixed parameters, to weight different terms in the energy. For (u, C) a minimizer of above energy, u is an "optimal" piecewise smooth approximation of initial, possibly noisy, image u_0 , and C approximates the edges of u_0 ; u will be smooth only outside C , i.e. on $\Omega \setminus C$. Theoretical results of existence and regularity of minimizers of (1) can be found in [27]-[30].

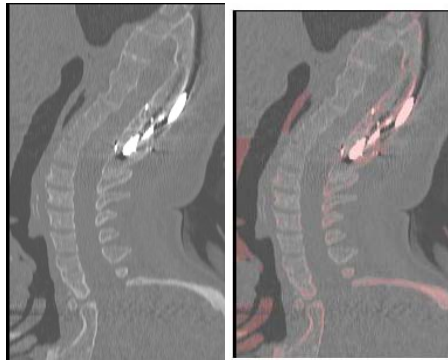
A reduced case of above model is got by restricting the segmented image u to piecewise constant functions, i.e. $u = \text{constant } c_i$ inside each connected component Ω_i . The problem then is often called a "minimal partition problem," and to solve it, in [27] it was proposed to minimize the following functional:

$$E^{MS}(u,C) = \sum_i \int_{\Omega_i} (u_0 - c_i)^2 dx dy + \nu |C|. \quad (2)$$

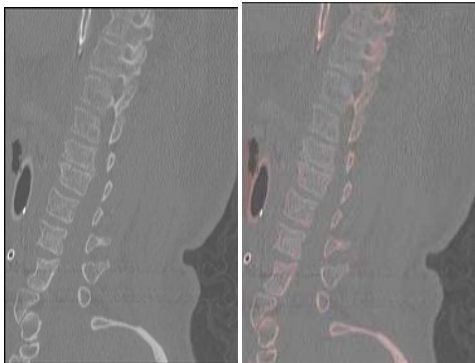
For a fixed C , energy from (2) is minimized in variables c_i by setting $c_i = \text{mean}(u_0)$ in Ω_i . Theoretical results for existence and regularity of minimizers of (2) are found in [27], [31]-[34]. It is not easy to minimize (1) and (2) in practice, because of the unknown set C of lower dimension, and also as the problems is not convex. Fig. 1 shows some of the sample images and its segmentation used in this investigation.



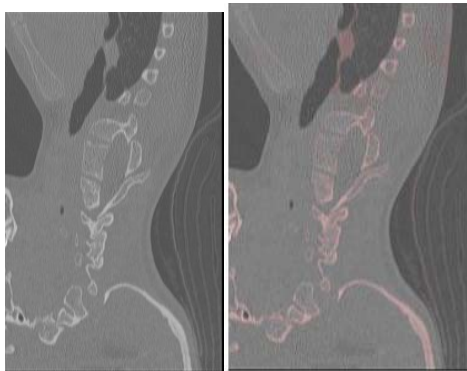
(a)



(b)



(c)



(d)

Fig. 1 Sample Images

IV. EXPERIMENTAL RESULTS

10 cases from the spine data set are used. From each case 3 slices are extracted. Each of disc center in the slice is manually annotated. The deviation occurred from the presented system from manual annotation in mm is presented in Table I. The seven vertebrae of cervical spine for each image are segmented, and the deviation in mm is calculated with respect to manual annotation.

TABLE I
DEVIATION FROM MANUAL ANNOTATION IN MM

	c1	c2	c3	c4	c5	c6	c7
1	1.7	2.4	2.2	1.5	1.9	1.9	2.8
2	1.9	0.5	2	0.6	2.5	1.3	0.3
3	2	3	0.2	2.8	1.5	2.3	2.2
4	1.6	2.6	0.7	1.9	1.3	2.7	1.7
5	1.8	1.5	2	3	2.3	1.4	1.4
6	0.5	0.9	1.7	2.2	1.9	0.4	0.6
7	0.3	0.5	2.1	1.9	1.2	1.8	3
8	1.9	2.1	1.5	2.9	1.5	1.8	0.4
9	1.4	0.5	2.9	0.9	1.4	2.3	0.7
10	1.3	1.4	0.9	1.3	2.6	2.8	1.6
11	2.5	1.4	1.2	1.4	1.9	2.8	0.4
12	2.5	0.6	2.3	3	1.3	0.4	0.8
13	2.6	1.7	2.8	0.2	1.4	1.3	2.4
14	2.2	2.2	2.4	1.2	1.7	2.1	0.8
15	1.3	1.4	1.2	0.6	0.6	1.2	1.3
16	2.7	0.4	2.4	2.5	2.9	2	2.2
17	0.9	1.8	2.6	0.4	0.3	2.6	0.6
18	2.7	1.7	2	1.9	1.2	1.3	2.2
19	1.9	1.1	1.8	1.6	1.6	2.8	3
20	1.8	0.6	0.6	1	0.6	2.7	1.5
21	2.1	1.6	1.1	1.5	1.2	0.3	0.3
22	1.2	1.1	0.7	2.4	2.4	0.6	1.6
23	1.1	1.5	0.5	0.3	1.1	1.9	2.8
24	1.6	2.6	2.9	1.2	1	1.8	2.1
25	0.3	2.9	1.9	0.6	2.1	2.4	2.5
26	1.3	1.8	0.4	2.3	1.6	1.3	1.6
27	2.7	2.8	2.7	0.9	0.9	2.9	3
28	0.8	2	0.8	1.7	2.7	0.4	2.5
29	2.8	0.8	0.6	1.5	2	2.2	2.2
30	1.4	1.2	1	1.5	2	1.8	2.2

It is observed from Table I that the maximum deviation is 3 mm and minimum of 0.2 mm is achieved by the automated method compared to manual annotation. Fig. 2 shows the deviations achieved graphically.

V. CONCLUSION

Cervical intervertebral discs degeneration is common and is held for the cause of neck and arm pain. The cervical intervertebral disc is a spongy structure that absorbs shock and ensures cervical vertebrae movement. IDD is diagnosed by first localizing every inter-vertebral disc and identifying the pathology in a disc based on its geometry and appearance. Automatic methods using image processing methods are widely researched to help diagnosis. In this study, the quantitative assessment of the intervertebral disc pathology of the cervical region discs is achieved using multilevel set segmentation model. For evaluation, 10 cases from the spine data set which is manually annotated are used. The deviation occurred from the presented system from manual annotation in mm is measured. It is observed from experimental results that the deviation is on the high side and further work to reduce the deviation is to be carried out.

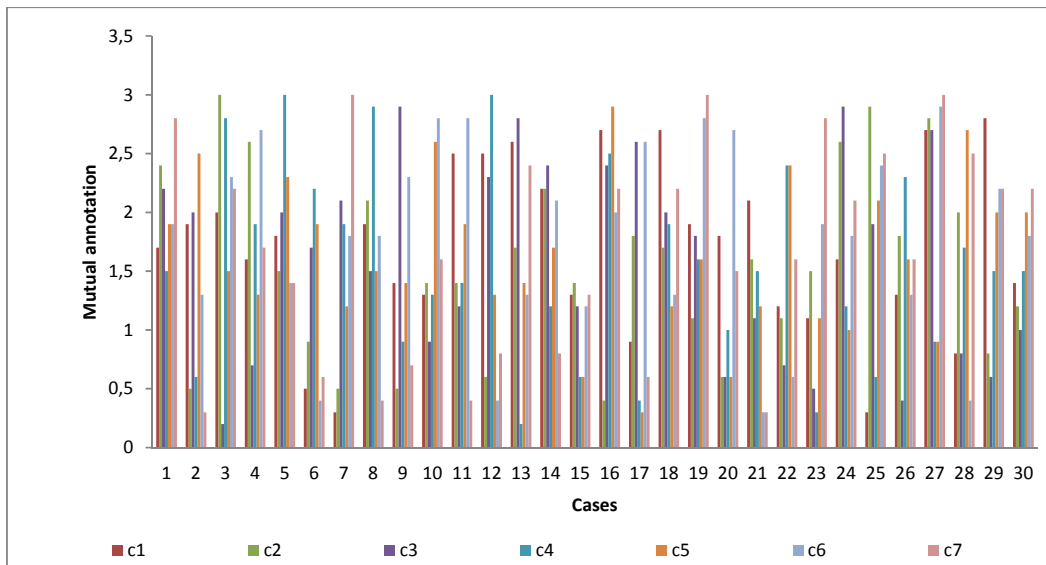


Fig. 2 Deviation from manual annotation in mm

REFERENCES

- [1] Uduma, F. U. (2011). Uncommon Types of Disc Hernia (A Report of Three Cases and Review of Literature). *Global Journal of Medical Research*, 11(2).
- [2] Ohnishi, K., Miyamoto, K., Kanamori, Y., Kodama, H., Hosoe, H., & Shimizu, K. (2005). Anterior decompression and fusion for multiple thoracic disc herniation. *Journal of Bone & Joint Surgery, British Volume*, 87(3), 356-360.
- [3] Boden, S. D. (1996). Current Concepts Review-The Use of Radiographic Imaging Studies in the Evaluation of Patients Who Have Degenerative Disorders of the Lumbar Spine*. *The Journal of Bone & Joint Surgery*, 78(1), 114-24.
- [4] Key, J. A. (1945). The conservative and operative treatment of lesions of the intervertebral discs in the low back. *Surgery*, 17(2), 291-303.
- [5] Teplick, J. G., & Haskin, M. E. (1985). Spontaneous regression of herniated nucleus pulposus. *American journal of neuroradiology*, 6(3), 331-335.
- [6] Vinas, F. C., Wilner, H., & Rengachary, S. (2001). The spontaneous resorption of herniated cervical discs. *Journal of clinical Neuroscience*, 8(6), 542-546.
- [7] Shi, R., Sun, D., Qiu, Z., & Weiss, K. L. (2007, May). An efficient method for segmentation of MRI spine images. In *Complex Medical Engineering, 2007. CME 2007. IEEE/ICME International Conference on* (pp. 713-717). IEEE.
- [8] Peng, Z., Zhong, J., Wee, W., & Lee, J. H. (2006, January). Automated vertebra detection and segmentation from the whole spine MR images. In *Engineering in Medicine and Biology Society, 2005. IEEE-EMBS 2005. 27th Annual International Conference of the* (pp. 2527-2530). IEEE.
- [9] Jensen, G. M. (1980). Biomechanics of the lumbar intervertebral disk: A review. *Physical therapy*, 60(6), 765-773.
- [10] Williams, F. M. K., & Sambrook, P. N. (2011). Neck and back pain and intervertebral disc degeneration: role of occupational factors. *Best Practice & Research Clinical Rheumatology*, 25(1), 69-79.
- [11] Alomari, R. S., Corso, J. J., & Chaudhary, V. (2011). Labeling of lumbar discs using both pixel-and object-level features with a two-level probabilistic model. *Medical Imaging, IEEE Transactions on*, 30(1), 1-10.
- [12] Glocker, B., Zikic, D., Konukoglu, E., Haynor, D. R., & Criminisi, A. (2013). Vertebrae Localization in Pathological Spine CT via Dense Classification from Sparse Annotations. In *Medical Image Computing and Computer-Assisted Intervention-MICCAI 2013* (pp. 262-270). Springer Berlin Heidelberg.
- [13] Kelm, B. M., Zhou, S. K., Suehling, M., Zheng, Y., Wels, M., & Comaniciu, D. (2011). Detection of 3D spinal geometry using iterated marginal space learning. In *Medical Computer Vision. Recognition Techniques and Applications in Medical Imaging* (pp. 96-105). Springer Berlin Heidelberg.
- [14] Michopoulou, S., Boniatis, I., Costaridou, L., Cavouras, D., Panagiotopoulos, E., & Panayiotakis, G. (2009). Computer assisted characterization of cervical intervertebral disc degeneration in MRI. *Journal of Instrumentation*, 4(05), P05022.
- [15] Alomari, R. S., Corso, J. J., Chaudhary, V., & Dhillon, G. (2009, June). Desiccation diagnosis in lumbar discs from clinical mri with a probabilistic model. In *Biomedical Imaging: From Nano to Macro, 2009. ISBI'09. IEEE International Symposium on* (pp. 546-549). IEEE.
- [16] Ghosh, S., Malgireddy, M. R., Chaudhary, V., & Dhillon, G. (2012, May). A new approach to automatic disc localization in clinical lumbar mri: Combining machine learning with heuristics. In *Biomedical Imaging (ISBI), 2012 9th IEEE International Symposium on* (pp. 114-117). IEEE.
- [17] Koh, J., Scott, P. D., Chaudhary, V., & Dhillon, G. (2011, March). An automatic segmentation method of the spinal canal from clinical MR images based on an attention model and an active contour model. In *Biomedical Imaging: From Nano to Macro, 2011 IEEE International Symposium on* (pp. 1467-1471). IEEE.
- [18] Schmidt, S., Kappes, J., Bergtholdt, M., Pekar, V., Dries, S., Bystrov, D., & Schnörr, C. (2007, January). Spine detection and labeling using a parts-based graphical model. In *Information Processing in Medical Imaging* (pp. 122-133). Springer Berlin Heidelberg.
- [19] Jerebko, A. K., Schmidt, G. P., Zhou, X., Bi, J., Anand, V., Liu, J., ... & Krishnan, A. (2007, January). Robust parametric modeling approach based on domain knowledge for computer aided detection of vertebrae column metastases in MRI. In *Information Processing in Medical Imaging* (pp. 713-724). Springer Berlin Heidelberg.
- [20] Wong, A., Mishra, A., Yates, J., Fieguth, P., Clausi, D. A., & Callaghan, J. P. (2009). Intervertebral disc segmentation and volumetric reconstruction from peripheral quantitative computed tomography imaging. *Biomedical Engineering, IEEE Transactions on*, 56(11), 2748-2751.
- [21] Glocker, B., Feulner, J., Criminisi, A., Haynor, D. R., & Konukoglu, E. (2012). Automatic localization and identification of vertebrae in arbitrary field-of-view CT scans. In *Medical Image Computing and Computer-Assisted Intervention-MICCAI 2012* (pp. 590-598). Springer Berlin Heidelberg.
- [22] Oktay, A. B., & Akgul, Y. S. (2011). Localization of the Lumbar discs using machine learning and exact probabilistic inference. In *Medical Image Computing and Computer-Assisted Intervention-MICCAI 2011* (pp. 158-165). Springer Berlin Heidelberg.
- [23] Bhole, C., Kompalli, S., & Chaudhary, V. (2009, February). Context sensitive labeling of spinal structure in MR images. In *SPIE Medical Imaging* (pp. 72603P-72603P). International Society for Optics and Photonics.

- [24] Pekar, V., Bystrov, D., Heese, H. S., Dries, S. P., Schmidt, S., Grever, R., ... & Van Muiswinkel, A. M. (2007). Automated planning of scan geometries in spine MRI scans. In *Medical Image Computing and Computer-Assisted Intervention–MICCAI 2007* (pp. 601-608). Springer Berlin Heidelberg.
- [25] Huang, S. H., Lai, S. H., & Novak, C. L. (2008, May). A statistical learning approach to vertebra detection and segmentation from spinal MRI. In *Biomedical Imaging: From Nano to Macro, 2008. ISBI 2008. 5th IEEE International Symposium on* (pp. 125-128). IEEE.
- [26] da Rocha Neto, A. R., Sousa, R., Barreto, G. D. A., & Cardoso, J. S. (2011). Diagnostic of pathology on the vertebral column with embedded reject option. In *Pattern Recognition and Image Analysis* (pp. 588-595). Springer Berlin Heidelberg.
- [27] Mumford, D., & Shah, J. (1989). Optimal approximations by piecewise smooth functions and associated variational problems. *Communications on pure and applied mathematics*, 42(5), 577-685.
- [28] Morel, J. M., & Solimini, S. (1995). *Variational methods in image segmentation*. Birkhauser Boston Inc..
- [29] Morel, J. M., & Solimini, S. (1989). Segmentation d'images par méthode variationnelle: une preuve constructive d'existence. *Comptes rendus de l'Académie des sciences. Série 1, Mathématique*, 308(15), 465-470.
- [30] Jean-Michel, M. O., OLIMINI, S. S., & de Lattre, P. D. M. (1988). Segmentation of Images by Variational Methods: a Constructive Approach. *Rev. Mat. Complut.*, 1(1), 2-3.
- [31] Massari, U., & Tamanini, I. (1993). On the finiteness of optimal partitions. *Annali dell'Università di Ferrara*, 39(1), 167-185.
- [32] Tamanini, I. (1996). Optimal approximation by piecewise constant functions. In *Variational Methods for Discontinuous Structures* (pp. 73-85). Birkhäuser Basel.
- [33] Tamanini, I., & Congedo, G. (1996). Optimal segmentation of unbounded functions. *Rendiconti del Seminario Matematico della Università di Padova*, 95, 153-174.
- [34] Leonardi, G. P., & Tamanini, I. (1998). On minimizing partitions with infinitely many components. *Annali dell'Università di Ferrara*, 44(1), 41-57.

Preetha J is with Muthayammal Engineering College, Namakkal. She is currently pursuing her doctorate in India.

S. Selvarajan is currently working in Muthayammal Engineering College, Namakkal, India.