

Histochemistry of Intestinal Enzymes of Juvenile Dourado *Salminus brasiliensis* Fed Bovine Colostrum

Debora B. Moretti, Wiolene M. Nordi, Thaline Maira P. Cruz, José Eurico P. Cyrino, Raul Machado-Neto

Abstract—Enzyme activity was evaluated in the intestine of juvenile dourado (*Salminus brasiliensis*) fed with diets containing 0, 10 or 20% of lyophilized bovine colostrum (LBC) inclusion for either 30 or 60 days. The intestinal enzymes acid and alkaline phosphatase (ACP and ALP, respectively), non-specific esterase (NSE), lipase (LIP), dipeptidyl aminopeptidase IV (DAP IV) and leucine aminopeptidase (LAP) were studied using histochemistry in four intestinal segments (S1, S2, S3 and posterior intestine). Weak proteolytic activity was observed in all intestinal segments for DAP IV and LAP. The activity of NSE and LIP was also weak in all intestines, except for the moderate activity of NSE in the S2 of 20% LBC group after 30 days and in the S1 of 0% LBC group after 60 days. The ACP was detected only in the S2 and S3 of the 10% LBC group after 30 days. Moderate and strong staining was observed in the first three intestinal segments for ALP and weak activity in the posterior intestine. The activity of DAP IV, LAP and ALP were also present in the cytoplasm of the enterocytes. In the present results, bovine colostrum feeding did not cause alterations in activity of intestinal enzymes.

Keywords—Carnivorous fish, enterocyte, intestinal epithelium, teleost.

I. INTRODUCTION

THE bovine colostrum has been used as an immunological and nutritional source for several species, including sheep, goats, pigs, rodents and, more recently by our research group, fish [1]–[6]. Besides being a rich source of fats, carbohydrates, proteins, vitamins and minerals, this lacteal secretion has high concentrations of hormones and growth factors, including the insulin-like growth factor type I and the epidermal growth factor, that are associated with gastrointestinal growth and development [7].

Unlike what happens with higher vertebrates, teleost fish have extensive uptake of molecules by the enterocytes in the posterior intestine [8], [9]. According to [8], three barriers hamper intestinal absorption: enzyme activity, presence of mucosal immune cells and physical barrier of epithelial cells. In herbivorous fish, carbohydrase activity is higher than proteases while in carnivorous fish, greater proteases activity

can be observed [10], [11].

The dourado *Salminus brasiliensis* (Cuvier, 1817), a carnivorous neotropical Characin, is considered the largest scaled fish of Platina Basin, one of the largest hydrographic basins of South America [12]. Larvae and juvenile dourado are carnivorous, while adults are Ichthyophagi, both preying on live animals [12]. The intestinal digestive physiology in this teleost has not been completely characterized and the present study investigated the distribution of select intestinal enzymes in juvenile dourado fed lyophilized bovine colostrum.

II. METHODOLOGY

A. Experimental Procedures

Farm-raised, feed-conditioned juvenile dourado (8.41 ± 0.76 g and 13.27 ± 0.35 cm) were stocked in 300 L, covered plastic cages, in a closed loop, continuous water circulation and aeration system (temperature $26.8 \pm 1.5^\circ\text{C}$; pH 7.9 ± 0.3 , dissolved oxygen 5.8 ± 1.0 mg l⁻¹; dissolved ammonia: <0.05 mg l⁻¹). Fish were assigned to experimental groups in a totally randomized design (n=3; 15 fish per cage), 3×2 factorial scheme with three diets (0, 10 and 20% of lyophilized bovine colostrum - LBC), and two feeding periods (30 and 60 days). Fish were adapted to the pelleted test diets for seven days and then hand-fed to apparent satiety twice a day (08h30 and 16h30). Fish were kept, maintained and treated according to accepted standards for the humane treatment of animals (authorized by Ethics Committees of Agriculture College/University of São Paulo, ESALQ/USP).

Bovine colostrum was collected from multiparous Holstein cows of commercial dairy farms. The animals were milked manually and lacteal secretions stored in sterile containers. The colostrum was homogenized to form a unique pool of bovine colostrum and stored at -20°C . The frozen pool was lyophilized and resulting powder homogenized and stored in sealed containers at -20°C until addition to the diet.

Formulation of test pellet diets, isonitrogenous and isoenergetic, and their centesimal composition are presented in Table I. Test diets and lyophilized bovine colostrum (LBC) were submitted to chemical analysis according to [13].

D. B. Moretti, W. M. Nordi, T.M.P. Cruz, and R. Machado-Neto are with the Department of Animal Science, Luiz de Queiroz College of Agriculture, University of São Paulo, São Paulo, 13418-260, Brazil, (phone: +55 19 3429 4260; e-mail: dmoretti@usp.br, wiolene@usp.br, thalinempcruz@usp.br, raul.machado@usp.br).

J.E.P.Cyrino is with the Department of Animal Science, Luiz de Queiroz College of Agriculture, University of São Paulo, São Paulo, 13418-260, Brazil, (phone: +55 19 3429 4177; e-mail: jepcyrio@usp.br).

Authors are indebted to São Paulo Research Foundation (FAPESP) and National Council for Scientific and Technological Development (CNPq) for the funding and support to the research project.

TABLE I
CHEMICAL COMPOSITION OF EXPERIMENTAL, PELLETED DIETS FED TO
JUVENILE DOURADO *SALMINUS BRASILIENSIS*

Ingredient (g kg ⁻¹)	Juvenile dourado diets		
	0%	10%	20%
Bovine colostrum (679 g kg ⁻¹ CP)	-	100	200
Soybean meal (45 g kg ⁻¹ CP)	230	230	230
Poultry by-product meal	204.8	119.8	24.5
Fish meal (55 g kg ⁻¹ CP)	320	300	300
Fish oil	95	90	85.2
Premix ¹	10	10	10
BHT	0.2	0.2	0.2
Cellulose	20	30	30
Corn (whole grain)	120	120	120
Chemical composition (g kg ⁻¹) ²			
Dry matter	924.4	936.7	925.7
Crude protein	422	425.1	444.7
Crude fiber	18.9	29.2	37.3
Fat	140.7	140.6	133.7
Ash	121.9	114.5	91.1
Gross energy (MJ kg ⁻¹)	20.8	21.1	20.8

(1) Guabi Nutrição Animal, Campinas, São Paulo (ingredient per kg). Vitamins: A, 2,500 UI; D3, 600,000 UI; E, 37,500 UI; K3, 3,750 mg; C, 50,000 mg; B1, 4,000 mg; B2, 4,000 mg; B6, 4,000 mg; B12, 4,000 mg; calcium pantothenate, 12,000 mg; biotin, 15 mg; acid folic, 1,250 mg; niacin, 22,500 mg. Mineral: Cu, 2,500 mg; Zn, 12,500 mg; I, 375 mg; Se, 87.5 mg; Co, 125 mg; Mn, 12,500 mg; Fe, 15,000 mg; BHT, 15,000 mg.

B. Sample Collection

Seven juveniles per treatment were sampled at each mentioned date for tissue collection. Sampling routine included 24 h of fasting and anesthesia with a benzocaine medium (0.1 g L⁻¹). After slaughter by cervical separation, the abdominal cavity was opened and the gastrointestinal tract removed within 5–10 min. Intestinal tracts (pyloric sphincter to anus) were then isolated, separated into middle intestine and rectum by identification of the ileum-rectal valve [14], and the former divided into three segments: S1 (anterior section), S2 (middle section) and S3 (posterior section). Intestinal samples were collected for histochemical analysis of cellular enzyme activity. The tissues were fixed in 4% phosphate-buffered paraformaldehyde solution, dehydrated with solutions of ethanol (30%, 50%, 70%, 90% and 100%) and then embedded in glycol methacrylate (JB-4, Polysciences, Inc., Warrington, PA, USA). For each fish and segment, 5 µm thick sections were taken.

C. Histochemical Analysis

The activity of dipeptidyl aminopeptidase IV (DAP IV) was evaluated in sections incubated for 50 min at room temperature in a solution containing 3 mg of gly-pro-4-methoxy-2-naphthylamine dispersed in 500 µL of N,N-dimethylformamide added to 10 mg of fast blue B in 10 mL of sodium phosphate buffer (0.1 M, pH 7.4). The slides were then washed with distilled water, immersed in 2% copper sulfate for 5 min, washed again, and post-stained [15].

The activity of leucine aminopeptidase (LAP) was evaluated in sections incubated for 120 min at room temperature in a solution containing 5 mL of acetate buffer (0.1 M, pH 6.5), 4 mL of 0.85% sodium chloride, 0.5 mL of

enzyme substrate solution (0.08% L-leucyl-4-methoxy-β-naphthylamide diluted in 2% ethyl alcohol solution), 0.5 mL of distilled water and 5 mg of fast blue B salt [16]. The slides were then washed with sodium chloride solution, immersed in copper sulfate (0.1 M) for 2 min, washed again and post-stained.

Non-specific esterase (NSE) activity was evaluated by the naphthyl acetate method [16]. Sections were incubated for 10 min at 37°C in a solution containing 0.25 mL of 4% sodium nitrite, disodium hydrogen phosphate buffer (0.2 M), pararosanilin-HCl solution (4% pararosanilin hydrochloric in hydrochloric acid 2 M), and enzyme substrate (1% α-naphthyl acetate in acetone), washed with distilled water and post-stained.

The activity of lipase (LIP) was evaluated by the tween method [16]. Sections were incubated for 90 min at 37°C in a medium solution containing 9 mL of Tris buffer (0.05 M, pH 7.2), 0.6 mL of tween 60 (5% in Tris buffer) and 0.3 mL of 2% calcium chloride. The slides were then washed with distilled water, incubated with 2% lead nitrate, washed again, immersed in 1% ammonium sulfate for 3 min, washed and post-stained.

The activity of acid phosphatase (ACP) was evaluated by the Gomori lead method [16]. Sections were incubated for 90 min at 37°C in Gomori medium solution containing 10 mL of sodium acetate buffer (0.05 M, pH 0.5), 20 mg of lead nitrate and 32 mg of enzyme substrate (β-sodium glycerophosphate). The slides were then washed with distilled water, incubated with 1% ammonium sulfate for 2 min, washed again and post-stained.

The activity of alkaline phosphatase (ALP) was evaluated by the Gomori calcium method [16] in sections incubated for 90 min at 37°C in a medium solution containing 2.5 mL of glycine buffer (0.2 M, pH 9.4), 5.0 mL of 2% calcium nitrate, 0.25 mL of 1% magnesium chloride and 2.5 mL of enzyme substrate (2% β-sodium glycerophosphate). The slides were then washed with distilled water, incubated with 2% cobalt nitrate, washed again, immersed in 1% ammonium sulfate for 2 min, washed and post-stained.

Post-staining was performed with toluidine blue O [16]. Slides were examined under light microscopy (JANAMED 2 Zeiss). Enzyme activities were assessed as strong (+++), moderate (++) , weak (+) or absent (-) depending on the staining intensity of the azo dye in the tissue [17]–[19]. Intestinal sections incubated without substrate were used as negative controls.

III. RESULTS AND DISCUSSION

Enzyme activity was detected along the brush border of the intestinal segments, Fig. 1. According to [20], digestive enzyme activity can be affected by feeding behavior, biochemical composition of food and onset of sexual maturity. Comparing carnivorous to omnivorous fish, greater protease activity and lower carbohydrase activity can be observed in the former species [21]. In the present study, the diet composition and experimental days did not influence significantly proteolytic activity in the dourado intestine,

Table II. Weak proteolytic activity was observed in all intestinal segments for both enzymes, DAP IV and LAP, conditions that could contribute to a condition of macromolecule absorption in the intestine. The teleost has enterocytes in the posterior portion of the intestinal tract that are capable of extensive absorption of macromolecules for a prolonged period [8], [9]. After being absorbed by lysosomes and coupled with hydrolases these proteins can be digested intracellularly or released to the interstice [8]. In the salmon *Oncorhynchus masou*, absorptive capacity occurs in the larval stage, while in the species *O. mykiss*, in adulthood, both species have the hindgut site of absorption [22]. In the present study, the membrane-linked activity of proteases was weak, but intracellular DAP IV activity was present in the S1 and S2 segments and in the vacuoles of the posterior intestine, Fig. 2. Intracellular activity of LAP was also present, however only in the vacuoles of the posterior intestine. These observations indicate an intense intracellular protein breakdown. Thus, inclusion of bovine colostrum that has antitrypsin factor, inhibitor of elastase and $\alpha 1$ -antichymotrypsin, in the fish diet, seems not to have inhibited proteolytic activity.

Authors have observed that lipolytic activity is related to changes in food quantity and quality and development stage [23]–[27]. Reference [28], for instance, observed higher levels of lipase activity in juveniles of farmed sharpsnout seabream (*Diplodus puntazzo*) than those found in larvae. In the present study, the activity of NSE and LIP was weak in all intestinal segments, except by the moderate activity of NSE in the S2 of 20% LBC group after 30 days and in the S1 of 0% LBC group after 60 days. These results suggest that membrane-linked digestion is still not fully completed in the studied juveniles. Identical distribution of enzymatic activity in the four intestinal segments of juvenile dourado revealed an undetermined segment for lipid digestion, in contrast to the findings by [29] that observed greater lipid digestion and absorption in the hindgut of large-scaled gurnard, *Lepidotrigla cavillone*, a carnivorous Scorpaeniformes.

The acid phosphatases, enzymes present in the lysosomes, are related to intracellular digestion [29], [30]. In the adult large-scaled gurnard, [29] reported a strong activity of acid phosphatase in the middle and posterior intestine. In the adult snow trout (*Schizothorax curvifrons*), in contrast, [31] observed that the acid phosphatase activity gradually decreased in posterior intestinal direction. The authors suggested that the rectal part of the intestine plays no role in intracellular digestion of proteins. In our work, only the juvenile dourado that were fed 10% LBC revealed positive reaction in the S2 and S3 segments after 30 days, indicating that the intracellular degradation process in this stage is low.

The alkaline phosphatase plays a role in the absorption of nutrients such as lipids, glucose, calcium, and inorganic phosphate [32], [33]. According [19], the greater enzyme activity of alkaline phosphatase in the cranial region of the intestine suggests less absorption of nutrients in the posterior region; similar results were also registered for other fish species [29], [34]. In this work, a strong reaction of the ALP was observed in the three first intestinal segments, agreeing

with the results of the above authors. Although the juveniles that consumed 20% of LBC showed a strong reaction in segments S2 and S3 after 60 days, the inclusion of this bovine milk secretion in the diet of juveniles seems not to have great influence in ALP activity.

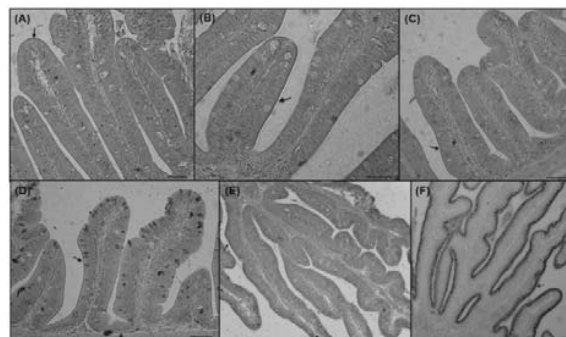


Fig. 1 Intestinal sections showing enzyme staining in the brush border of epithelial cells; (A) dipeptidyl aminopeptidase IV staining in the S2 of juvenile pacu fed diets containing 20% lyophilized bovine colostrum (LBC) after 60 experimental days; (B) leucine aminopeptidase staining in the rectum of juvenile pacu fed diet containing 10% LBC after 60 experimental days; (C) non-specific esterase staining in the S1 of juvenile pacu fed diet 20% LBC after 30 experimental days; (D) lipase staining in the S1 of juvenile pacu fed diet containing 10% LBC after 30 experimental days; (E) acid phosphatase staining in the S1 of juvenile pacu fed diet containing no LBC after 30 experimental days; (F) alkaline phosphatase staining in the S1 of a juvenile pacu fed diet containing 20% LBC after 30 experimental days; bar=50µm

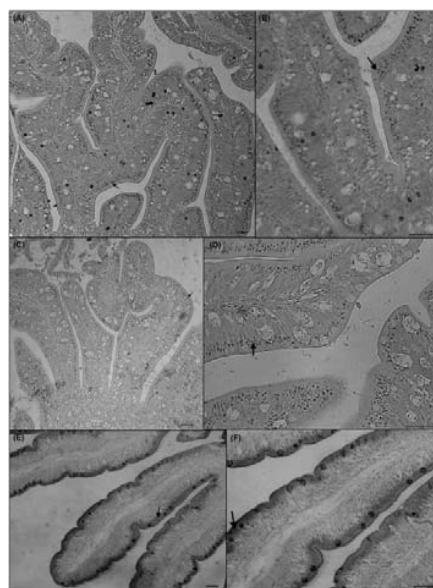


Fig. 2 Intestinal sections showing enzyme staining in the cytoplasm of epithelial cells; (A) and (B) dipeptidyl aminopeptidase IV staining in the posterior intestine of a juvenile dourado fed 10% of lyophilized bovine colostrum (LBC) after 30 experimental days; (C) and (D) leucine aminopeptidase staining in the posterior intestine of a juvenile dourado fed 10% of LBC after 30 experimental days; (E) and (F) alkaline phosphatase staining in the S1 of a juvenile dourado fed 0% of LBC after 60 experimental days; bar=40µm

TABLE II
ENZYME ACTIVITY IN THE INTESTINAL TRACT OF JUVENILE DOURADO *SALMINUS BRASILIENSIS* FED DIETS CONTAINING GRADED LEVELS OF LYOPHILIZED BOVINE COLOSTRUM

Enzyme	Experimental days	Diet	Intestinal segment			
			S1	S2	S3	Posterior intestine
DAP IV	30	0% LBC	+	+	+	+
		10% LBC	+	+	+	+
		20% LBC	+	+	+	+
	60	0% LBC	+	+	+	+
		10% LBC	+	+	+	+
		20% LBC	+	+	+	+
LAP	30	0% LBC	+	+	+	+
		10% LBC	+	+	+	+
		20% LBC	+	+	+	+
	60	0% LBC	+	+	+	+
		10% LBC	+	+	+	+
		20% LBC	+	+	+	+
NSE	30	0% LBC	+	+	+	+
		10% LBC	+	+	+	+
		20% LBC	+	++	+	+
	60	0% LBC	++	+	+	+
		10% LBC	+	+	+	+
		20% LBC	+	+	+	+
LIP	30	0% LBC	+	+	+	+
		10% LBC	+	+	+	+
		20% LBC	+	+	+	+
	60	0% LBC	+	+	+	+
		10% LBC	+	+	+	+
		20% LBC	+	+	+	+
ACP	30	0% LBC	-	-	-	-
		10% LBC	-	+	+	-
		20% LBC	-	-	-	-
	60	0% LBC	-	-	-	-
		10% LBC	-	-	-	-
		20% LBC	-	-	-	-
ALP	30	0% LBC	++	+++	++	+
		10% LBC	++	++	++	+
		20% LBC	++	++	++	+
	60	0% LBC	+++	++	++	+
		10% LBC	++	++	++	+
		20% LBC	++	+++	+++	+

Level of the staining intensity: (+++) strong; (++) moderate; (+) weak or (-) absent. 0% LBC – 0% of lyophilized bovine colostrum (LBC) inclusion in the diet; 10% LBC – 10% of LBC inclusion in the diet; 20% LBC – 20% of LBC inclusion in the diet.

IV. CONCLUSION

The present results suggest that intestinal enzyme activity in juvenile dourado is still not fully stimulated since weak activity was observed for almost all enzymes studied and that bovine colostrum, a rich source of protein, did not cause significant alteration in enzyme activity.

REFERENCES

- [1] A. Huguet, B. Sève, J. Le Dividich, and I. Le Huërou-Luron, "Effects of a bovine colostrum-supplemented diet on some gut parameters in weaned piglets", *Reproduction Nutrition Development*, vol. 46, pp. 167-178, 2006.
- [2] A.L. Lima, P. Pauletti, I. Susin, and R. Machado-Neto, "Fluctuation of serum variables in goats and comparative study of antibody absorption in newborn kids using cattle and goat colostrum", *Brazilian Journal of Animal Science*, vol. 38, pp. 2211-2217, 2009.
- [3] D.B. Moretti, L. Kindlein, P. Pauletti, and R. Machado-Neto, "IgG absorption by Santa Ines lambs fed Holstein bovine colostrum or Santa Ines ovine colostrum", *Animal*, vol. 4, pp. 933-937, 2010.
- [4] A.P.O. Rodrigues, P. Pauletti, L. Kindlein, J.E.P. Cyrino, E.F. Delgado, and R. Machado-Neto, "Intestinal morphology and histology of the striped catfish *Pseudoplatystoma fasciatum* (Linnaeus, 1766) fed dry diets", *Aquaculture Nutrition*, vol. 15, pp. 55-563, 2009.
- [5] P. Bodammer, C. Maletzki, G. Waitz, and J. Emmrich, "Prophylactic application of bovine colostrum ameliorates murine colitis via induction of immunoregulatory cells", *Journal of Nutrition*, vol. 141, pp. 1056-1061, 2011.
- [6] D.B. Moretti, W.M. Nardi, A.L. Lima, P. Pauletti, I. Susin, and R. Machado-Neto, "Enzyme activity in the small intestine of goat kids during the period of passive immunity acquisition", *Small Ruminant Research*, vol. 105, pp. 321-328, 2012.
- [7] N.N. Pandey, A.A. Dar, D.B. Mondal, and L. Nagaraja, "Bovine colostrum: A veterinary nutraceutical", *Journal of Veterinary Medicine and Animal Health*, vol. 3, pp. 31-35, 2011.
- [8] L.J. Schep, I.G. Tucker, G. Young, R. Ledger, and A.G. Butt, "Controlled release opportunities for oral peptide delivery in aquaculture", *Journal of Controlled Release*, vol. 59, pp. 1-14, 1999.

- [9] R.L. Barbieri, and F.J. Hernández-Blazquez, "Análise ultra-estrutural da absorção intestinal de macromolécula protéica com o uso de peixe como modelo experimental", *ConScientiae Saúde*, vol. 1, pp. 21-30, 2002.
- [10] K. Opuszynski, and J.V. Shireman, "Digestive mechanisms (book style)". In *Herbivorous Fishes: Culture and Use for Weed Management*, K. Opuszynski and J.V. Shireman, Boca Raton, FL: CRC Press, 1995, pp.21-31.
- [11] R. Ledger, I.G. Tucker, and G.F. Walker, "The metabolic barrier of the lower intestinal tract of salmon to the oral delivery of protein and peptide drugs", *Journal of Controlled Release*, vol. 85, pp. 91-103, 2002.
- [12] D.M. Fracalossi, G. Meyer, F.M. Santamaria, M. Weingastner, and E. Zaniboni Filho, "Desempenho do jundiá, *Rhamdia quelen*, e do dourado, *Salminus brasiliensis*, em viveiros de terra na Região Sul do Brasil", *Acta Scientiarum*, vol. 26, pp. 345-352, 2004.
- [13] Association of Official Analytical Chemists. Official methods of analysis, 18th ed. vol. 2, Arlington, VA: AOAC, 2004.
- [14] S.S. Rodrigues, and E. Menin, "Anatomia do tubo digestivo de *Salminus brasiliensis* (Cuvier, 1818) (Pisces, Characidae, Salmininae)", *Biotemas*, vol. 21, pp. 65-75, 2008.
- [15] Z. Lodja, "Studies on Dipeptidyl(Amino)Peptidase IV (Glycyl-Proline Naphthylamidase)", *Histochemistry*, vol. 59, pp. 153-166, 1979.
- [16] J.D. Bancroft, "Enzyme histochemistry", in *Theory and Practice of Histochemical Techniques*, vol. 4, J.D. Bancroft, and A. Stevens, New York, NY: Churchill Livingstone, 1996, pp.391-410.
- [17] K.N. Hirji, and W.A.M. Courtney "Leucine aminopeptidase activity in the digestive tract of perch, *Perca fluviatilis* L", *Journal of Fish Biology*, vol. 21, pp. 615-622, 1982.
- [18] A. Gawlicka, S. Teh, S.S.O. Hung, E. Hinton, and J. De Li Noüe, "Histological and histochemical changes in the digestive tract of white sturgeon larvae during ontogeny", *Fish Physiology and Biochemistry*, vol. 14, pp. 357-371, 1995.
- [19] B. Tengjaroenkul, B.J. Smith, T. Caceci, and S.A. Smith, "Distribution of intestinal enzyme activities along the intestinal tract of cultured Nile tilapia, *Oreochromis niloticus* L", *Aquaculture*, vol. 182, pp. 317-327, 2000.
- [20] V.V. Kuz'mina, "Classical and modern concepts in fish digestion", in *Feeding and Digestive Functions of Fishes*, J.E.P. Cyrino, D.B. Bureau, and B.G. Kapoor, Enfield, NH: Science Publishers, 2008, pp. 85-154.
- [21] V.V. Kuz'mina, and A.G. Gelman, "Membrane-linked digestion in fish", *Reviews in Fisheries Science*, vol. 5, pp. 99-129, 1997.
- [22] E. McLean, B. Rønsholdt, C. Sten, and Najamuddin, "Gastrointestinal delivery of peptide and protein drugs to aquaculture teleosts", *Aquaculture*, vol. 177, pp. 231-247, 1999.
- [23] J. Walford, and T.J. Lam, "Development of digestive tract and proteolytic enzyme activity in seabass (*Lates calcarifer*) larvae and juveniles", *Aquaculture*, vol. 109, pp. 187-05, 1993.
- [24] J.L. Zambonino Infante, and C.J. Cahu, "High dietary lipid levels enhance digestive tract maturation and improve *Dicentrarchus labrax* larval development", *Journal of Nutrition*, vol. 129, pp. 1195-1200, 1999.
- [25] V. Buchet, J.L. Zambonino Infante, and C.L. Cahu, "Effect of lipid level in a compound diet on the development of red drum (*Sciaenops ocellatus*) larvae", *Aquaculture*, vol. 184, pp. 339-347, 2000.
- [26] M.S. Izquierdo, J. Socorro, L. Arantzamendi, and C.M. Hernandez-Cruz, "Recent advances in lipid nutrition in fish larvae", *Fish Physiology and Biochemistry*, vol. 22, pp. 97-107, 2000.
- [27] S. Morais, M. Lacuisse, L.E.C. Conceição, M.T. Dinis, and I. Rønnestad, "Ontogeny of the digestive capacity of Senegalese sole (*Solea senegalensis*), with respect to digestion, absorption and metabolism of amino acids from *Artemia*", *Marine Biology*, vol. 145, pp. 243-50, 2004.
- [28] B. Savona, C. Tramati, and A. Mazzola, "Digestive enzymes in larvae and juveniles of farmed sharpnose seabream (*Diplodus puntazzo*) (Cetti, 1777)", *The Open Marine Biology Journal*, vol. 5, pp. 47-57, 2011.
- [29] Z. Kozarić, Z. Petrinc, S. Kužir, E. Gjurčević, and B. Baždarić, "Histochemical analyses of digestive enzymes in the intestine of adult large-scale gurnard (*Lepidotrigla cavillone*, Lacepède, 1801)", *Anatomia, Histologia, Embryologia*, vol. 40, pp. 314-320, 2011.
- [30] K. Baintner, 1994, "Demonstration of acidity intestinal vacuoles of the suckling rat and pig", *Journal of Histochemistry and Cytochemistry*, vol. 42, pp. 231-238, 1994.
- [31] I. Hussain, and A. Channa, "Histochemical distribution of lipase and acid phosphatase in the intestinal tract of the snow trout, *Schizothorax curvifrons* Heckel", *Journal of Biological Sciences*, vol. 10, pp. 643-647, 2010.
- [32] Y. Dupuis, S. Tardivel, Z. Poremska, and P. Fournier, "Effect of some phosphatase inhibitors on intestinal calcium transfer", *International Journal of Biochemistry*, vol. 23, pp. 175-180, 1991.
- [33] A. Mahmood, F. Yamagishi, R. Eliakim, K. DeSchryver-Kecsckemeti, T.L. Gramlich, and D.H. Alpers, "A possible role for rat intestinal surfactant-like particles in transepithelial triacylglycerol transport", *Journal of Clinical Investigation*, vol. 93, pp. 70-80, 1994.
- [34] Z. Kozarić, S. Kužir, Z. Petrinc, E. Gjurčević, and A. Opačak, "Histochemical distribution of digestive enzymes in intestine of goldline, *Sarpa salpa* L. 1758", *Journal of Applied Ichthyology*, vol. 22, pp. 43-48., 2006.

Débora B. Moretti born in Cerquilho, São Paulo/Brazil in August 19, 1983. She graduated in Biological Sciences at the Universidade Estadual Paulista "Julio de Mesquita Filho", Botucatu, São Paulo, Brazil, in 2005 and earned her MSc and Ph.D. at Luiz de Queiroz College of Agriculture (ESALQ), University of São Paulo, Brazil. Her research activities are related to animal physiology with focus on the supply of bovine colostrum for other species, including fish, and its effect on the serum proteins concentrations and the development of the gastrointestinal tract. Currently she is a postdoctoral student from USP/Brazil and published twelve papers in international journals.