

# Periodontal Disease or Cement Disease? New Frontier in the Treatment of Periodontal Disease in Dogs

C. Gallottini, W. Di Mari, A. Amaddeo, K. Barbaro, A. Dolci, G. Dolci, L. Gallottini, G. Barraco, S. Eramo

**Abstract**—A group of 10 dogs (group A) with Periodontal Disease in the third stage, were subjected to regenerative therapy of periodontal tissues, by use of nano hydroxy apatite (NHA). These animals induced by general anesthesia, were treated by ultrasonic scaling, root planning, and at the end by a mucogingival flap in which it was applied NHA. The flap was closed and sutured with simple steps. Another group of 10 dogs (group B), control group, was treated only by scaling and root planning. No patient was subjected to antibiotic therapy. After three months, a check was made by inspection of the oral cavity, radiography and bone biopsy at the alveolar level. Group A showed a total *restitutio ad integrum* of the periodontal structures, and in group B still mild gingivitis in 70% of cases and 30% of the state remains unchanged. Numerous experimental studies both in animals and humans have documented that the grafts of porous hydroxyapatite are rapidly invaded by fibrovascular tissue which is subsequently converted into mature lamellar bone tissue by activating osteoblast. Since we acted on the removal of necrotic cementum and rehabilitating the root tissue by polishing without intervention in the ligament but only on anatomical functional interface of cement-blasts, we can connect the positive evolution of the clinical-only component of the cement that could represent this perspective, the only reason that Periodontal Disease become a Cement Disease, while all other clinical elements as nothing more than a clinical pathological accompanying.

**Keywords**—Nanoidroxiapatite, Parodontal Disease, Regenerative Therapy.

## I. INTRODUCTION

**I**N the light of the scientific literature, the regenerative therapy of furcation lesions [2]-[17], appears not to have happened. We then wanted to evaluate the clinical response of Nano-hydroxyapatite than in previous tests [18]-[24], had shown an ability off again, regenerative, specifically oriented towards the mesenchymal tissues including fibrous tissue,

C. Gallottini is with the, ADI, Italian Dental Academy and Italian Dental Association, Roma, Italy. (e-mail: claudio.gallottini@adivet.it).

W. Di Mari is with the Director of Veterinary and Kennelclubs, Guardia di Finanza Military Police, Roma, Italy.

A. Amaddeo is Vet in Roma, Italy.

K. Barbaro, is with the Istituto Zooprofilattico Sperimentale Lazio e Toscana, Office of Biotechnology, Roma, Italy.

G. Barraco, and S. Eramo are with the Faculty of Medicine, Department of Dentistry, University of Perugia, Italy, Perugia, Italy.

A. Dolci is with the Faculty of Medicine, Department of Dentistry, University of Tor Vergata, Roma, Italy.

G. Dolci is with the, ADI, Italian Dental Academy and Italian Dental Association, Roma, Italy.

L. Gallottini is with the Maxillo-Facial and Dental Sciences Department, Sapienza University of Rome, Roma, Italy.

dentin and enamel, and decided to test its possible response in the functional anatomy of the root as a whole component that should interface with the supporting tissues. Given that the literature informs us of the fact that the techniques proposed so far, even the most complex show significant results only on single-rooted or in multi-rooted teeth but do not compromise on truck, we have developed a research protocol [1], absolutely comparable to a case study and methodology found in the bibliography:

1. The epidemiological catchment is the same one used by other authors with the particularity that in our case we focused more on injury of the dental gallow seat of failures with the techniques currently proposed;
2. With our technique we perform only a full-thickness flap, scaling and polishing, and then we put material that adheres to the essential feature of the operative site and then suturing the flap with simple steps. The material does not require maintenance system *in situ* and, in addition, is not colonized epithelium, thereby acting not only as a therapeutic substance inductor but also suitable for the formation of a long epithelial attachment. And 'therefore extremely simplified technique of execution that does not require a reworking much less the use of structures to guide (membranes) and/or peripheral measures (application of titanium cages with bone screws attached to support and maintain membranes in situ and bone fillers).

## II. MATERIALS AND METHODS

Inside of a dog kennel, have been identified a group of n. 20 male dogs, aged between 7 and 11 years of age suffer from periodontal disease to Stage III. The group is homogeneous by gender, stage of disease, breeding in captivity and feeding regime. These subjects, after excluding other pathologies and therapies in place of type antibiotic or anti-inflammatory, were subjected to periodontal therapy. To this end, each dog was subjected to sedation and / or general anesthesia by intubation, objective examination of the oral cavity using a special dental-chart and radiographic examination.

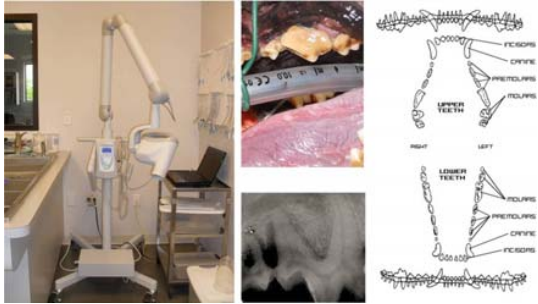


Fig. 1 X-ray equipment and dental chart used

A group of 10 subjects (called group A), will be treated by regenerative periodontal therapy, consisting of ultrasonic scaling, root planing and affixing by osteo-muco-gingival flap of Nano-Hydroxyapatite (NHA), Neo Active Apatite Powder Ghimas®;

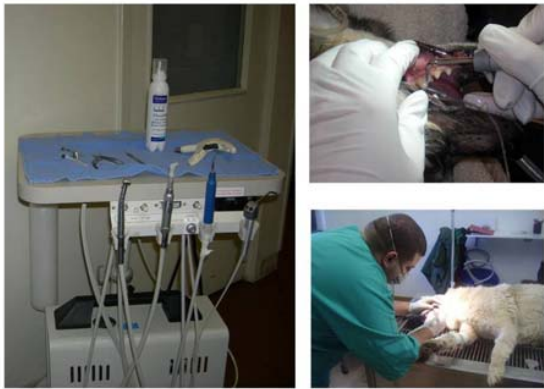

Fig. 2 Ultrasonic scaling

A second group of 10 animals, (called group B), will serve as a control group, to which it will carry only a standard treatment, an ultrasonic scaling with root planing. In both groups do not follow the treatment antibiotic therapies.



Fig. 3 NHA mixed with sterile water, ready to use

The powder NHA can be mixed with sterile water, obtaining a prepared paste, to be applied on the site to be treated or, alternatively, as in our case, the granules of NHA may be affixed directly on the site periodontal and

amalgamated with the patient's blood. For the application of Nano Hydroxyapatite is carried out, a flap osteo-muco-gingival to allow a broader contact with the periodontal structures damaged.

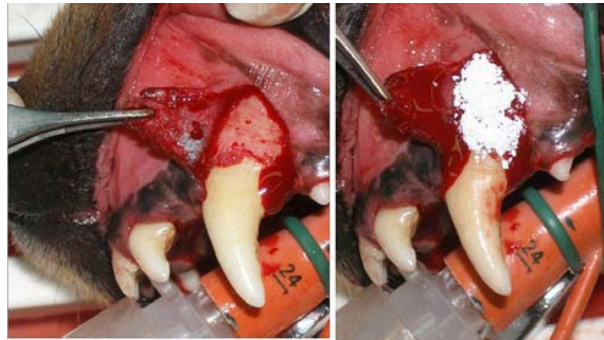


Fig. 4 Flap and direct application of NHA on osteo-muco-gingival flap

Each dog is checked quarterly. The controls are based on a thorough dental examination (evaluation of the mobility of the teeth and periodontal probing), x-ray examinations to verify the effectiveness of spontaneous regeneration of the periodontal structures and bone biopsy. The bone biopsies are performed by the alveolar area, placed in Helly fixative and evaluated, comparing subjects treated with NHA with biopsies of the cases treated with standard therapy.

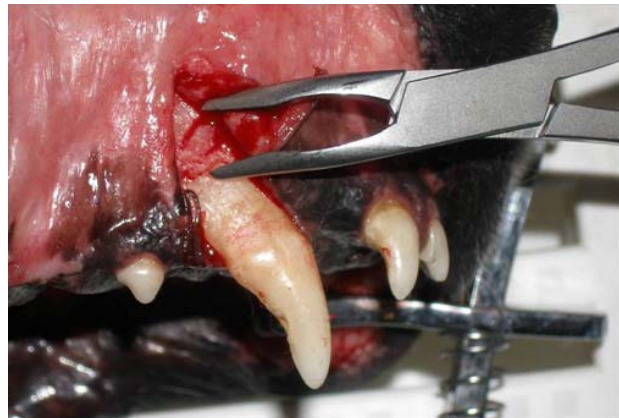

Fig. 5 Alveolar bone biopsy

After fixation, the biopsies are decalcified by the method Kristensen, or by the method of formic acid, according to the following technique: biopsy immersed in a mixture containing 5% formic acid (99%) with more than 4% of a solution of hydrochloric acid (37%). After a few days, these biopsies are washed with water, subjected to dehydration and embedded in paraffin. The blocks are then sectioned with a thickness of 5 µm and the slices obtained are subjected to histochemical examination with colorimetric methods, Schaffer and Schmorl. With these two methods, you can highlight the newly formed bone tissue or imperfectly calcified.

II. RESULTS

Those belonging to group A, under general anesthesia, were prima facie subject to inspection of the oral cavity and periodontal probing and found in all animals exceeding the physiological 3mm of the gingival sulcus in the dog, which has become a pocket between 7 and 10mm measured on the canines. It was also detected in all subjects, the presence of a fistula outcome of the inflammatory reaction in the gingival level mucus, which is typical in the course of periodontal disease, the subjects were then treated with ultrasonic scaling, polishing, root planing, removal of bone biopsy at the alveolar level, and finally, the NHA was applied directly on root cementum and alveolar bone through mucogingival flap surgery.

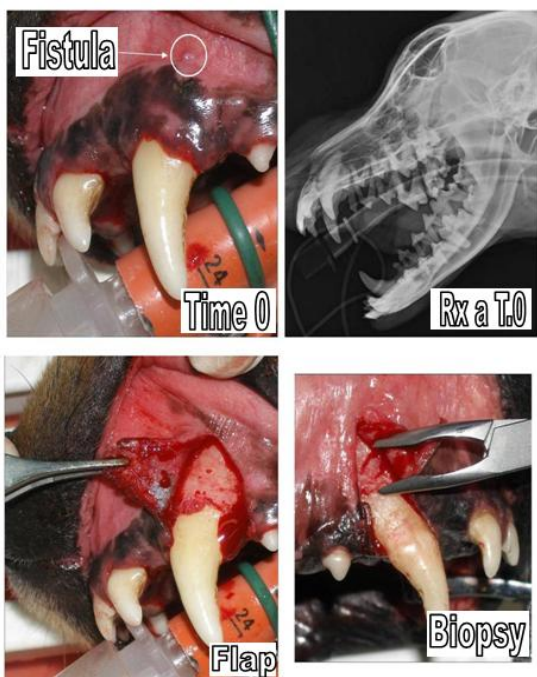


Fig. 6 First step in the treatment protocol of single-rooted

The granules of NHA were blended directly with the blood present in situ, in order to facilitate the adhesion and the containment. Histological examination of the biopsies, were detected in 60% of subjects granulomatous periostitis, osteitis-periostitis in 30% pio-granulomatous with necrotic areas, in 10% of phenomena-osteolytic bone resorption, confirmed radiologically.

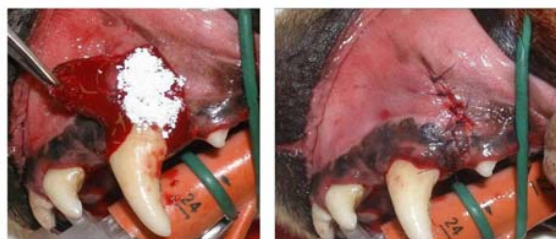

Fig. 7 Application of NHA and biopsy

Subsequently, the flap was closed and sutured with simple steps.

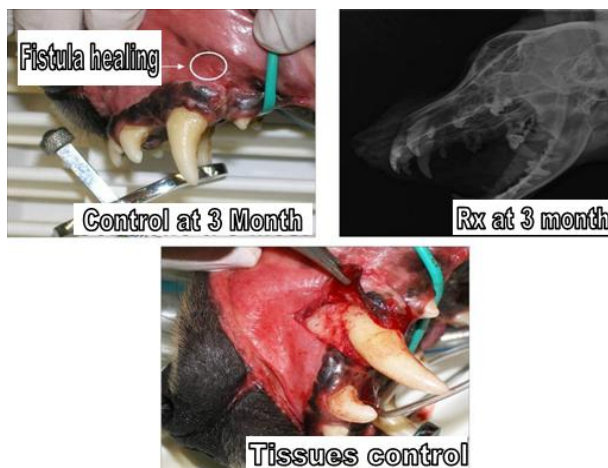


Fig. 8 Control at three months

At 3 months after treatment, subjects, sedated and anesthetized, were subjected to re-inspection of the oral cavity, periodontal probing and evaluation of the mobility of individuals treated dental elements. 100% of the subjects in group A were obtained thanks to regenerative therapy, the complete *restitutio ad integrum* of the periodontal tissue, with reduction of the periodontal pocket from 7 to 3.5-4mm-10mm, consolidation of teeth with radiographic evidence. A new biopsy was performed and it was inferred from reports in 30% of subjects hypertrophy of the fibrous ligament periosteal remaining 70% in the absence of inflammatory infiltrates or phenomena of bone resorption.

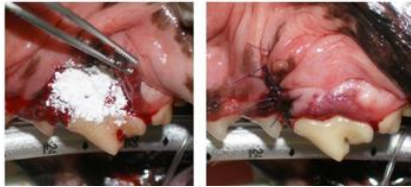
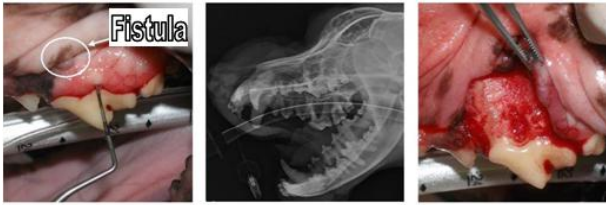
Fig. 9 First step of multi-rooted

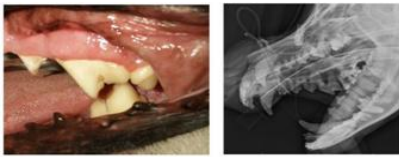

Fig. 10 Control at three months

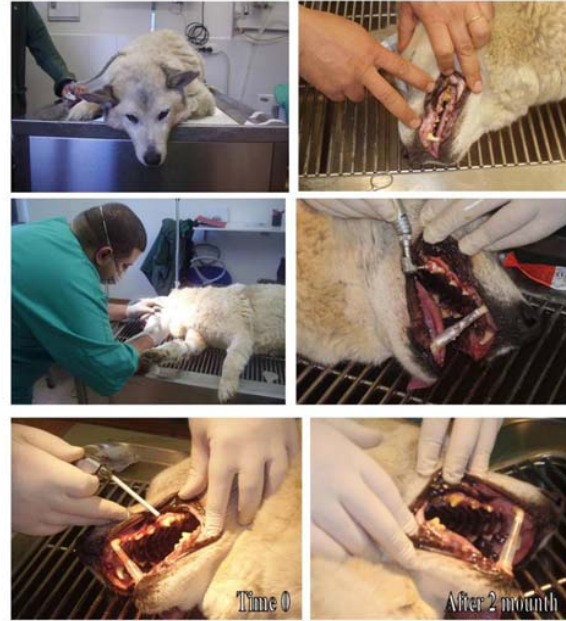

Fig. 11 Standard protocol of the control group

Clinical evidence of the disappearance of the pocket, seen as a site of least resistance, manifested by the disappearance of the fistula, an element that occurs in the course of the disease, in relation to an infectious process that colonizes a site with a picture of lesion and inflammatory which then becomes the primary cause of the fistula, the bacterium being only the secondary agent that infects anatomical site already compromised. If the fistula heals is only because there is an anatomical healing of the injured party, accompanied by the healing etiological, for the disappearance of the site of least resistance, and it's possible to over bacterial infection that represents the transition pathophysiological agent of production of 'exudate puruloide which the patient reacts with the formation of a drainage fistula manifested by the same.

The animals of group B, the control group, are subject to inspection of the oral cavity, periodontal probing, ultrasonic scaling, polishing, and polishing root. The subjects have a gingival stomatitis-spread with periodontal pockets between 7 and 10mm, accompanied by widespread mobility of teeth most affected by periodontal disease. Two months after the standard treatment, is detected in 70% of cases a mild persistent gingivitis, a reduction of periodontal pockets attested between 5 and 7mm, with retained mobility of teeth affected by periodontal disease. The remaining 30% of the animals do not show significant improvements. In 100% of the animals there is no disappearance of mucus fistula gum.

#### IV. CONCLUSION

Numerous experimental studies both in animals and in humans have also documented that the porous hydroxyapatite implants are quickly invaded by fibrovascular tissue which is subsequently converted into mature lamellar bone.

Histologically, the osteoid tissue shows the presence of osteoblastic cells vital and multinucleated giant cells, suggesting an active process of newly formed bone remodeling.

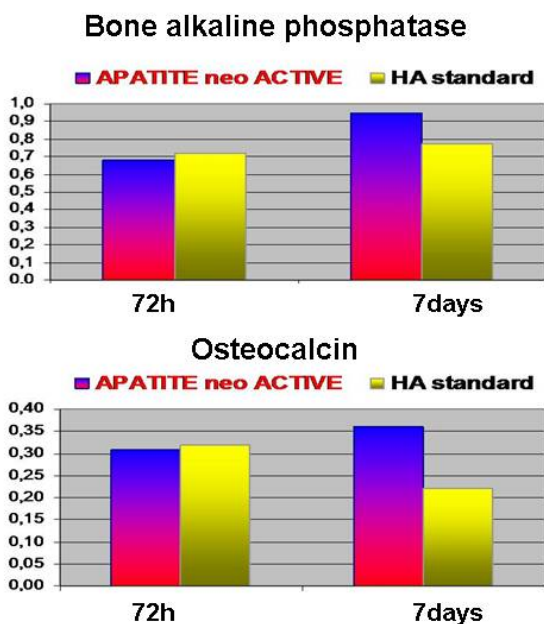


Fig. 12 The bone alkaline phosphatase and osteocalcin are the most significant markers of differentiation in the sense osteogenico. Per regarding the osteogenic differentiation observed no significant differences between the materials tested at 72 hours, 7 days a nanoidrossiapatite active induced a greater production of differentiation markers (bone alkaline phosphatase and osteocalcin) than hydroxyapatite standard

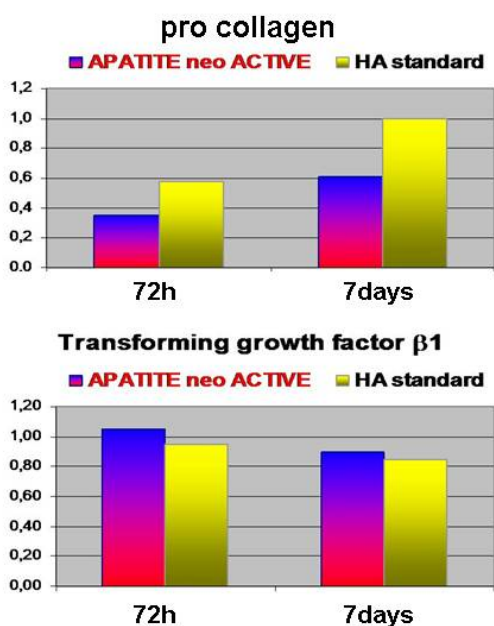


Fig. 13 Procollagen type I and Transforming Growth Factor  $\beta$ 1 are good indices of metabolic activity of osteoblasts

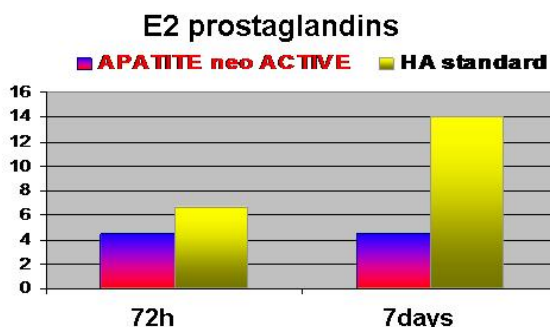


Fig. 14 As part of the inflammatory response, the hydroxyapatite-active resulted in a decreased synthesis of prostaglandin E2 compared with hydroxyapatite standard and no production of pro-inflammatory cytokines (interleukin-6 and tumor necrosis factor- $\alpha$ ) or 72 nor hours to 7 days

Numerous studies have already shown that the biocompatibility of hydroxyapatite binds chemically to the bone and does not induce toxicities or local or systemic inflammation. The results obtained in our study, demonstrate the disappearance of the inflammatory process and the recovery of the attack gingival, which cannot be ascribed to antibiotic therapy, as for other excluded from the research protocol. In light of the above, having acted on the removal of necrotic cementum and rehabilitating the root tissue by polishing without intervention in the field but only on the ligamentous anatomy functional interface of the cement - blasts, we believe we can connect the positive evolution of the single - clinical component of the cement that could represent this point of view the only causal factor of periodontal disease that would become a cementopatia, while all other clinical elements as nothing more than a clinical pathological accompanying.

REFERENCES

- [1] Gallottini C, Barraco G, Dolci G, Edizioni Accademiche Italiane, 2013 – ISBN 978-3-639-47472-5 – New Frontiers in the Treatment of Parodontal Disease in Dogs.
- [2] Pontoriero R, Nyman S, Ericsson I, Lindhe J. - J Clin Periodontol. 1992 Mar; 19(3): 159-63. Guided Tissue Regeneration in Surgically-Produced Furcation Defects. An Experimental Study in the Beagle Dog.
- [3] Giargia M, Ericsson I, Lindhe J, Berglundh T, Neiderud AM. J Clin Periodontol. 1994 Aug; 21(7): 457-64. Tooth Mobility and Resolution of Experimental Periodontitis. An Experimental Study in the Dog.
- [4] Lindhe J, Pontoriero R, Berglundh T, Araujo. J Clin Periodontol. 1995 Apr; 22(4): 276-83. The Effect of Flap Management and Bioresorbable Occlusive Devices in GTR Treatment of Degree III Furcation Defects. An Experimental Study in Dogs.
- [5] Araújo M, Berglundh T, Lindhe J. J Clin Periodontol. 1996 Jun; 23(6):532-41. The Periodontal Tissues in Healed Degree III Furcation Defects. An Experimental Study in Dogs.
- [6] J Clin Periodontol. 1997; 24: 738-746. M. G. Araujo, T. Berglundh and J. Lindhe. On the Dynamics of Periodontal Tissue Formation in Degree III Furcation Defects.
- [7] J Clin Periodontol. 1998; 25: 524-530. M. G. Araujo and J. Lindhe. GTR Treatment of Degree III Furcation Defects Following Application of Enamel Matrix Proteins.
- [8] M. G. Araujo, T. Berglundh and J. Lindhe. J Clin Periodontol. 1998; 25: 253-259. GTR treatment of Degree III Furcation Defects with 2 Different Resorbable Barriers.
- [9] J Clin Periodontol. 1999; 26: 643-652. M. G. Araujo, T. Berglundh, T. Albrektsson and J. Lindhe. Bone Formation in Furcation Defects.

- [10] J Clin Periodontol. 2003; 29: 1122–1131. M. G. Araujo, M. Sonohara, R. Hayacibara, G. Cardaropoli and J. Lindhe. Lateral Ridge Augmentation by the Use of Grafts Comprised of Autologous Bone or a Biomaterial. An Experiment in the Dog.
- [11] J Clin Periodontol. 2003; 30: 855–861. M. Araujo, R. Hayacibara, M. Sonohara, G. Cardaropoli and J. Lindhe. Effect of enamel matrix proteins (Emdogains) on Healing After Re-Implantation of “Periodontally Compromised” Roots.
- [12] J Clin Periodontol. 2004; 31: 845–849. N. U. Zitzmann, T. Berglundh, I. Ericsson and J. Lindhe. Pontaneous Progression of Experimentally Induced Periimplantitis.
- [13] Clin. Oral Impl. Res. 2010; 21; 55–64. Araujo MG, Liljenberg B, Lindhe J. Dynamics of BioOsss Collagen Incorporation in Fresh Extraction Wounds: An Experimental Study in the Dog.
- [14] Clin. Oral Impl. Res. 2010; 21; 445–454. Araujo MG, Liljenberg B, Lindhe J. b-Tricalcium Phosphate in the Early Phase of Socket Healing: An Experimental Study in the Dog.
- [15] Clin. Oral Impl. Res. 2011; 22; 1–8. Araujo MG, Linder E, Lindhe J. Bio-Osss Collagen in the buccal gap at immediate implants: a 6-month study in the dog.
- [16] Clin. Oral Impl. Res. 2011; 22; 9–13. Araujo MG, Lindhe J. Socket Grafting with the Use of Autologous Bone: An Experimental Study in the Dog.
- [17] Clin. Oral Impl. Res. 2012; 00; 1–6. Lindhe J, Araujo M. G, Bufler M, Liljenberg B. Biphasic Alloplastic Graft Used to Preserve the Dimension of the Edentulous Ridge.
- [18] Holmes R, Mooney V, Bucholz R, et al.: A Coralline Hydroxylapatite Bone Graft Substitute. Clin Orthop. 1984; 188: 252-62
- [19] Benqué EP, Gineste M, Heughebaert M: Etude Histologique de la Biocompatibilité des Cristaux d’Hydroxyapatite en Chirurgie Parodontale. J Biol Buccale. 1985; 13: 271-82
- [20] Kent JN: Reconstruction of the Alveolar Ridge with Hydroxyapatite. Dent Clin North Am. 1986 Apr; 30 (2): 231-57
- [21] Carranza FA Jr, Kenney EB, Lekovic V, Talamante E, Valencia J, Dimitrijevic B: Histologic Study of Healing of Human Periodontal Defects after Placement of Porous Hydroxylapatite Implants. J Periodontol. 1987 Oct; 58 (10): 682-8
- [22] Donath K, Rohrer MD, Hormann K: Mobile and Immobile Hydroxyapatite Integration and Resorption and Its Influence on Bone. J Oral Implantol. 1987; 13 (1): 120-7
- [23] Minegishi D, Lin C, Noguchi T, Ishikawa I: Porous Hydroxyapatite Granule Implants in Periodontal Osseous Defects in Monkeys. Int J Periodontics Restorative Dent. 1988; 8 (4): 50-63
- [24] Boone PS, Zimmerman MC, Gutteling E, Lee CK, Parsons JR, Langrana N: Bone Attachment to Hydroxyapatite Coated Polymers. J Biomed Mater Res. 1989 Aug; 23 (A2 Suppl): 183-99.

**C. Gallottini**, in 2004 become graduate in Veterinary Medicine with a thesis on dental disease in zoo animals; in 2007 he founded the Italian Dental Society for Human and Veterinary Dentistry (IDS, [www.odontovet.eu](http://www.odontovet.eu)); in 2008 wins in Italy a PRIN project (Research Project of Relevant National Interest) funded by the Italian Ministry of University and Research; in 2012 become a Ph.D. graduate with a thesis on new therapeutic approaches in the treatment of periodontal disease in dogs; in 2012 A.D.I. (Italian Dentists Association and Italian Dental Academy, [www.adi-informa.it](http://www.adi-informa.it)) appointed him head of the veterinary section ([www.avidet.it](http://www.avidet.it)). Speaker at numerous international conferences in EU and extra-EU countries.