

Protective Effect of Thymoquinone against Arsenic-Induced Testicular Toxicity in Rats

Amr A. Fouad, Waleed H. Albuali, Iyad Jresat

Abstract—The protective effect of thymoquinone (TQ) was investigated in rats exposed to testicular injury induced by sodium arsenite (10mg/kg/day, orally, for two days). TQ treatment (10mg/kg/day, intraperitoneal injection) was applied for five days, starting three day before arsenic administration. TQ significantly attenuated the arsenic-induced decreases of serum testosterone, and testicular reduced glutathione level, and significantly decreased the elevations of testicular malondialdehyde and nitric oxide levels resulted from arsenic administration. Also, TQ ameliorated the arsenic-induced testicular tissue injury observed by histopathological examination. In addition, TQ decreased the arsenic-induced expression of inducible nitric oxide synthase and caspase-3 in testicular tissue. It was concluded that TQ may represent a potential candidate to protect against arsenic-induced testicular injury.

Keywords—Thymoquinone, arsenic, testes, rats.

I. INTRODUCTION

INORGANIC arsenic is a major environmental pollutant with multiple toxic effects. High arsenic level in the ground water is the major source of arsenic exposure [1]. Also, arsenic contamination may occur due to its industrial uses [2]. Acute and chronic arsenic exposure intoxication is associated with impairment of male reproductive function, suppression of spermatogenesis and androgenesis, and reduction of the weight of testes and accessory sex organs [3]. Growing evidence supports the role of oxidative stress, increased generation of reactive oxygen species, and inflammation with increased production of inflammatory mediators in the pathogenesis of arsenic-induced organ damage [4], [5]. Also, previous studies demonstrated the effectiveness of antioxidants and anti-inflammatory agents against arsenic-induced testicular toxicity [6], [7].

TQ is the main active component of *Nigella sativa* seed oil. TQ possesses prominent antioxidant and anti-inflammatory activities [8], [9]. Also, recent studies showed that TQ significantly improved semen quality and reproductive characteristics of mice exposed to heat stress [10], reestablished spermatogenesis after testicular injury due to chronic toluene exposure in rats [11], protected against

methotrexate-induced testicular tissue damage in mice [12], and attenuated testicular ischemia-reperfusion injury resulted from torsion-detorsion in mice [13]. However, to the best of our knowledge, this is the first study to investigate the protective effect of TQ against arsenic-induced testicular toxicity.

II. MATERIALS AND METHODS

A. Drugs and Chemicals

Sodium arsenite powder (Loba Chemie, India) was dissolved in normal saline, and TQ powder (Sigma-Aldrich Co., USA) was prepared in 1% aqueous solution of Tween 80. The doses of sodium arsenite and TQ used in the present study were selected based on our preliminary experiments and in accordance with previous reports [4], [12].

B. Animals and Treatments

Male Sprague-Dawley rats, weighing 250±10g were obtained from the Animal House, King Faisal University. The animals were housed at standard facilities (24 ± 1°C, 45 ± 5% humidity, and 12h light-12h dark cycle), supplied with standard laboratory chow and water *ad libitum*, and left to acclimatize for one week before the experiments. Experimental procedures were done in accordance with international guidelines for care and use of laboratory animals. The rats were randomly allocated to three groups (n = 8, each). The first (control) group received normal saline (vehicle of sodium arsenite), orally, for two days. The rats of the second and third groups received sodium arsenite (10mg/kg/day, orally, for two days). The animals of the second and third groups received a daily intraperitoneal injection of the TQ vehicle or TQ (10mg/kg), respectively, for five days starting three days before arsenic administration.

C. Sample Preparation and Biochemical Analysis

The rats were euthanized 24h following the last administration of sodium arsenite. Blood samples were collected through a puncture in the left ventricle, left for 60 min to clot, and centrifuged for 10min at 5000rpm. The obtained clear sera were stored at -80°C and subsequently serum testosterone level was measured using rat testosterone ELISA kit following the manufacturer's instructions (DRG Diagnostics, Germany).

The right testis of each animal was homogenized in cold potassium phosphate buffer (0.05 M, pH 7.4). The testicular homogenates were centrifuged at 5000 rpm for 10 min at 4°C. The resulting supernatant was used for determination of malondialdehyde (MDA), reduced glutathione (GSH), and

Amr A. Fouad is with the Department of Biomedical Sciences, Pharmacology Division, College of Medicine, King Faisal University, Al-Ahsa, Saudi Arabia (Primary address: Department of Pharmacology, Faculty of Medicine, Minia University, El-Minia, Egypt) (corresponding author to provide phone: +966501776517; e-mail: amrfouad65@yahoo.com).

Waleed H. Albuali is with the Department of Pediatrics, College of Medicine, King Faisal University, Al-Ahsa, Saudi Arabia.

Iyad Jresat is with the Department of Biomedical Sciences, Pathology Division, College of Medicine, King Faisal University, Al-Ahsa, Saudi Arabia.

nitric oxide (NO) levels using colorimetric assay kits according to the recommendations of the manufacturer (Biodiagnostic, Egypt).

D. Histopathological Examination

The left testis of each animal was fixed in Bouin's solution, dehydrated in ascending grades of ethanol and embedded in paraffin. Sections at 4- μ m were stained with hematoxylin and eosin (H&E), and examined under light microscope.

E. Immunohistochemical Examinations

Four μ m thick sections were deparaffinised, rehydrated, and endogenous peroxidase activity was blocked with 3% H₂O₂ in methanol. Sections were pre-treated in citrate buffer (pH 6.0), and were incubated with rabbit polyclonal anti-inducible nitric oxide synthase (iNOS) and anti-caspase-3 antibodies (Thermo Scientific, USA, dilution 1:100). The sections were incubated with biotinylated goat anti-polyvalent, then with streptavidin peroxidase and finally with diaminobenzidine plus chromogen. Slides were counterstained with hematoxylin, and were visualized under light microscope.

F. Statistical Analysis

The data are expressed as mean \pm S.E.M. The results were analyzed by one-way analysis of variance (ANOVA) followed by Tukey test for post hoc comparisons using SPSS for Windows (version 18). $P < 0.05$ was selected as the criterion for statistical significance.

III. RESULTS

Arsenic administration caused significant decreases of serum testosterone, and testicular GSH, and significant increases in testicular MDA and NO as compared to control group. However, TQ-treated rats showed significantly higher serum testosterone, testicular GSH, and significantly lower testicular MDA and NO as compared to arsenic group non-treated with TQ (Table I).

TABLE I
EFFECTS OF TQ TREATMENT ON SERUM TESTOSTERONE, AND TESTICULAR MDA, GSH, AND NO IN RATS EXPOSED TO ARSENIC (AS) TOXICITY

	Control	Vehicle + As	TQ + As
Testosterone (ng/ml)	2.65 \pm 0.19	1.01 \pm 0.09 ^a	2.14 \pm 0.26 ^b
MDA (nmol/g tissue)	28.19 \pm 3.47	71.73 \pm 5.26 ^a	40.52 \pm 6.31 ^b
GSH (mmol/g tissue)	8.37 \pm 0.65	2.69 \pm 0.12 ^a	7.04 \pm 0.58 ^b
NO (nmol/100 mg tissue)	51.48 \pm 3.57	98.19 \pm 6.33 ^a	70.21 \pm 5.72 ^b

The data are expressed as mean \pm S.E.M. n = 8 in each group.

^a $P < 0.05$ vs. control group, ^b $P < 0.05$ vs. vehicle + arsenic group.

Also, Fig. 1 shows that arsenic caused widespread necrosis vacuolization of the seminiferous tubular cells, associated with impaired spermatogenesis, and interstitial tissue edema.

However, TQ markedly ameliorated the arsenic-induced testicular damage and preserved spermatogenesis in most seminiferous tubules.

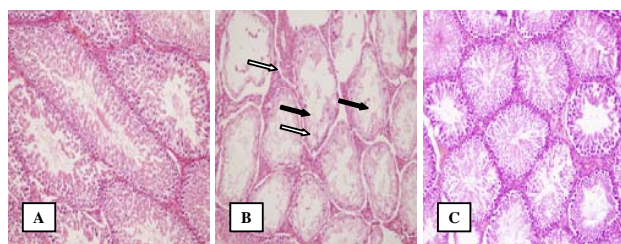


Fig. 1 Photomicrographs of rat testes (H&E, 200 \times). (A) control showing normal architecture of testicular tissue with normal spermatogenesis in seminiferous tubules; (B) vehicle plus arsenic showing widespread necrosis, vacuolar degeneration of seminiferous tubular cells (black arrows), marked reduction in spermatogenesis, and interstitial tissue edema (white arrows); (C) TQ plus arsenic showing a histological picture comparable to that of the control

In addition, increased expression of inducible nitric oxide synthase and caspase-3 in the cytoplasm of the cells of seminiferous tubules were observed in rats received sodium arsenite as compared to the control animals. TQ markedly reduced the arsenic-induced expression of inducible nitric oxide synthase and caspase-3 as compared to arsenic group non-treated with TQ (Figs. 2 and 3).

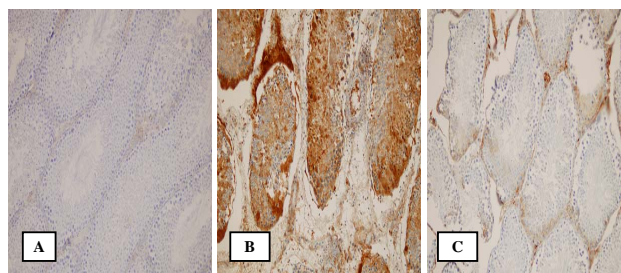


Fig. 2 Immunohistochemical staining (200 \times) of inducible nitric oxide synthase in rat testes. (A) control showing no expression of inducible nitric oxide synthase; (B) vehicle plus arsenic showing a marked increase in inducible nitric oxide synthase immunoreactivity in the cytoplasm of the cells of seminiferous tubules; (C) thymoquinone plus arsenic showing an obvious decrease in inducible nitric oxide synthase immunostaining. Brown color indicates inducible nitric oxide synthase positivity

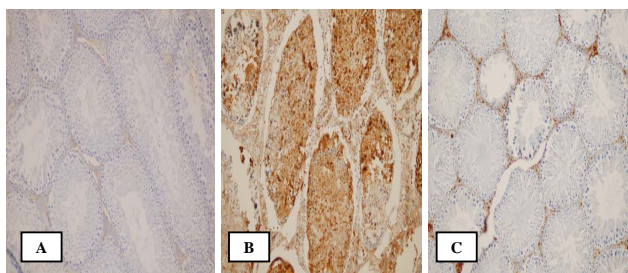


Fig. 3. Immunohistochemical staining (200 \times) of caspase-3 in rat testes. (A) control showing no expression of caspase-3; (B) vehicle plus arsenic showing a marked increase in caspase-3 immunoreactivity in the cytoplasm of the cells of seminiferous tubules; (C) thymoquinone plus arsenic showing an obvious decrease in caspase-3 immunostaining. Brown color indicates caspase-3 positivity

IV. CONCLUSION

The present work confirmed that oxidative stress, increased lipid peroxidation, depletion of antioxidant defenses, and increased production of inflammatory mediators are implicated in the pathogenesis of arsenic-induced testicular injury. In addition, it has been demonstrated that increased NO is involved in the pathogenesis of arsenic-mediated cytotoxicity [14]. This can be explained by the ability of inflammatory mediators to cause an up-regulation of iNOS enzyme which catalyzes the production of large amounts of NO which reacts with superoxide anion to generate peroxynitrite radical that causes further cell damage by nitrating cellular proteins and macromolecules [15], [16]. Also, excess NO depletes intracellular GSH increasing the susceptibility to oxidative stress [17].

TQ, the main active constituent isolated from *Nigella sativa* seed oil, exerts marked antioxidant activity, scavenges reactive oxygen radicals, suppresses lipid peroxidation, and maintains the antioxidant defense mechanisms during free radical reactions [8], [9]. Also, TQ inhibits iNOS activity and decreases NO production, and therefore prevents nitrosative tissue stress [11]. In addition, TQ exhibits significant anti-inflammatory activity because it reduces the release of inflammatory cytokines, and inhibits cyclooxygenase-2 the inducible form of cyclooxygenases thus decreasing the production of inflammatory prostaglandins [18]-[20]. It was also revealed that TQ decreased the arsenic-induced expression of caspase-3, an executioner of cell apoptosis, in the testicular tissue. This is in agreement with previous studies which showed that TQ provided a significant anti-apoptotic effect by inhibiting caspase-3 activity [21], [22]. Therefore, it could be stated that TQ protected against arsenic-induced testicular cell apoptosis. The reduced caspase-3 activity observed with TQ treatment may be due to its free radical scavenging activity, and anti-inflammatory action.

The results of the present study indicate that TQ significantly ameliorated arsenic-induced testicular injury in rats. The antioxidant, anti-inflammatory, and anti-apoptotic activities of TQ can be considered the main factors which are

responsible for the testicular protective effect. Therefore, TQ represents a potential therapeutic option to prevent the deleterious effect of arsenic exposure on the testes.

REFERENCES

- [1] W.A. Pott, S.A. Bengamin, R.S.H. Yang, "Pharmacokinetics, metabolism and carcinogenicity of arsenic," *Rev. Environ. Contam. Toxicol.*, vol. 169, pp. 165-214, 2001. W.-K. Chen, *Linear Networks and Systems* (Book style). Belmont, CA: Wadsworth, 1993, pp. 123-135.
- [2] H. Shi, X. Shi, K.J. Liu, "Oxidative mechanism of arsenic toxicity and carcinogenesis," *Mol. Cell. Biochem.*, vol. 255, pp. 67-78, 2004.
- [3] N. Pant, R.C. Murty, S.P. Srivastava, "Male reproductive toxicity of sodium arsenite in mice," *Hum. Exp. Toxicol.*, vol. 23, pp. 399-403, 2004.
- [4] J. Das, J. Ghosh, P. Manna, M. Sinha, P.C. Sil, "Taurine protects rat testes against NaAsO₂-induced oxidative stress and apoptosis via mitochondrial dependent and independent pathways," *Toxicol. Lett.*, vol. 187, pp. 201-210, 2009.
- [5] N. Singh, D. Kumar, K. Lal, S. Raisuddin, A.P. Sahu, "Adverse health effects due to arsenic exposure: modification by dietary supplementation of jaggery in mice," *Toxicol. Appl. Pharmacol.*, vol. 242, pp. 247-255, 2010.
- [6] P.S. Reddy, G.P. Rani, S.B. Sainath, R. Meena, Ch. Supriya, "Protective effects of N-acetylcysteine against arsenic-induced oxidative stress and reprotoxicity in male mice," *J. Trace Elem. Med. Biol.*, vol. 25, pp. 247-253, 2011.
- [7] A. Samadder, J. Das, S. Das, A.R. Khuda-Bukhsh, "Dihydroxyisosteviol-methyl-ester, an active biological component of *Pulsatilla nigricans*, reduces arsenic induced cellular dysfunction in testis of male mice," *Environ. Toxicol. Pharmacol.*, vol. 34, pp. 743-752, 2012.
- [8] C. Sankaranarayanan, L. Pari, "Thymoquinone ameliorates chemical induced oxidative stress and β -cell damage in experimental hyperglycemic rats," *Chem. Biol. Interact.*, vol. 190, pp. 148-154, 2011.
- [9] F. Basarslan, N. Yilmaz, S. Ates, T. Ozgur, M. Tutanc, V.K. Motor, V. Arica, C. Yilmaz, M. Inci, S. Buyukbas, "Protective effects of thymoquinone on vancomycin-induced nephrotoxicity in rats," *Hum. Exp. Toxicol.*, vol. 31, pp. 726-733, 2012.
- [10] S. Al-Zahrani, M. Mohany, S. Kandeal, G. Badr, "Thymoquinone and vitamin E supplementation improve the reproductive characteristics of heat stressed male mice," *J. Med. Plants Res.*, vol. 6, pp. 493-499, 2012.
- [11] M. Kanter, "Thymoquinone reestablishes spermatogenesis after testicular injury caused by chronic toluene exposure in rats," *Toxicol. Ind. Health*, vol. 27, pp. 155-166, 2011.
- [12] A. Gökçe, S. Oktar, A. Koc, Z. Yonden, "Protective effects of thymoquinone against methotrexate-induced testicular injury," *Hum. Exp. Toxicol.*, vol. 30, pp. 897-903, 2011.
- [13] A. Gökçe, S. Oktar, A. Koc, R. Gonenci, F. Yalcinkaya, Z. Yonden, M. Duru, "Protective effect of thymoquinone in experimental testicular torsion," *Urol. Int.*, vol. 85, pp. 461-465, 2010.
- [14] A.K. Bera, T. Rana, S. Das, S. Bandyopadhyay, D. Bhattacharya, D. Pan, S. De, S.K. Das, "L-ascorbate protects rat hepatocytes against sodium arsenite-induced cytotoxicity and oxidative damage," *Hum. Exp. Toxicol.*, vol. 29, pp. 103-111, 2010.
- [15] Y. Kobayashi, "The regulatory role of nitric oxide in proinflammatory cytokine expression during the induction and resolution of inflammation," *J. Leukoc. Biol.*, vol. 88, pp. 1157-1162, 2010.
- [16] S.M. Morris, T.R. Billiar, "New insights into the regulation of inducible nitric oxide synthesis," *Am. J. Physiol.*, vol. 266, pp. E829-E839, 1994.
- [17] S. Ekici, A.I. Doğan Ekici, G. Öztürk, F. Benli Aksungar, O. Sinanoğlu, G. Turan, N. Lüleci, "Comparison of melatonin and ozone in the prevention of reperfusion injury following unilateral testicular torsion in rats," *Urology*, vol. 80, pp. 899-906, 2012.
- [18] S. Umar, J. Zargan, K. Umar, S. Ahmad, C.K. Katiyar, H.A. Khan, "Modulation of the oxidative stress and inflammatory cytokine response by thymoquinone in the collagen induced arthritis in Wistar rats," *Chem. Biol. Interact.*, vol. 197, pp. 40-46, 2012.
- [19] R. El Mezayen, M. El Gazzar, M.R. Nicolls, J.C. Marecki, S.C. Dreskin, H. Nomiyama, "Effect of thymoquinone on cyclooxygenase expression and prostaglandin production in a mouse model of allergic airway inflammation," *Immunol. Lett.*, vol. 106, pp. 72-81, 2006.
- [20] F. Vaillancourt, P. Silva, Q. Shi, H. Fahmi, J.C. Fernandes, M. Benderdour, "Elucidation of molecular mechanisms underlying the

- protective effects of thymoquinone against rheumatoid arthritis," *J. Cell. Biochem.*, vol. 112, pp. 107-117, 2011.
- [21] I. Ullah, N. Ullah, M.I. Naseer, H.Y. Lee, M.O. Kim, "Neuroprotection with metformin and thymoquinone against ethanol-induced apoptotic neurodegeneration in prenatal rat cortical neurons," *BMC Neurosci.*, vol. 13, p. 11, 2012.
- [22] G.K. Helal, "Thymoquinone supplementation ameliorates acute endotoxemia-induced liver dysfunction in rats," *Pak. J. Pharm. Sci.*, vol. 23, pp. 131-137, 2010.