

# The Key Role of the Steroidal Hormones in the Pattern Distribution of the Epiphyseal Structure in Rabbit

Fatahian Dehkordi R.F., Parchami A.

**Abstract**—Steroidal hormones with the efficient changes on the epiphyseal growth plate may influence tissue structure properties. Presents paper to investigate the effects of gonadectomy in the pattern distribution of the epiphyseal structure. Fifteen adult female New Zealand white rabbits were separated into three groups. One group was intact and others groups were selected for surgical operation. From these two groups, one group carried out steroidal administration. The results obtained showed that there is no statistically difference in the mean diameter of the growth plate cells between all three groups. The maximum value of the cartilage cells were allocated to the gonadectomized group and the minimum number were observed in Hormonal induced group significantly. Growth plate height was significantly greater in gonadectomized group than in two other groups.

**Keywords**—Steroidal hormones, Ovariectomy, Rabbit, Epiphyseal structure

## I. INTRODUCTION

THERE is between the bone epiphyseal and metaphyseal an extremely established cartilage structure give a name to the "growth plate" that lie at the proximal or distal extremity of the long bones. In mammals longitudinal bones, under process namely endochondral ossification, are developed by growth plate in which immediately formed cartilage exchange by bone tissue fully. This progress method is regulated by environmental and nutritional conditions and factors of the hormonal and growth; in addition to, chondrocytes in the epiphyseal growth plate controls activity of bone formation from cartilage by endochondral ossification [4, 5, 11]. It detected androgenic hormones have crucial role during sexual maturity [2]. Some genetic disorders confirm important function of the estrogen, hereby cause estrogen resistance resulting from mutations changes in the receptor-alpha (ER $\alpha$ ) of estrogen. Therefore concluded that the estrogens physiological effects chiefly are intervened with two known estrogen receptors,  $\alpha$  and  $\beta$ , despite effect of estrogen is performed primarily via estrogen receptors  $\alpha$  [10].

In unusually well-developed puberty, untimely estrogen exposure, hastens skeletal sexual maturity, therefore making happen premature epiphyseal fusion and decreased final height.

Rahamat Allah Fatahian Dehkordi is with Department of Anatomical Sciences, Faculty of Veterinary Medicine, university of Shahrekord, 2-Kilometer Saman Road, Shahrekord, Iran. Phone: +98 (381)4424427; Fax: +98 (381)4424427; e-mail: fatahian\_1349@yahoo.com.

Ali Parchami is with Department of Anatomical Sciences, Faculty of Veterinary Medicine, university of Shahrekord, 2-Kilometer Saman Road, Shahrekord, Iran. phone: +98 (381)4424427; Fax: +98 (381)4424427; e-mail: parchami431rf@yahoo.com

In a contrary manner, absence of estrogen, as ingonadectomized, results in delayed fusion and tall stature [8, 9]. However, the effects of ovariectomy on the tissue morphometry of the growth plate of the rabbit have not yet been investigated. Thus, the aim of this study was designed to examine the morphometrical changes in the growth plate cartilage of gonadectomized rabbit.

## II. MATERIALS AND METHODS

In this investigation and trial with animal conditions, approval of protocol was obtained by Institutional Animal Care and Use Committee before research can start. Fifteen adult female New Zealand white rabbits (3.3 $\pm$ 0.2 kg body weight) were utilized in our examination. Animals were kept under standard conditions and had free access on commercial food pellets and tap water at all the entire period. They were randomly divided into three experiment groups of five each. Sham operations performed on the rabbits of the control group (Co). Two other groups with the surgical procedures were bilaterally ovariectomized (Ovz) beneath ketamine anesthesia (80 mg/kg). One month postovariectomy, animals were treated for an additional 4-week period at five day intervals by intramuscular injection of estradiol valerate (5mg), (Ovz-E). Two months was allowed to elapse after hormonal induced and ketamine utilized in anesthetic doses to sacrifice animals and fixed by intravascular perfusion via the left ventricle with 10% Merk buffered formalin. Tibias were exposed with gentle blunt dissection of fascia and muscle and then were removed, split additional accessory structures. The tibias were immediately immersed in %10 neutral buffered formalin and were then decalcified for light microscopy. The samples were processed, embedded in paraffin; tissue sections were cut at 5  $\mu$ m and stained with a sequence of haematoxylin and eosin.

Morphometric measurements were compared using SPSS software and data were expressed for groups with the 95% confidence interval and  $P < 0.05$  that were considered statistically significant.

## III. RESULTS

Table I reveals the effect of ovariectomy and the hormone-induced changes on the tissue parameters.

In the measured parameters were statistically detected significant differences between all three (Co, Ovz and Ovz-E) groups, except for diameter of the growth plate cells which there were not significant differences between total groups about this variable. The most mean growth plate heights were observed in the gonadectomized group and minimum mean were found in the control group.

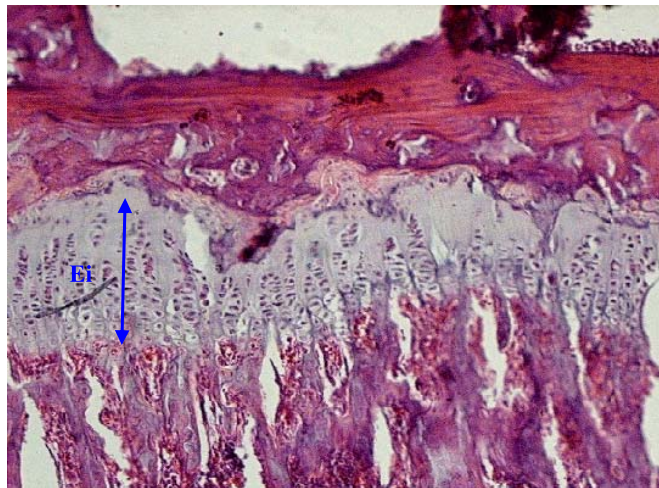


Fig. 1 Light microscopic structure of the epiphyseal growth plate in intact rabbits. Note to the position and height of cartilage tissue in the epiphysis, (Ei) (original magnification  $\times 400$ )

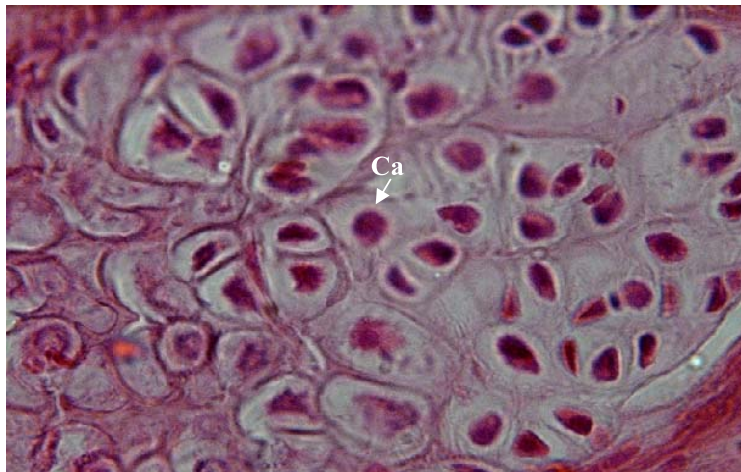


Fig. 2 Light microscopic structure of the epiphyseal growth plate in gonadectomized rabbits. Note to the increased Cartilage cells (Ca) number in the epiphysis, (original magnification  $\times 1000$ )

TABLE I  
THE MEAN HISTOMETRIC PARAMETERS OF EPIPHYSEAL GROWTH PLATE

<i>Groups Parameter</i>	<i>Hormonal induced</i>	<i>Gonadectomized</i>	<i>Control</i>
Growth plate height	12.71 $\pm$ 1.04	15.2 $\pm$ 1.12	12.5 $\pm$ 1.03
Cartilage cells number in per microscopic	45.74 $\pm$ 9.87	68.83 $\pm$ 10.19	44.23 $\pm$ 9.32
Growth plate cells diameter ( $\mu$ m)	1.15 $\pm$ 0.07	1.10 $\pm$ 0.04	1.14 $\pm$ 0.08

This data was similarly repeated for the number of the cartilage cells, as maximum mean for mentioned parameter was in control group and minimum mean was for the gonadectomized group. Inversely, the least mean diameter of growth plate cells were observed in the gonadectomized group than other groups. Mean measure of the growth plate varies in height depending on the different groups. The Mean height of growth plate was significantly higher in gonadectomized group than in the control group. In the estradiol-treated rabbits there was a significant decline in the total growth plate height than in gonadectomized group. There aren't any significant different in the mean diameter of the growth plate cells between each three groups. The figure 1 and 2 show tissue structural in epiphysis growth plate.

#### IV. DISCUSSION

In relation to animals of the surgical group and steroidal-induced group, growth plate underwent the hormonal changes in which morphometric properties of cartilage cells were measured by histological techniques. With ovariectomy, there was a progressive increase in growth plate height due to an increase in the structure properties of epiphyseal plate tissue. This oncoming enlargement of structure was accompanied by a gradual increase in the number of the cartilage cells in the growth plate. However increase of the growth plate height directly depend on the changes of the cartilage cells number in epiphysis. The observed structure variations in the ovariectomized-induced group are affected by the different concentrations of plasma steroidal hormones. With the finding of an estrogen-opposed man in which estrogen receptor- $\alpha$  (ER- $\alpha$ ) gene had a homozygous invalid mutation, the estrogen function in skeletal maturation and epiphyseal fusion was confirmed [10]. Estrogenic hormonal loss in the hypogonadism animals results in decrease maturation process and thus causing increase final thickness [9]. Therefore it seems that delays routine condition of epiphyseal fusion for osteogenesis status and result in increase thickness of the growth plate in ovariectomized group. Estrogen exposure in the premature hormonal treatments causing premature epiphyseal fusion and accelerates skeletal maturation; conversely, lack of estrogen, results in delayed fusion and tall stature [9]. But in condition of the ovariectomy animals that were treated by estradiol-induced, observed that tissue structure changes not only decreased than ovariectomized group but also reversible to the position in front of surgical-induced procedure. Estrogen has been found as an essential donor to the bone growth regulation and its development. The estrogen effects are intervened directly on the cells affecting proliferation of the chondrocytes, differentiation, and extracellular matrix synthesis, and also circuitously by other hormones and local agents secreted by cells in response to stimulation of estrogen [1, 7, 13].

It has been customarily agreed that effect of estrogens intercede through classic steroid-hormone receptor mechanisms. Following estrogen binding to its private receptor (either estrogen receptor-alpha [ER $\alpha$ ] or estrogen receptor-alpha [ER $\alpha$ ], [6, 8].

Therefore, estrogen signaling through ER- $\alpha$  is critical for regular skeletal maturation and epiphyseal fusion. These findings mention that the final height of children might be increased by therapy with aromatase inhibitors [15] or antiestrogens [3]. Effects of the estrogen in vitro studies on the bone and cartilage have been found to be different. Cultures chondrocytes cell that come from the growth plate cartilage, 17 $\beta$ -estradiol inhibits cell proliferation and stimulates protein production measure by RNA synthesis, which is highly contingent upon the concentration and model being tested [7, 13].

#### ACKNOWLEDGMENT

This work was financially supported by the University of Shahrekord, Iran.

#### REFERENCES

- [1] O. T. Gray, "Estrogens and the skeleton: Cellular and molecular mechanisms," *J. Steroid. Biochem.*, vol. 34, p. 285, 1989.
- [2] M. M. Grumbach, and R. J. Auchus, "Estrogen: consequences and implications of human mutations in synthesis and action," *J. Clin. Endocrinol. Metab.*, vol. 84, pp. 4677-4694, 1999.
- [3] D. F. Gunther, A. S. Calikoglu, and L. E. Underwood, "The effects of the estrogen receptor blocker, Faslodex (ICI 182,780), on estrogen-accelerated bone maturation in mice," *Pediatr. Res.*, vol. 46, pp. 269-273, 1999.
- [4] T. M. Hering, "Regulation of chondrocyte gene expression," *Front. Biosci.*, vol. 4, pp. 743-761, 1999.
- [5] H. M. Kronenberg, "Development regulation of the growth plate," *Nature*, vol. 423, pp. 332-336, 2003.
- [6] G. Kuiper, E. Enmark, and M. Peltö-Huikko, "Cloning of a novel estrogen receptor expressed in rat prostate and ovary," *Proc. Natl. Acad. Sci.*, vol. 93, p. 5925, 1996.
- [7] E. Nasatzky, Z. Schwartz, and B. D. Boyan, "Sex-dependent effects of 17-beta-estradiol on chondrocyte differentiation in culture," *J. Cell. Physiol.*, vol. 154, p. 359, 1994.
- [8] L. Nilsson, A. Boman, and L. Sävendahl, "Demonstration of estrogen receptor-immunoreactivity in human growth plate cartilage," *J. Clin. Endocrinol. Metab.*, vol. 84, p. 370, 1999.
- [9] O. Nilsson, R. Marino, F. De Luca, M. Phillip, and J. Baron, "Endocrine Regulation of the Growth Plate," *Horm. Res.*, vol. 64, pp. 157-165, 2005.
- [10] E. P. Smith, J. Boyd, G. R. Frank, H. Takahashi, R. M. Cohen, B. Specker, T. C. Williams, D. B. Lubahn, and K. S. Korach, "Estrogen resistance caused by a mutation in the estrogen-receptor gene in a man," *N. Engl. J. Med.*, vol. 331, pp. 1056-1061, 1994.
- [11] D. A. Stevens, and G. R. Williams, "Hormone regulation of chondrocyte differentiation and endochondral bone formation," *Mol. Cell. Endocrinol.*, vol. 151, pp. 195-204, 1999.
- [12] R. M. Talwar, B. S. Wong, K. Svoboda, and R. P. Harper, "Effects of estrogen on chondrocyte proliferation and collagen synthesis in skeletally mature articular cartilage," *J. Oral. Maxillofac. Surg.*, vol. 64(4), pp. 600-9, 2006.
- [13] M. Takahashi, and T. Noumura, "Sexually dimorphic and laterally asymmetric development of the embryonic duck syrinx: Effects of estrogen on in vitro cell proliferation and chondrogenesis," *Dev. Biol.*, vol. 121, p. 417, 1987.
- [14] M. Weise, S. De-Levi, K. M. Barnes, R. I. Gafni, V. Abad and J. Baron, "Effects of estrogen on growth plate senescence and epiphyseal fusion," *PNAS.*, vol. 98(12), pp. 6871-6876, 2001.
- [15] S. Wickman, I. Sipila, C. Ankarberg-Lindgren, E. Norjavaara, and L. Dunkel "A specific aromatase inhibitor and potential increase in adult height in boys with delayed puberty: a randomized controlled trial," *Lancet*, vol. 357, pp. 1743-1748, 2001.