

Histological Study of Postmortem Juvenile Green Sea Turtle (*Chelonia mydas*) from Royal Thai Navy Sea Turtle Nursery, Phang-nga, Thailand

Saowaluk Sikiwat, Mayuree Pumipaiboon, Sutee Kaewsangiem, and Mayuva Areekijserree

Abstract—The problem on the conservation programme of the Royal Thai Navy Sea Turtle Nursery, Phang-nga Province, Thailand is high mortality rate of juvenile green sea turtle (*Chelonia mydas*) on nursing period. So, during May to October 2012, postmortem examinations of juvenile green sea turtle were performed to determine the causes of dead. Fresh tissues of postmortem of 15 juvenile green sea turtles (1-3 months old) were investigated using paraffin section technique. The results showed normal ultrastructure of all tissue organs. These instances reviewed the health and stability of the environments in which juvenile green sea turtles live and concern for the survival rate. The present article also provides guidance for a review of the biology, guidelines for appropriate postmortem tissue, normal histology and sampling collection and procedures. The data also provides information for conservation of this endangered species in term of acknowledging and encouraging people to protect the animals and their habitats in nature.

Keywords—Green sea turtles (*Chelonia mydas*), histology, juvenile sea turtles.

I. INTRODUCTION

GREEN sea turtles (*Chelonia mydas*) have been afforded legislative protection under of treaties on appendix I by the International Union for Conservation of Nature (IUCN) and the Convention on International Trade in Endangered Species of Wild Fauna and Flora (CITES) [1]-[4]. In Thailand, green sea turtles is listed as endangered species and supervised under the programmed in nature of The Royal Thai Phang-nga Naval Base, Phang-nga Province. The navy was conducting a research on the biology, spawning, migration and nourishment [2]. However, they are still in danger because of several human activities such as turtles and their eggs are hunted for food. Many turtles die cause of caught in fishing nets and live in unsuitable environment [2], [5]-[8]. Presently, knowledge about basic biology on histology of captive or farmed juvenile sea turtles is still limited, leading to sea turtle husbandry in

many facilities have been through trial and error [2]. Therefore, information of the histology of juvenile green sea turtles is useful for effective management of the animal captivity. This finding of histology on ultrastructure of gastrointestinal tract of 1-3 months old juvenile green sea turtles from nursery ponds is a review basic knowledge of histological biology, and sampling collection in the juvenile green sea turtles. It is also useful for conservation of this endangered and would be used as important data for further study of diseases in all sea turtles in the conservation center.

II. MATERIAL AND METHOD

Green sea turtles were collected after death immediately and the carcasses were measured curved length and width of the carapace and plastron. Then, tissues of gastrointestinal tract (esophagus, crop, stomach, duodenum, ileum, and colon) were dissected and washed with 0.9% saline before fixation in Bouin solution for 24h. The samples were rinsed with 0.1M phosphate at room temperature for 1-2h. After fixation, all samples were washed 3 times in 0.1M phosphate buffer pH 7.2 followed by dehydration through an acetone series, and embedded in paraffin. The microtome material was cut into 7µm thickness, and stained with Haematoxylin and Eosin before examination under a light microscope to identify histological morphology of gastrointestinal tract.

III. RESULTS

Gross external and internal examinations of juvenile green sea turtle carcasses revealed normal at carapaces, flippers, tails and anuses, oral cavities, and gastrointestinal tract (Fig. 1). The primary lesion was not found. The weight, carapace, and plastron were measured. The weight of 1-3 months old juvenile green sea turtle was ranging from 42 ± 11.47 - 49 ± 5.48 g. The average of carapace length and width were ranging from 6.82 ± 0.97 - 7.54 ± 0.15 cm, and 6.5 ± 0.92 - 6.94 ± 0.38 cm, respectively. The average of plastron length and width were ranging from 5.88 ± 0.95 - 6.42 ± 0.18 cm, and 5.06 ± 0.09 - 5.66 ± 0.11 cm, respectively (Table I).

Fresh postmortem tissues of 15 juvenile green sea turtles from 1-3 months old were investigated using paraffin section technique. The results showed normal ultrastructure of all tissue organs of gastrointestinal tract. The esophagus of juvenile green sea turtle shows lumen (L) which lining by a thick stratified squamous epithelium (Sse) to protect the lumen and underlie with vascular and relatively loose of submucosa

M. Areekijserree is with the Department of Biology, Faculty of Science, Silpakorn University, Sanamchan Palace, Muang, NakhonPathom, 73000, Thailand (corresponding author: phone: +66 34 245327; fax +66 34 245325; e-mail: Maijackee@yahoo.com)

M. Pumipaiboon is with the Department of Finance and Accounting Section, Faculty of Business Administration, Ramkhamhaeng University, Bangkok, 10240, Thailand.

S. Sikiwat is with the Department of Biology, Faculty of Science, Silpakorn University, Sanamchan Palace, Muang, NakhonPathom, 73000, Thailand.

S. Kaewsangiem is with The Petroleum and Petrochemical College, Chulalongkorn University, Bangkok, 10330, Thailand.

(SM) to allow for pass food and bolus, and the underlying inner circular layer (CM) of smooth muscle (Fig. 2 (A)). Crop and stomach are food ingestion part by chemical and mechanical process to form chyme. Micrograph of crop illustrated the mucosa (M) with mucous-secretory cells (Msc) while the micrograph of stomach showed lumen, mucosa, submucosa, inner circular muscular layer (CM), and outer longitudinal muscular layer (LM) (Fig. 2 (B), (C)). The small intestine of juvenile green sea turtle compose of duodenum and ileum. It is a site for major part of absorption of digestion food from stomach. Duodenum micrograph showed submucosa and inner circular layer. While, the ilium demonstrates mucosa with folding finger-like projection to

increase surface area called intestinal villi (V). The vascular submucosa and inner circular muscular layer are shown and connect to the mucosa layer (Fig. 2 (D), (E)). The micrograph of colon illustrated the thick muscular wall: the inner circular and outer longitudinal layers of smooth muscles which powerful for peristaltic process. The submucosa connects to the inner circular layer. Inside the lumen is the mucosa which consists of absorptive cells and mucus-secretory goblet cells. Their functions are water absorption and lubricated faeces (Fig. 2 (F)). These instances reviewed the health and stability of the environments in which juvenile sea turtles have capable to live and concern for the survival rate.

TABLE I
THE WEIGHT, CARAPACE, PLASTRON LENGTH AND WIDTH OF 1-3 MONTHS OLD JUVENILE GREEN SEA TURTLE

Age (month)	N	Weight (g)	Carapace		Plastron	
			Length (cm)	Width (cm)	Length (cm)	Width (cm)
1	5	42.00 ± 11.47	6.82 ± 0.97	6.50 ± 0.92	5.88 ± 0.95	5.06 ± 0.09
2	5	46.00 ± 9.62	7.26 ± 0.43	6.74 ± 0.53	5.72 ± 0.22	5.20 ± 0.21
3	5	49.00 ± 5.48	7.54 ± 0.15	6.94 ± 0.38	6.42 ± 0.18	5.66 ± 0.11

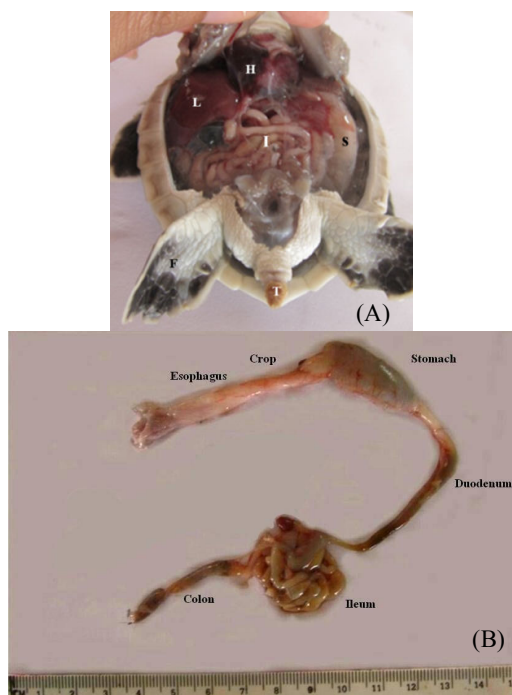


Fig. 1 (A) Internal and external organs of 1-3 months old juvenile green sea turtle; heart (H), liver (L), stomach (S), intestine (I), flippers (F) and tail (T), (B) Part of the gastrointestinal tract (esophagus, crop, stomach, duodenum, jejunum, ileum, and colon)

IV. DISCUSSIONS AND CONCLUSION

Chuen-Im et al. [2] studied, surveyed diseases, and characterize microbes associated with the diseases in 2-3 months old juvenile green turtles and hawksbill turtles (on 2005-2007). They found bacteria which is a major cause of diseases and subsequently death of juvenile sea turtles at the Sea Turtle Conservation Centre of Thailand. Two diseases were found in the turtles in 2005. They are primary lesion of ulcerative stomatitis is (65%) and necrotizing hepatitis (35%). In year 2006, they reported the complex diseases of traumatic ulcerative dermatitis, gastric asenteritis, impacted intestine, and ulcerative shell. In 2007, they showed the data of the primary disease from ulcerative stomatitis (32.14%) to necrotizing hepatitis (46.43%). In addition, Oroset et al. [8] listed the pathological findings and causes of mortality among the sea turtles which exposure to persistent environmental contaminants, pesticides and heavy metals in the Canary Islands. Santoro et al. [9] also demonstrated wide spectrum of aerobic bacterial flora of nesting green turtles at Tortuguero National Park. Unlike this report, using paraffin section technique showed no evidence of disease was observed in juvenile sea green turtles. It might be possible that the cause of death in our study was mainly from other factors such as the pond's environment. It will be proof in future studies. However, the present work also provides guidance for a review of the basic histological biology, sampling collection and procedures to determine from paraffin section technique. The basic information is essential for the conservation of protected animals such as prevention of potential disease and rehabilitation of slicked animals in the future.

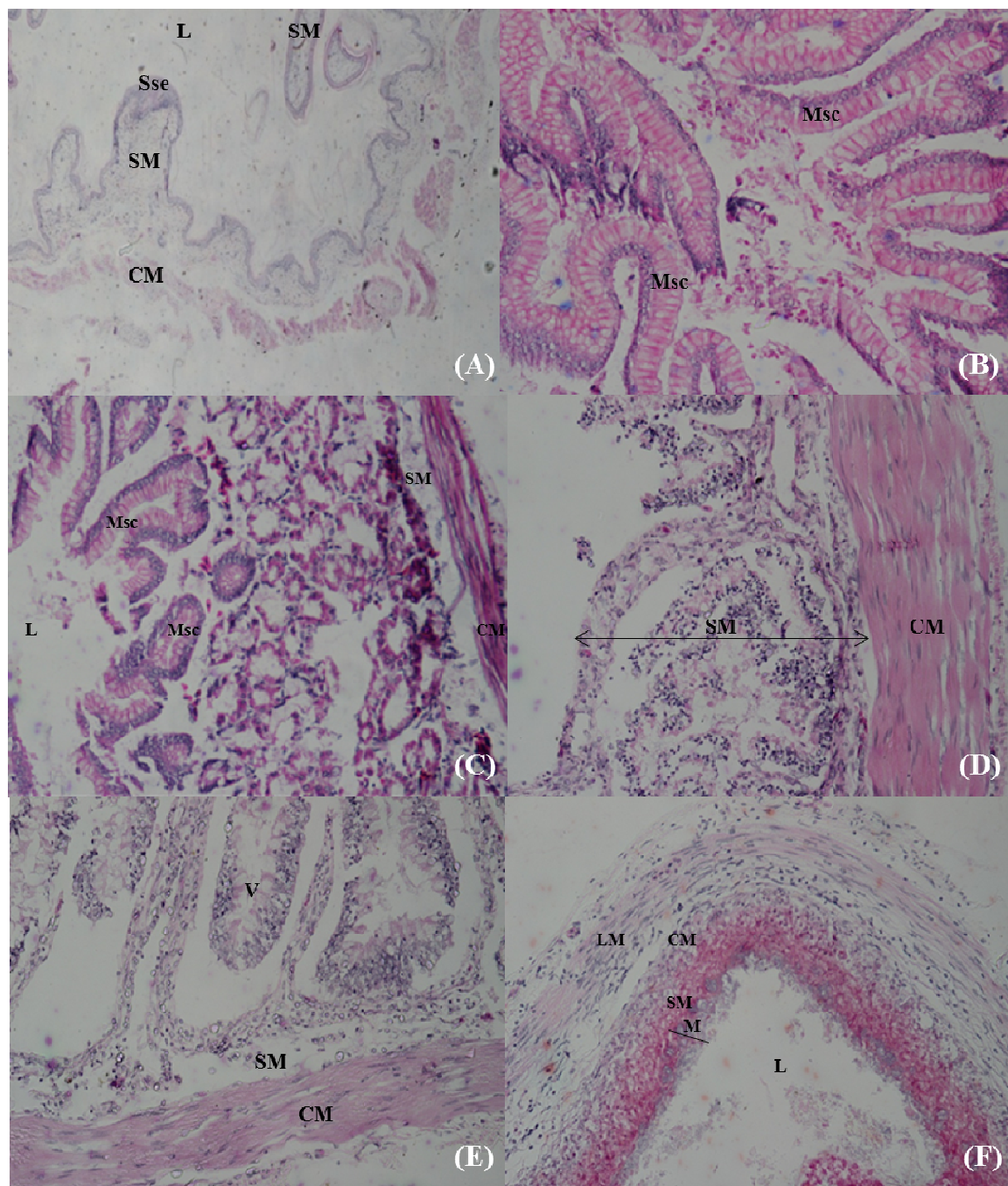


Fig. 2 Microscopes of gastrointestinal tract of 1-3 months old juvenile green sea turtles showed normal histology of (A) esophagus, (B) crop, (C) stomach, (D) duodenum, (E) ileum, and (F) colon. (H & E, x40, lumen: L, stratified squamous epithelium: Sse, mucosa: M, submucosa: SM, inner circular smooth muscle layer: CM, longitudinal smooth muscle layer: LM, intestinal villi: V, mucous-secreting cells: Msc)

ACKNOWLEDGMENT

This research was funded by grants from Silpakorn University Research & Development Institute (SURDI), and Faculty of Science, Silpakorn University, Thailand. We are grateful to the Royal Thai Navy Sea Turtle Nursery, Phang-nga, Thailand and the Phuket Marine Biological Centers,

Phuket, Thailand for their kind support in providing the post mortem juvenile green sea turtles.

REFERENCES

- [1] K.L. Eckert, K.A. Bjorndal, F. Alberto Abreu-Grobois, and M. Donnelly (Eds). *Research and Management Techniques for the Conservation of Sea Turtle*, IUCN/SSC Marine Turtle Specialist Group Publication no. 4,

Consolidated Graphic Communications, Blanchard, Pennsylvania, 232 pages, 1999.

- [2] T. Chuen-Im, M. Areekijserree, S. Chongthammakun, and S.V. Graham, "Aerobic bacterial infections in captive juvenile green (*Cheloniamydas*) and hawksbill (*Eretmochelysimbricata*) sea turtles from Thailand", *Chelonian Conservation and Biology*, vol. 9, no 1, pp. 135-142. DOI: 10.2744/CCB-0808.1., 2010.
- [3] M. Areekijserree, S. Nuamsukon, T. Chuen-Im, and N. Narkkong, "Microanalysis on ultrastructure and elemental composition of green turtles (*Cheloniamydas*) eggshells", *Journal of the Microscopy Society of Thailand*, vol.24, no 2, pp. 78-82, 2010.
- [4] S.Nuamsukon, T. Chuen-Im, S. Rattanayuvakorn, K. Panishkan, N.Narkkong, and M. Areekijserree, "Thai marine turtle eggshell: Morphology, ultrastructure and composition", *Journal of Microscopy Society of Thailand*, vol. 23, no 1, pp. 52-56, 2009.
- [5] B.M. Higgins, *Sea turtle husbandry*. In: P.L. Lutz, J.A. Musick, and J. Wyneken, (Eds.). "The Biology of Sea Turtles Volume II". Florida: CRC Press, Boca Raton, pp. 411-440. 2003.
- [6] S. N. Al-Bahry, I.Y. Mahmoud, I.S. Al-Amri, T.A. Ba-Omar, K.O. Melgheit, and A.Y. Al-Kindi, " Ultrastructural features and elemental distribution in eggshell during pre and post hatching periods in the green turtle, *Cheloniamydas* at Ras Al-Hadd, Oman. *Tissue and Cell*, vol. 41, pp. 214-221, 2009.
- [7] J. C. W. Lam, S. Tanab, S.K.F. Chan, M.H.W. Lam, M. Martin, and P.K.S. Lam, "Levels of trace elements in green turtle eggs collected from Hong Kong: Evidence of risks due to selenium and nickel." *Environ. Pollut.* vol. 144, pp. 790-801, 2006.
- [8] J. Oros, A. Torrent, P. Calabuiq, and S. Deniz, "Diseases and causes of mortality among sea turtles stranded in the Canary Islands, Spain (1998-2001)". *Diseases Aquatic Organisms* vol. 25, pp. 13-24. 2005.
- [9] M. Santoro, G. Hernandez, M. Caballero, and F. Garica, "Aerobic bacterial flora of nesting green turtles (*Cheloniamydas*) from Tortuguero National Park, Costa Rica". *Journal of Zoo Wildlife Medicine*, vol. 37, pp. 549-552. 2006.