

Aqueous Extract of *Flacourtia indica* Prevents Carbon Tetrachloride Induced Hepatotoxicity in Rat

Gnanaprakash K^{*1}, Madhusudhana Chetty C¹, Ramkanth S¹, Alagusundaram M¹,
Tiruvengadarajan VS², Angala Parameswari S², Mohamed Saleem TS³

Abstract—Carbon tetrachloride (CCl₄) is a well-known hepatotoxin and exposure to this chemical is known to induce oxidative stress and causes liver injury by the formation of free radicals. *Flacourtia indica* commonly known as 'Baichi' has been reported as an effective remedy for the treatment of a variety of diseases. The objective of this study was to investigate the hepatoprotective activity of aqueous extract of leaves of *Flacourtia indica* against CCl₄ induced hepatotoxicity. Animals were pretreated with the aqueous extract of *Flacourtia indica* (250 & 500 mg/kg body weight) for one week and then challenged with CCl₄ (1.5 ml/kg bw) in olive oil (1:1, v/v) on 7th day. Serum marker enzymes (ALP, AST, ALT, Total Protein & Total Bilirubin) and TBARS level (Marker for oxidative stress) were estimated in all the study groups. Alteration in the levels of biochemical markers of hepatic damage like AST, ALT, ALP, Total Protein, Total Bilirubin and lipid peroxides (TBARS) were tested in both CCl₄ treated and extract treated groups. CCl₄ has enhanced the AST, ALT, ALP and the Lipid peroxides (TBARS) in liver. Treatment of aqueous extract of *Flacourtia indica* leaves (250 & 500 mg/kg) exhibited a significant protective effect by altering the serum levels of AST, ALT, ALP, Total Protein, Total Bilirubin and liver TBARS. These biochemical observations were supported by histopathological study of liver sections. From this preliminary study it has been concluded that the aqueous extract of the leaves of *Flacourtia indica* protects liver against oxidative damages and could be used as an effective protector against CCl₄ induced hepatic damage. Our findings suggested that *Flacourtia indica* possessed good hepatoprotective activity.

Keywords—Carbon Tetrachloride, *Flacourtia indica*, Hepatoprotective activity, Oxidative stress

I. INTRODUCTION

LIVER – a major metabolic organ affected by various chemicals and toxins daily and identification of a successful hepatoprotective agent will provide a useful tool for the treatment of hepatic diseases. In absence of reliable liver-protective drugs in modern medicine, a large number of medicinal preparations are recommended for the treatment of

liver disorders and quite often claimed to offer significant relief [1]. Exposure to various organic compounds including a number of environmental pollutants and drugs can cause cellular damages through metabolic activation of those compounds to highly reactive substances such as reactive oxygen species (ROS). Carbon tetrachloride (CCl₄) is a well-known hepatotoxin and exposure to this chemical is known to induce oxidative stress and causes liver injury by the formation of free radicals [2].

Flacourtia indica (Burm. f.) Merr. Synonymous to *Flacourtia ramontchi* L'Herit. (Family-Flacourtiaceae), commonly known as 'Baichi' or 'Katai', is an indigenous medicinal plant widely distributed in Bangladesh and India [3]. This plant has been reported as an effective remedy for the treatment of a variety of diseases. Fruits are used as appetizing and digestive, diuretic, in jaundice and enlarged spleen. Barks are used for the treatment of intermittent fever. Roots are used in nephritic colic and gum is used in cholera [3]-[4]. Previous phytochemical investigation on this plant resulted in the isolation of β -sitosterol (a well-known phytosterol), β -sitosterol- β -D-glucopyranoside, ramontoside, butyrolactone lignan disaccharide [5], and flacourtin [6]. Recent report shows the presence of coumarin such as scoparone and aesculetin [7]. In the view of scientific report, the leaves of *Flacourtia indica* was evaluated against CCl₄ induced hepatic damage in rats with the aim of developing a natural hepatoprotective drug.

II. MATERIALS & METHODS

A. Plant Material

Flacourtia indica leaves were collected from Kanyakumari District, Tamilnadu, India and authenticated by Dr. Soma Sundaram, Siddha Medical College, Tirunelveli, Tamilnadu, India. The material was air dried under shade, powdered mechanically and stored in airtight containers. About 1 kg of the powdered material was boiled with 5 L of distilled water for 30 min and filtered to obtain the aqueous extract. The extract was concentrated under reduced pressure and lyophilized. The freeze-dried material was weighed, dissolved in the water and used for this study.

*Corresponding author email: pharmagp@gmail.com

¹Department of Pharmaceutics, Annamacharya College of Pharmacy, New Boyanapalli, Rajampet-516 126, Kadapa Dt, Andhrapradesh, India

²Department of Pharmaceutical analysis, Annamacharya College of Pharmacy, New Boyanapalli, Rajampet-516 126, Kadapa Dt, Andhrapradesh, India.

³Department of Pharmacology, Annamacharya College of Pharmacy, New Boyanapalli, Rajampet-516 126, Kadapa Dt, Andhrapradesh, India

B. Animals

Male Wistar albino rats, weighing about 150 – 200 g were obtained from institute animal center and used in the experiments. The protocol was approved by the Institute's Animal Ethical Committee. Animals were kept in animal house at an ambient temperature of 25°C and 45 – 55% relative humidity, with 12 h each of dark and light cycles. Animals were fed pellet diet and water *ad-libitum*. CPCSEA guidelines for laboratory animal facility (IJP 2003; 35: 257-274) were followed.

C. Phytochemical screening

The aqueous extract obtained was subjected to preliminary phytochemical screening, to identify the chemical constituents. The methods of analysis employed were those described by [8]-[9].

D. CCl₄ induced hepatotoxicity in rats

Animals were divided into five groups of six rats each. Group I and II served as normal and toxic control, and received only the vehicle (5% gum acacia; 1 ml/kg; p.o). Group III animals were treated with standard silymarin at an oral dose of 100 mg/kg and group IV and V received the aqueous extract of *Flacourtia indica* (AEFI) at an oral dose of 250 and 500 mg/kg respectively, as a fine suspension of 5% aqueous gum acacia. The treatment was continued for 7 days, once daily. On the day of 7 for groups II-V, 30 min post-dose of extract administration animals received CCl₄ at the dose of 1.5 ml/kg (1:1 v/v of CCl₄ in olive oil) orally [10]-[11].

E. Biochemical estimation

The animals were sacrificed 36 h after administration of acute dose of CCl₄. The blood was collected by retro orbital artery bleeding. Blood samples were centrifuged for 10 minutes at 3000 rpm to separate the serum. Alkaline Phosphatase (ALP), Alanine Transaminase (ALT), Aspartate Transaminase (AST), Total Protein (TP) and Total Bilirubin (TB) levels were estimated from the serum by using standard kits [12]. Liver was excised immediately, quickly cooled and perfused with cold normal saline and the liver tissue was used for estimation of Thiobarbituric acid reactive substance (TBARS) [13], an index of oxidative stress and a section of liver was processed for histological studies.

F. Histopathological studies

The livers were excised quickly and fixed in 10% formalin and stained with haematoxylin and eosin and then observed under microscope for degeneration, fatty changes, necrotic changes and evidence of hepatotoxicity if any.

G. Statistics

All values were expressed as Mean \pm SE. (n = 6 in each groups). One way ANOVA was applied to test for significance of biochemical data of the different groups. Significance is set at $p < 0.05$.

III. RESULTS

A. Phytochemical analysis

The freshly prepared extracts were subjected to preliminary phytochemical screening test for various constituents. This revealed the presence of alkaloids, tannins, saponins, flavonoids, glycosides, terpenoids and steroids.

B. Survival and Mortality

No mortality occurred in any of the treatment groups.

C. Biochemical parameters (Graph 1-6)

a. Control Group (G1)

The basal levels of liver enzymes (ALP, AST, ALT and TB) in control were 77.93 ± 2.39 IU/dl, 73.99 ± 5.13 IU/dl, 50.63 ± 3.1 IU/dl and 0.45 ± 0.11 mg/dl respectively. TP and TBARS levels were 6.55 ± 0.01 mg/dl and 210.47 ± 0.01 nmol/g wet wt respectively.

b. Toxic Control (G2)

There was significant increase in TB (1.13 ± 0.62 mg/dl), ALP (104.59 ± 2.93 IU/dl), AST (98.99 ± 4.86 IU/dl), ALT (88.68 ± 3.8 IU/dl) and TBARS (426.43 ± 1.99 nmol/g wet wt) accompanied by significant decrease in levels of TP (4.35 ± 0.04 mg/dl) as compared to the control.

c. Standard Group (G3)

There was significant decrease in TB (0.56 ± 0.15 mg/dl), accompanied by significant increase in level of TP (7.1 ± 0.11 mg/dl) and also significant decrease in ALP (75.26 ± 1.9 IU/dl), AST (71.74 ± 2.92 IU/dl), ALT (44.78 ± 2.92 IU/dl) and TBARS (314.24 ± 1.75 nmol/g wet wt) as compared to the toxic control.

d. AEFI (250 mg/kg) Groups (G4)

There was significant decrease in TB (0.71 ± 0.18 mg/dl), accompanied by significant increase in level of TP (6.8 ± 0.07 mg/dl) and also significant decrease in ALP (79.24 ± 1.42 IU/dl), AST (75.84 ± 3.12 IU/dl), ALT (45.98 ± 1.85 IU/dl) and TBARS (317.12 ± 3.67 nmol/g wet wt) as compared to the toxic control.

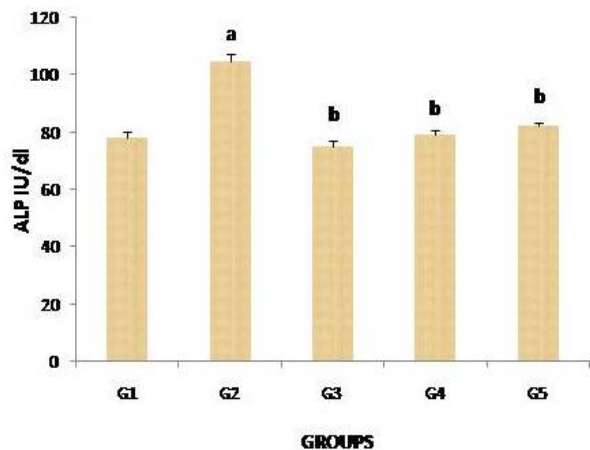
e. AEFI (500 mg/kg) Groups (G5)

There was significant decrease in TB (0.82 ± 0.03 mg/dl), accompanied by significant increase in level of TP (7.85 ± 0.01 mg/dl) and also significant decrease in ALP (82.16 ± 1.23 IU/dl), AST (68.26 ± 1.82 IU/dl), ALT (40.64 ± 3.48 IU/dl) and TBARS (288.63 ± 1.04 nmol/g wet wt) as compared to the toxic control.

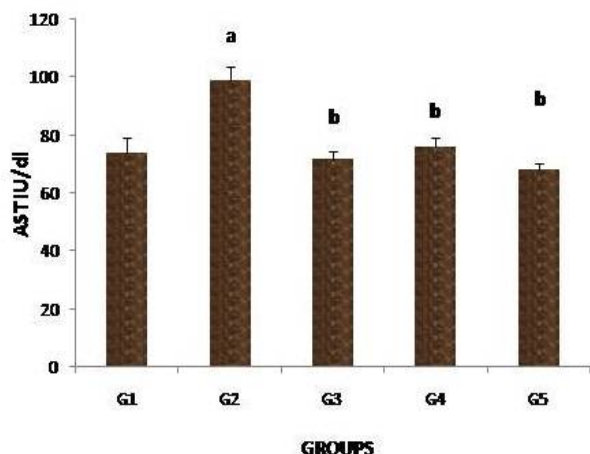
D. Histopathological studies

Histopathological examination of liver sections of control group showed normal cellular architecture with distinct hepatic cells, sinusoidal spaces and central vein (Fig.1). Disarrangement of normal hepatic cells with necrosis, vacuolization of cytoplasm, portal tiaditis and feathery degeneration were observed in CCl₄ treated animals (Fig. 2). The liver sections of the rats treated with AEFI (250 & 500 mg/kg) and silymarin followed by CCl₄ showed a sign of protection as it was evident by the absence of necrosis,

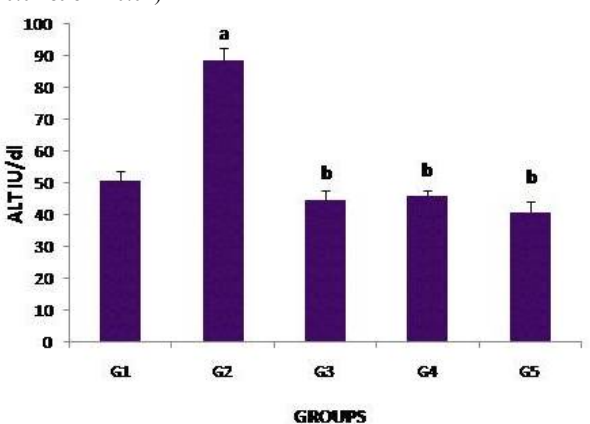
minimal of inflammation with moderate portal triaditis and vacuoles (Fig. 3, 4 and 5).



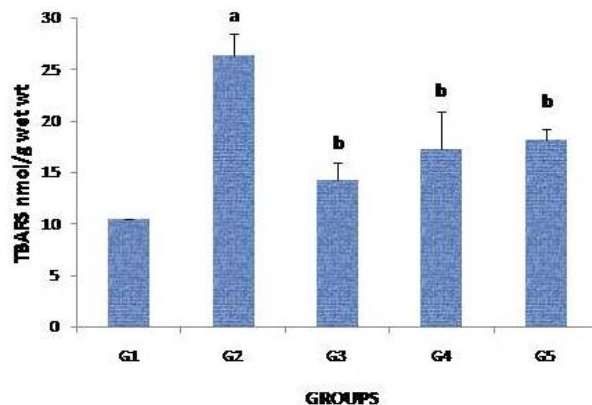
Graph. 1 Effect of aqueous extract of *Flacourtia indica* on ALP activity in rat serum. Each coloumn represents Mean±SEM, n=6 (a-P<0.01 & b-P<0.01)



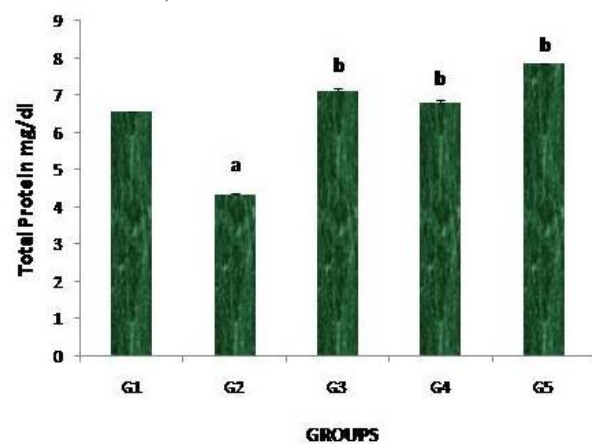
Graph. 2 Effect of aqueous extract of *Flacourtia indica* on AST activity in rat serum. Each coloumn represents Mean±SEM, n=6 (a-P<0.01 & b-P<0.01)



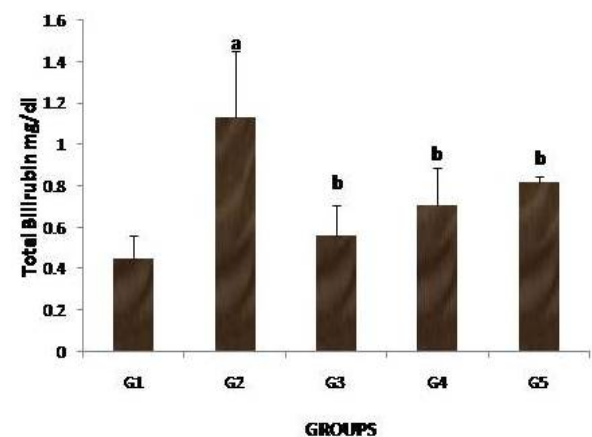
Graph. 3 Effect of aqueous extract of *Flacourtia indica* on ALT activity in rat serum. Each coloumn represents Mean±SEM, n=6 (a-P<0.01 & b-P<0.01)



Graph. 4 Effect of aqueous extract of *Flacourtia indica* on TBARS activity in rat serum. Each coloumn represents Mean±SEM, n=6 (a-P<0.01 & b-P<0.01)



Graph. 5 Effect of aqueous extract of *Flacourtia indica* on Total Protein activity in rat serum. Each coloumn represents Mean±SEM, n=6 (a-P<0.01 & b-P<0.01)



Graph. 6 Effect of aqueous extract of *Flacourtia indica* on Total Bilirubin activity in rat serum. Each coloumn represents Mean±SEM, n=6 (a-P<0.01 & b-P<0.01)

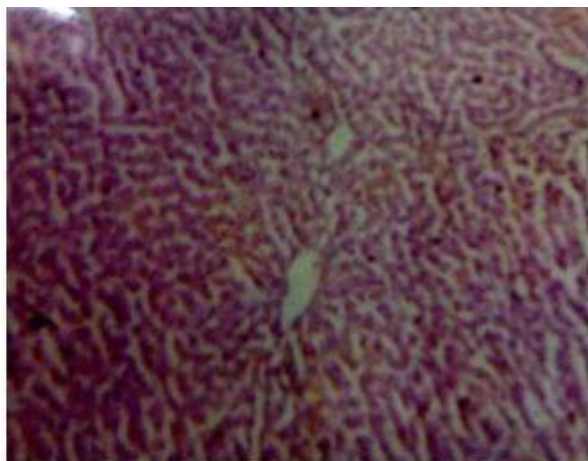


Fig. 1 Microphotograph of normal rat liver section

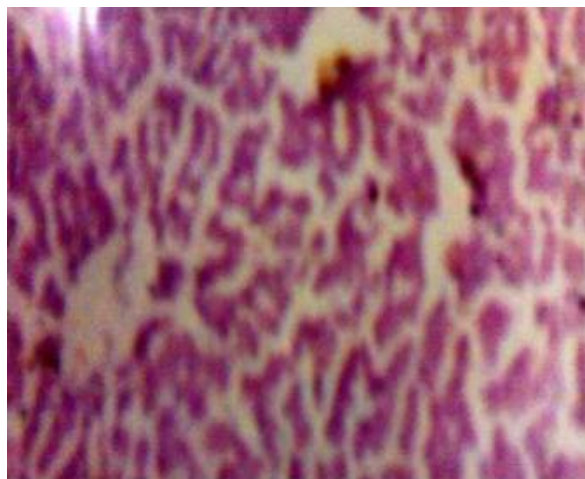


Fig. 4 Microphotograph of AEFI (250 mg/kg) treated rat liver section

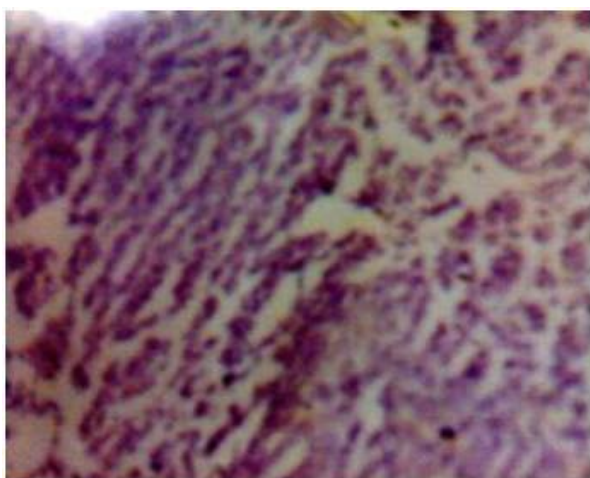


Fig. 2 Microphotograph of CCL₄ treated rat liver section

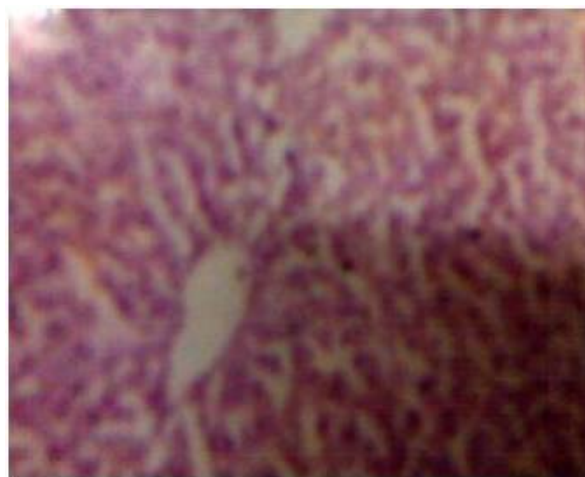


Fig. 5 Microphotograph of AEFI (500 mg/kg) treated rat liver section

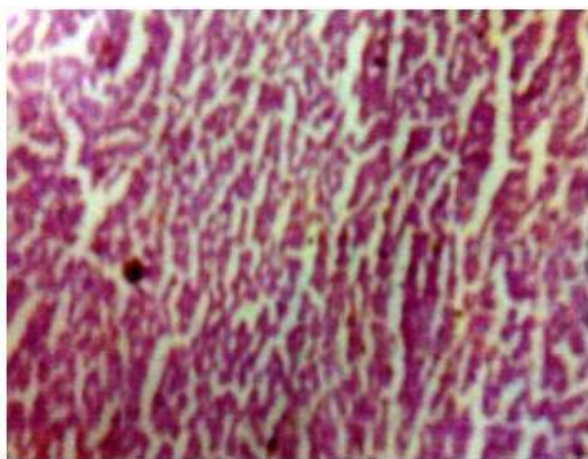


Fig. 3 Microphotograph of silymarin treated rat liver section

IV. DISCUSSION

A number of chemicals including various environmental toxicants and clinically useful drugs can cause severe cellular damages in different organs of our body through the metabolic activation to highly reactive substances such as free radicals. CCl₄ is one of such extensively studied environmental toxicant [2]. Up to the present time, the etiology and treatment of most liver diseases are not known. The liver is the commonest site affected during the toxic manifestation of many drugs. Toxicity in liver due to CCl₄ and other chemicals is attributed to the toxic metabolites formed, responsible for the initiation of CCl₄ dependent lipid peroxidation, the nature of which is not yet unambiguously determined. The most likely candidate is the trichloromethyl radical [1]. In the liver, CCl₄ is metabolized by the cytochrome P450-dependent monooxygenase systems followed by its conversion to more chemically active form, trichloromethyl radical (CCl₃). The

enzymes involved in this process are located in the endoplasmic reticulum of the liver and their activities are dependent on many environmental factors. Some herbal extracts are known to prevent the oxidative damages in different organs by altering the levels of cytochrome P-450 through their antioxidant properties [2].

Present study was conducted to evaluate the protective effect of the AEFI against CCl₄ induced hepatic damage in rat. Results suggest that the extract possesses protective action against hepatic dysfunctions induced by the potent toxin CCl₄. Both biochemical and histopathological data showed that there was no difference in extract treatment when compared with standard drug silymarin. Aerial parts of this plant also showed the significant protective effect in paracetamol induced hepatic damage [7]. Extensive evidence demonstrated that .CCl₃ and .Cl are formed as a result of the metabolic activation of CCl₄, which in turn, initiate lipid peroxidation process. A known potent antioxidant, vitamin E, could protect CCl₄ induced liver injury indicating that oxidative stress is responsible for CCl₄ induced hepatic disorder in this particular model [14]-[15]. From our study it was observed the significant increased level of TBARS in CCl₄ treated group indicating that the development of oxidative stress in this model. AEFI and silymarin treated groups significantly reduced the TBARS level and could protect organ against CCl₄ induced hepatic damage. Our results suggest that the aqueous extract of the leaves of *Flacourtia indica* possesses potent hepatoprotective activity and protects liver against CCl₄ induced oxidative stress probably via the alteration of cytochrome P-450.

V.CONCLUSION

From this preliminary study it has been concluded that the aqueous extract of the leaves of *Flacourtia indica* protects liver against oxidative damages and could be used as an effective protector against CCl₄ induced hepatic damage. Further works are needed to identify the active principle(s) present in the plant and elucidate its possible mode of action and that is in progress.

ABBREVIATION

CCl₄: Carbon Tetrachloride; ALT: Alanine transaminase; AST: Aspartate transaminase; ALP: Alkaline phosphatase; TBARS: Thiobarbituric acid reactive substances; AEFI: Aqueous extract of *Flacourtia indica*; TB: Total Bilirubin; TP: Total Protein.

REFERENCES

- [1] K.S.G. Arulkumar, A. Rajasekaran, R. Ramasamy, M. Jegadeesan, S. Kavimani, and A. Somasundaram, "Cassia roxburghii seeds protect Liver against Toxic effects of Ethanol and Carbontetrachloride in rats," Int J PharmTech Res., 2007, Vol. 1(2), pp. 273-246.
- [2] P.C. Sil, P. Manna, and M. Sinha, "Aqueous extract of Terminalia arjuna prevents carbon tetrachloride induced hepatic and renal disorders," BMC Complementary Alternative Medicine., 2006, Vol. 6: 33. Doi:10.1186/1472-6882-6-33.
- [3] K.R. Kirtikar, and B.D. Basu, "Indian Medicinal Plants," India, Singh, and MP Singh Publications, pp: 220.
- [4] M. Nazneen, M.A. Mazid, J.K. Kundu, S.C. Bachar, M.A. Rashid, and B.K. Datta, 2002, Dhaka Univ J Biol Sci, Vol. 11(2), pp. 183-187.
- [5] V. Satyanarayana, G.L. Kurupadanam, and G. Srimanaraya, "A butyrolactone lignan disaccharide from *Flacourtia ramontchi*," Phytochemistry, 1991, Vol. 30, pp. 1026-1029.
- [6] P.K. Bhaumik, K.P. Guha, G.K. Biswas, and B. Mukherjee, "Flacourtin, a phenolic glucoside ester from *Flacourtia indica*," 1987, Phytochemistry, Vol. 26, pp. 3090-3091.
- [7] M. Nazneen, A. Mazid, J.K. Kundu, S.C. Bachar, F. Begum, and B.K. Datta, "Protective effects of *Flacourtia indica* aerial parts extracts against paracetamol induced hepatotoxicity in rats," 2009, JTUSCI, Vol. 2, pp. 1-6.
- [8] J.B. Harbone, and H.H. Baxter, "Phytochemical Dictionary: A hand Book of Bioactive Compound from plants," Taylor and Francis, Washington, D.C., U.S.A, 1993, pp: 237.
- [9] G.E. Trease, and M.C. Evans, "Text book of Pharmacognosy," 13th Edition Bailleire Tindall, London, Toronto, Tokyo, 1989, pp: 200-201, 340-348, 419-423, 626-630, 765-775.
- [10] S. Saraf, and V.K. Dixit, "Hepatoprotective activity of *Tridax procumbens* part-II," Fitoterapia, 1991, Vol. 62, pp. 534-536.
- [11] S. Mohideen, R. Ilavarasan, E. Sasikala, and T.R. Kumarn, "Hepatoprotective activity of *Nigella sativa* Linn," Ind J Pharm Sci, 2003, Vol. 65, pp. 550-551.
- [12] K.G. Rajesh, N.K. Achyut, W. Geeta, P.S. Murthy, C. Ramesh, and T. Vibha, "Nutritional and Hypoglycemic Effect of Fruit Pulp of *Annona squamosa* in Normal Healthy and Alloxan-Induced Diabetic Rabbits," Ann Nutr Metab, 2005, Vol. 49, pp. 407-413.
- [13] H. Okhawa, N. Qohishi, and K. Yagi, "Assay of lipid peroxides in animal tissues by thiobarbituric acid reaction," Anal Biochem, 1979, Vol. 95, pp. 351-358.
- [14] T. Yoshikawa, Y. Furukawa, M. Murakami, S. Takemura, and M. Kondo, "Effect of vitamin E on D-Galactosamine-induced or carbon tetrachloride-induced hepatotoxicity," Digestion, 1982, Vol. 25, pp. 222-229.
- [15] L.W. Weber, M. Boll, and A. Stampfl, "Hepatotoxicity and mechanism of action of haloalkanes: carbon tetrachloride as a toxicological model," Crit Rev Toxicol, 2003, Vol. 33, pp. 105-136.