

# Brain MRI Segmentation and Lesions Detection by EM Algorithm

Mounira Rouaïnia, Mohamed Salah Medjram, and Nouredine Doghmane

**Abstract**—In Multiple Sclerosis, pathological changes in the brain results in deviations in signal intensity on Magnetic Resonance Images (MRI). Quantitative analysis of these changes and their correlation with clinical finding provides important information for diagnosis. This constitutes the objective of our work. A new approach is developed. After the enhancement of images contrast and the brain extraction by mathematical morphology algorithm, we proceed to the brain segmentation. Our approach is based on building statistical model from data itself, for normal brain MRI and including clustering tissue type. Then we detect signal abnormalities (MS lesions) as a rejection class containing voxels that are not explained by the built model. We validate the method on MR images of Multiple Sclerosis patients by comparing its results with those of human expert segmentation.

**Keywords**—EM algorithm, Magnetic Resonance Imaging, Mathematical morphology, Markov random model.

## I. INTRODUCTION

QUANTITATIVE analysis of magnetic resonance (MR) images deals with the problem of estimating tissue quantities and segmenting the anatomy into contiguous regions of interest. The problem has received along the ten years much attention largely due to the improved fidelity and resolution of MR imaging systems, and the effective clinical utility of image analysis and understanding in diagnosis and monitoring of several diseases. In addition, MR images provide three-dimensional (3-D) data with high contrast between soft tissues. However, the amount of data is far too much for manual analysis in particular in case of diagnosis. For this reason, automated techniques of computer aided image analysis are necessary to perform segmentation of MR images into different tissue classes, especially grey matter, white matter and cerebrospinal fluid.

Several pathological studies show that many neurological diseases are accompanied by subtle abnormalities change in brain tissue quantities and volume. This is the case of multiple sclerosis (MS), which is a disease of the central nervous system that appears as the myelin sheathes protecting nerves axons break down causing plaques. About 95% of multiple sclerosis lesions occur within white matter tissue [1] and cause signal intensity changes in MR images.

This is the most important property of MS MR imaging which makes MRI be the best paraclinical test in MS. Furthermore, MR images analysis is capital in monitoring treatment and studying its evolution in time, that is why it is very important to obtain accurate measurements of the lesions visible in the image data. The need for automated methods for MS lesions segmentation that can analyse large amount of data has been recognized and a lot of work has been spent to this aim.

Automated quantification of lesions remains to quantify signal intensity changes in MR images, and this is a difficult problem because of the artefacts affecting images such as partial volume effects and intensity inhomogeneities. Low level segmentation methods such as intensity thresholding, edge detection, region growing, region merging and morphological operation are not well suited for automated quantification of the signal abnormalities as these techniques rely on image operators that analyse intensity, texture or shape locally in each voxel, and therefore too easily misled by ambiguities in the image or require user interaction. Intensity driven methods fit intensity models to the data, and by taking imaging artefacts (partial volume effect, intensity homogeneities,...etc) into account, voxels (volume pixels) are classified independently or based on a Markov random field (MRF) prior [3, 4, 5]. And this is the methodology adopted in our work since our aim is to quantify changes in MR intensity. After the enhancement of images contrast and the brain extraction by mathematical morphology algorithm, we consider an automated stochastic method for detecting MS lesions from  $T_2$  weighted MR images. We use a model based iterative algorithm that simultaneously corrects from MR field inhomogeneities estimates tissue classes distribution parameters, and classifies the image voxels. MS lesions are detected as voxels that are not well described by the fitted model.

The method is detailed in section 2, section 3 presents and discusses the results of the implementation method. We finally formulate our conclusion in section 5.

## II. METHOD

### A. Preprocessing and Brain Extraction

The preprocessing step consists in the enhancement of images contrast by a local intensity histogram equalisation.

The brain extraction is a necessary step before segmentation. Indeed pixels lying outside the brain contour and which are not of interest (skin, fat, bone and air) share intensity with the structures of interest. By limiting the segmentation to brain, the computation time is reduced. This

Manuscript received September 30, 2006.

Mounira Rouaïnia is with The Skikda university PB 26 Route El Hadaek Skikda 21000 Algeria ( e-mail: rouainia\_m@yqhoo.fr).

Mohamed Salah Medjram is with The Skikda university PB 26 Route El Hadaek Skikda 21000 Algeria .

Nouredine Doghmane is with Annaba university BP 12 Annaba 23000 Algeria.

extraction is done with an algorithm based on mathematical morphology.

*B. EM Segmentation of MR Images of the Brain*

Suppose that there are J tissue types or so-called classes present in an MR image of the brain. The intensity of voxel i is denoted as  $y_i$ , then  $y = \{y_1, \dots, y_i, \dots, y_N\}$  describes the observed intensities where N is the total number of voxels. An often-used simple model for the intensity distribution of a voxel i that belongs to class j is a normal distribution with parameters mean  $\mu_j$  and variance  $\sigma_j^2$  grouped in

$\theta_j = \{\mu_j, \sigma_j^2\}$  [7]. As MR images suffer in general from an imaging artefact that introduces a spatially smoothly varying intensity inhomogeneity or so-called bias field in the images. We model the bias field in image y as a linear combination  $\sum_k c_k \phi_k(x)$  of K smoothly varying basis functions  $\phi_k(x)$ , where x denotes the spatial position [ref]. Thus, the intensity distribution of a voxel i that belongs to class j is given by:

$p(y_i / \Gamma_i = j, \theta_j, C) = G_{\sigma_j}(y_i - \mu_j - \sum_k c_k \phi_k(x_i))$  where  $G_j()$  is a zero-mean normal distribution with variance  $\sigma_j^2$ ,  $\Gamma_i \in \{1, \dots, 1, \dots, j\}$  denotes the class to which voxel i belongs, and  $C = \{c_1, \dots, c_k\}$  contains the bias field parameters.

We assume that the tissue types of the voxels are independently sampled from the J classes with known probability  $p(\Gamma_i = j)$ , the overall model becomes then  $p(y/\theta, C) = \prod_i p(y_i / \theta, C)$  where:

$$p(y_i/\theta, C) = \sum_j p(y_i / \Gamma_i = j, \theta_j, C) p(\Gamma_i = j) \quad (1)$$

and  $\theta = \{\theta_1, \dots, \theta_j\}$  denotes all the normal distributions parameters.

Assessing the maximum likelihood (ML) model parameters  $\{\theta, C\}$  given the observed intensities  $y_i$ , we apply the Expectation-Maximization (EM) algorithm that interleaves the following equations:

$$p(\Gamma_i = j / y_i, \theta, C) = \frac{p(y_i / \Gamma_i = j, \theta_j, C) p(\Gamma_i = j)}{\sum_j p(y_i / \Gamma_i = j, \theta_j, C) p(\Gamma_i = j)} \quad (2)$$

$$\mu_j = \frac{\sum_i p(\Gamma_i = j / y_i, \theta, C) (y_i - \sum_k c_k \phi_k(x_i))}{\sum_i p(\Gamma_i = j / y_i, \theta, C)} \quad (3)$$

$$\sigma_j = \frac{\sum_i p(\Gamma_i = j / y_i, \theta, C) (y_i - \mu_j - \sum_k c_k \phi_k(x_i))^2}{\sum_i p(\Gamma_i = j / y_i, \theta, C)} \quad (4)$$

$$C = (A^T W A)^{-1} A^T W R, \quad A_k = \phi_k(x_i)$$

$$R_i = y_i - \tilde{y}_i, \quad W = \text{diag}(w_i) \quad (5)$$

where

$$\tilde{y}_i = \frac{\sum_j w_{ij} \mu_j}{\sum_j w_{ij}}, \quad w_i = \sum_j w_{ij}, \quad w_{ij} = \frac{p(\Gamma_i = j / y_i, \theta, C)}{\sigma_j^2}$$

This EM algorithm interleaves classification of the voxels (equation 2), estimation of the normal distributions parameters (equation 3 and 4) and estimation of the bias field (equation 5). By the use of a digital brain atlas that contains spatially varying prior probabilities for grey matter (GM), white matter (WM) and cerebro-spinal fluid (CSF), the method can be fully automated. In addition, it can be extended to multispectral MR images by substituting the normal distributions with multivariate normal distributions with mean vector  $\mu_j$  and covariance matrix  $\Sigma_j$ .

*C. Multiple Sclerosis Lesions Detection*

The Gaussian mixture model described above gives good results in case of normal brain MR images. However, it does not include a model for MS lesions. Therefore, we can think to detect them as another class or rejection class that is not explained by the mixture model. This approach was proposed by [8] for modelling non-brain tissue in MR images by adding a uniform intensity distribution to the mixture model so that equation 1 becomes:

$$p(y_i/\theta, C) = \sum_j p(y_i / \Gamma_i = j, \theta_j, C) p(\Gamma_i = j) + \lambda p(\Gamma_i = \text{reject})$$

where  $\lambda$  is a small constant defined by the unity of the integral over all the intensities.

In the same ideas order, we can add to equation 2 a new uniform rejection class that contains voxels that are not described by the normal distributions such as MS lesions. Equations 3 and 4 remain valid and the same for equation 5 that estimate the bias field, except that the weights w are only calculated with respect to the normal distribution. That is, voxel rejected will have a zero weight for the estimation of the bias field.

*Spatial Constraints*

In general, 95% of the MS lesions are located inside white matter. This information is added to the model by assigning the atlas prior probability map of white matter to  $p(\Gamma_i = \text{reject})$ . In addition to this spatial constraint, we insert intensity constraint: MS lesions have an intensity between that of WM and CSF in T<sub>1</sub> images and appears hyper-intense in T<sub>2</sub> and PD images. Consequently, we can exclude voxels with intensity darker than the mean of CSF in T<sub>1</sub> images or darker than the mean of WM in T<sub>2</sub> and PD images from the rejection class. After the convergence of the modified EM algorithm, the obtained classification of the voxels contains lesions and non-lesions voxels, a post-processing step is then necessary to optimize this detection (decrease the number of false positive and false negative).

*Post-processing*

Given a single normal distribution with mean  $\mu_j$  and variance  $\sigma_j^2$ , an intensity  $y_i$  is said abnormal with respect to this distribution if its Mahalanobis distance  $d_j^i = (y_i - \mu_j) / \sigma_j$  exceeds a predefined threshold. But in the case of Gaussian mixture distributions assessing the abnormality of an intensity  $y_i$  is more involved. Intuitively,

we can make this assumption if the probability that  $y_i$  is generated by the GMM is small i.e. when:

$$\sum_j \sigma_j G_{\sigma_j}(y_i - \mu_j - \sum_k c_k \phi_k(x_i)) p(\Gamma_i = j) \leq k p(\Gamma_i = \text{lesion}) \quad (6)$$

where  $k$  is a small value defining a Mahalanobis distance threshold above which a voxel is detected as abnormal, independent of the variance of the classes. It is explicated as  $k = 1/\sqrt{2\pi} \exp(-0.5T^2)$  with  $T$  a Mahalanobis threshold experimentally set to  $\sqrt{3}$ . And given  $\theta$  and  $C$  as calculated by the EM algorithm, voxels where equation 6 holds will be classified as MS lesions.

However, as we explained in introduction, partial volume voxels are not described by the mixture model considered and are then misclassified as MS lesions, so we must discard this misclassification, the idea is to incorporate contextual information in the segmentation process by the use of **Markov Random Fields (MRF)**. As in [9], we make the hypothesis that the segmentation  $\Gamma$  is a realisation of a random process where the probability that voxel  $i$  belongs to class  $j$  depends on the classification of its neighbours. The Hammerley-Clifford theorem states that the configuration of such a random field obey to the distribution  $p(\Gamma) = Z^{-1} \exp(-U(\Gamma))$  where  $U(\Gamma)$  is an energy function and  $Z$  a normalization constant. We use the Potts model  $U(\Gamma) = \sum_i \sum_j \beta_{\Gamma_i, j} u_{i, j}$  where  $u_{i, j}$  counts the number of neighbours of voxel  $i$  that belong to class  $j$  and  $\beta_{l, j}$ ,  $1 \leq l, j \leq J$  are MRF parameters. These parameters are estimated from an image that was manually labelled into grey matter, white matter, MS lesions, csf and non brain tissues and by the use of histogram based technique [9]. We use the 8 in-plane neighbours because the slice thickness in MRI can vary widely.

This contextual information is incorporated in the final classification process by using the Iterated Conditional Modes algorithm (ICM) [7]. The prior probability that voxel  $i$  belongs to the class  $j$  depends on the classification of its neighbours:  $p(\Gamma_i = j) \propto \exp(-\sum_j \beta_{\Gamma_i, j} u_{i, j})$ . This prior replaces the atlas in this post-processing step, except for  $p(\Gamma_i = \text{lesion})$  where it is multiplied with the atlas prior probability for white matter. Starting from this segmentation obtained with this final classification rule, we calculate  $p(\Gamma_i = j)$  and re-apply the same rule with the updated prior. This is repeated until the classification stabilizes.

### III. RESULTS

As example of the implementation of the method, Fig. 1 shows a representative slice of a  $T_2$  MR image of a brain presenting multiple sclerosis lesions. On Fig. 2 we can see that the histogram equalization improves the contrast between lesions and other tissues. Fig. 3 shows the binary mask obtained by the morphological algorithm and which allows us to extract the brain as shown on Fig. 4.

The lesions detection results for the same slice are represented on Fig. 5. These results have been compared with

those obtained by manual tracing. The comparison has shown a significant correspondence.

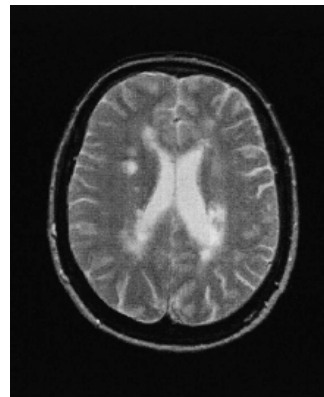


Fig. 1  $T_2$  weighted image with MS lesions

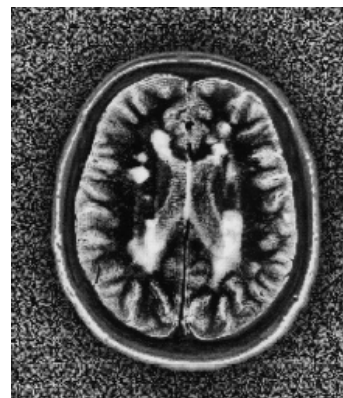

Fig. 2 Histogram equalization of the image

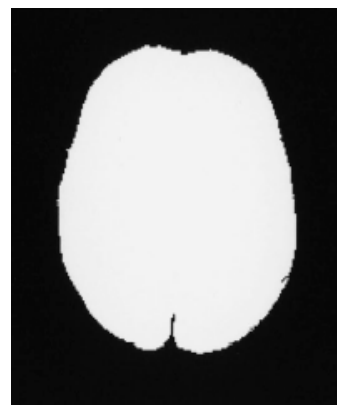


Fig. 3 Binary mask

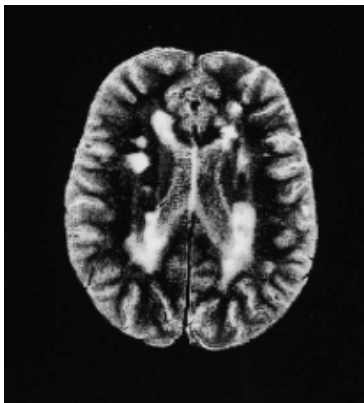


Fig. 4 Brain extraction

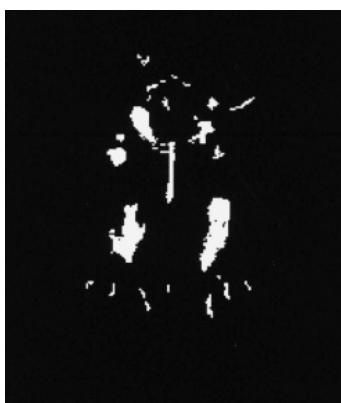


Fig. 5 Results of lesions detection

- [3] K.Held, E.R.Kops, B.J.Kraus, W.M.Wells, R.Kikinis, H.W.Mullet-Gartner, "Markov random field segmentation of brain MR images" *IEEE Trans Med Imag* vol 16 (6) 1997, pp 878-886.
- [4] W.M.Wells, W.E.L.Grimson, R.Kikinis, F.A.Jolesz, "Adaptive segmentation of MRI data" *IEEE Trans Med Imag* vol 15 (4) 1996, pp429-442.
- [5] Y.Zhang, M.Brady, S.Smith "Segmentation of brain MR images through a Hidden Markov random field model and the expectation maximization algorithm" *IEEE Trans Med Imag* vol. 20 (01) Jan 2001, p 45-57.
- [6] J.L.Marroquin, B.C.Venuri, S.Botello, F.Calderon, A.Fernandez-Bouzas "An accurate and efficient Bayesian method for automatic segmentation of brain MRI" *IEEE Trans Med Imag* vol. 21(08) Aout 2002, p 934-945.
- [7] H.Yang, "Signal processing for Magnetic Resonance Imaging and Spectroscopy" Marcel Dekker London, 2002 chapter 13.
- [8] R.Guillemaud, M.Brady, "Estimating the bias field of MR images" *IEEE Trans Med Imag* vol 16 (3) 1997, pp 238-251.
- [9] K.Van Leemput, F.Maes, D.Vandermeulen, P.Suetens, "Automatic segmentation of brain tissues and MR bias field correction using a digital brain atlas" *Proceedings of MICCAI'98* vol 1496 of Lecture notes in computer sciences, Springer 1998, pp1222-1229.
- [10] F.Bello, A.C.F.Colchester, "Measuring global and local spatial correspondence using information theory" *Proceedings of MICCAI'98* volume 1496 of Lecture notes in computer science, Springer 1998, pp 964-973.

#### IV. CONCLUSION

We presented in his paper an automated stochastic model based method for multiple sclerosis lesions detection from MR images. After preprocessing the images and brain extraction, the method estimates tissue class distribution parameters and classifies the image voxels and simultaneously corrects from MR field inhomogeneities. MS lesions are detected as voxels belonging to a rejection class that is not described by the fitted model. The results were compared with those obtained by human expert showing a significant correspondence. The most important requirement for an automated method is that its measurements change in response to a treatment in a manner proportionate to manual measurements. It seems to be necessary to analyse the patients MR images along the treatment for a best validation of this automatic method.

#### REFERENCES

- [1] I.Grosman, J.C.Mc Gowan, "Perspectives on Multiple Sclerosis" *AJNR* n° 19, 1998, pp 1251-1265.
- [2] J.Rajakse, J.Giedd, J.Rapoport, "Statistical approach to segmentation of single channel cerebral MRimages" *IEEE Trans Med Imag* vol 16(2), 1997, pp 176-186.