

A Fuzzy Tumor Volume Estimation Approach Based on Fuzzy Segmentation of MR Images

Sara A. Yones, and Ahmed S. Moussa

Abstract—Quantitative measurements of tumor in general and tumor volume in particular, become more realistic with the use of Magnetic Resonance imaging, especially when the tumor morphological changes become irregular and difficult to assess by clinical examination. However, tumor volume estimation strongly depends on the image segmentation, which is fuzzy by nature. In this paper a fuzzy approach is presented for tumor volume segmentation based on the fuzzy connectedness algorithm. The fuzzy affinity matrix resulting from segmentation is then used to estimate a fuzzy volume based on a certainty parameter, an Alpha Cut, defined by the user. The proposed method was shown to highly affect treatment decisions. A statistical analysis was performed in this study to validate the results based on a manual method for volume estimation and the importance of using the Alpha Cut is further explained.

Keywords—Alpha Cut, Fuzzy Connectedness, Magnetic Resonance Imaging, Tumor volume estimation.

I. INTRODUCTION AND RELATED WORK

MAGNETIC Resonance Imaging (MRI) radiologic evaluation of treatment response during clinical testing of novel therapeutic drugs has become increasingly important [1]. The paradigm of radiologic assessment of drug efficacy is especially attractive in cancer patients. This is because tumor size can be monitored serially from before treatment is started through the treatment period to any follow-up interval. Currently, tumor size measurement is based on uni-dimensional tumor measurement technique, which measures the longest lesion diameter in the axial plane. This approach is obviously accurate for perfectly spherical lesions and can be used for measuring tumor size for response classification. However, prior studies have shown that when tumors develop into shapes in which the width is more than twice the length, which often occurs after treatment because of scarring, bi-dimensional measurements such as volume provide a more accurate classification of treatment response than diameter alone [1]. The latter problem has led the research to be directed towards tumor volume estimation. Jianguo Liu *et al.* [2] presented a method for precise, accurate, and efficient quantification of brain tumor (glioblastomas) and emphasized the importance of estimation of tumor volume for evaluating disease progression, response to therapy, and in assessing the need for changes in treatment plans. Yasser M. Salman emphasized that quantitative measurements of tumor response

rate in three dimensions (3D) become more realistic with the use of advanced technology imaging during therapy, especially when the tumor morphological changes remain subtle, irregular, and difficult to assess by clinical examination [3]. Gul Moonis *et al.* highlighted this fact in [4] by indicating that reproducible measurements of brain tumor volume are helpful in evaluating the response to therapy and the need for changing treatment plans.

Segmentation of tumors in MR images is an essential step for the computation of their volume [2]. Several approaches have been reported in the literature for tumor segmentation in MR images. Fletcher-heath *et al.* [5] developed an automatic segmentation method which separates non-enhancing brain tumor using an unsupervised fuzzy clustering method. Zhu, Y. and Yan, H. [6] presented an approach to detect brain tumor boundary in MR images using a Hopfield Neural Network. Rai, A. and Juluru, K. proposed a semi-supervised technique using k-means clustering in a hybrid intensity-spatial feature space to segment Hepatocellular carcinoma (liver tumor) from MR images [7]. Rodrigues, P. *et al.* developed an interactive algorithm for liver tumor segmentation in MR and CT images. The technique was based on an image partitioning into homogeneous primitives regions and the outcome of the latter initial segmentation was the input of a region merging process to find the best image partitioning, based on the minimum description length principle [8]. Zheng, Y. *et al.* devised new graph cut based segmentation algorithm for refining coarse manual segmentation, which allows identification of breast tumor regions [9].

In spite of the above cited activities in research none of them used the notion of fuzzy volume. None of the segmentation algorithms can guarantee perfect segmentation of tumors from medical images when the lesions have complicated topological structures and heterogeneous intensity distribution. In this study we make use of the fuzzy affinity matrix produced by the Fuzzy Connectedness segmentation algorithm to estimate the volume based on an Alpha Cut parameter provided by the user. The user can then compare the output volume and segmentation for each Alpha Cut provided to the system. Subsequently, the user can decide which Alpha Cut is more adequate to use for volume estimation. This should result in more realistic decisions in tumor response to therapeutic drugs and in surgical resection. It would be very important for brain tumor surgeries because each millimeter removed could highly affect the function of other organs.

In this work the experiments were based on axial STIR and Vdyn_etrive_Sense MR slices for breast tumor patients. Delineation of breast lesions is known to be challenging, since

Sara A. Yones is with Computer Science Department, Faculty of Computers and Information, Cairo University, Giza, Egypt (Institutional mailing address: 5 DR. Ahmed Zewail street, Postal code 12613, Orman, Giza, Egypt (e-mail: s.yones@fci-cu.edu.eg).

Ahmed S. Moussa is with Computer Science Department, Faculty of Computers and Information, Cairo University, Giza, Egypt (Institutional mailing address: 5 DR. Ahmed Zewail street, Postal code 12613, Orman, Giza, Egypt (e-mail: a.moussa@fci-cu.edu.eg)

the lesions may have diverse intensity distributions and unfamiliar structures. The rest of the paper is divided into five sections. Section II explains required background information. The methodology is described in Section III. Our evaluative studies conducted to validate the output of the system are described in Section IV. Concluding remarks are stated in Section V.

II. BACKGROUND

Image segmentation divides an image into multiple parts and is typically used to identify objects or other relevant information in digital images. Most of the image segmentation algorithms only consider pixels which are close in intensity values form an object. The output is another binary image where the identified objects have white pixels and the rest of the pixels are black. This should not be the case when dealing with medical images since the intensity characteristics of pixels are similar to each other. Additionally, the tumor contour is fuzzy by nature because the intensity distinction between tissue classes (tumor and non tumor) is usually blurry. The Fuzzy Connectedness segmentation algorithm attempts to handle this limitation [4]. The main idea behind the Fuzzy Connectedness theory is that the strength of connectedness is considered to exist between any two pixels p_1 and p_2 on the image. This strength is determined by considering all possible connecting paths between p_1 and p_2 . Each path has strength of connectedness associated with it that is determined by examining successive pairs of pixels along the path. Each pair of nearby pixels has an affinity associated with it that is determined not only on the similarity in their intensity characteristics, but also on the basis of how close the pixels are spatially. Affinity describes how strongly the pixels hang together locally in the same object. The strength assigned to a path is the smallest affinity of pair wise elements along the path. The strength of connectedness between any two elements p_1 and p_2 is the strength of the strongest of all paths between p_1 and p_2 . To compute a fuzzy-connected object, the strength of connectedness between all possible pairs of pixels in the image must be determined. The output of the algorithm is not a binary image that strictly defines the contours of identified objects but an affinity matrix where the object of interest is characterized by pixels with values indicating as closely as possible their degree of membership in that object not binary values. Seeding the segmentation with representative pixels within the object of interest is an essential input step for the algorithm. This enables the algorithm to designate the neighboring pixels and segment the object accordingly.

In order to segment the tumor and estimate the volume from MR images, MR series have to be collected for each patient a priori. Each MR series contains sequential slices or images for the organ under investigation, scanned with a certain MRI protocol (such as T1, T2, STIR, etc.), and from a certain position (Axial, Coronal or Sagittal). The MR slices where the lesion appears are chosen for segmentation and volume estimation. The MR slices chosen should be from the same series and sequential. The appearance of the lesion in each

slice constitutes a portion of the tumor. The area of the region where the tumor appears is computed independently in each MR slice and used afterwards for volume computation. Fig. 1 shows three sequential slices from an axial STIR series and the lesion appears in each one of them.

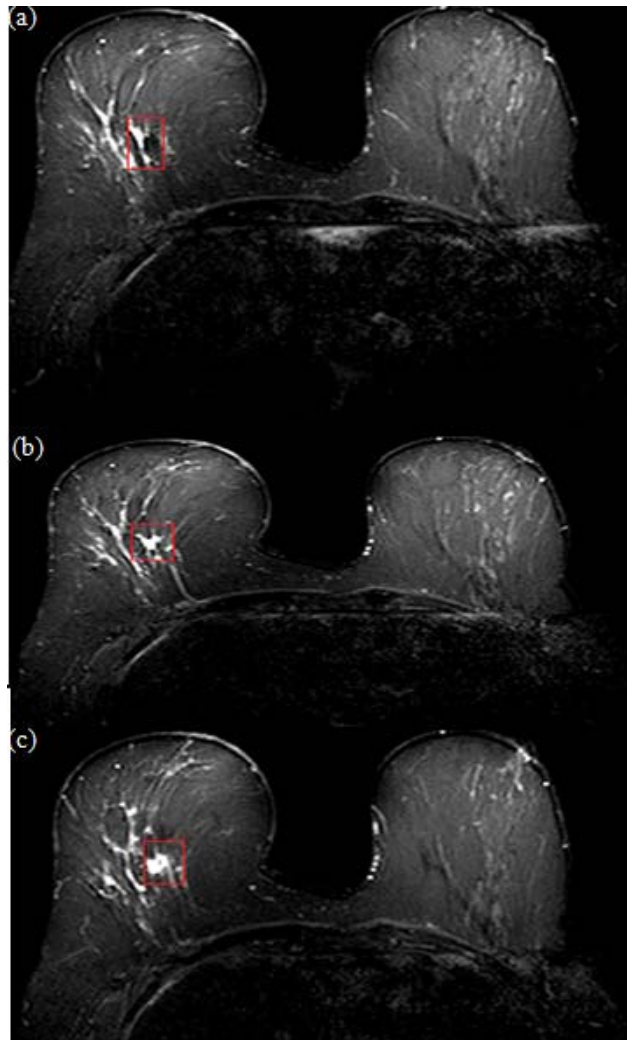


Fig. 1 Images show three sequential slices and the lesion appears in each one of them

III. METHODOLOGY

In order to compute the volume of the tumor for each patient six steps were executed:

- 1- MR data acquisition.
- 2- MR slices pre-processing.
- 3- Segmentation of MR slices.
- 4- Post-processing of the output MR slices.
- 5- Computing the area of the tumor in each MR slice
- 6- Computing the volume.

The rest of this section describes the details of each of the six steps.

1- MR data acquisition

MR data of six female patients with malignant breast lesions aging from 48-60 were included in this study. All studies were performed with 3-T Philips imaging system. An experienced radiologist conducted the analysis on Vdyn_ethrive_Sense and STIR images for each patient to filter the malignant cases and locate the slices where the tumor appears.

2- MR slices pre-processing

Three pre-processing steps were done on each MR slice prior to segmentation.

A. Defining a Region of Interest

For each chosen MR slice two coordinates were chosen to define a rectangular Region of Interest (ROI) confining the lesion. This was not an attempt to trace the borders of the lesion; it served to limit the region in which subsequent analyses were performed. This is to simplify the segmentation process to detect only one object which is the tumor. Additionally, processing time was considerably reduced. Without choosing a ROI segmentation process took up to 20 seconds or more whereas with specifying a region of interest segmentation time was less than 2 seconds. All subsequent operations used the cropped slices after the ROI was defined. Fig. 2 shows the cropped MR slices after defining the ROI.

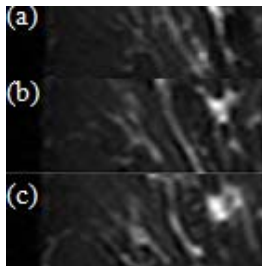


Fig. 2 The cropped MR slices after defining the ROI for Fig. 1(a), Fig. 1(b), and Fig. 1(c) respectively

B. Applying Edge Preserving Smoothing Filter

Noise present in the image can reduce the capacity of the Fuzzy Connectedness algorithm to grow large regions. When faced with noisy images, it is usually convenient to pre-process the image by using an edge-preserving smoothing filter. In this study we used Curvature Flow Image Filter. The idea behind the Curvature Flow Image Filter is that the regions of high curvature diffuse very quickly. This removes noise artifacts. The regions of less curvature (such as image edges) diffuse much slower, thereby preserving the features.

C. Rough Segmentation for Computing Required Parameters

Since the Fuzzy Connectedness algorithm requires an estimation of the grey level mean and variance for the region to be segmented, another segmentation filter was used prior to it in order to compute these parameters. In this study we used

the Confidence Connected Image Filter as a pre-processor to estimate these values [10].

3- Segmentation of MR slices

The seed point was specified within the tissue of interest for each cropped MR STIR slice after specifying the ROI. The rest of the pre-processing steps were done after choosing the seed point. Each seed point, the parameters required (The mean and variance of the grey level for the region to be segmented), and each MR slice were fed as an input to the system implementing the Fuzzy Connectedness algorithm. The system then displayed the delineated tumor region by writing the output fuzzy affinity matrix to a DICOM file. The DICOM headers of the original MR slices were preserved for area calculation. In some cases, new ROI can be defined on selected output images if there are irrelevant segmented tissues. ITK 3.2[11] and Visual studio 2010 programming development environments were used to implement the pre-processing steps and the segmentation. ITK was chosen for its wide range of medical image processing functions. Fig. 3 shows three output MR slices after defining the ROI and after segmentation.



Fig. 3 Output MR slices after defining the ROI and after segmentation for Fig. 2(a), Fig 2(b), and Fig. 2(c) respectively

4- Post-processing of the output MR slices

The output MR slices from segmentation were scaled to enhance their contrast. There were cases in which the segmented object (foreground) was darker than the background. In order to solve this, the scaling was done on the inverse of the image. Fig. 4 shows the output MR slices after segmentation and contrast enhancement.




Fig. 4. The output MR slices after segmentation and contrast enhancement for Fig 3(a), Fig. 3(b) and Fig. 3(c) respectively

5- Computing the area of the tumor in each MR slice

The user first specifies the certainty or the Alpha Cut upon which the area will be computed. For each output MR slice a threshold operation is done. The pixels which have values greater than the Alpha Cut are given a binary value equal to one. The rest of the pixels are assigned a zero value.

The area is computed by counting the white pixels. In order to compute the area of the irregular tumor shape in cm after the thresholding operation, the area of each pixel should be computed in cm² first. This is done by reading the pixel spacing tag from the DICOM header of any of the output MR slices. The pixel spacing tag represents the spacing between the centers of any two adjacent pixels in mm. Half the length of the pixel spacing represents half the length of a pixel and the other half represents half the length of the adjacent pixel. Since all the pixels in the image have the same length, then the pixel spacing is equal to the pixel length. The area of any pixel in cm² is computed using (1).

$$area\ of\ pixel = \left(\frac{pixel\ spacing}{10}\right)^2 \quad (1)$$

Fig. 5 shows that the pixel spacing is equal to the pixel length. The area of the irregular tumor shape is computed using (2). $area_i$ represents the area of the tumor in the i^{th} output MR slice.

$$area_i = pixel\ area * Number\ of\ white\ pixel \quad (2)$$

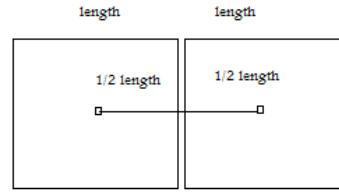


Fig 5 The spacing between two adjacent pixel centers (Pixel Spacing) is equal to the pixel length

6- Computing the volume

Volume is generally computed by multiplying the area and the height together. The height in this case is represented by the MR slice thickness and the gap between any two MR slices. The slice thickness and the inter slice gap values can be obtained by reading the two DICOM tags; slice thickness and spacing between MR slices from any output MR slice. The values should be converted to cm because they are represented in mm. Volume is computed using (3). N represents the number of output slices and $area_i$ represents the area of the tumor in the i^{th} output MR slice.

$$Volume = \sum_{i=1}^N area_i * (Slice\ Thickness + Spacing\ between\ slices) \quad (3)$$

IV. RESULTS AND DISCUSSION

It was difficult to validate the results of our method due to the absence of pathology that would establish the true delineation of the object of interest in a scene. Consequently, an appropriate surrogate of truth was used in place of true delineation. The segmentation resulting from manual tracing of object boundaries by knowledge operator (radiologist) is commonly used as this surrogate. We used this approach to validate the computed volume.

The volume of the tumor for each patient was computed two times once with our approach and the second by manual tracing of the tumor borders in each MR slice using Onis 2.4 tool. The tool computes the area of the highlighted portion in each MR slice and the volume was computed manually using step 6 in section 5.

Let V_c be the volume computed by our system and V_t be the volume computed manually by the radiologist. The Mean Square Error (MSE) between V_c and V_t for each Alpha Cut per each patient is shown in Table I. Equation (4) was used to compute the MSE between V_t and V_c for each Alpha Cut. N refers to the number of patients.

$$MSE = \frac{\sum_{i=1}^N (V_{t_i} - V_{c_i})^2}{2} \quad (4)$$

TABLE I
THE MEAN SQUARE ERROR BETWEEN V_t AND V_c

| | Patient1 | Patient2 | Patient3 | Patient4 | Patient5 | Patient6 |
|-----|----------|----------|----------|----------|----------|----------|
| 0.1 | 7.4 | 202.8 | 16.6 | 1.0 | 18.7 | 88.4 |
| 0.2 | 8.3 | 229.8 | 29.7 | 1.1 | 49.6 | 57.3 |
| 0.3 | 9.0 | 249.4 | 39.6 | 1.1 | 78.3 | 28.0 |
| 0.4 | 9.4 | 280.8 | 50.8 | 1.2 | 108.3 | 13.5 |
| 0.5 | 9.7 | 311.8 | 57.2 | 1.3 | 134.6 | 4.0 |
| 0.6 | 10.2 | 346.2 | 65.2 | 1.4 | 211.8 | 0.1 |
| 0.7 | 10.6 | 389.2 | 77.1 | 1.5 | 247.4 | 5.6 |
| 0.8 | 10.8 | 457.8 | 86.3 | 1.6 | 285.5 | 27.1 |
| 0.9 | 11.0 | 561.8 | 95.6 | 1.7 | 360.3 | 55.1 |

It is obvious from the results that some patients such as Patient1 and Patient4 have low MSE for all Alpha Cuts compared to Patient2 and Patient5 this is because of error aggregation due to the number of MR slices used. For example, the tumor appeared in only 3 MR slices for Patient4 while for Patient2 the tumor appeared in 20 MR slices. Additionally, the numbers show that in most cases there is a decreasing function between the Alpha Cut and the MSE.

Fig. 6 highlights the latter observation. This observation makes sense since as the degrees of certainty (the Alfa Cut) increase the delineated area of the tumor per each output MR slice decreases and accordingly, the volume decreases. This is shown in Fig. 7.

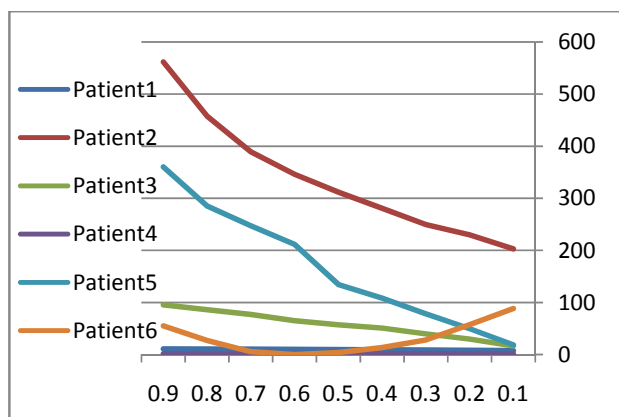


Fig. 6 There is a decreasing function between the Alpha Cut and the Mean Square Error in most cases




Fig. 7 Three output MR slices for Patient4. The red filling in Fig. 7(a), Fig. 7(b), and Fig. 7(c) represents the tumor coverage for Alpha Cut 0.5. The red filling in Fig. 7(d), Fig. 7(e), and Fig. 7(f) represents the tumor coverage for Alpha Cut 0.9

The Alpha Cut concept is extremely important for the purpose of accurate evaluation of treatment response of therapeutic drugs in specific cases. Consider a case such as Patient4 (Fig. 4). Assume that the shape of the tumor did not change before and after treatment. Using any system for volume computation that uses any non fuzzy segmentation technique the shape and the computed volume of the segmented tumor will be the same before and after treatment. Even if a slight change occurred in the grey level distribution of the tumor none of the segmentation methods would consider this change. Assume that Fig. 7(a), Fig. 7(b), and Fig. 7(c) is the shape of the tumor after segmentation in each output MR slice using our approach with Alpha Cut 0.9 before treatment and Fig. 7(d), Fig. 7(e), and Fig. 7(f) is the shape of the tumor after segmentation with the same Alpha Cut. This shows that the tumor volume has diminished. This wouldn't have been noticed if another image segmentation method was used. Accordingly, a wrong decision would have been taken.

V. CONCLUSION

Fully making use of the Fuzzy Connectedness technology and MRI, we have developed a complete methodology for tumor volume estimation based on an Alpha Cut provided by the user. The methodology runs automatically except for choices of a region of interest and seed points. Our method was validated with respect to manual volume estimation and the results were close at small Alpha Cut Values. The results showed the importance of Alpha Cut in volume estimation in cases when the shape of the tumor before and after treatment remains the same but the grey level distribution changes. Further work can be done on Sagittal and Coronal MR sequences beside the axial sequences.

ACKNOWLEDGMENT

The authors are grateful to Dr. Maha Hussein Helal for providing the MR images in addition to filtering malignant cases, and to Mohamed Abd El Wahab for his help in implementing the system.

REFERENCES

- [1] Sanjay Saini, "Radiological Measurement of Tumor Size in Clinical Trials: Past, Present, and Future," *AJR*: 176 February 2001.
- [2] Jinaguo Liu, Jayaram K. Udupa, Dewey Odhner, David Hackney, and Gul Moonis, "A system for brain tumor volume estimation via MR imaging and fuzzy connectedness," *Computerized Medical Imaging and Graphics, Elsevier*, vol. 29, pp. 21-34, 2005.
- [3] Yasser M.Salman, "Modified technique for volumetric brain tumor measurements," *J Biomedical Science and Engineering, Scientific Research Publishing*, vol. 2, pp.16-19, 2009.
- [4] Gul Moonis, Jianguo Liu, Jayaram K. Udupa, and David B. Hackney, "Estimation of Tumor Volume with Fuzzy Connectedness Segmentation of MR Images," *AJNR Am J Neuroradiol*, vol. 23, pp.356-363, American Society of Neuroradiology, March 2002.
- [5] Fletcher-Heath LM, Hall LO, Goldgof DB, Murtagh FR, "Automatic segmentation of non-enhancing brain tumors in magnetic resonance images," *Artif Intell Med*, vol 21, pp. 43-63, 2001.
- [6] Zhu Y, Yan H. "Computerized tumor boundary detection using a Hopfield neural network," *IEEE Trans Med Imag*. vol. 16, no. 1, pp. 55-67, February 1997.
- [7] Rai A, and Juluru K, "Visualization and segmentation of liver tumors using dynamic contrast MRI," *Conf Proc IEEE Eng Med Biol Soc*, vol 2009, pp. 6985-6989, 2009.
- [8] Rodrigus, Vilaca, J.L, and Fonseca, J, "An image processing application for liver tumor segmentation," *Bioengineering (ENBENG)*, 2011.
- [9] Zheng Y, Baloch S, Englander S, Schnall MD, and Shen D, "Segmentation and classification of breast tumor using dynamic contrast-enhanced MR images," *Med Image Comput Comput Assist Interv*, vol 10, pp. 393-401, 2007.
- [10] http://orfeo-toolbox.org/doxygen-current/FuzzyConnectednessImageFilter_8cxx_source.html
- [11] <http://www.itk.org/>