

Wound Healing Effect of *Ocimum sanctum* Leaves Extract in Diabetic Rats

Manish Kumar Gautam and Raj Kumar Goel

Abstract—Delayed wound healing in diabetes is primarily associated with hyperglycemia, over-expression of inflammatory marker, oxidative stress and delayed collagen synthesis. This unmanaged wound is producing high economic burden on the society. Thus research is required to develop new and effective treatment strategies to deal with this emerging issue. Our present study incorporates the evaluation of wound healing effects of 50% ethanol extract of *Ocimum sanctum* (OSE) in streptozotocin (45mg/kg)-induced diabetic rats with concurrent wound ulcer. The animals showing diabetes (Blood glucose level >140 and <250 mg/dL) will be selected for wound healing study using standard dead space wound model. Wounds were created by implanting two polypropylene tubes (0.5 x 2.5 cm² each), one on either side in the lumbar region on the dorsal surface of each rat. On the 10th post-wounding day, the animals were sacrificed and granulation tissue formed on the implanted tubes was carefully dissected out and study the status of antioxidants (Superoxide dismutase, SOD and Glutathione, GSH) free radicals (Lipid peroxidation, LPO and nitric oxide, NO) acute inflammatory marker (myeloperoxidase, MPO) connective tissue determinants, hydroxyproline, hexosamine and hexuronic acid, which play a major role in wound healing and diabetes. Besides the anti-diabetic parameters (estimation of serum blood glucose, triglycerides and total cholesterol), the above parameters for wound healing were studied both in normal, untreated and OSE treated diabetic rats. The effects of extract on above parameters will be compared with known standard antioxidant (Vitamin E) and anti-diabetic (Glybenclamide) drugs. OSE 400 mg/kg substantiated by significantly decreased serum blood glucose, triglycerides and total cholesterol. OSE also decrease granulation tissue free radicals (LPO, 58.1% and NO, 52.7%) and myeloperoxidase (MPO, 63.3%), and enhanced antioxidants (GSH, 116.4% and SOD, 201.1%) and connective tissue markers (hydroxyproline, 169.2%; hexuronic acid, 156.7% and hexosamine, 134.3%) with histological evidence. *Ocimum sanctum* seems to promote wound healing by enhancing connective tissue formation and antioxidants status with decrease in blood glucose level, free radicals and myeloperoxidase.

Keyword—Wound healing, diabetes, *Ocimum sanctum*, Antioxidant, Free radical, Myeloperoxidase

I. INTRODUCTION

CUTANEOUS wound healing is a complex processes that involves coordinated interaction between a number of cell types, extracellular matrix (ECM) molecules, and growth factors in three overlapping phases, coagulation and inflammation, Proliferation and remodeling [1]. Delayed

wound healing in diabetes is primarily, associated with hyperglycemia, over-expression of inflammatory cytokines, oxidative stress, delayed collagen synthesis, reduced angiogenesis and also the microbial infections [2]. In fact, the microbial infection indirectly enhances FR stress through respiratory burst. This unmanaged wound is producing high economic burden on the society. Thus research is required to develop new and effective treatment strategies to deal with this emerging issue.

Ocimum sanctum Linn (family- Labiatae) known as holy basil, is a commonly used home remedy have been advocated for various ailments like cold, fever, dysentery, hemorrhage and dyspepsia, glaucoma, cataract, chronic conjunctivitis and other painful eye diseases, gastric and hepatic disorders. Pharmacological properties including anti-stress, antifertility, immunoregulatory, hypoglycemic, antibacterial, anti-fungal, anti-inflammatory, anti-carcinogenic, antioxidant and cyclooxygenase inhibitory reported for this plant. *O. sanctum* (OS) has been reported to show gastroduodenal ulcer protective, antisecretory and gastric mucosal defense enhancing activities. The leaves of *O. sanctum* contains a volatile oil composed of limonene, borneol, copaene, caryophyllene and elemol; phenolic compounds (rosmarinic acid, apigenin, cirsimaritin, isothymusin), flavonoids (orientin, vicianin) and aromatic compounds (methyl chavicol, methyl eugenol) [3], [4].

Our present study incorporates the evaluation of wound healing effects of 50% ethanol extract of *Ocimum sanctum* (OSE) in streptozotocin induced diabetic rats with concurrent wound ulcer.

II. MATERIAL AND METHODS

A. Experimental Animals

Inbred Charles-Foster albino rats (160-180 g) and Swiss albino mice (20-25 g) of either sex were obtained from the central animal house of Institute of Medical Sciences, Banaras Hindu University, Varanasi. They were kept in the departmental animal house at 26 ± 2^o C and relative humidity 44-56%, light and dark cycles of 10 and 14 h. respectively for one week before and during the experiments. Animals were provided with standard rodent pellet diet (Pashu Aahar Vihar, Ramnagar, Varanasi) and water *ad libitum*. 'Principles of laboratory animal care' (NIH publication no. 82-23, revised 1985) guidelines were followed. Approval from the Central Animal Ethical Committee of the University was taken prior to the experimental work (Notification no. - Dean/2010-11/173 dated 23.07.2010).

MK Gautam is with the Department of Pharmacology, Faculty of Modern Medicine, Institute of Medical Sciences, Banaras Hindu University, Varanasi 221005, India (email- manishpharmacology@gmail.com)

RK Goel is with the Department of Pharmacology, Faculty of Modern Medicine, Institute of Medical Sciences, Banaras Hindu University, Varanasi 221005, India (email- rkgoelbhu50@gmail.com)

B. Plant Material and Preparation of Extract

The leaves of *Ocimum sanctum* (OS) (Ayurvedic Gardens, Banaras Hindu University) were collected during October-December and identified with the standard sample preserved in the department of Dravyaguna, Institute of Medical Sciences, Banaras Hindu University, Varanasi. 50% ethanolic extract of OS (OSE) was prepared by adding 500 g of dried, crushed and powdered leaves of OS in 1000 ml of 50% ethanol in a round bottom flask and was kept at room temperature for 3 days in shade. The extract was filtered and the above procedure was repeated twice. The extract filtrate so obtained were pooled and evaporated on water bath till it dried. The yield of OSE was about 5.00% (w/w).

C. Induction of Severe Diabetes

Diabetes was induced in rats by single intraperitoneal injection of streptozotocin (45mg/kg body weight) in normal saline. The animals showing diabetes (Blood glucose level >140 and <250 mg/dL) will be selected for wound healing study using standard dead space wound model.

D. Dead Space Wound Model

Rats were anesthetized with ketamine and 1 cm incision was made on dorso-lumbar part of the back. Two polypropylene tubes (0.5 x 2.5 cm² each) were placed in the dead space of lumbar region of rat on each side, and wounds were closed with a suture material. On the 10th post-wounding day, the animals were sacrificed and granulation tissue formed on and around the implanted tubes was carefully dissected out, weighed and processed for the estimation of free radicals, antioxidants and collagen tissue parameters [5].

E. Estimation of Granulation Tissue Free Radical and Antioxidant

Antioxidants- superoxide dismutase, SOD; and reduced glutathione, GSH; free radicals- lipid peroxidation, LPO and nitric oxide, NO and acute inflammatory marker, myeloperoxidase (MPO) and protein were estimated in wet granulation tissue homogenates. Briefly, the wet granulation tissues were homogenized in a glass Teflon homogenizer (10% w/v) at 4°C in Phosphate buffered saline (PBS, pH 7) used for the estimation of protein, free radicals and antioxidants [5]. For myeloperoxidase (MPO) estimation, granulation tissue (5% w/v) was homogenized in 0.5% hexadecyltrimethylammonium bromide (HTAB, Sigma-Aldrich, Co., St. Louis, MO, USA) with 50mM potassium phosphate buffer (pH 6). The above homogenate was freeze-thawed three times and sonicated for 10 seconds and then centrifuged at 14000 X g for 45 minutes at 4°C and the resulting supernatant was used for estimation of MPO. A unit of MPO activity is defined as that converting 1 μ mol of H₂O₂ to water in 1 min at 25°C.

F. Estimation of Connective Tissue Parameters

Approximately 250 mg of wet tissue was dried at 50°C for 24 h. It was weighed and kept in glass stoppered test tubes. To each tube containing 40 mg of the dried granulation tissue, 1 ml of 6N HCl was added. The tubes were then kept on boiling

water bath for 24 h (12 h each day for two days) for hydrolysis. The hydrolysate was then cooled and excess of acid was neutralized by 10N NaOH using phenolphthalein as indicator. The volume of neutral hydrolysate was diluted to a concentration of 20 mg/ml with distilled water. The final hydrolysate was used for the estimation of hydroxyproline, hexosamine and hexuronic acid following the standard curve prepared using the proper substrate [5].

G. Statistical Analysis

Statistical comparison was performed using either unpaired *t*-test or one way analysis of variance (ANOVA) for multiple comparisons versus control group was done by Dunnett's test. All statistical analysis was performed using SPSS statistical version 16.0 software package (SPSS® Inc., USA).

III. RESULTS

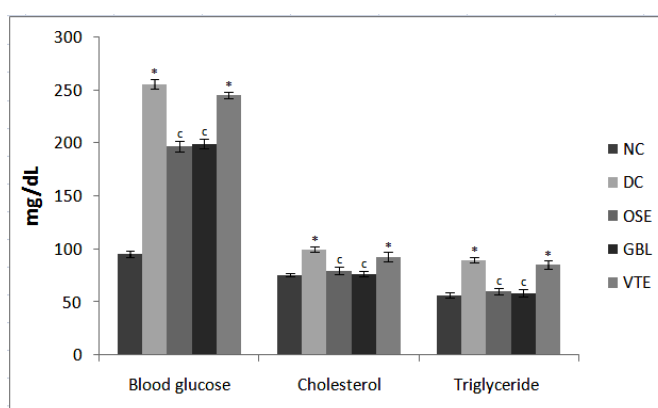


Fig. 1 Effect of OSE on blood glucose, cholesterol and triglyceride levels in diabetic rat. Results are mean \pm SEM of 6 rats in each group. **P*<0.001 compared to normal control (NC) group (unpaired 't' test), and °*P*<0.001 compared to respective diabetic control (DC) group (one way analysis of variance followed by Dunnett's test)

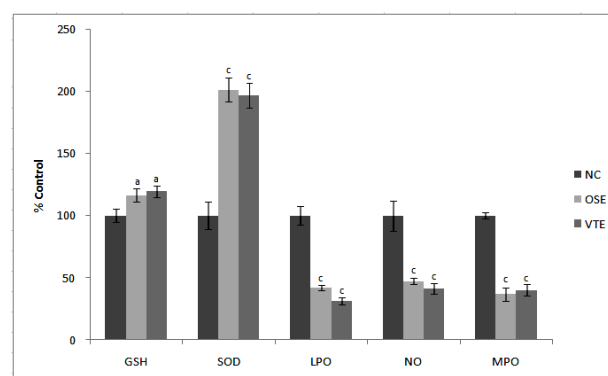


Fig. 2 Effect of OSE and VTE on wet granulation tissue antioxidants (GSH & SOD), free radicals (LPO & NO) and myeloperoxidase (MPO) levels in rats. Results are mean \pm SEM of 6 rats in each group. °*P*<0.05 and °°*P*<0.001 compared to respective vitamin E (VTE) group (one way analysis of variance followed by Dunnett's test)

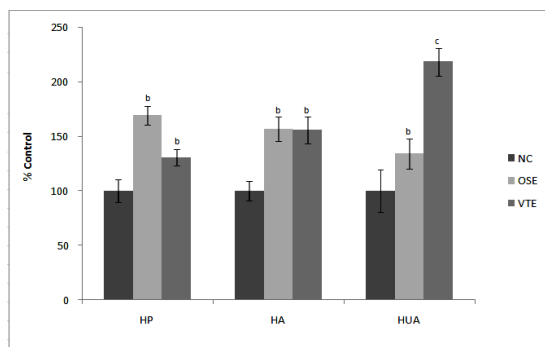


Fig. 3 Effect of OSE and VTE on dry granulation tissue hydroxyproline (HP), hexuronic acid (HA) and hexosamine (HUA) content in rats. Results are mean \pm SEM of 6 rats in each group. ^b $P < 0.01$ and ^c $P < 0.001$ compared to respective vitamin E (VTE) group (one way analysis of variance followed by Dunnett's test)

IV. DISCUSSION

Streptozotocin is one of the standard substances used for the induction of diabetes mellitus and it has a destructive effect on the beta cells of the pancreas. In our study, significant increase in blood glucose level was observed in alloxan induced diabetic rats. Alloxan cause immense reduction in insulin release by the destruction of beta cells of the islets of langerhans and caused hyperglycemia. The adipose tissue and skeletal muscle are unable to uptake glucose from serum in the absence of insulin so glucose conversion to fat and glycogen is blocked in the adipose tissue and skeletal muscles, resulting in increase of blood glucose level [6]. Cutaneous wound healing involves a complex series of physiological processes that include inflammation, proliferation and migration of different cell types, angiogenesis, matrix synthesis, collagen deposition leading to re-epithelialization, neovascularization and formation of granulation tissues [7]. In the current study, the healing of skin wounds was delayed significantly in diabetic rats, which may be correlated with the elevated glucose levels measured in the blood plasma of these animals. As expected, the diabetic conditions had a deleterious influence on the wound healing process through abnormal physiological response. Significant decrease in the body weight gained by the diabetic animals indicates impaired metabolic activities and may also be due to irregular absorption and elimination of wastes. The hyperglycemic status triggered the animals to become catabolic, breaking down protein and fat stores for energy, as glucose is not accessible to cell nutrition, which had not supported the actual healing process. Involvement of oxidative stress is implicated in the progression of complications of DM, which may also lead to secondary complications such as hepatotoxicity, nephropathy, neuropathy and coronary heart disease [8]. The oral administration of OSE decreased the blood glucose, cholesterol and triglyceride levels significantly after 10 days.

Collagen is the predominant extracellular protein in the granulation tissue of a healing wound and there is a rapid increase in the synthesis of this protein in the wound area soon after an injury. Breakdown of collagen liberates free

hydroxyproline and its peptides. Measurement of this hydroxyproline, therefore, has been used as an index of collagen turnover. The biochemical data of dead space wound study showed an increase in wet tissue weight and protein per g tissue in OSE treated groups. The increased hydroxyproline content in the dead space wounds has indicated faster collagen turnover leading to rapid healing with concurrent increase in the breaking strength of the treated wounds. Hexosamine and hexuronic acid are matrix molecules, which act as ground substratum for the synthesis of new extracellular matrix. The glycosaminoglycans are known to stabilize the collagen fibres by enhancing electrostatic and ionic interactions with it and possibly control their ultimate alignment and characteristic size. Their ability to bind and alter protein-protein interactions has identified them as important determinants of cellular responsiveness in development, homeostasis and disease [9]. In our study, hexuronic acid and hexosamine concentrations which are the component of glycosaminoglycans were significantly increased with BME when compared with control indicating stabilization of collagen fibres.

Experimental and clinical evidences suggest that chronic wound undergoes substantial oxidative stress by neutrophils-derived oxidants and MPO activity, both of which contribute markedly to tissue damage during chronic wound inflammation [10]. Over production of reactive oxygen species (ROS) results in oxidative stress thereby causing cytotoxicity and delayed wound healing and elimination of ROS could be an important strategy in healing of chronic wounds [11]. Therefore, estimation of antioxidants like GSH, SOD and CAT in granulation tissues is relevant because the antioxidants have been reported to hasten wound healing by decreasing the free radicals [12]. Our studies on the antioxidants, free radicals and MPO status revealed that OSE had significant antioxidant activity and reducing MPO and free radicals stress and helped to prevent inflammation and oxidative damage and promote the healing process.

V. CONCLUSION

Thus, in our present study involving dead space wound models in diabetic condition, which included observation of different physical, histological and biochemical parameters, indicated the wound healing activity in the 50% ethanol extract of dried leaves of *Ocimum sanctum*. The healing effects seemed to be due to decreased blood glucose, free radical generated tissue damage, promoting effects on antioxidant status, faster collagen deposition and other connective tissue constituent formation.

REFERENCES

- [1] S.A. Eming, S. Werner, P. Bugnon, C. Wickenhauser, L. Siewe, Utermohlen et al. (2007). Accelerated wound closure in mice deficient for interleukin-10. *Am. J. Pathol.* 170:188–202.
- [2] O.Z. Lerman, R.D. Galiano, M. Armour, J.P. Levine, G.C. Gurtner. (2003). Cellular dysfunction in the diabetic fibroblasts: impairment in migration, vascular endothelial growth factor production, response to hypoxia. *Am. J. Pathol.* 162:303–312.
- [3] P. Prakash, N. Gupta. (2005). Therapeutic uses of *Ocimum sanctum* Linn (tulsi) with a note on eugenol and its pharmacological actions: a short review. *Indian J. Physiol. Pharmacol.* 49:125–131.

- [4] P. Pattanayak, P. Behra, D. Das, S.K. Panda. (2010). *Ocimum sanctum* Linn. A reservoir plant for therapeutic applications: An overview. *Pharmacog. Rev.* 4:95–105.
- [5] S. Murthy, M.K. Gautam, S. Goel, V. Purohit, H. Sharma, R.K. Goel. (2013). Evaluation of *In-Vivo* Wound Healing Activity of *Bacopa monniera* on Different Wound Model in Rats. *Biomed Res Int* 2013. [Available at: <http://dx.doi.org/10.1155/2013/972028>]
- [6] L.P. Turcotte, J.S. Fisher. (2008). Skeletal muscle insulin resistance: Roles of fatty acid metabolism and exercise. *Phys. Ther.* 88:1279–1296.
- [7] Micera, A., Vigneti, E., Pickholtz, D., Rerch, R., Pappo, Q., Bonini, S., Maguart, F.X., Aloc, L., Levi-Schaffer, F. (2001). Nerve growth factor displays stimulatory effects on human skin and lung fibroblasts, demonstrating a direct role for this factor in tissue repair. *Proc. Natl. Acad. Sci. USA* 98:6152–6167.
- [8] X. F. Zhang, B.K. Tan. (2000). Antihyperglycaemic and anti-oxidant properties of *Andrographis paniculata* in normal and diabetic rats. *Clin. Exp. Pharmacol. Physiol.* 27: 358–363.
- [9] J.M. Trowbridge, R.L. Gallo. (2002). Dermatan sulphate - new functions from an old glycosaminoglycan. *Glycobiology* 12:117R–125R.
- [10] H.S. Song, T.W. Park, U.D. Sohn, Y.K. Shin, B.C. Choi, C.J. Kim, S.S. Sim. (2008). The effect of caffeic acid on wound healing in skin-incised mice. *Korean J. Physiol. Pharmacol.* 12:343–347.
- [11] E.V. Mikhalechik, M.V. Anurov, S.M. Titkova, E.A. Miroshnikova, E.V. Lukashova, I.B. Deeva, G.A. Ibragimova, L.G. Korkina. (2006). Activity of antioxidant enzymes in the skin during surgical wounds. *Bul. Exp. Biol. Med.* 142:667–669.
- [12] G. Weindl, M. Schaller, H.C. Korting. (2004). Hyaluronic acid in the treatment and prevention of skin diseases: molecular biological, pharmaceutical and clinical aspects. *Skin Pharmacol. Physiol.* 17:207–213.