

Use of Smartphone in Practical Classes to Facilitate Teaching and Learning of Microscopic Analysis and Interpretation of Tissues Sections

Lise P. Labéjof, Krisnayne S. Ribeiro, Jackson A. Santos, Nicolle P. dos Santos

Abstract—An unrecorded experiment of use of the smartphone as a tool for practical classes of histology is presented in this paper. Behavior and learning of students of science courses at the University were analyzed and compared as well as the mode of teaching of this discipline and the appreciation of the students, using either digital photographs taken by phone or drawings for record microscopic observations, analyze and interpret histological sections of human or animal tissues.

Keywords—Cell phone, digital micrographs, learning of sciences, teaching practices.

I. INTRODUCTION

TODAY we ask many questions about the training of professionals in the biomedical sciences, methods of training, and course content they receive in specialized training centers and universities [1]-[3]. Knowledge and application of scientific research has advanced a lot in recent decades and professionals are still traditionally trained without having the opportunity to use the techniques and tools of our age of technology for their future profession. The mode of teaching biomedical sciences has not changed for almost a century or more for some disciplines such as for courses histology practices [4], [5]. As the subject of study, animal and human tissues, seems to have not changed, we did not feel the necessity to change the way of passing this knowledge to younger generations. But something changed? Yes our tissues had certainly changed because our lifestyles have changed due to our diet, stress of everyday life, the appearance of new diseases and advances in medical treatment. Must we continue to teach this discipline in the manner we have been taught or must we find new methods? Students also have changed because their environment has changed. They are immersed in a world of technologies. In these recent years, some teachers were trying to bring innovations in the way of teaching for practical classes of histology by creating for their students, virtual microscopes, and atlas with virtual slides, quizzes and

interactive animations with a free internet access [6]-[10]. All efforts to integrate new technologies in education are good for the formation of professionals of the future. One of these new technologies that students have constantly at their disposal is the mobile phone.

Since the democratization and expansion of the cell phone to all generations and all strata of society, it is become an everyday and all time companion. This new technology invaded our lives and now it is difficult to think without it. And it is among the younger generation that the phenomenon is more demonstrative and more rooted in their habits. The mobile phone has become an extension of their hands and their thinking. It is genial but because of its constant use, it became the villain [11]. It is hunted everywhere and especially in educational institutions [11], [12]. Why should we ban it in the classroom, a tool that has so many advantages? New cell phones are more than phones. They replace the diary, text book, alarm clock, camera, music player, book, computer, and more if new applications are loaded. Another important benefit is that they are always connected to internet, an infinite source of information. Would not be better to use it as an ally to education for some activities such as taking digital photographs in practical classes?

This paper presents a promising and successful experience of using smartphone by students in order to capture digital images of histological sections observed by light microscopy during practical classes of the discipline of histology. In order to demonstrate the importance of this new teaching tool, this method was compared with the traditional method that uses the drawing to record observations of histological sections.

II. MATERIAL AND METHODS

A. Procedure of Practical Classes

In order to assess the effectiveness of using smart phone for teaching and learning histology, three classes of the undergraduate degree of area of health of the State University of Santa Cruz participated in the experiment during the year of 2014: one in autumn, from the Bachelor of Veterinary Medicine (BVM) and two in winter, from the Bachelor of Science in Nursing (BSN) and the Bachelor of Biomedical Science (BBS). Practical classes with duration of 1:40 hour, was conducted by a professor accompanied by a student monitor. Each theoretical class was divided in two groups of students, forming 6 groups of practical classes for a total of 58 students ($n_1=10$, $n_2=11$, $n_3=12$, $n_4=9$, $n_5=7$, $n_6=9$). Ten

L. Labéjof is with the Universidade Estadual de Santa Cruz, Departamento de Ciências Biológicas, Centro de Microscopia Eletrônica, Ilhéus/Bahia, CEP 45 650-000 Brazil (corresponding author to provide phone: (55) 73-3680-5191; fax: (55) 73-3680-5262; e-mail: llabejof@uesc.br).

K. Ribeiro and N. P. dos Santos Ribeiro are with the Universidade Estadual de Santa Cruz, Departamento de Ciências da Saúde, Nursing Course Ilhéus/Bahia, CEP 45 650-000 Brazil (e-mail: krisnayne@hotmail.com, ny.paiva@live.com)

This work was partially supported by the Brazilian government through CNPq (Conselho Nacional de Desenvolvimento Científico e Tecnológico) and The State University of Santa Cruz (UESC).

practical sessions were included in this study, which were studied the following tissues of the first part of the general course of histology: 1- Epithelial tissue; 2-Exocrine glandular tissue; 3-Endocrine glandular tissue; 4-Connective tissues; 5- Adipose and reticular tissues; 6-Cartilaginous tissues; 7-Bone tissues; 8-Blood cells; 9-Nervous tissues; 10-Muscular tissues. Tissues sections used for practical classes, were part of the collection of permanent slides of the University Laboratories Management (Gerência dos Laboratórios : GERLAB) and were produced from samples of human or animal (murine, canine, equine and avian) organs, processed by routine method of histology and quasi almost stained by hematoxylin and eosin (H/E). At the beginning of the practical session, students were received the plan of the current practice with instructions for their microscopic observations. The professor gave the list of the histological structures to detect and some explanations in order to recall the theoretical lessons using power-point presentation with data show and drawings on the whiteboard. The visualization of these structures was made by student, under light microscopes available in the teaching laboratory (one microscope by pair of students) at magnifications 100, 200 or 400 (the magnification 1000 was used in some cases). The focusing of the histological slides and the search for structures to be studied was performed by the student assisted by the monitor or the professor if necessary. Two types of practical classes, drawings and smartphone classes were done in the same manner and all students received the same lesson plans with the same instructions.




Fig. 1 Conventional practical classes of histology with BBS students using drawings for their reports

The conventional practical classes with drawings made by the students on the observation of the histological slides under a light microscope were assessed with the BBS students. They should compare the observation zones and their analysis to micrographs of the atlas or the books of histology (Fig. 1A). In case of doubt on the identification of structures, the teacher or the monitor helped them find the correct observation areas. They then made drawings of a field of the studied histological section. Their drawings were done using black and colors pencils on a sheet of the practical class plan presented at the beginning of the session, in circles representing the microscope field of view and they should include captions (Fig. 1 B). Their report was to be individual and be developed during the same session and one report was handed over to the teacher at the end of each session. They received their report

duly corrected by the teacher during the practical class of the following week.

Students of BVM and BSN participated in the experience of using the smartphone to record their microscopic observations. They should compare the observation zones and their analysis to micrographs of the same atlas or books of histology than those of BBS students. These areas were then verified by the teacher or monitor before capture of images with the smartphone (Fig. 2). They used their personal mobile phones to take pictures with the viewfinder of the camera of the phone closed to the eyepiece of the microscope after increasing the intensity of the light of the microscope. Digital micrographs were immediately assessed on the screen of the smartphone by students, monitor and professor on the sharpness of the image and the presence of histological structures to observe and include in their report (Figs. 2 A and C). Observation and analysis of tissue sections were performed by alone directly under the microscope and thus the smartphone images were compared with those of the book of histology or atlas and commented on by the group of students (Figs. 2 B and D). During practice classes with smartphone, it was possible to study 5-8 different histological sections per session. The report was to be prepared by each group of two to three students outside of school hours and sent to the teacher by e-mail in a time of one week after the course. Their report was corrected by the teacher at the front desk and was immediately sent to them by email.

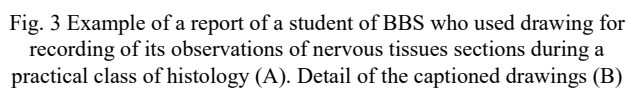


Fig. 2 New practical classes of histology with BSN students using smartphone pictures for their reports

B. Methods of Evaluation of the Practical Classes

Students of all groups were required to submit a report of practical classes that was noted from 0.1 to 1.0 point for a total score of 10 corresponds to the ten practices in this study. In the reports, it was assess students' ability to identify and caption the major histological structures without assessing the quality of the drawing for the drawing groups. And for smartphone groups, the quality of the digital pictures was not taken into account. The knowledge acquired by the students during the ten practical classes was evaluated too by a test which consisted to identify the tissues and organs shown in several micrographs. To determine whether the students

way or another program such as Power-Point for the realization of their report. Most reports were sent to the teacher in the deadlines set at one week. The students participated in the experiment very seriously and during the sessions they were enthusiastic and showed great curiosity and genuine interest to detect and recognize histological structures studied. They had realized different pictures of the same cut at various magnifications in order to find the best representation of the fabric. Early reports showed some clumsiness, but the following ones were improved gradually. At the end of the third report, 90% of them were of excellent quality. The photos have been captioned and completed with some descriptions of the tissue studied. Often a detail of the tissue was shown at higher magnification with some explanation. In these reports it was observed that the students have actually done an effort of accuracy in the description of the images. It was noted that there were a search for additional information plan to the given lesson. It was added some references of documents consulted during their search for information. As with reports of the BBS students they were scored on 1 point for a total of 10 points for the ten reports. There was no significant difference between the scores of the different groups (drawing or smartphone). The distribution of the total scores ranging from 6.0 to 10 points, was similar for the reports of both groups which had an average score of 9 points.



A. Evaluation of the Report of Practice Classes

B. Evaluation of Acquired Knowledge

The students of BSN and BBS (n3, n4, n5 and n6) were subjected to the same test to assess their knowledge during practical classes. The test of a period of ten minutes was to recognize the tissue represented on pictures of histological sections. On one board were grouped, the color micrographs numbered from one to ten, and on another sheet, the answers grid. Each correct answer was worth one mark out of ten for up to ten tissues to identify the name of the organ or tissue with its classification. Fig. 5 shows the average of the marks obtained by the students of the 2 practical classes in each group (n3 and n4 for the BNS group and n5 and n6 for BBS group). Thus it was showed that the average score of BSN students was significantly higher than that of BBS students.

The groups that used the smartphone as a learning tool to practice histology seems to have acquired a better recognition of observed tissues during practical classes than those who used the drawing. In the same group, smartphone or drawing, there is no significant difference between the means of the scores of the two classes.

C. Evaluation of the Students Opinion

224

who participated in the study only 30 of them responded to the evaluation questionnaire.

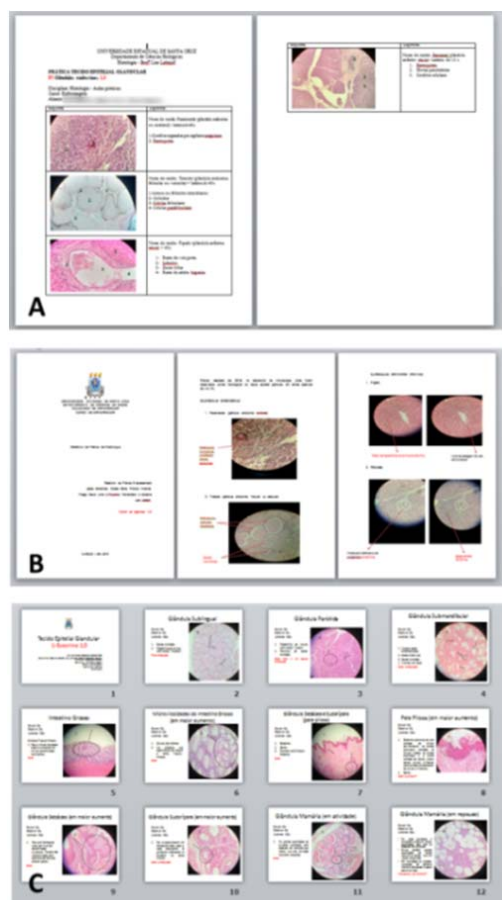

Fig. 4 Some reports of BSN students that used digital images of their smartphone. Professor model of report in Word (A), student's model in Word (B) and in Power-Point (C)

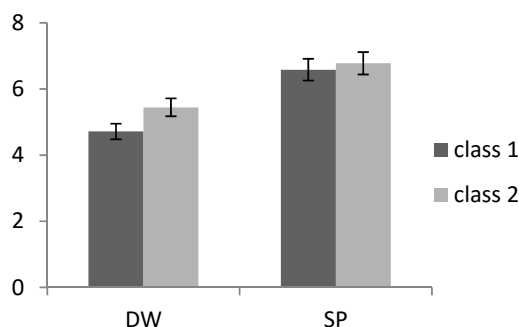


Fig. 5 Average scores obtained in the test of tissue recognition by the students that have used one of the two methods of practical class (DW = students with drawings, SP = students with smartphone). Class 1 corresponds to n3 or n5 and Class 2 to n4 or n6

Among the students of all groups, 85% responded that they had difficulties in practical class of histology, and mainly to recognize the tissue structures. For the question regarding the use of drawing as a means of learning of histological

structures, 60% of BBM students said that drawing histological structures viewed under the microscope helped in understanding and learning of histology. But they have complained about the difficulties they had to make the drawings, especially because of the many details of some histological sections that required a lot of time to copy them.

IV. DISCUSSION

This study aimed to demonstrate how new technology can be used for educational purposes for teaching practical of histology at the university. Interesting results have been highlighted on the benefits of a method for teaching and learning of histology practices. The BBS students have encountered some difficulties during the class due to the long time spent to draw. Thus BBS students were able to analyze fewer histological slides than the BSN students. The students of BBS should hand their report to the teacher at the end of the practical course while students of BSN had a week to send it to him by e-mail. The learning process is better in the second case because to prepare their report, BSN students had to see their photos and notes taken during the course, seek further information from books or the internet to complete the description of the tissues observed during the practical course. They have review tissue to study several times at the time of observation, during comparison with the atlas, when taking pictures and at the time of preparation of the report. Spaced repetition is a very effective learning technique because human memory is not reliable, it is necessary to regularly review what we learned to permanently fix knowledge. Because we know that with each repetition of information, new nerve connections are created in the brain and thus short term memory is converted into long-term memory.



Fig. 6 Adapters of smartphone for taking microscopic pictures, they are commercial (A) or hand-made (B) adapters. They can be fixed on the eyepiece or on the stage of the light microscope

Some students have taken excellent quality photos, and others not. Depending on the type of smartphone it was more or less easy to focus. This problem was solved by the use of a smartphone adapter for light microscope. This is a device which fixes the smartphone on the microscope eyepiece by clips or hooks. It is in metal or plastic with different formats but for a high price. It can be realized by oneself using a smartphone cover and a PVC tube stuck with glue on the cover, whose internal diameter corresponds to the external diameter of the microscope eyepiece (Fig. 6).

The knowledge assessment test showed that BBS students have better recognized the histological structures that students

BSN. The evaluation of the knowledge acquired during the practical classes has failed to make a real comparison between the students of BBS and BSN because their motivation to dedicate to histology is different. Indeed, they do not need the same knowledge; a biomedical scientist needs of this knowledge for his university education and for the exercise of their future profession. But this is not the case for a nurse who needs histology knowledge only for understanding normal and pathological physiology of future patients. So this can explain that BBS students had better results than those of BSN. For this type of evaluation, the method used for the reports of practical classes does not influence student learning.

Histology is a science that employs methods and techniques for studying the normal and pathological microanatomy of biological tissues. Since the advent of histology, the drawing was the best method to save the microscopic observations. Since the discovery of the existence of the cell by Robert Hooke in the 17th century, through the use of the first microscope that he had created by himself, his drawings have revealed to all, a fantastic microscopic world that served basis for the breakthrough of the pathology [13]-[18]. After the publication of his observational works in his handwriting book, illustrated with its drawings of an extreme scientific accuracy, microscopy has progressed rapidly in all directions and associated techniques have been improved. Photography is an important element of scientific work. The first micrograph of a histological slide was made in 1929 [19] and today, a microscopist may have at its disposal a dozen types of microscopes and hundreds of associated techniques to observe, detect, assess and analyze biological phenomenon. The microscopic study of cells and tissues has contributed to the progress of medicine by improving the diagnosis and treatment of disease through knowledge gained by the study of numerous scientific disciplines such as physiology, anatomy, histology, and etc. In our time, it is still necessary to draw pictures to describe a concept not visible under the microscope, but they are done digitally by computer. It is no longer using paper, pencil and eraser as did the "father of microscopy" to describe and disclose an observation. Similarly, at the hospital, a pathologist must analyze and interpret micrographs in order to draft a report that allows the surgeon or the doctors to do a diagnosis and in case of doubt he will review the histological slides. Thus the use of digital micrographs is now very important in the work of professionals of biomedical sciences.

V.CONCLUSIONS

This experiment shown here of using of smartphones for practical class of histology should be applied to others courses of life sciences that require the recording of microscopic images as microbiology, parasitology, hematology, botany, and etc. The use of the smartphone can be a tool that could be applied in their future profession especially for BBS students. In remote areas of a medical center or a specialized analytical laboratory, a biopsy may be prepared and observed with a rudimentary microscope. And digital images of microscopic observations could be sent by the internet in the reference

analyses center for the confirmation of a diagnosis.

ACKNOWLEDGMENT

The authors would like to thank the students from the Bachelor of Veterinary Medicine, Bachelor of Science of Nursing and Bachelor of Biomedical Science and the students monitors whom participated of this work.

REFERENCES

- [1] Robert Alan Bloodgood, "The history of medical histology teaching: where have we come from and where are we going?" *The FASEB Journal*, vol. 27, pp 191-1, 2013.
- [2] J. A. Hightower, F.R. Boockfor, C. A.Blake, and C. F. Millette, *The Standard Medical Microscopic Anatomy Course: Histology Circa 1998, The anatomical record (New Anat.)*, vol. 257, pp. 96–101, 1999.
- [3] S. E. Groh, "The Power of Problem-Based Learning. A practical "how to" for teaching undergraduate courses in any discipline" Paperback – Ed. B. J. Duch, , D. E. Allen, Oct. 2001
- [4] K. D. Tanner, L. Chatman and D. Allen, "Approaches to Biology Teaching and Learning: Science Teaching and Learning Across the School–University Divide—Cultivating Conversations through Scientist–Teacher Partnerships" *Cell Biology Education*, vol. 2, 195–201, Winter 2003.
- [5] N. Salamé. "Contribution de l'informatique au renouvellement des activités expérimentales dans l'enseignement de la biologie et de la géologie", *L'informatique et apprentissages*, p .59-62. 1991, Ed. INRP Paris.
- [6] D. Allen, "Recent Research in Science Teaching and Learning" *CBE—Life Sciences Education*, vol. 10, 132–134, Summer 2011.
- [7] T. L. Rocha, M. L. de Oliveira, J. C. Seraphin, S. M.Teixeira Sabóia-Moraes, "A comparative analysis of practical classes in cellular biology for undergraduate biological sciences students" *Investigações em Ensino de Ciências*, vol. 5(2), pp. 297-309, 2010.
- [8] V. Ndiaye, C. T. Sall, S. Diouf, b. d. Ndiaye, B. Gueye, M. S. Thiaw, "Quels travaux pratiques pour les sciences expérimentales au premier cycle à la faculté des sciences et techniques de l'université Cheikh Anta Diop de Dakar? " *Ecole Normale Supérieure de Dakar – Sénégal*, vol. 3 pp. 203-15, 2007.
- [9] B. Saikia, K. Gupta and U. N. Saikia, "The modern histopathologist: in the changing face of time." *Diagnostic Pathology*, vol.3, pp. 25-8, 2008.
- [10] A. G. Gona, P. B. Berendsen, and E. A. Alger, "New Approach to Teaching Histology" *Medical Science Educator*, vol. 15(2), pp.78-89, 2012.
- [11] M. Soskil, "5 Reasons to Allow Students to Use Cell Phones in Class" A Teacher's Life for Me, <http://theinnovativeeducator.blogspot.fr/>, posted in July, 2012.
- [12] W. M. Ferriter, "Digitally Speaking / Cell Phones as Teaching Tools" *Interventions That Work*, vol. 68 (2), pp. 85-86, Oct. 2010.
- [13] N. Kirkham, "The pathologist in the 21st century—generalist or specialist?" *Journal of Clinical Pathology*, vol. 53, pp. 7-9, 2000.
- [14] R. Kumar, B. Freeman, G. M. Velan, and P. J. de Permentier, "Integrating histology and histopathology teaching in practical classes using virtual slides." *The anatomical record (part b: new anat.)*, vol. 289b, pp. 128 –133, 2006.
- [15] Meyer G. "Reducing the time taken to teach histology". Meyer's Histology. Online learning and teaching resources <http://histology-online.com/>
- [16] Meyer G. "Working less and getting better results from your histology course." Meyer's Histology. Online learning and teaching resources <http://histology-online.com/>
- [17] P. M. Heidger, F. Dee, D. Consoer, T. Leaven, J. Duncan, and C. Kreiter "Integrated Approach to Teaching and Testing in Histology With Real and Virtual Imaging", *The anatomical record (New Anat.)*, vol. 26, pp. 107–112, 2002.
- [18] C. Jason, "The History of Histology: An Interesting Evolution of Teaching and Testing" *Education Reform*, Education Portal, posted in Sept. 2013 (<http://www.aplusillinois.org/category/education-reform/>)
- [19] R. Hooke, "Micrographia, Some physiological descriptions of minute bodies made by magnifying glasses". Ed J. Martyn and J. Allestry, London, 1665 (first edition).