

Preliminary Toxicological Evaluations of Polypeptide-K Isolated from *Momordica Charantia* in Laboratory Rats

M Nazrul-Hakim, A Yaacob, Y Adam, A Zuraini

Abstract—This study examined the toxicological effects and safety of polypeptide k isolated from the seeds of *Momordica charantia* in laboratory rats. 30 male Sprague Dawley rats (12 weeks old, bodyweight 180-200 g) were randomly divided into 3 groups (1000 mg/kg, 500 mg and 0 mg/kg). Rats were acclimatized to laboratory conditions for 7 days and at day 8 rats were dosed orally with polypeptide k (in 2% DMSO/normal saline) and the controls received the dosed vehicle only. Rats were then observed for 72 hours before sacrificed. Rats were anaesthetized by pentobarbital (50 mg/kg ip) and 2-3.0 mL of blood was taken by cardiac puncture and rats were scarified by anaesthetic overdose. Immediately, organs (heart, lungs, liver, kidneys) were weigh and taken for histology. Organ sections were then evaluated by a histopathologist. Serum samples were assayed for liver functions (ALT and γ -GT) and kidney functions (BUN and creatinine). All rats showed normal behavior after the dosing and no statistical changes were observed in all blood parameters and organ weight. Histological examinations revealed normal organ structures. In conclusion, dosing of rats up to 1000 mg/kg did not have any effects on the rat behavior, liver or kidney functions nor histology of the selected organs.

Keywords—Polypeptide k, safety, histology, toxicology, *Momordica charantia*

I. INTRODUCTION

MOMORDICA CHARANTIA (MC) or bitter gourd/bitter melon in English, kerala in Hindi, paharkai in Tamil, pinyin in Chinese and peria in Malay is a climber belonging to family Cucurbitaceae. It is a plant widely cultivated in many tropical and subtropical regions of the world as food and medicinal plant [1], [2]. This plants has been extensively studied for its many medicinal properties which includes antidiabetic, antiviral, antitumor, antileukemic, antibacterial, anthelmintic, antimutagenic, antimycobacterial, antioxidant, antiulcer, anti-inflammatory, hypocholesterolemic, hypotriglyceridemic, hypotensive, immunostimulant, and

insecticidal, contraceptive, antimalarial, eczema, emmenagogue, pneumonia, psoriasis, rheumatism and scabies [3], [4]. MC is most widely studied for its antidiabetic effect and all parts of the plant (fruit, seed, leaves, root and whole plant) have shown hypoglycemic activity [5]-[7]. It was studied in all normal, diabetic induced and genetically mutant laboratory animals. Many biologically active chemicals have been identified from all parts of MC that include alkaloids, fixed oils, glycosides, proteins, saponins, steroids, and triterpenes [4]. Crude extract of MC showed a significant reduction in blood glucose, glycosylated haemoglobin, and an increase in plasma insulin in animals [8], [9] reported antidiabetic activity of MC that was similar to glibenclamide in diabetic rats. Isolated individual phytochemicals have also been tested such as Charantin, Polypeptide-p, momordin Ic, and oleanolic acid 3-O-glucuronide have shown more potent hypoglycemic activity than crude extracts [10], [11]. More recently, polypeptide-k is isolated from seeds of MC with high homology to human insulin and helps in rejuvenating pancreas and activates inactive insulin. It contains 18 standard amino acids in a single molecule and may help in reducing blood glucose level and prevention of diabetes [12]. Although numerous reports on MC various biomedical properties have been published, the toxicity/safety evaluation MC and especially its individual phytochemical is lacking. No large-scale studies have been undertaken to establish the safety of MC or its constituents. One study had revealed relatively low toxicity of all parts of MC in laboratory animals when extracts were ingested but severe hepatotoxicity and some death were observed given in high doses intravenously or intraperitoneally [13]. Therefore, the objective of this current study was to determine the toxicological effects of Polypeptide-k in rats especially towards the liver and kidney functions.

II. MATERIALS AND METHOD

Polypeptide-k (isolated from *Momordica charantia* was generously given by Magna Bio-Laboratories, Malaysia). All other chemicals were of analytical grade from Sigma Chemicals (USA). 30 male Sprague Dawley rats (12-16 weeks old, bodyweight 180-200 g) were randomly divided into 3 groups. Rats were acclimatized to laboratory conditions for 7 days and at day 8 rats were dosed orally with polypeptide k (in 2% DMSO/normal saline at 500 and 1000mg/kg) and the controls received the dosed vehicle only. Rats were then observed for 72 hours before sacrificed. Rats were anaesthetized by pentobarbital (50 mg/kg ip) and 2-3.0 mL of blood was taken by cardiac puncture and rats were scarified by anaesthetic overdose. Immediately, organs (heart, lungs, liver,

Nazrul-Hakim A., is a Professor in the Department of Biomedical Sciences, Faculty of Medicine and Health Sciences and Director of Sports Academy, University Putra Malaysia (phone:603-8947-1133;fax:603 89464278;email:nazrulh@medic.upm.edu.my)

Yaacob, A. is a Research Officer in the Sports Academy, University Putra Malaysia. (e-mail: azhar_y@putra.upm.edu.my).

Adam, Y. is a Research Officer in the Sports Academy, University Putra Malaysia. (e-mail: yunus_a@putra.upm.edu.my).

Zuraini, A. is an Associate Professor in the Department of Biomedical Sciences, Faculty of Medicine and Health Sciences. (email:zuraini@medic.upm.edu.my).

kidneys) were removed, weigh and taken for histology. Serum samples were assayed for liver functions (ALT and γ -GT) and kidney functions (BUN and creatinine). All procedures are approved by the university's animal care and use committee (ACUC). Data were expressed as mean \pm SD. Data were analysed using analysis of variance. When interactions were significant, Duncan multiple post-test was performed. Values of $p < 0.05$ was considered significant.

III. RESULT AND DISCUSSION

After oral dosing of rats with polypeptide-k or dosed vehicles, all rats revealed normal behavior of bright, alert and healthy for the duration of study. After sacrificed, organs were examined macroscopically and all were in good condition. Organ weights for all treatment groups were statistically similar to those of controls (Table 1). All organs which include the heart, lungs, liver and kidneys were statistically similar in weight and this is the first indicator of no adverse reactions induced by drug/chemicals [14].

TABLE I
ORGAN WEIGHT IN POLYPEPTIDE-K DOSED RATS

| | Controls (2% DMSO/Normal Saline) | 500 mg/kg Ppk ¹ | 1000 mg/kg Ppk ¹ |
|----------------------------------|--|-------------------------------|-----------------------------------|
| Liver (g/100g bodyweight) | 4.35 \pm 0.41 | 4.12 \pm 0.29 | 4.42 \pm 0.24 |
| Kidney (g/100g bodyweight) | 6.70 \pm 0.16 | 6.92 \pm 0.50 | 6.59 \pm 0.82 |
| Heart (g/100g bodyweight) | 3.20 \pm 0.17 | 3.15 \pm 0.14 | 3.35 \pm 0.27 |
| Lungs (g/100g bodyweight) | 5.89 \pm 0.21 | 5.71 \pm 0.30 | 5.74 \pm 0.40 |

*Values are mean \pm SD (n=10). ¹ Ppk: Polypeptide -k diluted in 2% DMSO/Normal Saline. All values are not statistically significant ($p > 0.05$) by analysis of variance.

Similar trends were also observed in the blood parameters. All parameters (liver and kidney function enzymes) were statistically similar to those of controls. All parameters were within the normal range for laboratory rats (Figure 1 and 2). These were also observed in the histological examination of liver and kidney sections. Liver sections from both 500 and 1000 mg/kg revealed normal liver (Figure 3) and kidney histology (Figure 4). Only, the 1000 mg/kg had mild congestion in the liver (Figure 3C). The heart and lungs also revealed normal histology (data not shown). We can conclude that oral ingestion of polypeptide-k up to 1000mg/kg did not have any adverse effects on the major organs and bodily functions of laboratory rats.

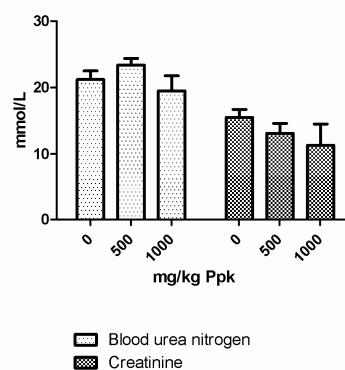


Fig. 1 plasma liver enzyme activity of polypeptide-k treated rats

*Values are mean \pm SD (n=10).

All values are not statistically significant ($p > 0.05$) by analysis of variance.

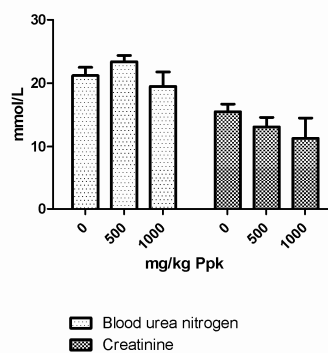


Fig. 2 plasma kidney enzyme activity of polypeptide-k treated rats

*Values are mean \pm SD (n=10).

All values are not statistically significant ($p > 0.05$) by analysis of variance.

Previously, [15] reported significant increase in γ -glutamyltransferase and alkaline phosphatase in animals after oral administration of MC fruit juice and seed extract. But, this increase was not associated with significant histopathologic changes in the liver. In this present study, all liver parameters were normal. The liver toxicity of MC is absent when testing only one constituent of MC seed phytochemical, polypeptide-k. The hepatotoxic constituents of the seeds of MC have been removed by the process of isolation of polypeptide-k or other single constituent of MC as reported by [16].

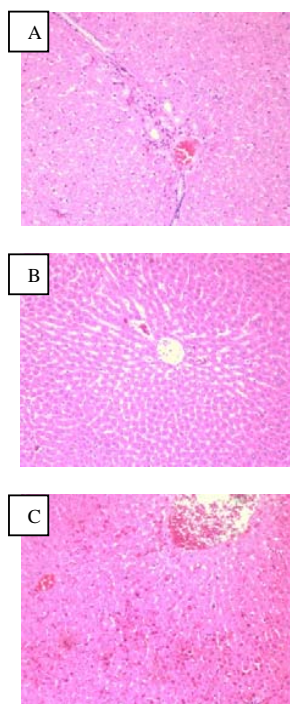


Fig. 3 liver histology of polypeptide-k treated rats

Liver of (A) control rat, (B) 500 mg/kg Ppk dosed rat and (C) 1000 mg/kg Ppk dosed rat revealed normal histology. It is composed of hexagonal lobules with central veins and peripheral hepatic triads. Hepatocytes are arranged in trabeculae running radially from the central vein. All hepatocytes have regular and contain a large spheroidal nucleus with a distinctly marked nucleolus and peripheral chromatin distribution. Only section (C) revealed moderate congestion. H&E, $\times 100$.

In a small clinical trial, a single subcutaneous injection of pure protein (p-insulin) from MC to nine diabetic patients produced reduction blood glucose by 45 % [17]. These were then repeated by [10]. Future clinical and safety work must be performed to further evaluate the efficacy and toxic potential of these purified phytochemicals prior to marketing or prescribing them to diabetic patients.

Interestingly, MC has been proposed as an antiviral and antineoplastic agent [18]. They have isolated a 30-kDa protein from MC seeds, MAP30, which has shown to have some positive results *in vitro*. However, there are no reliable human trials showing efficacy for these indications. Indeed, MC has an endless

list of its biomedical/medicinal properties. All that are missing from these are well structure clinical trials and toxicity evaluations. This current study revealed that polypeptide-k isolated from seeds of MC has no adverse effects when given orally at the dose of up to 1000 mg/kg.

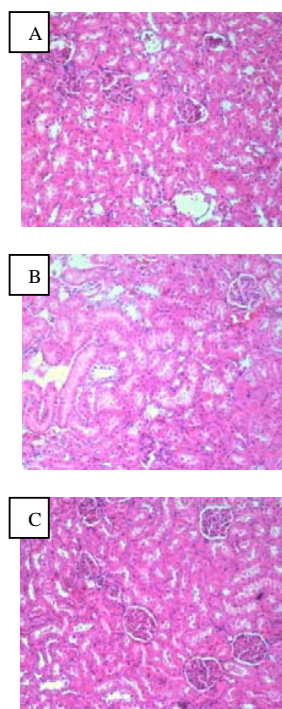


Fig. 4 kidney histology of polypeptide-k treated rats

Kidney (cortical part) of (A) control rat, (B) 500 mg/kg Ppk dosed rat and (C) 1000 mg/kg Ppk dosed rat. Renal glomeruli show normal structure. The renal tubules are lined with typical thick cubic epithelium. Tubules have a relatively regular distinct lumen. H&E, $\times 100$.

ACKNOWLEDGMENT

The authors wish to thank Magna Bio Laboratories and Universiti Putra Malaysia for sponsoring this study.

REFERENCES

- [1] O. Ahmed, I. Adeghate, E., Sharma, A.K., Pallot, D.J., Singh, J., 1998. Effects of Momordica charantia fruit juice on islet morphology in the pancreas of the streptozotocin-diabetic rat. *Diabetes Research Clinical Practices* 40, 145–151.
- [2] Modak, M., Dixit, P., Londhe, J., Ghaskadbi, S., Devasagayam, T. 2007. Indian Herbs and Herbal Drugs Used for the Treatment of Diabetes. *Journal of Clinical Biochemistry & Nutrition* 40: 163-173.
- [3] Basch, E., Gabardi, S., Ulbricht, C., 2003. Bitter melon (*Momordica charantia*): a review of efficacy and safety. *American Journal of Health and Systemic Pharmacology* 65, 356–359.
- [4] Grover, J.K., Yadav, S.P. 2004. Pharmacological actions and potential uses of *Momordica Charantia*: A Review. *Journal of Ethnopharmacology* 93: 123-124.
- [5] Akhtar, M.S., 1982. Trial of *Momordica charantia* Linn (karela) powder in patients with maturity-onset diabetes. *Journal of Pakistan Med Association* 32, 106–107.
- [6] Jayasooriya, A.P., Sakono, M., Yukizaki, C., Kawano, M., Yamamoto, K., Fukuda, N., 2000. Effects of *Momordica charantia* powder on serum glucose levels and various lipid parameters in rats fed with cholesterol free and cholesterol-enriched diets. *Journal of Ethnopharmacology* 72, 331–336.
- [7] Grover, J.K., Vats, V., Rathi, S.S., Dawar, R., 2001. Traditional Indian antidiabetic plants attenuate progression of renal damage in streptozotocin induced diabetic mice. *Journal of Ethnopharmacology* 76, 233–238.
- [8] Pari, L., Ramakrishnan, R., Venkateswaran, S., 2001. Antihyperglycaemic effect of Diamed, a herbal formulation, in

- experimental diabetes in rats. *Journal of Pharmacy Pharmacology* 53, 1139–1143.
- [9] Virdi, J., Sivakami, S., Shahani, S., Suthar, A.C., Banavalikar, M.M., Biyani, M.K., 2003. Antihyperglycemic effects of three extracts from *Momordica charantia*. *Journal of Ethnopharmacology* 88, 107–111.
- [10] Khanna, P., Jain, S.C., Panagariya, A. 1981. Hypoglycemic activity of polypeptide-p from a plant source. *Journal of Natural Products* 44: 648–655.
- [11] Matsuda, H., Li, Y., Murakami, T., Matsumura, N., Yamahara, J., Yoshikawa, M., 1998. Antidiabetic principles of natural medicines. Part III. Structure-related inhibitory activity and action mode of oleanolic acid glycosides on hypoglycemic activity. *Chemical and Pharmaceutical Bulletin (Tokyo)* 46, 1399–1403.
- [12] Kanna, P. 2004. Protein/polypeptide-k obtained from *Momordica charantia*. United States Patent 6831162.
- [13] Kusamran, W.R., Ratanavila, A., Tepsuwan, A., 1998. Effects of neem flowers, Thai and Chinese bitter gourd fruits and sweet basil leaves on hepatic monooxygenases and glutathione S-transferase activities, and in vitro metabolic activation of chemical carcinogens in rats. *Food and Chemical Toxicology* 36, 475–484.
- [14] Somchit, N., Norshahida, A. R., Hasiah, A. H., Zuraini, A., Sulaiman, M. R., Noordin, M. M., Hepatotoxicity induced by antifungal drugs itraconazole and fluconazole in rats: a comparative in vivo study, *Human and Experimental Toxicology*, vol. 23, no. 11, pp. 519–525, 2004.
- [15] Tennekoon KH, Jeevathayaparan S, Angunawala P et al. Effect of *Momordica charantia* on key hepatic enzymes. *J Ethnopharmacol.* 1994; 44:93-7.
- [16] Yuan, X., Gu, X., Tang, J. 2008. Purification and characterisation of a hypoglycemic peptide from *Momordica Charantia* L. Var. abbreviate Ser. *Food Chemistry* 111: 415–420.
- [17] Baldwa, V.S., Goyal, R.K., Bhandari, C.M., Pangariya, A., 1976. A clinical trial of insulin obtained from the vegetable source (plant insulin) in patients with diabetes mellitus. *Rajasthan Medical Journal* 16, 54.
- [18] Lee-Huang, S., Huang, P.L., Chen, H.C., Huang, P.L., Bourinbaiar, A., Huang, H.I., Kung, H.F., 1995a. Anti-HIV and anti-tumor activities of recombinant MAP30 from bitter melon. *Gene* 61, 151–156.