

Intraoperative ICG-NIR Fluorescence Angiography Visualization of Intestinal Perfusion in Primary Pull-Through for Hirschsprung Disease

Mohammad Emran, Colton Wayne*, Shannon M Koehler, P. Stephen Almond, Haroon Patel

Abstract—Purpose: Assessment of anastomotic perfusion in Hirschsprung disease using Indocyanine Green (ICG)-near-infrared (NIR) fluorescence angiography. Introduction: Anastomotic stricture and leak are well-known complications of Hirschsprung pull-through procedures. Complications are due to tension, infection, and/or poor perfusion. While a surgeon can visually determine and control the amount of tension and contamination, assessment of perfusion is subject to surgeon determination. Intraoperative use of ICG-NIR enhances this decision-making process by illustrating perfusion intensity and adequacy in the pulled-through bowel segment. This technique, proven to reduce anastomotic stricture and leak in adults, has not been studied in children to our knowledge. ICG, an FDA approved, nontoxic, non-immunogenic, intravascular (IV) dye, has been used in adults and children for over 60 years, with few side effects. ICG-NIR was used in this report to demonstrate the adequacy of perfusion during transanal pullthrough for Hirschsprung's disease. Method: 8 patients with Hirschsprung disease were evaluated with ICG-NIR technology. Levels of affected area ranged from sigmoid to total colonic Hirschsprung disease. After leveling, but prior to anastomosis, ICG was administered at 1.25 mg (< 2 mg/kg) and perfusion visualized using an NIR camera, before and during anastomosis. Video and photo imaging was performed and perfusion of the bowel was compared to surrounding tissues. This showed the degree of perfusion and demarcation of perfused and non-perfused bowel. The anastomosis was completed uneventfully and the patients all did well. Results: There were no complications of stricture or leak. 5 of 8 patients (62.5%) had modification of the plan based on ICG-NIR imaging. Conclusion: Technologies that enhance surgeons' ability to visualize bowel perfusion prior to anastomosis in Hirschsprung's patients may help reduce post-operative complications. Further studies are needed to assess the potential benefits.

Keywords—Colonic anastomosis, fluorescence angiography, Hirschsprung disease, pediatric surgery, SPY, ICG, NIR

I. INTRODUCTION

WHILE there are numerous surgical techniques to treat Hirschsprung disease, all involve defining the area of agangliosis, dividing the mesentery to that segment, mobilizing the remaining ganglionic bowel to reach the perineum, and performing an anastomosis. Each part of these procedures is critical and problems with them can detrimentally impact the outcome. For example, pulling

potentially dilated bowel through the anal sphincter can lead to ischemia. Mobilization of the bowel can further compromise blood flow. Conversely, inadequate mobilization can lead to tension on the anastomosis. Thus, operative modalities for Hirschsprung disease have undergone many modifications to decrease the incidence of stricture and leak complications and ultimately improve outcomes. While the complications of stricture and leak in Hirschsprung's operations are infrequent, they do remain two of the most common complications of pull-through procedures [1]-[5]. The postoperative stricture rate has been reported as 8.6%, although reports suggest that the Duhamel procedure has lower rates [6].

With evident stricture rate requiring intervention this high, there is a need to identify those with perfusion issues that can be addressed intraoperatively to reduce this. Furthermore, currently, there is debate regarding the need for postoperative anal dilation in Hirschsprung coloanal pull-through procedures and its efficacy in preventing long-term stricture. Dilation does not completely reduce the risk of stricture; therefore, operative technique and microperfusion of the anastomotic segment are potential sources of stricture risk [2], [3], [5], [7]. Finding ways to improve technique of preserving local perfusion can eliminate the need for this invasive and frequently painful postoperative management technique in patients who required additional treatment options or procedures for stricture.

The level of anastomosis in colonic surgery has been identified as one of the main risk factors predicting leak or other complications [8]. Anastomotic level closer than 6 cm from the anal verge is one of these predictive factors. Since our population of Hirschsprung patients all have anastomoses within this higher risk zone, they are all in a higher risk group for complications. Visualizing anastomotic perfusion during coloanal pull-through procedures can potentially decrease the risk of these complications and therefore improve long-term patient outcomes.

The surgeon's ability to visually discern viability of a gastrointestinal segment during anastomosis in adults and children has historically been challenging [1]-[3], [9], [10]. It is at best subjective with inherent variability between surgeons [1]-[3], [9]-[12]. Visual assessments of perfusion are influenced by the current hemodynamic status of the patient, temperature and lighting, and can vary by a surgeon's experience and skill [2], [4], [5], [12].

Other modalities have been employed to assess vascularity intraoperatively. Some of these modalities include Doppler

Mohammad Emran*, Shannon M Koehler, Stephen Almond, and Haroon Patel are with the Driscoll Children's Hospital Dept of Pediatric Surgery - Corpus Christi, TX, United States (*Corresponding author, phone: 361-694-4700; e-mail: mohammad.emran@dchstx.org).

Colton Wayne is with the UT Rio Grande Valley School of Medicine - Edinburg, TX.

and Wood's lamp with fluorescein dye [13].

An objective way to determine perfusion employs real-time injection of a contrast material allowing distinct visualization of the vascularity at the bowel segment's terminus. Thus, the surgeon can clearly delineate bowel perfusion status and determine an ideal site of anastomosis or determine the need for additional bowel resection.

In 1959, the FDA approved the use of ICG dye in surgical procedures; ICG is a water-soluble chemical compound with a half-life of only 3-5 minutes [2], [7]. It is a nontoxic, nonimmunogenic dye administered intravenously that has been used for more than 60 years in both adults and children with few reported adverse effects [9], [12]. The dye is metabolized by the liver, thus it is not contraindicated in patients with renal disease. It can be dosed once or multiple times during an operation as indicated, due to the relatively quick metabolism of the compound. The dye is administered intravascularly by the anesthesiologist, and NIR imaging is performed with either an external or laparoscopic camera to demonstrate fluorescence. Systems are also available for use to perform NIR imaging during robotic-assisted laparoscopic procedures. Since there is no radioactive labelling, no toxicity and rapid ease of administration, there is little preparation and low barriers to use of the technology. This imaging method has been introduced in adult colorectal surgery to address poor visual accuracy of tissue perfusion and assess anastomotic viability. The process is known as ICG NIR fluorescence angiography, or ICG-NIR (also referred to as ICG-FA, fluorescence angiography) [2]. Using this technique, perfusion of bowel segments can be examined prior to anastomosis to determine site(s) of resection, as well as the safety and efficacy of proceeding with connection at a site selected by the operating surgeon. In a study by Ris et al., ICG-NIR imaging demonstrated a reduction in the anastomotic leak rate of the patient population from 5.8% to 2.6%. Use of ICG-NIR intraoperatively has changed surgical decision making in 5.8-28% of cases [11]. In another report, leak rates were reduced from 3.7 to 0.8% demonstrating a dramatic improvement in morbidity [14]. ICG-NIR reduces the incidence of colonic and colorectal anastomotic stricture and leak in adults [1], [3], [7], [9], [11], [14] potentially improving patient outcomes related to these common complications in colorectal surgery. However, the efficacy, feasibility, and ease of use of this technology have not been studied in children to our knowledge.

In this study, a SPY-Elite or SPY-PHI camera (Stryker) was used for in-situ imaging and to capture tissue perfusion via photo and video imaging. Measurement of relative perfusion concentration to surrounding normal tissues is also possible [2], [4], [9], [12], and area under the curve measurements can be taken for further perfusion analysis of the tissue(s) under investigation.

II. METHODS

This article is a single-center observational report on the efficacy and feasibility of using ICG-NIR to assess adequacy of tissue perfusion and viability during anastomosis in

Hirschsprung disease coloanal pullthrough procedures.

Between September 2016 and September 2019, eight patients with Hirschsprung disease underwent transanal, open or laparoscopically-assisted Hirschsprung transanal endorectal pullthrough procedures after biopsy confirmation of aganglionosis. Two of our patients had undergone previous abdominal surgery for neonatal emergencies likely related to Hirschsprung disease and required laparotomy for adhesiolysis to adequately mobilize the bowel. Only these two patients had colostomies prior to their definitive pullthrough procedure, again related to their initial abdominal emergency.

Patients were brought to the operating room and placed in lithotomy position after administration of general anesthesia. The rectum was irrigated with saline until clear on visual inspection and a betadine impregnated gauze was introduced into the rectum to reduce fecal spillage. A mucosal incision was made 1 cm above the dentate line and submucosal dissection was carried 1 cm proximally until full thickness dissection was continued to mobilize the entire affected segment.

In patients without clear evidence of a transition point on prior contrast enema, multiple seromuscular biopsies were performed laparoscopically, at the beginning of the procedure, around the entire colon to determine the extent of disease. Patients with contrast enema images suggestive of distal segment disease had start of dissection immediately. Dissection was continued until biopsy confirmation of circumferential presence of ganglion cells and determination that the ganglionic segment would reach the perineum. Once the normally innervated bowel was pulled through, each patient had interrogation of the pullthrough segment perfusion with ICG-NIR prior to anal anastomosis.

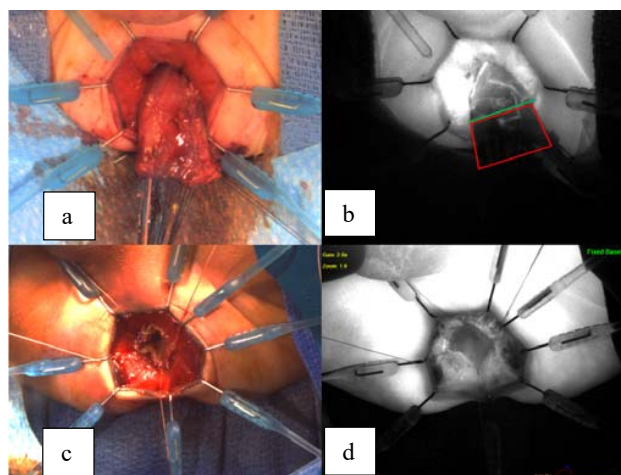


Fig. 1 (a) Pulled-through colonic segment after leveling biopsies under white light. (b) same patient with ICG-NIR demonstrating lack of perfusion to distal segment (outlined in red) and line of transection (green line). (c) after leveling biopsies and just prior to anastomosis on second patient under white light. (d) second patient with ICG-NIR demonstrating mucosal perfusion and perfusion at the cut edge of the muscle

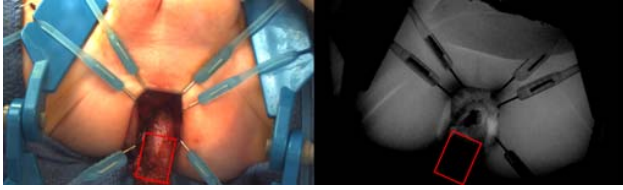


Fig. 2 Visual versus ICG-NIR assessment of perfusion of pullthrough segment. Of note, perfusion is approximately 2 cm above the last site of biopsy. No difference of color could be seen with the naked eye

ICG was injected intravascularly and real-time imaging with the SPY-Elite or SPY-PHI camera (Stryker) was performed. After leveling of the ganglia and prior to anastomosis, ICG was administered by the anesthesiologist at a dose of 1.25 mg (< 2 mg/kg) and NIR camera was used to view the bowel segment in-situ to visualize the local perfusion before and after anastomosis (Figs. 1, 2). Areas of perfusion were brightly lit as white, blue, or green depending on the modality used, while ischemic areas were black. Areas with decreased perfusion may have varying degrees of contrast intensity that can be assessed by comparison to surrounding undissected tissues with normal perfusion.

Ischemic or poorly perfused segments were resected further back proximally using cautery until reaching viable, well-vascularized tissue. Perfusion before and after anastomosis was evaluated using ICG-NIR to examine the tissue for any discernible effects of the anastomosis on local perfusion. Anastomosis was created using full thickness single layer absorbable braided polyglactin suture (Vicryl, Ethicon Inc.) and visually inspected for possible leaks or stricture sites prior to the replacing of the pulled-through segment.

III. RESULTS

Video and photo imaging were performed during fluorescence angiography, and perfusion of the bowel segments involved in the anastomosis site was compared to surrounding tissues. In five out of the eight patients (62.5%), the level of intended bowel transection was modified based on the ICG-NIR result. In the other three patients (37.5%), an acceptable quality of perfusion was confirmed at the level of the transected bowel and correlated with the surgeon's visual assessment. Interrupted absorbable suture was used to create the anastomosis in all patients. No impact on perfusion was seen, both on gross inspection and ICG-NIR investigation, due to anastomosis. Postoperative hospital courses were uneventful in all eight patients with no immediate complications.

Patients were discharged on average between 3 and 5 days postoperatively once the following conditions were met: bowel function returned, the patient tolerated diet well, and urinary catheter was removed. All eight patients included in the study were seen as outpatients in clinic at two weeks after discharge, at one month and then three months and followed annually thereafter. No leak or strictures were identified in any of the patients by their three month follow up visit. No incontinence was seen. Two of the eight patients had perineal

excoriation treated with topical perineal zinc ointment and antifungal powder. One of these resolved within ten days of treatment; however, the other continued with the excoriation for a longer period and developed pseudoverrucous dermatitis for several months related to his total colonic disease and ileoanal anastomosis. This patient, with the severe excoriation of the perineal skin, had leakage of small amounts of mucus and liquid stool between bowel movements. Continence has not yet been determined due to the ongoing inflammation of the skin and anal canal.

IV. DISCUSSION

The visual assessment of bowel viability in patients with Hirschsprung disease prior to anastomosis is subjective and a potential source of post-operative complications such as bowel stricture and leak at site of colonic anastomosis [1]-[5]. Use of technologies that image vascular irrigation prior to anastomosis may help reduce these complications. In this study, ICG-NIR influenced the surgeon's assessment of the site of transection in five out of eight patients (62.5%), and likely decreased or prevented ischemia-associated complications and excessive transection of viable tissue. The positive procedural outcomes in our study population suggests that a majority of patients may benefit from use of this technology, although sample size was small.

Employment of a new technology in medicine, and especially in surgery, has to have a significant benefit to patients while also providing ease of use for the operator. For procedures where vascular perfusion status was of interest, learning to use the ICG-NIR imaging in our institution was very quick. Training on the digital recording and file storage system, as well as the NIR camera itself, was reportedly easy and efficient, and it took very little time for our surgeons to feel comfortable incorporating this technology into their everyday practice. Combined with no complications and the benefits in colonic surgery, this ease of use and quick learning curve reduces the barriers for potential adoption of the technology. The technology has been used for numerous visceral and soft tissue indications with clear benefits in some areas while not yet demonstrating the expected benefits in others.

Other surgical fields, outside of colorectal surgery, where ICG-NIR has been used for vascular perfusion assessment include breast surgery, cardiac surgery, neurosurgery, plastic and reconstructive surgery, and even podiatric surgery [15]-[19]. Further study is required to elucidate the areas where these benefits are significant enough for routine use. In our institution, we have used it in bowel surgery, urologic surgery, conjoined twin separation, plastic surgery, esophageal surgery and trauma. It was also used in cases of necrotizing fasciitis to demarcate debridement lines.

Economically, the technology has to be cost effective for institutional employment, especially for routine use. An estimated 2.8-8.4% of colonic surgeries are at risk for anastomotic complications resulting in up to seven to ten additional days of admission per patient and additional costs of greater than \$24,000 and upwards of \$50,000 per leak or

stricture [14], [20], [21]. With reports of Hirschsprung surgical complication rate greater than 8%, these costs for the patient, the family and the health care system may be just as high or higher. Most ICG-NIR cameras now come in high-definition and cost ranges from \$40,000-250,000 depending on manufacturer, hospital contract and features available. They are also available for both open and laparoscopic versions. The ICG kits cost approximately \$125 and usually include the contrast, diluent and drape for the camera. The reduction in leak rates and strictures means the cost savings may be greater than \$1200 per patient, meaning, the technology pays for itself within 40 to 200 patients making it not only useful for reducing patient morbidity but also a means of reducing care costs [14].

The capability of some NIR cameras to do relative perfusion measurements (area under the perfusion intensity curve) can be used to enhance accuracy of assessment of bowel vascularity. This is especially useful in the settings of extensive mobilization, lysis of adhesions, or in redo surgery. It also becomes a very valuable tool when bowel length is at issue and when there is questionable or partially compromised bowel. It is currently unknown if ischemic appearance on ICG-NIR imaging correlates to worse outcomes in the pediatric population. Our findings, while encouraging and suggestive, are not definitive. Larger, long-term studies are necessary to further understand the efficacy of using ICG-NIR in pediatric colorectal surgery and other areas. ICG-NIR may turn out to be the next step to significantly reducing the morbidity associated with these complex pediatric surgical procedures.

REFERENCES

- [1] Gröne J, Koch D, Kreis ME. "Impact of intraoperative microperfusion assessment with pinpoint perfusion imaging on surgical management of laparoscopic low rectal and anorectal anastomoses". *Colorectal Dis*. 2015 Oct; 17 Suppl 3:22-8.
- [2] Mangano A, Gheza F, Chen LL, Minerva EM, Giulianotti PC. "Indocyanine green (Icg)-enhanced fluorescence for intraoperative assessment of bowel microperfusion during laparoscopic and robotic colorectal surgery: The quest for evidence-based results". *Surgical Technology International*. 2018 Jun 1;32:101-104.
- [3] Jafari MD, Wexner SD, Martz JE, et al. "Perfusion assessment in laparoscopic left-sided/anterior resection (PILLAR II): A multi-institutional study". *Journal of the American College of Surgeons*. 2015;220(1). doi:10.1016/j.jamcollsurg.2014.09.015.
- [4] Degett TH, Andersen HS, Gögenur I. "Indocyanine green fluorescence angiography for intraoperative assessment of gastrointestinal anastomotic perfusion: a systematic review of clinical trials". *Langenbecks Archives of Surgery*. 2016;401(6):767-775.
- [5] Boni L, David G, Dionigi G, Rauser S, Cassinotti E, Fingerhut A. "Indocyanine green-enhanced fluorescence to assess bowel perfusion during laparoscopic colorectal resection". *Surgical Endoscopy*. 2015;30(7):2736-2742.
- [6] Tannuri AC, Tannuri U, Romão RL. Transanal endorectal pull-through in children with Hirschsprung's disease-technical refinements and comparison of results with the Duhamel procedure. *Journal of Pediatric Surgery*. 2009 Apr;44(4):767-72.
- [7] Cassinotti E, Costa S, DE Pascale S, Oreggia B, Palazzini G, Boni L. "How to reduce surgical complications in rectal cancer surgery using fluorescence techniques". *Minerva Chirurgica*. 2018 Apr;73(2):210-216.
- [8] Tsai YY, Chen WTL. "Management of anastomotic leakage after rectal surgery: a review article". *Journal of Gastrointestinal Oncology*. 2019 Dec; 10(6):1229-1237.
- [9] Foppa C, Denoya PI, Tarta C, Bergamaschi R. "Indocyanine green fluorescent dye during bowel surgery: Are the blood supply "guessing days" over?" *Techniques in Coloproctology*. 2014;18(8):753-758. doi:10.1007/s10151-014-1130-3.
- [10] Kin C, Vo H, Welton L, Welton M. "Equivocal effect of intraoperative fluorescence angiography on colorectal anastomotic leaks". *Diseases of the Colon & Rectum*. 2015;58(6):582-587. doi:10.1097/dcr.0000000000000320.
- [11] Ris F, Liot E, Buchs NC, Kraus R, Ismael G, Belfontali V, Douissard J, Cunningham C, Lindsey I, Guy R, Jones O, George B, Morel P, Mortensen NJ, Hompes R, Cahill RA; "Near-infrared anastomotic perfusion assessment network VOIR. Multicentre phase II trial of near-infrared imaging in elective colorectal surgery". *British Journal of Surgery*. 2018 Sep;105(10):1359-1367.
- [12] Mangano A, Masrur MA, Bustos R, Chen LL, Fernandez E, Giulianotti PC. "Near-infrared indocyanine green-enhanced fluorescence and minimally invasive colorectal surgery: Review of literature". *Surgical Technology International*. 2018 Nov 11;33:77-83.
- [13] Urbanavičius L, Pattyn P, Van de Putte D, Venskutonis D. "How to assess intestinal viability during surgery: A review of techniques". *World Journal of Gastrointestinal Surgery*. 2011 May; 3(5):59-69.
- [14] Starker PM, Chinn B. "Using outcomes data to justify instituting new technology: a single institution's experience". *Surgical Endoscopy*. 2018; 32(3):1586-1592.
- [15] Chatterjee A, Krishnan N, Vliet M, Powell S, Rosen J, Ridgway E. "A Comparison of Free Autologous Breast Reconstruction with and without the Use of Laser-Assisted Indocyanine Green Angiography: A Cost-Effectiveness Analysis". *Journal of Plastic and Reconstructive Surgery*. 2013 May; 131(5):693e-701e.
- [16] Moyer H, Losken A. "Predicting Mastectomy Skin Flap Necrosis with indocyanine Green Angiography: The Gray Area Defined". *Journal of Plastic and Reconstructive Surgery*. 2012 May; 129(5):1043-1048.
- [17] Schade, Valerie L., et al. (2015). "How Fluorescence Angiography Illuminates the Potential for Limb Salvage". *Podiatry Today*, Volume 28 Issue 9.
- [18] Snyder, Mark (2016). "How Fluorescence Angiography Can Clarify Treatment Options for Patients with PAD". *Podiatry Today*.
- [19] Christensen, Joani M., et al. (2012). "Indocyanine Green Near-Infrared Laser Angiography Predicts Timing for the Division of a Forehead Flap". *Journal of Plastic Surgery*. Volume 12.
- [20] Park JS, Huh JW, Park YA, Cho YB, Yun SH, Kim HC, Lee WY. "Risk Factors of Anastomotic Leakage and Long-Term Survival after Colorectal Surgery". *Medicine (Baltimore)*. 2016 Feb; 95(8):e2890.
- [21] Hammond J, Lim S, Wan Y, Gao X, Patkar A. "The Burden of Gastrointestinal Anastomotic Leaks: an Evaluation of Clinical and Economic Outcomes". *Journal of Gastrointestinal Surgery*. 2014; 18(6):1176-1185.