

Incidence, Occurrence, Classification and Outcome of Small Animal Fractures: A Retrospective Study (2005-2010)

L. M. Ben Ali

Abstract—A retrospective study was undertaken to record the occurrence and pattern of fractures in small animals (dogs and cats) from year 2005 to 2010. A total of 650 cases were presented in small animal surgery unit out of which of 116 (dogs and cats) were presented with history of fractures of different bones. A total of 17.8% (116/650) cases were of fractures which constituted dogs 67% while cats were 23%. The majority of animals were intact. Trauma in the form of road side accident was the principal cause of fractures in dogs whereas as in cats it was fall from height. The ages of the fractured dog ranged from 4 months to 12 years whereas in cat it was from 4 weeks to 10 years. The femoral fractures represented 37.5% and 25% respectively in dogs and cats. Diaphysis, distal metaphyseal and supracondylar fractures were the most affected sites in dog and cats. Tibial fracture in dogs and cats represented 21.5% and 10% while humoral fractures were 7.9% and 14% in dogs and cats respectively. Humoral condylar fractures were most commonly seen in puppies aged 4 to 6 months. Fractured radius-ulna incidence was 19% and 14% in dogs and cats respectively. Other fractures recorded were of lumbar vertebrae, mandible and metacarpals etc. The management comprised of external and internal fixation in both the species. The most common internal fixation technique employed was Intramedullary fixation in long followed by other methods like stack or cross pinning, wiring etc as per findings in the cases. The cast bandage was used majorly as mean for external coaptation. The paper discusses the outcome of the case as per the technique employed.

Keywords—Animal, Fracture, Incidence, Occurrence.

I. INTRODUCTION

NOWADAYS, with the relative increase in pet animals ownership, bone fractures constitute a major problem among dogs and cats [1], [2]. Classification of bone fractures were reported elsewhere [2], [3], [4], [5], [6], [7], [8]. The most common type of fractured long bone in dogs and cats was the femur and tibia representing 45% (128/282) 26% respectively [9]. Fractures involving the distal femoral physis were common among puppies and kittens 4 to 11 months of age [10]. He added that, physeal fractures in both dogs and cats were representing 37% and 25% respectively. On the other hand, the same author mentioned that, the most common types of fractures in cats were femoral (diaphyseal 30% and condylar 25%) and pelvic types. The most common breeds of cats affected by bone disorders were Siamese, Egyptian Mau and Short-hair [11]. They estimated bone disorders in adult cats (between 1-3 years old) by 14% among other surgical

affections. They added that the causes of traumatic fractures in cats were falling from heights, road traffic accidents and cat bites.

Bone fractures in dogs and cats are amenable to a variety of surgical and nonsurgical intervention options. Numerous options ranging from external to internal fixation, casting, cage (box) rest and limb amputation are available for choice. The selection of appropriate treatment is based on the type of fracture, available materials and directives of the client [2], [3], [4], [12], [13]. Severe spiral fracture in left humerus of German shepherd bitch was treated by three full threaded bone screws and one lag – screw [14].

Intramedullary Stienmann pin was inserted successfully retrograde for treatment of transverse fracture at the distal left radius and ulna in a female seven month old Miniature poodle dog. Diaphyseal fracture of the radius and ulna was occur in a 3 years old 10.5 kg dog. Intact dog was treated successfully by using Lizarov fixator [15]. Fractures of the distal extremity of the radius and ulna of dogs were treated by external

TABLE I
THE DIFFERENT SURGICAL APPROACHES ADOPTED IN DOGS

Fractured bone	Types of external fixation			Types of internal fixation		
	Box rest	Adhesive bandage	Gypsona	Stack pin	Cross pin	Cerclage wire and pin
Pelvic bone	6	-	-	-	-	-
Femur	-	-	-	2	11	20
Tibia	-	-	2	-	6	11
Humerus	-	-	-	-	2	5
Radius and Ulna	-	4	8	-	2	3
Metacarpals	-	-	3	-	-	-
Vertebral column	3	-	-	-	-	-
Total	9	4	13	2	21	39

coaptation or surgical stabilization using plates and external fixator [9]. Cortical and cancellus bone grafts were used for repair of a comminuted femoral fracture in an eighteen month old neutered male domestic short-hair cat [16]. Fractures involving the distal extremities of the femur in dogs were treated by placement cross pins [10], [17]. Fractures of the supracondylar region of the femur in the adult dogs are frequently comminuted. They were treated by using AO/ASIF reconstruction plate [18]. A subgingival fracture of the left maxillary intermediate incisor and a chip fracture in the left mandible of a 6 month old 27 kg spayed German shepherd

L. M. Ben Ali is with the Department of Surgery and Obstetrics, Faculty of Veterinary Medicine, Tripoli University, 13662 Tripoli, Libya (e-mail: hizer84@yahoo.com).

were treated successfully by 22 gauge wire looped around the mandible [19].

The aim of the present work is to throw light on the incidence of different types of fractures among pet animals in Tripoli-Libya, with evaluation of the treatment and postoperative care.

TABLE II
THE DIFFERENT SURGICAL APPROACHES ADOPTED IN CATS

Fractured bone	Types of external fixation		Types of internal fixation		
	Cage rest	Adhesive bandage	Gypsona	Cross pin	Steinmann pin and Cerclage wires
Pelvic bone	6				
Femur				2	5
Tibia			1	2	10
Humerus				2	2
Radius and Ulna	1		3		
Vertebral column					
Mandible	1				3 Cerclage wires
Total	7	1	4	6	20

II. MATERIALS AND METHODS

This study was conducted on 116 fractured dogs and cats of different ages, breeds, sexes and weights admitted to the Surgery Department, Faculty of Veterinary Medicine, Tripoli University, Tripoli, Libya.

TABLE III
THE DIFFERENT BREEDS OF THE PRESENTED FRACTURED DOGS

Breed	Number of fractured dogs
German shepherd	17
Wolf	15
Mongrels	14
Small toys	9
Cocker Spaniel	8
Poodle	8
Miniature cross breed	7
Spaniels	5
Rottweiler	5
Total	88

Each animal was subjected to thorough orthopedic examination as reported by [3], [20], and [21] including anamnesis, clinical observations, and radiological examinations. Radiographs were taken on lateral and craniocaudal position. The anesthetic protocol included 0.02 mg/Kg atropine sulphate, Xylazine (Xylaway 2%; vetway Ltd, York, UK) 1 mg/Kg IM or 0.5 mg/Kg IV as preanesthetic and Ketamine HCl 10% 5 mg/Kg IV according to [22].

The used surgical techniques in dogs and cats comprised external coaptation and internal fixation included intramedullary bone pinning, stack pins and cerclage wire (Table I and II) as described by [2], [3], [23], [24], [25], [26].

Prophylactic course of antibiotic (Betasporina 1 gm (Ceftriaxona/ceftriaxone) were given 30 minutes before surgery and continued every 12 hours for 4 successive days intravenously in dogs and intramuscularly in cats. Clinical and radiographic assessments were performed for 4 months postoperatively.

TABLE IV
THE DIFFERENT FORMS OF TRAUMAS RESULTING FRACTURES IN DOGS AND CATS

Species	Falling from height	Road traffic car accident	In door trauma	Animal bites	Human abuse	unknown traumas	Total
Dog	5	32	22	15	12	2	88
Cat	10	6	4	4	3	1	28
							116

III. RESULTS

In the present work fractures represented about 17.8 % (116/650) among other surgical affections in pet animals which admitted to the Surgery Department. Dogs represented 67% (88/116) of the total fractured pet animals whereas cats represented about 24 % (28/116). Many breeds of the fractured dogs met with in the present work, were imported by their owners. The most common breeds in dogs and cats were illustrated in Table III.

The majority of the fractured dogs and cats were intact males and females. Most of the presented fractures in dogs and cats were caused by traumas as shown in Table IV. Road traffic car accidents, indoor traumas in dogs and falling from heights in cats were the most common types of trauma respectively.

The young ages were the most commonly affected animals. In the present work, the ages of the fractured dogs were ranging between 4 months to 12 years old, whereas in cats from 4 weeks till 10 years old. Metaphyseal femoral and tibial fractures were common in puppies and kittens (4-18 months old). The body weights of the fractured dogs were ranging from 4 - 30 kg and that of cats from 1- 6 kg.

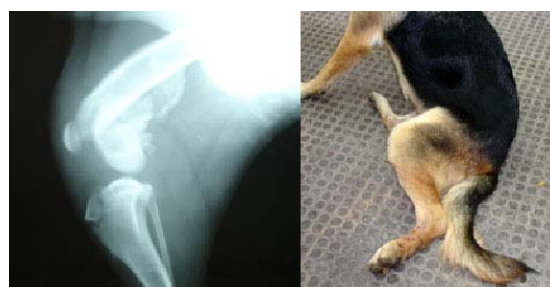

Fig.1 Mediolateral x-ray image of supracondylar metaphyseal femoral fracture in one-year old German shepherd dog

The incidence of the fractured bones in both dogs and cats in the present work were illustrated in Table V. The findings revealed that femoral fractures in dogs and cats represented 37.5 % and 25 % respectively. Femoral and pelvic fractures

were the most common types of traumatic fractures in cats, each one represented 25% and 21% respectively. The most common sites of the fractures in the femur were the shaft (diaphysis), distal metaphysis and supracondylar in dogs (Fig.1), whereas in cats, femur neck (Fig. 2), distal metaphysis and diaphysis (Fig. 3).

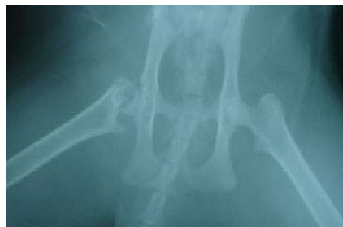

Fig. 2 Vento-dorsal radiographic image of one year old tom cat with femoral neck fracture

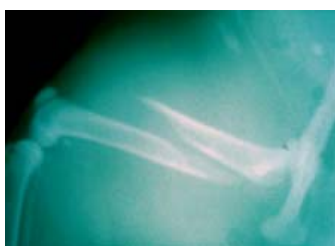

Fig. 3 Medio-lateral x-ray image of complete wedged diaphyseal femoral fracture in a 6-months old Siamese queen

The most common types of fractures met with in the present work were complete simple transverse or oblique and comminuted. Tibial fractures in dogs and cats (Fig. 4) represented 21.5 % and 10% respectively, whereas humeral fractures (Fig. 5) were represented as 7.9% and 14% in dogs and cats respectively. Humeral condylar fractures were most often seen in puppies 4 to 6 months old. The vast majority involved the lateral condyle.

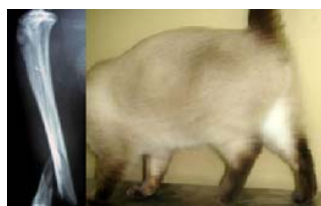

Fig. 4 Medio-lateral x-ray image of complete wedged diaphyseal tibial fracture in a 2 year old cat

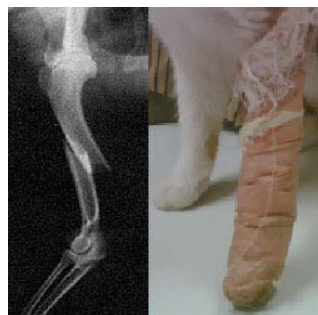

Fig. 5 Mediolateral x-ray image of complete overlapping diaphyseal humeral fracture in a cat

Fractured radius and ulna in dogs (Fig. 6) and cats represented (19 % and 14% respectively). Fractures of the metacarpal, (Fig. 7), lumbar vertebrae (Fig. 8), and mandible represented 3.4 % and 0 , 3.4 % and 3.5 % , 0 and 10% in dogs and cats respectively.

TABLE V
THE INCIDENCE OF DIFFERENT TYPES OF FRACTURES IN DOGS AND CATS

Affected bones	No. of cases (dog/cat)	Sites of fracture	Types of fractures
Pelvic bone	Dog 6 (6.8%)	Symphysis, pubis, ilium, Hip dislocation	complete distracted, complete overlapping, dorsal complete dislocations
	Cat 6 (21%)		
Femur	Dog 33 (37.5%)	Shaft, Supracondylar, Neck- femur, Metaphyseal	complete diaphyseal overlapping, complete supracondylar comminuted, complete without displacement, simple metaphyseal transverse
	Cat 7 (25%)		
Tibia	Dog 19 (21.5%)	Shaft, Metaphysis, Supracondylar, Condylar	complete diaphyseal overlapping, complete metaphyseal comminuted, complete overlapping
	Cat 3 (10%)		
Humerus	Dog 7 (7.9%)	Shaft, Condyles	complete diaphyseal, simple condylar
	Cat 4 (14%)		
Radius and ulna	Dog 17 (19%)	Metaphysis, Shaft	complete metaphyseal oblique, complete simple transverse
	Cat 4 (14%)		
Metacarpal	Dog 3 (3.4%)		
	Cat -		
Vertebral column	Dog 3 (3.4%)	Lumbar, Sacral	complete depressed (one case)
	Cat 1 (3.5%)		
Mandible	Dog -		complete without displacement
	Cat 3 (10%)		
Total	Dog 88		
	Cat 28		

In 26 fractured dogs, box rest (9 cases), adhesive bandage (4 cases), and gypsona cast (13 cases), were used as external coaptation. The results were good in 18 cases, satisfactory in 6 cases, and 2 cases were unsatisfactory. Out of 33 femoral fractures, treated with internal fixation, 22 cases gave good results, 6 cases gave satisfactory results whereas 5 cases were unsatisfied. Seventeen fractured tibia in dogs treated with internal fixation gave good results and two cases treated with external fixation gave satisfactory results.

The traumatic supra – condylar femoral fractures in dogs were repaired successfully using cross- pin technique (Fig. 9). Stack pins provided effective stabilization to complete oblique femoral fracture (Fig. 10), whereas use of Intramedullary pinning technique and circlage wire was effective in tibial fractures (Fig.11) and in humeral fractures (Fig.12).

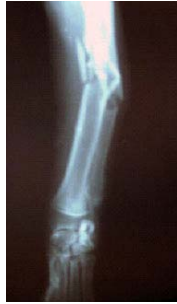

Fig. 6 Dorsoventral x- ray image of complete comminuted fracture of radius and ulna in a dog

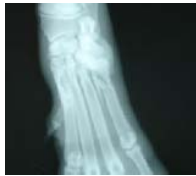

Fig. 7 Dorsopalmar x- ray image of complete oblique fracture of 5th metacarpal bone in a dog

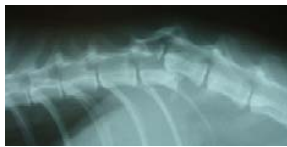


Fig. 8 Lateral x- ray image of an oblique displaced fracture of dorsal spinous process of the 1st lumbar vertebra in 6 months old German shepherd dog

External coaptation with cast and adhesive tape bandages gave good results in fractured radius and ulna (Fig. 13) as well as fractured metacarpal bones.

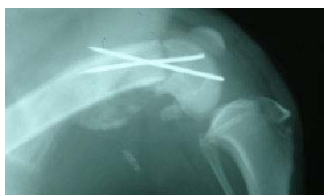

Fig. 9 Mediolateral radiographic image of the supracondylar femoral fracture treated with cross pin

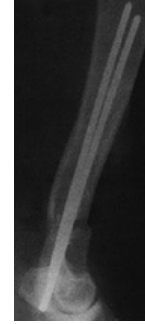

Fig. 10 An x- ray image of complete femoral diaphyseal fracture of a dog treated with stack pins

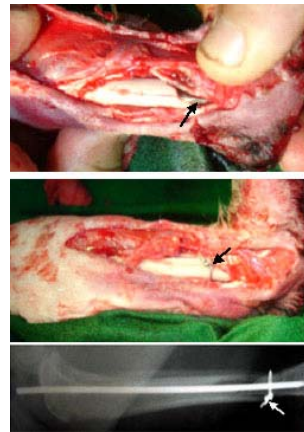


Fig. 11 Mediolateral radiographic image of complete tibial fracture in a cat treated with intramedullary pin and cerclage wire

In 12 affected cats, cage rest (7 cases), adhesive bandage (1) and gypsum cast (4 cases), were used as external coaptation. The results of these approaches were good in 9 cases, satisfactory in 2 cases, and one case unsatisfactory. Out of 7 femoral fractures treated with internal fixation 4 cases gave good results (Fig. 14), 3 cases gave satisfactory results. Twelve fractured tibia in cats treated also with internal fixations, 8 cases were good, 2 gave satisfactory and 2 gave unsatisfactory results.

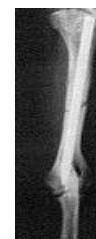

Fig. 12 An x- ray image of complete oblique humeral fracture in a dog treated with intramedullary pin

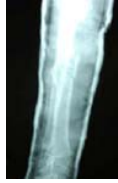

Fig. 13 Mediolateral x-ray image of complete fracture of radius and ulna in a dog treated with gypsona bandage

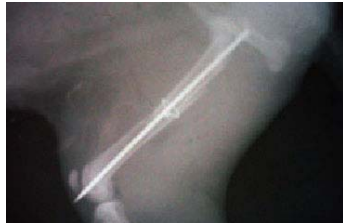

Fig. 14 Mediolateral radiographic image of 6-months old dog with complete femoral fracture treated with intramedullary pin and circlage wire

After 3-5 months complete remodeling occurred in operated cases. The fractured humerus, radius and ulna were illustrated in the same table. Femoral neck fractures in young cats were treated by femoral head resection.

IV. DISCUSSION

In the present study, fractures represented about 17.8 % in dogs and cats among other surgical affections. These findings were similar to that mentioned by [11] who recorded that bone disorders in cats represented about 14.7%. among all other feline affections.

In the present work dogs represented about 67% (88 / 116) of the total fractured pet animals whereas cats represented about 24% (28 /116), whereas in a previous study [11] feline traumatic fractures were representing 76.4%. This variation between the two results could be due to increased number of complicated cases of feline orthopaedics due to overcrowded and increased car accidents in Egypt than in Libya. The most common breed which exposed to fractures in dogs German shepherd whereas in cats were the Siamese breed. These findings were similar to that mentioned by [27], [11].

Most of the fractured dogs and cats met with in the present work were entire males and female. This could reflect that neutering, under our circumstances, was not a routine approach. Consequently, intact pet animals, wandering outdoors in mating seasons may be subjected to traumatic fractures. Similar observation made by [11]. Adult cats (between 1-3 years old) were highly subjected to bone fractures as they when moving from their familiar territories were subjected to traumatic situations. These observations were in agreement with [11].

In dogs, road traffic accidents and indoor traumas were the most common type of trauma forms causing fractures whereas in cats falling from heights followed by traffic accident and cat bites were the most common traumas inflicted over the

affected cats. These observations agreed with [11]. It was interesting to note that bone fractures in small pet animals occurred in the hind limbs more than the fore limbs as they expose their hind quarters to the major force of the impact. These results were similar to that mentioned by [9]. On clinical examinations, feline patients and viscous dogs showed potential difficulties in their restraint rather than unwillingness to walk around an unfamiliar examination room. The same observations were recorded by [21], [2], [11]. Moreover, difficulties of postoperative physical therapy and exercises to rehabilitate these patients were an important aspect that should be taken in consideration [2], [11].

Femoral, tibial as well as radius and ulna were the most common types of traumatic fractures in dogs whereas in cats the femoral and pelvic traumatic fractures were the most common types met with in the present work. These findings incorporate the similar results in cats mentioned by [11]. The most common sites of femoral fractures in dogs and cats mentioned in this study were similar to [9], [11]. Humeral condylar fractures were most often seen in puppies 4 to 6 months old. The vast majority involved the lateral condyle because the lateral condyle is situated somewhat eccentrically, lateral to the force vector directed proximally through the humerus in the standing animal. This observation was similar to that recorded by [9]. Fractures of the radius, ulna, or both were considered together since, concurrent fractures of both bones were seen in dogs and cats representing 19 % and 14 % respectively. These observations were in agreement with [9]. The adopted surgical techniques achieved satisfactory results in all treated cases of dogs and cats. These results were in agreement with those of [3], [4], [6], [25], [17], [11].

REFERENCES

- [1] N. A. Senna, "Observations on some aspects of dogs and cats ownership: A new role for veterinarians," *J. Egypt. Vet. Med.*, vol. 61, no. 3, pp. 199-216, 2001.
- [2] J. Harari, "Treatment of feline long bone fractures," *Vet. Clin. North Am. Small Anim. Pract.*, vol. 32, no. 4, pp. 927-947, 2002.
- [3] H. R. Denny, "A guide to canine and feline orthopedic surgery," 3rd ed. Blackwell Sci. Publ. Oxford, 1993.
- [4] S. J. Langley-Hobbs, S. Carmichael and W. McCartney, "Use of external skeletal fixators in the repair of femoral fractures in cats," *J. Small Anim. Pract.*, vol. 37, pp. 95-101, 1996.
- [5] S. J. Langley-Hobbs, S. Carmichael and W. McCartney, "External skeletal fixation for stabilization of comminuted humeral fractures in cats," *J. Small Anim. Pract.*, vol. 38, no. 7, pp. 280-285, 1997.
- [6] D. L. Piermattei and G. L. Fla, "Small animal orthopaedic and fracture repair," 3rd ed, W. B. Saunders Co., Philadelphia, London, 1997, pp. 503-511.
- [7] O. I. Lanz, "Lumbosacral and pelvic injuries," *Vet. Clin. North Am. Small Anim. Pract.* vol. 32, no. 4, pp. 949-962, 2002.
- [8] W. T. Jr. McNicholas, B. E. Wikens, W. E. Blevins, P. W. Snyder, G. P. McCabe, A. A. Applewhite, P. H. Lavery and G. I. Breur, "Spontaneous femoral capital physal fractures in adult cats; 26 cases (1996-2001)," *JAVMA*, vol. 221, no. 12, pp. 1731-1736, 2002.
- [9] G. Harasen, "A: Common long bone fractures in small animal practice-part 1," *Can. Vet. J.*, vol. 44, pp. 333-334, 2003.
- [10] G. Harasen, "Fractures involving the distal extremity of the femur. Part1-the immature patient," *Can. Vet. J.*, vol. 42, pp. 949 - 950, 2001.
- [11] N. A. Senn, S. M. Gadallah and M. K. Zabady, "Studies on some bone disorders in cats: incidence, radiological assessment and surgical

- management," *J. Egypt. Vet. Med. Assoc.*, vol. 64, no. 3, pp. 113-137, 2004.
- [12] D. D. Lewis, A. R. Cross, S. Carmichael, and M. A. Anderson, "Recent advances in external skeletal fixation," *J. Small Anim. Pract.*, vol. 29, no. 5, pp. 1097-1117, 2001.
- [13] J. P. Farese, D. D. Lewis, A. R. Cross, K. E. Collins, G. M. Anderson and K. B. Halling, "Use of IMEX SK- circular external fixator hybrid constructs for fracture stabilization in dogs and cats," *J. Am. Anim. Hosp. Assoc.*, vol. 38, no. 3, pp. 279-289, 2002.
- [14] A. L. Johnson and C. E. DeCAMP, "External skeletal fixation. Linear fixators," *Vet. Clin. North Am. Small Anim. Pract.*, vol. 29, no. 5, pp. 1135-1152, 1999.
- [15] C. S. Rahal, S. R. Volpi, C. L. Vulcano and B. R. Ciani, "Acute shortening and subsequent lengthening of the radius and ulna for the treatment of Infected nonunion in a dog," *Can. Vet. J.* vol. 42, pp. 724-726, 2001.
- [16] G. Harasen, "Repair of comminuted femoral fracture in a cat using cortical and cancellous bone grafting techniques," *Can. Vet. J.*, vol. 38, pp. 574- 575, 1997.
- [17] K. A. Farag, "Distal femoral fractures: use of cross- pinning technique for repair in dogs and cats," *J. Egypt. Vet. Med. Ass.*, vol. 62, no. 1, pp. 83-92, 2002.
- [18] G. Harasen, "Fractures involving the distal extremity of the femur: part 2 – the mature patient," *Can. Vet. J.*, vol. 43, pp. 131-132, 2002.
- [19] A. F. Hale and G. M. Anthony, "Treatment of mandibular and dental fractures in a young dog," *Can. Vet. J.*, vol. 37, pp. 307-309, 1996.
- [20] W. J. Whittick, "Examination of the patient. In: canine orthopedics," Lea and Febiger, USA, 1974, pp. 81-88.
- [21] C. A. Leonard, "Feline lameness," *Vet. Clinics North Am. Small Anim. Pract.*, vol. 31 no. 1, pp. 143-163, 2001.
- [22] K. K. Diane and K. W. Hollingshead, "Small animal Anesthesia (canine and feline practice), Mosby's Fundamental of Veterinary Technology, 1993.
- [23] D. Franczusi, J. A. Chalm and H. C. Butler, "The use of paired pins in fixation of distal femoral fracture in the dogs and cat," *J. Am. Anim. Hosp. Assoc.*, vol. 22, pp. 173-178, 1986.
- [24] O. Whitney and S. C. Schrader, "Dynamic intramedullary cross pinning technique for repair of distal femoral fractures in dogs and cats: 71 cases (1981-1985)," *JAVMA*, vol. 191, pp. 1592-1596, 1987.
- [25] R. McLaughlin, "Internal fixation; Intramedullary pins, Cerclage wires and Interlocking nails," *Vet. Clin. North Am. Small Anim. Pract.*, vol. 29, no. 5, pp. 1097-1117, 1999.
- [26] R. E. Oakley, "External coaptation," *Vet. Clin. North Am. Small Anim. Pract.*, vol. 29, no. 5, pp. 1083-1095, 1999.
- [27] G. Harasen, "B : Common long bone fracture in small animal practice – part 2," *Can. Vet. J.*, vol. 44, no. 6, pp. 503-504, 2003.