

# Histopathological and Morphological Defects in the Mice Prenatally Exposed to Low EMF

Y. Rosli, A. Husna AH and M. Nurhayati

**Abstract**—This research was carried out to determine the possible effects of low electromagnetic field (EMF) exposure to the developing mice fetuses. Pregnant mice were exposed to EMF exposure at 0mT (sham) and 1.2 mT for six hours per session, carried out on gestation day 3, 6, 9, 12 and 15. Samples from the stillborn offspring were observed for morphological defects. The heart didn't show progressive cellular damage, the lungs were congested and emphysemic. The bones were in advance stage of hypertrophy. Spectrums of morphological defects were observed over 70% of the surviving offspring. These results indicate that even at lower exposure to low EMF, is enough to induce morphological defects in prenatal mice.

**Keywords**— bone hypertrophy, EMF, low electromagnetic field.

## I. INTRODUCTION

THE advances in the technology during the last century had increased an unprecedented population exposure to electromagnetic fields (EMF) generated by many sources (power transmission lines, mobile phones, household electrical appliances etc). Researches on the bioeffects of electromagnetic field is being conducted for over three decades but have found inconsistent results. Epidemiologically, it has been substantial proofs linking the occurrence of leukemia, brain tumor and breast cancer to the environmental magnetic field [1].

Any embryotoxicity of EMF in pregnant mothers raises public apprehension. Concerns about potential susceptibility of embryo, fetal, newborn and the juvenile to EMF are comprehensible due to the immaturity of all organs in their developing stages. A large number of *in vivo* studies have been carried out in mammals reported no or only slightly effects on fetus [2]-[6].

One of the main important characters of the skeletal systems is that it follows a process of development, growth and maturation from beginning of life to the postnatal stage. Exposures to exogenous physical agents during embryogenesis could be detrimental. EMF was reported to exerts therapeutic effects, promoting neural regeneration, bone

repair [7] and osteogenesis of bone marrow mesenchymal stem cells [8]. There are also reports on the possible vasodilatory, biphasic and restorative effects of EMF on micro vascular tone [9]-[11]. The present study was designed to evaluate whether gestational exposure of low-intensity (1.2mT) EMF affects the lungs alveolar regions which are rich in micro-vessels and the rib bones in stillbirth mice. This report is part of a larger scale study that had been described in a companion study in which the surviving offspring life qualities were monitored closely [12], [13].

## II. MATERIALS AND METHODS

### A. Animals

All procedures in this study is carried out according to the practices approved by the Animal Ethics Committee, (FSKB/BIOMED/2008/UKM/YANTI/12-AUGUST/231-SEPT-2008-JUNE-2011). For the study on the offspring, twenty four female *Mus musculus* mice weighing between 120-140g were obtained from the UKM Faculty of Medicine Animal House and were mated overnight in separate standard plastic cages. When a vaginal plug was found, the mice were accepted as pregnant. Pregnant animals were house in standard plastic cages on sawdust bedding in well ventilated at 27°C, under a 12/12h light/dark cycle and fed *ad libitum*. They were randomly divided into negative control (8 animals) and EMF (1.2mT) exposed groups (8 animals).

### B. Low EMF delivery

The low EMF was created by means of a solenoid coil, consisting of a rigid PVC tube and insulated copper wire of 0.8mm diameter. The solenoid is supplied by adjustable DC power supply (Daedalon), EMF generated inside the coil was uniform and was measured using a digital Teslameter with axial and transverse probes (Daedalon); the difference between the theoretical and measured values was lower than 1%. The voltage (V) is kept constant by the DC current  $i$ ; the related equation for the magnetic field is:

$$B = \mu_0 ni. \quad (1)$$

$\mu_0$  = the permeability of free space and  $n$  = the number of turns (125 turns). In this study, the constant value of  $B$  for a fixed value of  $i$  (1.3V) for all exposures was checked for each pre- and post- experiment. The animals in the solenoid coil are ventilated via the mesh plastic cover, enclosing the PVC tube. The room temperature was kept at 26°C throughout the experiment. For the pregnant mice group, each EMF exposure

Y. Rosli is with the Department of Biomedical Science, Faculty of Allied Health Sciences, Universiti Kebangsaan Malaysia, Jalan Raja Muda Abdul Aziz, 53300, Kuala Lumpur, Malaysia (phone: 0392897049; fax: 0326929032; e-mail: dr\_yanti@medic.ukm.my).

A. Husna AH, and M. Nurhayati were honors year student at Department of Biomedical Science, Faculty of Allied Health Sciences, Universiti Kebangsaan Malaysia, Jalan Raja Muda Abdul Aziz, 53300, Kuala Lumpur, Malaysia.

lasted for 6 hours, on gestation day 3, 6, 9, 12 and 15. Animals of the control groups underwent the same procedure, minus the EMF exposure. All the stillbirth were examined morphologically and later processed for histopathology. The morphological observations were carried out on the surviving offspring, week 6-8 postnatal.

### C. Histopathology

The tissue samples were trimmed properly and fixed for 24 h more. To remove the fixative, the tissues were kept in running tap water for overnight. The tissues were dehydrated in ascending grades of alcohol. The tissues were embedded in paraffin wax. The tissues were sectioned with a rotary microtome at 5µm thickness and stained with H&E. The tissues were examined under microscope and photomicrograph was taken using compound microscope and photo micrographic camera (Olympus PM-C 35 Model).

### III. RESULTS

Spectrums of morphological defects were found in the surviving offspring, mainly relating to the fore and back limbs or digits, and the tail. These include total absence of hind limbs (18%), incomplete fore and hind limb digit separation (25%, not shown) and stumpy tail growth (12%).

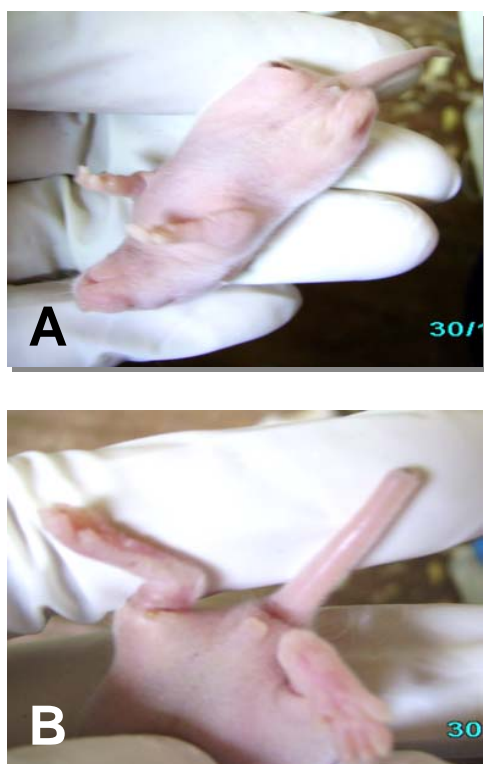


Fig. 1 The absence of the hind limb (A) and the incomplete tail growth in the surviving offspring of the treated group (B).

The percentage of stillbirth in the sham group is 2% compared to 5.9% in the EMF exposed group. Necropsy on

the stillbirths in the EMF exposed group shows massive hemorrhage of the lungs, short, but developed ribs.

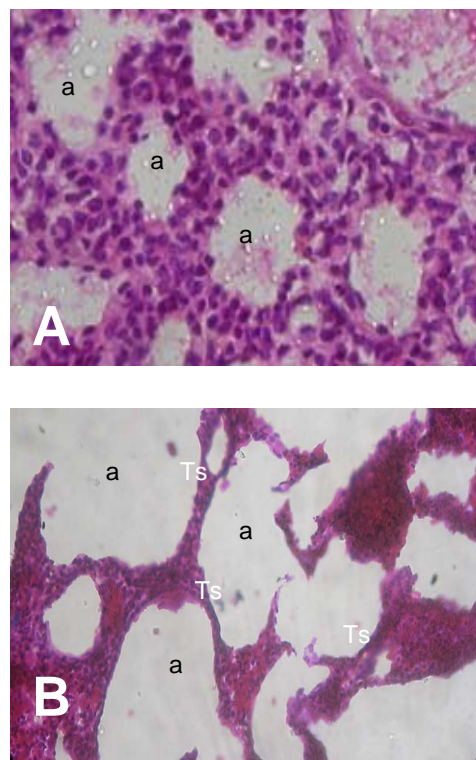


Fig. 2 Cross section of the lung of the control (A) and the treated group (B) at 40x; a-denotes alveolus, Ts denotes thickened septaes.

In macroscopic examination, the lungs from the EMF exposed group were heavy, edematous and congested. In the lung microscopy, congestion was the most common finding in our study, followed by oedema, hemorrhage, collapses of alveoli, alveolar thickening, alveolar wall disturbance and dilated capillaries and round cell infiltration around bronchioles (Fig. 2B). This type of disturbance of alveolar wall was seen in wasn't reported in other previous studies.

The microscopic study of the ribs from the sham group shows the normal mesenchymal cells differentiate into chondrocytes to form a cartilage scaffold lined by a thin layer of osteoblasts and vascularization were observed and shows incomplete ossification. In comparisons, the ribs from the of EMF exposed stillbirths show a more advanced stage of chondrocyte differentiation in which the osteoblasts were numerous and the presence of osteoclasts were noted. The chondrocytes were appeared to be realigned into column-like structures and the layer of the osteoblasts forming the cuff on the ribs are thicker and no vascularization could be seen (Fig. 3B).

The histology of the heart of the treated group do not show any significant changes as compared to the treated group, although there are signs of thromboses could be readily observed at the higher magnification Fig. 4C)

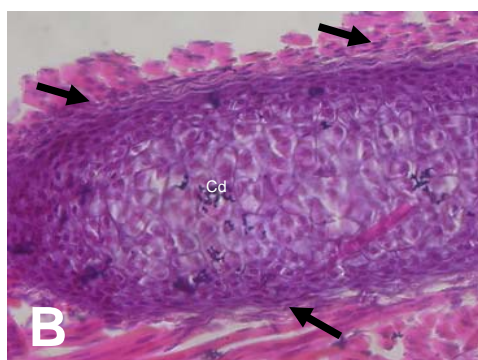
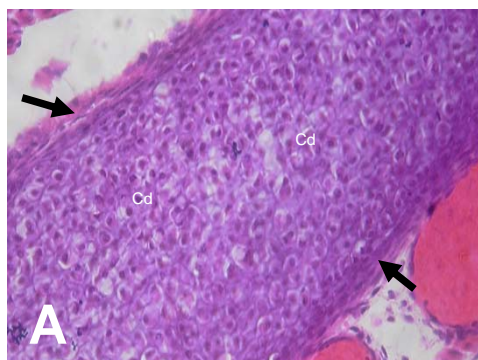


Fig. 3 Micrograph (A) is rib cross section of the control and treated group (B) at x100; arrow points at the osteoblasts and Cd denotes chondrocytes.

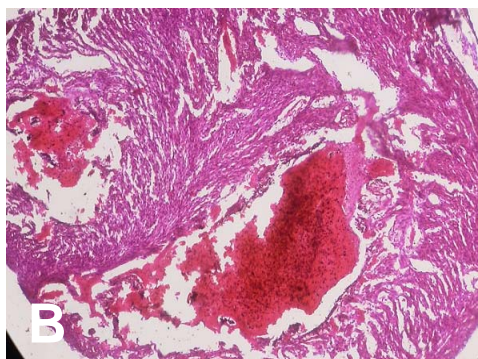
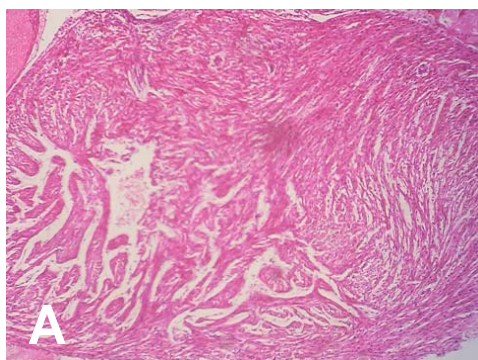


Fig. 4 Micrograph (A) shows the cross section of the heart of the control and treated group (B) at x100; and (C), treated group at x400. The arrow points at the thromboses found in the cardiac tissue.

Based on our results, the exposure to low EMF during gestation period causes congested lungs that are fatal meanwhile late stage of intramembranous ossification seen in this same group may not be of a direct fatal contributory factor. Although the observation on the cross section of the heart in the treated group do not show any significant defect as compared to the control group, what it means however, it had proven what previous researchers have reported earlier about EMF promotes osteogenesis [14], [15]; although none had reported using the low EMF strength as in this study. We conclude that exposure to EMF even at 1.2mT during gestation period effects organogenesis.

#### REFERENCES

- [1] Wertheimer, N., Savitz, D., Leeper, E. 1995. Childhood cancer in relation to indicators of magnetic fields from ground current sources. *Bioelectromagnetics* **16**:86-96.
- [2] Frolen, H., Svedenstal, B., Paulsson, L. 1993. Effect of pulsed magnetic fields on the developing mouse embryo. *Bioelectromagnetics* **14**:197-204.
- [3] Kim, S., Song, J., Kim, S., Oh, H., Gimm, Y., Yoo, D. 2004. Teratological studies of prenatal exposure of mice to a 20kHz sawtooth magnetic field. *Bioelectromagnetics* **25**:114-117.
- [4] Stuchly, M., Ruddick, J., Villeneuve, D., Robinson, K., Reed, B., Lecuyer, D., Tna, K., Wong, J. 1988. Teratological assessment of exposure to time-varying magnetic fields. *Teratology* **38**:461-466.
- [5] Svedenstal, B., Johanson, K. 1995. Fetal loss in mice exposed to magnetic fields during early pregnancy. *Bioelectromagnetics* **16**:284-289.
- [6] Wiley, M., Corey, P., Kavert, R., J. C., Harvey, S., Agnew, D., Walsh, M. 1992. The effects of continuous exposure to a 20-kHz sawtooth magnetic fields on the litters of CD-1 mice. *Teratology* **46**:391-398.
- [7] Bassett, C. 1993. Beneficial effects of electromagnetic fields. *Journal of Cellular Biochemistry* **51**:387-393.
- [8] Zhao, D., Wu, H., Li, F., Li, R., Tao, C. 2008. Electromagnetic field change the expression of osteogenesis genes in the murine bone marrow mesenchymal stem cells. *Journal of Huazhong University Science and Technology* **28**:152-155.
- [9] McKay, J., Prato, F., Thomas, A. 2007. A Literature Review: The effects on Magnetic Field Exposure on Blood Flow and Blood Vessels in the Microvasculature. *Bioelectromagnetics* **28**:81-98.
- [10] Okano, H., Ohkubo, C. 2003. Anti-pressor effects of whole-body exposure to static magnetic field on pharmacologically induced hypertension in conscious rabbits. *Bioelectromagnetics* **24**:139-147.
- [11] Xu, S., Okano, H., Ohkubo, C. 2001. Acute effects of whole-body exposure to static magnetic fields and 50-Hz electromagnetic fields on

- muscle microcirculation in anaesthetized mice. *Bioelectrochemistry* **53**:127-135.
- [12] Rosli, Y, Teoh PJ. 2009 The effect of low electromagnetic field in the cerebellar layers of mice. *Journal of Biological Sciences* 9(6): 601-606.
- [13] Rosli, Y., Proomwittichit P, Nurhayati, M. 2007. Mobile Hazards. *Prospect Malaysia*. June. Issue 3: 54
- [14] Sert, C., Deniz, M., Duz, M., Aksen, F., Kaya, A. 2002. The Preventive Effect On Bone Loss Of 50Hz, 1 Mt Electromagnetic Field In Ovariectomized Rats. *Journal of Bone Mineral and Metabolisme* **20**:345-349.
- [15] Tabrah, F., Hoffmeier, M., Gilbert, F., Batkin, C. 1990. Bone Density Changes In Osteoporosis-Prone Women Exposed To Pulsed Electromagnetic Fields. *Journal of Bone Mineral Research* **5**:437-441.