

Gonadotoxic and Cytotoxic Effect of Induced obesity via Monosodium Glutamate on *Mus musculus* Testis Cytoarchitecture and Sperm Parameter

I. Nur Hilwani, R. Nasibah, S. Nurdiana, M. J. Norashirene

Abstract—Impaired fertility may be the result of indirect consumption of anti-fertility agents through food. Monosodium glutamate (MSG) has been widely used as food additive, flavour enhancer and included in vaccines. This study focuses in determining the gonadotoxic and cytotoxic effect of MSG on selected sperm parameters such as sperm viability, sperm membrane integrity and testes cytoarchitecture of male mice via histological examination to determine its effect on spermatogenesis. Twenty-four *Mus musculus* were randomly divided into 4 groups and given intraperitoneal injections (IP) daily for 14 days of different MSG concentrations at 250, 500 and 1000mg/kg MSG to body weight to induce obesity. Saline was given to control group. Mice were sacrificed and analysis revealed abnormalities in values for sperm parameters and damages to testes cytoarchitecture of male mice. The results recorded decreased viability ($p < 0.05$) and integrity of sperm membrane ($p > 0.05$) with degenerative structures in seminiferous tubule of testes. The results indicated various implications of MSG on male mice reproductive system which has consequences in fertility potential.

Keywords—Sperm parameter, sperm viability, sperm membrane integrity and testes histology.

I. INTRODUCTION

SPERM parameter and spermatogenesis are powerful fertility indicators which may be impaired through fertility-affecting agents such as monosodium glutamate (MSG) which is widely found in food. Glutamate is a type of amino acid readily absorbed by the body. Glutamate is a naturally present excitatory neurotransmitter in the brain that mediates the fast synaptic transmission almost in all central nervous system synapse. Increasing availability of glutamate in the body affects the activity of glutamate receptors which in turn indirectly affects neuronal firing by docking on the receptors and facilitating the flooding of calcium into the cell, causing cytotoxic effects [1].

The most common use of MSG is as flavour enhancer designed to convey umami taste naturally associated with meat, fish and dairy products. MSG increases the perception

of sweetness and saltiness and diminishes the bitterness and sourness of the food [2]. It has been reported to have many functions in the human body such as a metabolic intermediate and protein constituent in many protein-rich food items such as meat, cheese and some vegetables [3]. MSG has also been reported to be used as an additive in patented vaccines namely adenovirus vaccine and influenza vaccine [4].

Previous studies incriminated MSG as the major cause affecting various pathological conditions such as learning difficulty, autism, obesity and gonadal dysfunction. Subsequently, MSG has been recognized to produce oxygen derived free radicals [5]. Effects of MSG on reproductive organs specifically testes, ovary and uterus have been studied in neonatal animals which show reduction in weight of both testes and ovaries thus reducing fertility potential of both sexes [6]. Reference [7] reported that oral consumption of MSG affects the structure and function of male reproductive system and shown to be toxic to the testis of human and experimental animals. Oral administration of MSG also results in lower serum testosterone levels and reduction in the caudal epididymis sperm of male rats [8].

II. MATERIALS AND METHODS

A. Animals for Study

Sexually matured male mice (7-8 weeks old) weighing 22g to 32g were used in the experiment. Mice were fed with standard mouse pellets (Gold Coin Feed Mills (M) Sdn. Bhd) and water given *ad libitum*. Mice were maintained under standard conditions of humidity, temperature with 12 hours of light/12 hours of dark cycle. The test mice were allowed to acclimatize for one week prior to the experiment. All experimental procedures and animal maintenance were conducted in accordance to ethical approval by the university's UiTM CARE ethical committee (Ref. No.: 600-FF (PT. 5/2) 24/2013)

Monosodium Glutamate (SIGMA-ALDRICH, Germany) was prepared into 3 concentrations: 250 mg/kg MSG; 500 mg/kg MSG and 1000mg/kg MSG.

B. Induction of Obesity via Monosodium Glutamate (MSG)

Sexually matured male *Mus musculus* were induced to obesity via intraperitoneal injection of different concentrations. Experimental animals were randomly divided into four groups (n=6/group): Control Group: animals in this group received normal diet and saline solution; Group 1:

I. Nur Hilwani, S. Nurdiana, and M. J. Norashirene are faculty members with the Department of Biology, Faculty of Applied Sciences, Universiti Teknologi MARA (UiTM) Malaysia.

I. Nur Hilwani is a Lecturer in Cellular Biology, Universiti Teknologi MARA (UiTM) Malaysia (phone: +603 5543 8435; fax: +603 5544 4562; e-mail: hilwani@salam.uitm.edu.my).

This project was funded by Research Acculturation Grant Scheme (file no.: RAGS/2012/UITM/ST03/1) awarded by the Ministry of Education Malaysia and Universiti Teknologi MARA (UiTM) Malaysia.

animals were induced obesity with 250 mg/kg MSG to body weight via IP for 14 days; Group 2: animals were induced obesity with 500 mg/kg MSG to body weight via IP for 14 days and Group 3: animals were induced obesity with 1000 mg/kg MSG to body weight via IP for 14 days. Degree of obesity was determined using Lee's index by calculating the cube root of body weight (g) / naso-anal length (cm) [9]. Individual mice were considered obese with indices exceeding 0.3.

C. Sperm Viability and Sperm Membrane Integrity Parameter Analysis

The control and treatment groups were analyzed for viability by using Eosin-Nigrosin (EN) staining technique. Briefly, 10 μ l of semen was mixed with EN stain and smeared onto a slide and was air dried. The slides were observed under 40x magnification, and the number of viable and non-viable spermatozoa cells were enumerated. As an indication of functional sperm, membrane integrity was determined through the osmoregulatory capacity under hypo-osmotic conditions of 150mOsm/L [10]. Preparation of swelling solution and procedure were conducted as outlined in [11]. Briefly, 0.735g of sodium citrate dihydrate and 1.351g of D-fructose were dissolved in 100ml of purified water. The sperm sample to hypo-osmotic solution was mixed in ratio 1:1 and incubated at 37°C for 30min to evaluate membrane integrity. Following incubation period, sperm were scored as having intact membrane integrity by visual scoring of swollen tails based on [11].

D. Testis Histology

Collected testes tissue blocks were formalin fixed and embedded in paraffin wax. Sections of 4 μ m were made and stained with hematoxylin and eosin (HE). Morphometric analysis of spermatogenic cell and sertoli cell within the seminiferous tubule epithelium were performed on HE-stained sections by means of an automated image analyzer connected to a Nikon ECLIPSE Ti-E Inverted Research Microscope (Nikon Corp., Japan) supplemented with NIS-Elements software (Nikon Corp., Japan) including Image Pro Plus Program (Media Cybernetics, Inc., Silver Spring, MD) for image capture. For each specimen, 10 images of seminiferous tubule were taken and images were stored in the digital memory and displayed on the monitor screen.

III. RESULTS AND DISCUSSION

A. Induction of Obesity via Monosodium Glutamate (MSG)

Mean body weight of mice increased in a dose dependent manner as compared to control group when induced with MSG. This observation is corroborated by previous studies by [5] and [3] where MSG improves the palatability of meals and positively influences the appetite thus resulting in increase of body weight. For further evaluation, percentage increase in body weight of mice in each group was calculated. The percentage increase in body weight was 7.01%, 3.11% and 4.74% for 250, 500 and 1000mg/kg MSG to body weight respectively.

B. Sperm Viability Analysis

The mean percentages of viable sperm were significantly decreased for all treatment groups administered with 250, 500 and 1000mg/kg MSG to body weight (Table I). Consumption of high doses of MSG had been reported to cause damage to the testes. The viability and efficiency of sperm were reduced due to the alteration of sperm characteristic and could be the major cause of infertility in males [12]. However, sperm viability of 500 mg/kg MSG group was slightly higher as compared to the other groups. This observation could be due to physiological differences contributed by individual mouse [13] or due to factors contributed during the sperm handling period.

TABLE I
SPERM VIABILITY ANALYSIS

Treatment groups	Viability percentage (mean \pm SEM)
Control	55.00 \pm 2.61
250 mg/kg MSG	27.67 \pm 8.23*
500mg/ kg MSG	31.44 \pm 6.94*
1000 mg/kg MSG	22.33 \pm 4.37*

*significantly different ($p < 0.05$)

C. Sperm Membrane Integrity Evaluation

The negative effect of MSG on membrane integrity was reflected in the observation for membrane integrity where the mean percentage of membrane intact sperm suffered a decline across all treatment groups (Table II). However, the figures were statistically insignificant.

TABLE II
ENUMERATION OF MEMBRANE INTACT SPERM VIA HOS TEST

Treatment groups	Percentage of membrane intact sperm (mean % \pm SEM)
Control	63.33 \pm 1.99
250 mg/kg MSG	49.44 \pm 7.39
500mg/ kg MSG	48.33 \pm 7.74
1000 mg/kg MSG	46.11 \pm 4.24

Not significantly different ($p > 0.05$)

The basis of HOS test is the semi-permeability of the intact sperm membrane which induces sperm tail to swell under hypo-osmotic conditions due to the influx of water that lead to the expansion in cell volume [14]. The sperm plasma membrane is involved in maintenance and survival of sperm within the female genital tract and is important for sperm capacitation [15]. In the present study, MSG negatively affected cells of the testes, thereby affecting the cellular integrity which caused a defect in membrane permeability and cell volume homeostasis [16]. The observation could be more significant if the time for administration of MSG was prolonged as long term treatment may indicate a lead to severe damage of germ cell line and a marked reduction in testes and epididymis weight as well as sperm count and increase in occurrence of sperm abnormalities in MSG-treatment groups [17].

D. Analysis of Testis Cytoarchitecture

Section of the testis stained by Haematoxylin and Eosin (HE) in control group as demonstrated in Fig. 1 (A) showed

thick seminiferous tubule (ST) with lumen that is small in diameter. The ST appeared as rounded or oval surrounded by a thin Basal Lamina (BL). MSG-treatment groups in Fig. 1 (B) (250 mg/kg MSG), Fig. 1 (C) (500 mg/kg MSG) and Fig. 1 (D) (1000 mg/kg MSG) showed a disorganization of the normal appearance of the testicular cells with different degrees of atrophy in the seminiferous tubule as well as diameter of tubular lumen. Further in this study, the histological changes detected in the testis of mice treated with MSG mainly included alterations of the seminiferous tubule such as atrophied seminiferous tubule, loss of spermatogenic cells and decrease in tubular lumen size. The results were in accordance

with [18] who reported similar histological changes in the testis after the administration of MSG. The 1000 mg/kg MSG group had the greatest changes in the testicular structure with severe damage of the seminiferous tubule and had recorded the largest diameter size of tubular lumen as compared to other groups. The mechanism of spermatogenesis inhibition by MSG was demonstrated by the presence of functional glutamate receptors in mice testis [19]. Thus, testes are considered as target organs for MSG. From the observation it is clear that increase in MSG concentration lead to the distortion of testes cytoarchitecture which then may inhibit the process of spermatogenesis, a major indicator of male fertility.

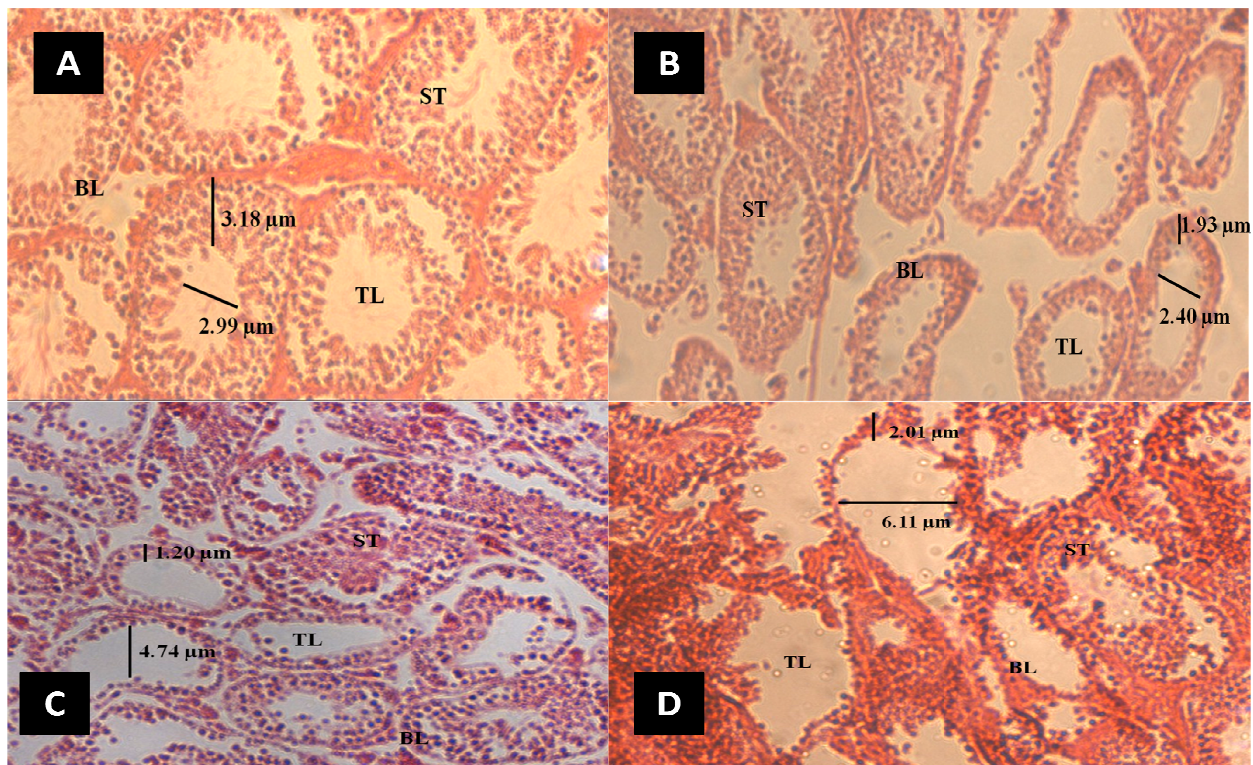


Fig. 1 Photomicrograph cross sections of testis showing seminiferous tubules (ST), basal lamina (BL) and tubular lumen (TL) of control group (A) and MSG treated groups (B): 250 mg/kg MSG; (C): 500 mg/kg MSG and (D): 1000 mg/kg MSG

IV. CONCLUSION

The investigation clearly demonstrated a direct synergistic effect of induced obesity and MSG intake on sperm parameters such as viability and membrane integrity as well as testis cytoarchitecture. Intake of MSG showed a reduction in viability and membrane integrity of sperm. The structural histological changes of testis in MSG induced obese mice were found to be dosage dependent and ranged from slightly damaged to severely damaged testis structure. Thus, these findings indicated gonadotoxic and cytotoxic effects of MSG on the testis and spermatozoa. Any irregularity in sperm parameters and testicular structure is usually associated with poor fertility rate in men. Testicular size reflects the level of spermatogenic activity, which also affects sperm morphology [11]. In order to further elucidate the severity of the effect of

MSG on spermatogenesis and testis cytoarchitecture, research on prolonged exposure to MSG is recommended.

ACKNOWLEDGMENT

Authors would like to thank Prof. Dr. Noorzan Mohd Noor (professor of linguistics) for proof reading the manuscript. This project was funded by Research Acculturation Grant Scheme (file no.: RAGS/2012/UiTM/ST03/1) awarded by the Ministry of Education Malaysia. Authors would like to acknowledge Research Management Institute (RMI) Universiti Teknologi MARA (UiTM) Malaysia and Faculty of Applied Sciences, Universiti Teknologi MARA (UiTM) Malaysia for their support.

REFERENCES

- [1] Ghosh, S.K., Bhattacharya, T. and Bhakta, A. (2011). "Long term effect of monosodium glutamate in liver of albino mice after neo-natal exposure". *Nepal Medicine College Journal*, 13(1): 11-16.
- [2] John, E. (2006). "A report on the toxic effects of the food additive monosodium glutamate". *FAO/WHO Expert Committee*.
- [3] Zai, H., Kusano, M., Hosaka, H., Shimoyama, Y., Nagoshi, A., Maeda, M. and Mori, K.O. (2009). "Monosodium glutamate added to a high energy, high protein liquid diet promotes gastric emptying". *American Journal of Clinical Nutrition*, 89: 431-435.
- [4] CDC (Centre for Disease Control and Prevention): "Vaccines and Immunizations". Retrieved 25 June 2014. <http://www.cdc.gov/vaccines/pubs/pinkbook/downloads/appendices/B/excipient-table-2.pdf>
- [5] Henneberry, R.C. (2006). "Monosodium glutamate a multibillion dollar flavor enhancer". *Biomedicine Pharmacother*, 60: 86-91.
- [6] Das, R.S. and Ghosh, S.K. (2011). "Long term effects in ovaries of the adult mice following exposure to monosodium glutamate during neonatal life: A histological study". *Nepal Medicine College Journal*, 13(2): 77-83.
- [7] Moore, K.L. (2003). "Congenital malformations due to environment in developing humans". 2nd ed. Philadelphia: W.B Saunders Co. Ltd., 173-183pp.
- [8] Igwebuike, U.M., Ochiogu, I.S., Ihedinihu, B.C., Ikokide, J.E. and Idika, I.K. (2011). "The effect of oral administration of Monosodium Glutamate (MSG) on the testicular morphology and cauda epididymal sperm reserves of young and adult male rats". *Veterinarski Archive*, 81: 525-534.
- [9] Novelli, E. L. B., Diniz, Y. S., Galhardi, C. M., Ebaid, G. M. X., Rodrigues, H. G., Mani, F., ... & Novelli Filho, J. L. V. B. (2007). "Anthropometrical parameters and markers of obesity in rats". *Laboratory animals*, 41(1), 111-119.
- [10] Barnard, L. and Aston, K. (Eds) (2012). "Spermatogenesis: Method and protocol". In S. I. Librach, *Methods of sperm vitality assesment* Toronto, Canada: Humana Press, 927: 13-19pp.
- [11] World Health Organization, Department of Reproductive Health and Research. (2010). "WHO laboratory manual for the examination and processing of human semen" (5th ed.) 287 pages. Geneva, Switzerland: WHO Press.
- [12] Watson, P. F. (2000). "The causes of reduced fertility of cryopreserved semen". *Animal Reproductive Science*, 60/61: 481-482.
- [13] Bjorndhal, L., Soderlund, I. and Kvist, U. (2003). "Evaluation of the one-step eosin- nigrosin staining technique for human sperm vitality assessment". *Human Reproduction*, 18(4): 813-816.
- [14] Bassiri, F, Tavalae, M, and Nasr Esfahani, MH. "Correlation between different patterns of hypo-osmotic swelling and sperm functional tests". *Int J Fertil Steril*. 2013; 7(3): 193-198.
- [15] Moce, E. and Graham, J.K. (2008). "In vitro evaluation of sperm quality". *Animal Reproduction Science*, 105: 104-118.
- [16] Eweka, A.O., Igbigbi, P.S. and Ucheya, R.E. (2011). "Histochemical studies of the effects of monosodium glutamate on the liver of adult wistar rats". *Annals of Medical and Health Sciences Research*, 1: 21-29.
- [17] Ekaluo, U. B., Ikpeme, E. V., & Udokpoh, A. E. (2009). "Sperm head abnormality and mutagenic effects of aspirin, paracetamol and caffeine containing analgesics in rats". *The Internet Journal of Toxicology*, 7(1), 1-9.
- [18] Fransa, L.R., Suescun, M.O., and Miranda, J.R. (2005). "Testis structure and function in a monogenetic hyperadipose rat model at prepubertal and adult ages". *Endocrinology*, 147(3), pp. 1556-1563.
- [19] Hu, J.H., Yang, N., Ma Y.H., Jiang, J., Zhang, J.F., Fei, J. and Guo, L.H. (2004). "Identification of glutamate transporters and receptors in mouse testis". *Acta. Pharmacol. Sin.*, 25: 366-371.