

Automatic Detection of Breast Tumors in Sonoelastographic Images Using DWT

A. Sindhuja, V. Sadasivam

Abstract—Breast Cancer is the most common malignancy in women and the second leading cause of death for women all over the world. Earlier the detection of cancer, better the treatment. The diagnosis and treatment of the cancer rely on segmentation of Sonoelastographic images. Texture features has not considered for Sonoelastographic segmentation. Sonoelastographic images of 15 patients containing both benign and malignant tumors are considered for experimentation. The images are enhanced to remove noise in order to improve contrast and emphasize tumor boundary. It is then decomposed into sub-bands using single level Daubechies wavelets varying from single co-efficient to six coefficients. The Grey Level Co-occurrence Matrix (GLCM), Local Binary Pattern (LBP) features are extracted and then selected by ranking it using Sequential Floating Forward Selection (SFFS) technique from each sub-band. The resultant images undergo K-Means clustering and then few post-processing steps to remove the false spots. The tumor boundary is detected from the segmented image. It is proposed that Local Binary Pattern (LBP) from the vertical coefficients of Daubechies wavelet with two coefficients is best suited for segmentation of Sonoelastographic breast images among the wavelet members using one to six coefficients for decomposition. The results are also quantified with the help of an expert radiologist. The proposed work can be used for further diagnostic process to decide if the segmented tumor is benign or malignant.

Keywords—Breast Cancer, Segmentation, Sonoelastography, Tumor Detection.

I. INTRODUCTION

BREAST Cancer is the second leading cause of cancer deaths for women all over the world and more than 8% women suffer from this disease during their lifetime. According to the latest WHO statistics, cancer causes around 7.9 million deaths worldwide each year. It has been reported that one in four women in the world are affected with breast cancer making breast cancer the most rampant cancer. Of the newly diagnosed ten cancers one is breast cancer. Since the cause of breast cancer is still unknown, early detection is the key to reduce the death rate [2].

Ultrasonography works as an essential tool in diagnosing breast cancer. For mass screening of breast cancer, mammography is used worldwide as a main tool. However, in detecting small cancer, when screening of women with dense breasts, ultrasonography is known to be more useful as it reduces unnecessary biopsies compared to mammography and

conventional ultrasonography [16]. Ultrasonography is generally described as a "safe test" because it does not use ionizing radiation, which imposes hazards, such as cancer production and chromosome breakage. It also has some advantages such as ease of use, mobility, relatively inexpensive and quick performance. In recent years, the degree and distribution of tissue strain induced by tissue compression with an ultrasound device (Ultrasound elastography (UE)) has enabled evaluation with color. Elastography is a relatively new medical imaging technique aimed at examination of elasticity of images subjected to controlled mechanical excitation [10]. A combination of elastography and sonography gives the best result in detecting cancer and potentially could reduce unnecessary biopsy. The real time moving image obtained can be used to guide drainage and biopsy procedures. Unnecessary biopsies not only increase the cost, but also put the patients through emotional trauma. Sonoelastography is different from conventional ultrasound, as a transceiver and a transmitter are used instead of only a transceiver. One transducer which acts as transmitter and receiver is used to image the region of interest. Compared with conventional B-mode sonography, elastography is superior in specificity. Elastography is a technique that maps relative tissue stiffness. Ultrasonographic (US) elastography is a novel modality that is subject of active research, primarily for breast and prostate lesion imaging. Breast and prostate tumors have biomechanical properties different from those of normal tissues: Tumors are usually 30% stiffer than normal tissue [11].

Automated detection of tumor margin in breast elastography is desired for diagnostic purposes. The size and shape of the tumor must be extracted by segmentation to diagnose the stage of the cancer. Texture is used as a main parameter to differentiate the unhealthy tissue from the healthy one. The proposed work concentrates on segmentation based on the texture features extracted from the wavelet decomposed image. In general the number of texture types present in the image is not known in advance. So, an unsupervised or an automatic segmentation is therefore preferred. The texture segmentation is concerned with automatically determining boundaries between various textured regions in an image [17]. Analysis of texture requires the identification of proper attributes or features that differentiate the textures in the image for segmentation and recognition. The features are assumed to be uniform within the regions containing the same textures.

The input image can be transformed into a reduced set of features. Transforming the input data into a set of features is

A.Sindhuja is a research scholar at Department of Computer Science and Engineering, ManonmaniamSundaranar University, Tirunelveli 627021 India (e-mail: a.sin2ja@gmail.com).

V.Sadasivam was with ManonmaniamSundaranar University, Tirunelveli 627021 India. He is now The Principal, PSN college of Engineering and Technology, Tirunelveli 627152 India (e-mail: vs_msu@yahoo.com).

the feature extraction; this describes the data with sufficient accuracy. If the features extracted are carefully chosen it is expected that the features set will extract the relevant information from the input data in order to perform the desired task using this reduced representation instead of the full size input. The features selected by the SFFS technique [14] are used for segmentation by finding the similarity between the adjacent regions. K-Means clustering algorithm [5] separates samples into a predefined number of k clusters by minimizing the total sum of distances between samples and centers of clusters they are assigned to. This paper proposes the segmentation of the image by extracting the feature vector and finding the similarity or dissimilarity between them and choosing the best features for accurate segmentation.

A. Motivation

The motivation for early breast cancer detection is not only to reduce the mortality from this disease, but also to prevent side effects from local symptoms such as swelling of all or part of the breast, skin irritation or dimpling, breast pain, nipple pain, a lump or swelling, bleeding in the nipple and the development of painful metastasis.

With traditional radiology screening techniques, visually analyzing medical images is laborious, time consuming, expensive and each individual scan is prone to interpretation error [6]. Usually a second opinion may be used. Human assistance through second opinion would be costly and impractical and as a result, there has been growing interest in incorporating automated image analysis techniques. Such computer-aided diagnosis systems are considered to be the second reader, which re-analyses the images after the physician. They are designed to objectively quantify pathology in a robust, reliable and reproducible manner.

Since the sixties, texture analysis has been an area of intense research. Texture Analysis is used in medical image analysis, biometric identification, remote sensing, content-based image retrieval, document analysis, environment modeling, texture synthesis and model-based image coding. Most of the texture analysis methods incorporating both spatial frequencies and local edge information tends to be computationally very demanding, especially with large mask sizes and is also affected by varying illumination conditions. To meet the requirements of real-world applications, texture operators should be computationally cheap, robust and simple against variations in the appearance of a texture. Texture features are widely used for classification problems, mainly for diagnostic purposes where the ROI is delineated manually [7], [15]. CADx delineates the tumor boundary automatically, that can be used for diagnosis.

Study of the performance of low-pass filters and adaptive low-pass filters has shown that these filters, although successfully filter much of the speckle, cause loss of details in low-contrast border regions. An alternative method of filtering speckle using sticks is proposed by Czerwinski et al. [3], is also used by Pathak et al. [13] as a smoothing filter and has been implemented with success. Varying the stick lengths and thicknesses gives different filtering effects.

The image is being analyzed at single scale for the texture analysis and can be improved by employing multi scale representations. In the last few decades, wavelet theory has emerged and became a mathematical framework which provides a more formal, solid and unified framework for multi-scale image analysis. Wavelet transform has been applied to various fields of science. The Discrete Wavelet Transform is among the most popularly used wavelet transforms. The Discrete Wavelet Transform (DWT), which is based on sub-band coding, is found to yield a fast computation of Wavelet Transform. It is easy to implement and reduces the computation time and resources required. The discrete wavelet transform is suitable for identifying the fine texture and coarse texture which provides useful information for image processing. The proposed segmentation extracts the texture features from the wavelet transformed image. Literature shows that the wavelet transform has been used in texture analysis [1]. The wavelet decomposition calculates the "resemblance index". The indices are the wavelet coefficients. If the index is large the resemblance is strong. The Daubechies wavelet, the basic and the simplest type of wavelet resembling a step function is used for transformation. For the proposed work Daubechies with a single coefficient to six coefficients are taken at single level decomposition. Using wavelet transforms, the information contained in a digital image is separated into features. The purpose of Segmentation is to find the appropriate features that differentiate the texture types.

Local Binary Pattern (LBP) is a very strong texture discriminator operator. LBP technique describes a very simple, computationally efficient, multiresolution approach to gray-scale and rotation invariant texture classification based on local texture patterns adding complementary information to the "amount" of texture in images. This method is based on recognizing certain local binary patterns, termed uniform, which are the fundamental properties of local image texture. It was first mentioned by Harwood et al. [19] and introduced to the public by Ojala et al. [9]. In a way, the approach is bringing together the separate statistical and structural approaches to texture analysis. It has shown excellent performance in many applications, in terms of both speed and discrimination performance. The approach is very robust in terms of gray-scale variations since the operator is, by definition, invariant against any monotonic transformation of the gray scale. This motivates to represent the UE image using LBP for interpreting the textures. LBP was supplemented by an independent measure of local contrast. These two measures supplement each other in a very useful way.

GLCM, a commonly used method for deriving texture measures from images uses a spatial co-occurrence matrix that computes the relationships between the pixel pairs in the image and uses these values to compute the second-order statistics. Haralick and Shanmugam [4] has proposed a variety of features that can be used to extract useful textural information from local GLCMs and since has been used in various disciplines to quantify patterns within an image. A number of these Haralick features have been proved quite efficient for textural characterization. Eighteen features

extracted from the co-occurrence matrix are used for the proposed work.

All the 19 features are optimized to a reduced feature set. K-Means clustering is the most common algorithm used to cluster the selected features into groups. The Proposed work assists in breast cancer diagnosis and can also be used in determining lesion size.

The paper is organized as follows: Section II describes the methodology involved in the work. Section III presents the detail about the experiments conducted and their corresponding results. Section IV concludes the paper.

II. METHODOLOGY

The representation of the image in the wavelet transform and the texture features used are described in this section. The complete segmentation process is given in Fig. 1.

A. Image Acquisition

Ultrasound elastography images of the breast are acquired using Siemens Acuson Antares ultrasound scanner with a 7.3 MHz linear array transducer. Slight compression is required for acquiring the elasticity image. The effect of breathing and heart beat produces the required compression. Elasticity imaging provides a live dual image display of both the standard B-mode ultrasound image and the elastographic image. The machine provides both the gray scale and color UE image. The Proposed work focuses on the gray scale elastogram images.

B. Pre-processing

Distortions of the echo signals due to tissue compression introduce correlation artifacts in the elastogram. Noise and speckle is present in both the B-mode and elastograms. The image is to be enhanced to improve the quality of the sonoelastograms. The tumor detection is the key todagnosis. For the segmentation process, the tumor boundary detection is the primary step to be performed. It has been shown that the number of false edges can be reduced by modeling edges in ultrasound images as a line process. Using line segments i.e. sticks in different angular orientations as templates and selecting the orientation at each point that is most likely to represent a line in the image, it is possible to significantly reduce speckle and improve edge information in ultrasound images [12]. Stick operation is carried out on the sonoelastographic image to enhance the tumor boundary. The contrast is also enhanced during this procedure.

C. Discrete Wavelet Transform

Wavelets are functions generated from one single function by dilations and translations. The basic idea of the wavelet transform is to represent any arbitrary function as a superposition of wavelets. The 2D wavelet analysis operation consists of filtering and down-sampling using 1-D lowpass filter L and highpass filter H over the rows and columns separately in the image. The 2D Discrete Wavelet Transform (DWT) is being used in a wide range of applications, including numerical analysis, image and video coding, pattern recognition, medical and telemetric imaging, etc. According to DWT decomposition by Mallat [18] the DWT can be viewed as a multiresolution decomposition of signal. This means it decomposes the signal into its components in different frequency bands. First level decomposition is used for the proposed work. In the first level decomposition of 2D DWT the image is divided into four parts. Each part is quarter size the original image, they are approximation (Low-Low LL), Horizontal (Low-High LH), Vertical (High-Low HL), Detail (High-High HH) coefficients. LH, HL, HH represents the finest scale wavelet coefficients, while the sub band LL corresponds to coarse level coefficients. Since the textures have non-uniform gray level variations, they are statistically characterized by the values in the DWT transformed sub-band images or the features derived from these sub-band images or their combinations.

In the standard wavelets, the Daubechies are the most used because of their fast computation and regularity. They give remarkable results due to the efficiency of the transformation coefficients in representing images. Daubechies wavelets are orthonormal, regular wavelets of compact support and are therefore suitable for the analysis of signals with finite support, particularly for image analysis. Among a wide range of wavelets, the Daubechies wavelets include members ranging from highly localized DAUB 2 with two coefficients to highly smooth DAUB 20 with twenty coefficients. Among the family members, the Daubechies 4 (DAUB4) and Daubechies 6 (DAUB6) are popular choices in medical imaging applications. All the wavelet-based techniques used Daubechies 4 wavelet basis and single level of decomposition. For the proposed work DAUB1 to DAUB6 are taken for segmentation at the first level of decomposition. From this the best member and sub-band is selected for the sonoelastographic breast images.

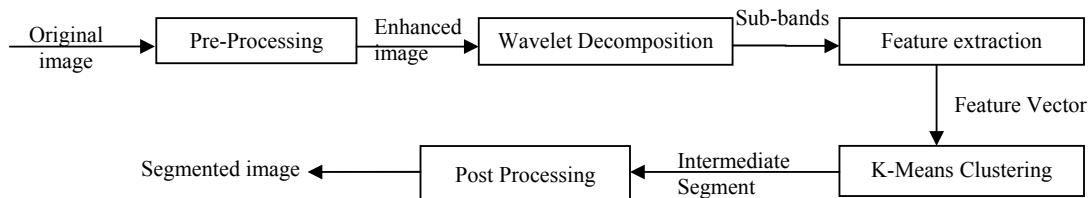


Fig. 1 The Proposed Segmentation methodology

The Daubechies wavelet coefficients are based on computing wavelet coefficients, C_n (where, $n = 0, 1, 2, \dots, N-1$ and N is the number of coefficients) to satisfy the following conditions:

1. The conservation of area under a finite length signal $x(t)$:

$$\sum_n C_n = 2 \tag{1}$$

2. The accuracy conditions:

$$\sum_n (-1)^n n^m C_n = 0 \tag{2}$$

where $m = 0, 1, 2, \dots, p-1$ and $p=N/2$

3. The perfect reconstruction conditions:

$$\sum_n C_n^2 = 2 \tag{3}$$

and

$$\sum_n C_n C_{n+2m} = 0 \tag{4}$$

Then the low-pass filter is $h(n) = \frac{C_n}{2}$ and the high-pass filter is $g(n) = (-1)^{n+1} h(n - N - 1)$.

If the number of multi-resolution levels is too small they cannot sufficiently separate the tumor from the repetitive texture pattern. However, a too large number of multi-resolution levels yields the fusion effect of the anomalies, and may result in false detection.

D. Feature Extraction

The texture features are extracted from the decomposed image. In this technique contrast, variance, uniform and non-uniform pattern over a local region is found at the micro level. Experiments are conducted and results are thus reported.

The multiresolution approach to the gray scale and rotation invariance in textures by using local binary pattern is proposed by Ojala and Pietikainen [8].

The texture T in a local neighbourhood of a monochrome texture image is the joint distribution of the grey levels of P ($P > 1$) image pixels:

$$T = t(g_c, g_o, \dots, g_{p-1}) \tag{5}$$

where the centre pixel of the local neighborhood is g_c and g_p ($p = 0 \dots P-1$) corresponds to the gray values of P equally spaced pixels on a circle of radius R ($R > 0$) that forms a circularly symmetric neighbor set. The coordinates are given by $(-R \sin(2\pi p/P), R \cos(2\pi p/P))$. The gray values of neighbors other than the centre of pixels are estimated by interpolation.

The uniformity measure U , corresponds to the number of spatial transitions that describes the “uniform” pattern. The patterns that have U value of at most 2 is “uniform” and is described as:

$$LBP_{P,R}^{riu2} = \begin{cases} \sum_{p=0}^{P-1} s(g_p - g_c), & U(LBP_{P,R}) \leq 2, \\ P+1, & \text{otherwise.} \end{cases} \tag{6}$$

where,

$$U(LBP_{P,R}) = |s(g_{p-1} - g_c) - s(g_o - g_c)| + \sum_{p=1}^{P-1} |s(g_p - g_c) - s(g_{p-1} - g_c)|$$

Exactly $P+1$ “uniform” binary pattern can occur in a circularly symmetric neighbor set of P pixels. A unique label is assigned to each of the number of “1” bits in the pattern, while the “non uniform” patterns are grouped under the label $(P+1)$. An advantage of the LBP is its computational simplicity as the operator is realized with a few operations in a small neighborhood and a lookup table.

Since the LBP was, by definition, invariant to monotonic changes in gray scale, it was supplemented by an independent measure of local contrast. Pattern information is independent of the gray scale, whereas contrast is not. On the other hand, contrast is not affected by rotation, but patterns are, by default. These two measures supplement each other in a very useful way. The LBP operator was originally designed just for this purpose: to complement a grey-scale dependent measure of the “amount” of texture. The joint distribution of LBP codes and a local contrast measure (LBP/C) is used as a texture descriptor. Rotation invariant local contrast can be measured in a circularly symmetric neighbor set just like the LBP:

$$VAR_{P,R} = \frac{1}{P} \sum_{p=0}^{P-1} (g_p - \mu)^2, \text{ where } \mu = \frac{1}{P} \sum_{p=0}^{P-1} g_p \tag{7}$$

$VAR_{P,R}$ is, by definition, invariant against shifts in the gray scale. Since contrast is measured locally, the measure can resist even intra-image illumination variation as long as the absolute gray value differences are not badly affected. A rotation invariant description of texture in terms of texture patterns and their strength is obtained with the joint distribution of LBP and local variance.

GLCM is the most powerful statistical method for texture analysis based on features extracted from the Co-occurrence matrix. The two dimensional GLCM counts the number of occurrences of a base pixel x and its neighbor y occupying grey levels i, j and their relative position specified by pixel pair distanced and pixel pair angle θ . For an image $I(x,y)$, the i,j th entry of the co-occurrence matrix $GLCM_{ij}$ is defined as

$$GLCM_{ij} = |[x, y]: I(x, y) = i \text{ and } I(x + dx, y + dy) = j| \tag{8}$$

where (dx, dy) is the displacement vector for a given value of displacement angle θ . The pair x and y is contained in a predefined window W , $[x, y] \in W$. The commonly used values are $0, \pi/4, \pi/2$, and $3\pi/4$. The size of the GLCM depends on the number of gray levels used. $GLCM_{ij}$, when divided by the total number of pixel pairs, is the estimate of the joint probability of two pixels, for a given distance d apart along a given direction θ having co-occurring values i and j and is given $p_{ij}(d, \theta)$. The features extracted from GLCM are auto-correlation, contrast, cluster prominence, cluster shade,

dissimilarity, energy, entropy, homogeneity, maximum probability and nine other features.

E. Feature Selection

Sequential Floating Forward Selection (SFFS) Search is used to reduce the feature dimensionality. The extracted feature is optimized by SFFS. SFFS is a fast and powerful method. The redundant and negligible features are removed from the set by SFFS. The SFFS algorithm added one feature at each stage by means of applying the basic sequential forward selection (SFS) procedure starting from the current feature set, followed by a series of successive conditional exclusion of the worst feature in the newly updated set provided a further improvement can be made to the previous sets. Again, the SFFS procedure stopped when a feature subset of fixed cardinality was selected.

F. K-Means Clustering

The next step in segmentation is clustering the features into a number of clusters representing the original texture regions. K-means clustering is used for this purpose. K-means start by assigning the cluster centers to random points in the input set. Then it calculates the distance between the cluster center to its nearest cluster center based on the Euclidean distance. The next step is to re-calculate the cluster centers. The algorithm works iteratively by updating the cluster centers until it converges and no changes can be made. Labeling the clusters finally produces the segmented image.

G. Post Processing

The image attained from the previous step goes through the post-processing phase to remove some of the spurious spots present in the image. Morphological operations such as disk filtering, dilation are performed on the clustered image. The segmented image is then thinned to get a single pixel thickness. This results in the tumor boundary.

H. Evaluation

There is no gold standard for evaluating the results of the medical image segmentation. If the expected result is known in advance there would be a gold standard. The only available standard is the comparison done by the expert observers. Such comparison cannot be considered as gold standard. The segmented results are evaluated using the following metrics: Overlap, Combination metric, and accuracy where S is the system segmented and G is the ground truth.

(i) Overlap (also known as AOM, Jaccard similarity measure, or the Tanimoto coefficient) :

$$P_1 = \frac{|S \cap G|}{|S \cup G|} \quad (9)$$

(ii) Under-Segmentation:

$$P_2 = \frac{|G - (S \cap G)|}{|G|} \quad (10)$$

(iii) Over Segmentation :

$$P_3 = \frac{|S - (S \cap G)|}{|S|} \quad (11)$$

(iv) Combined Metric :

$$P = (P_1 + (1 - P_2) + (1 - P_3)) / 3 \quad (12)$$

Accuracy is the degree to which the segmentation agrees with the truth. Confusion matrix is created to assess the accuracy of the segmentation by comparing the segmentation result with the ground truth. Table I shows the confusion matrix. The accuracy is defined as follows:

$$\text{Acc} = \frac{\text{TP} + \text{TN}}{\text{TP} + \text{FP} + \text{FN} + \text{TN}} \quad (13)$$

TABLE I
CONFUSION MATRIX

Actual Pixel	Unhealthy Tissue Healthy Tissue	Detected Pixel	
		Unhealthy Tissue	Healthy Tissue
	True Pos. (TP)	False Pos. (FP)	
	False Neg. (FN)	True Neg. (TN)	

III. FINDINGS AND DISCUSSIONS

To evaluate whether GLCM features or LBP is suitable for segmentation using Daubechies wavelet; real data of 15 patients are acquired. The images contain both benign and malignant tumor. The parameters such as frequency, depth are same for all the images. The images are then subjected to pre-processing using the sticks filter. Stick filter is applied with stick length 5 and thickness 1. For further enhancement apply sticks again with length 7 and thickness 3. These values are proved to boost the image quality which helps a lot in tumor detection. The enhanced images undergo wavelet decomposition into four sub-bands CA, CH, CV, and CD containing the Approximation, Horizontal, Vertical and Detail Coefficients respectively. The GLCM and LBP features are obtained from each of the sub-band. A sliding window of sub-image block size 3x3 is chosen over the overlapping region in the horizontal direction. The image is interpreted as local texture patterns with radius R=1, and P=8. With the same block size GLCM is obtained from which the features are obtained. Tumor boundary in the breast image is detected by clustering followed by few morphological operations. The number of clusters is known in advance. The initial clusters are taken in random. The results are quantified with the help of an expert radiologist. The graphical representation of the evaluation of the features for each sub-band versus the evaluation metrics are given in Figs. 2-4. Figs. 2-4 show the measure of the overlap, combination metric, and accuracy for each of the sub-bands of the 6 taps of Daubechies wavelet for the GLCM and LBP features. Fig. 2 shows that LBP outperforms GLCM in all the sub-bands. The CV sub-band which has the vertical coefficients of the Daubechies wavelet with two coefficients has the highest overlap measure. This measure shows that LBP in CV sub-band with coefficients is suited for the segmentation of the sonoelastographic breast

images. Fig. 3 too provides the same result as of overlap measure since the over segmentation and under segmentation of the images are negligible. They are approximately the same.

IV. CONCLUSION

Sonoelastographic texture analysis is a very challenging task due to the artifacts present in the image. The features are approximately the same for the same texture region and different if they are from different texture region. The LBP feature proved to segment the image better than the GLCM features. LBP is rotation invariant. So, any texture that cannot be perceptually identified by human vision can be identified by machines. Ojala et al. proved that the LBP is best suited for classification of natural images. The proposed work suggests that the image decomposed by Daubechies wavelet and

interpreted using the LBP technique is appropriate for texture segmentation of sonoelastographic images. CV sub-band with vertical coefficients of Daubechies with two coefficients is suggested among all the sub-bands decomposed using the Daubechies with one co-efficient to Daubechies with six co-efficients. The segmentation method proposed was capable of delineating the lesion contours with high accuracy in comparison to the radiologists' delineations. However this work is in its early stage of development. In the near future this proposed work can be used for classification i.e. for diagnosis purpose also. The proposed work is used to distinguish unhealthy tissue from the healthy one. The same set of features with additional features such as size and shape features, when compared with B-mode image is used to distinguish benign tumor from malignant tumor.

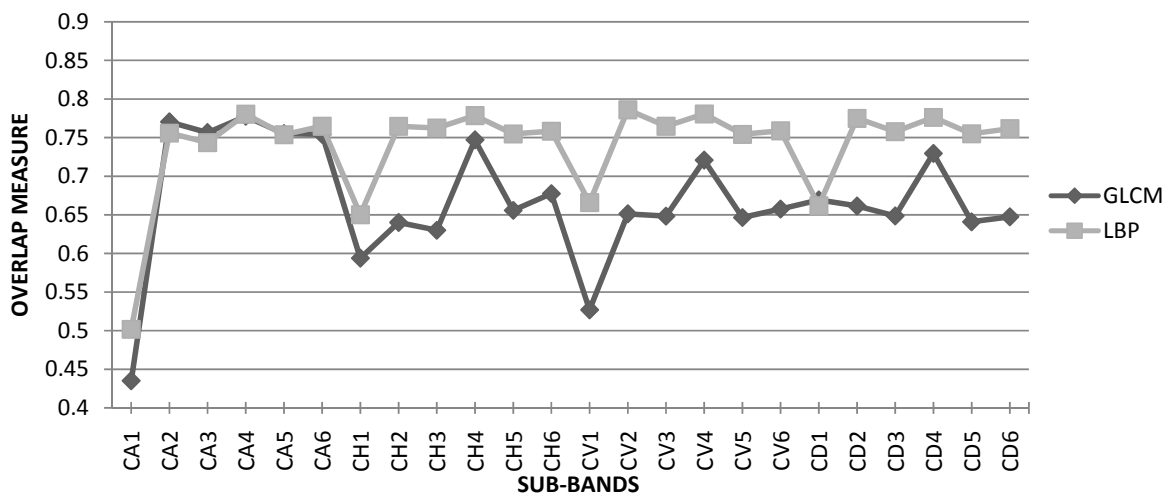


Fig. 2 Overlap measure versus the sub-bands for the GLCM and LBP features

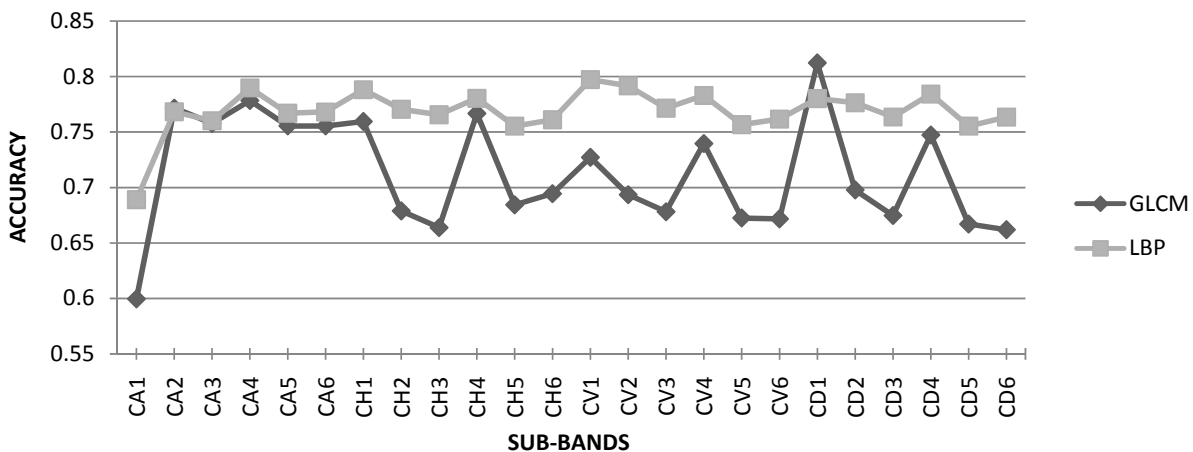


Fig. 3 Combination metric measure versus the sub-bands for the GLCM and LBP features

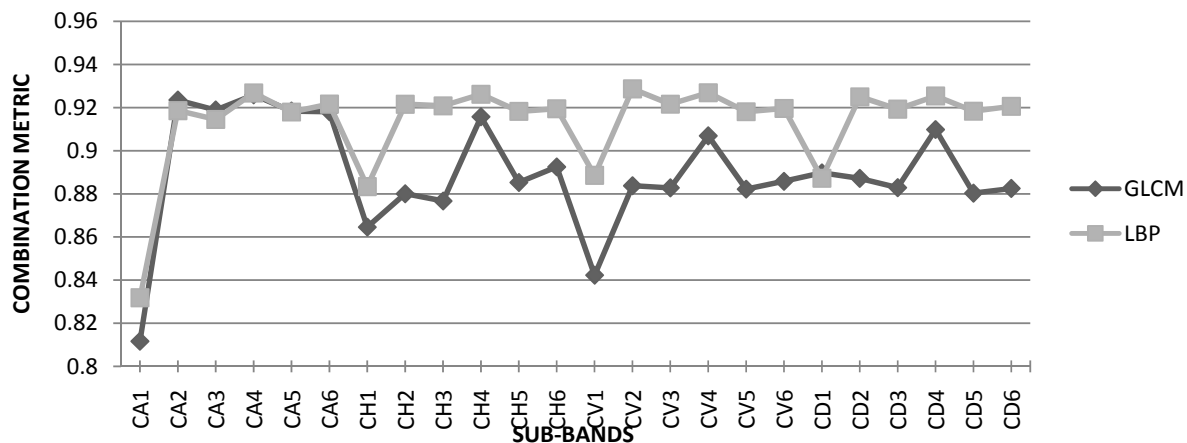


Fig. 4 Accuracy measure versus the sub-bands for the GLCM and LBP features

REFERENCES

- [1] Arivazhagan S, Ganesan L. "Texture classification using wavelet transform," *Pattern RecognLett*, Vol.24, pp.1513-1521, 2003.
- [2] H. Cheng, X. J. Shi, R. Min, L. M. Hu, X. P. Cai, and H. N. Du, "Approaches for automated detection and classification of masses in mammograms," *Pattern Recognition*, Vol. 39, Issue 4, pp. 646-668, 2006.
- [3] R. N. Czerwinski, D.L. Jones, and W. D. O'Brien Jr, "Line and boundary detection in speckle images," *IEEE Trans. on Image Processing*, Vol. 7, Issue 12, pp. 1700-1714, Dec. 1998.
- [4] Robert M Haralick, Shanmugam K, Its'hak Dinstein, "Textural Features for Image Classification," *IEEE Trans. On Systems, Man, and Cybernetics*, Vol. SMC-3 (6): pp. 610 -621, 1973.
- [5] J. Hartigan, M. Wong, "A K-Means clustering algorithm," *Journal of Royal Statistical Society Series C, Applied Statistics*, Vol.28, pp. 100 - 108,1979.
- [6] J. K. T. Lee, "Interpretation accuracy and pertinence," *American College of Radiology*, Vol.4, pp. 162-165, 2007.
- [7] Mojsilovic, M. V. Popovic, A. N. Neskovic, and A. D. Popovicq, "Wavelet image extension for analysis and classification of infarcted myocardial tissue", *IEEETrans.on Biomed. Eng.*, Vol. 44, pp. 856-866, 1997.
- [8] T. Ojala, and M. Pietikainen, "Multiresolution Gray-Scale and Rotation Invariant Texture Classification with Local Binary Patterns," *IEEE transactions on pattern analysis and machine intelligence*, Vol. 24, Issue 7, pp. 971-987, 2002.
- [9] T. Ojala, M. Pietikainen, and D. Harwood, "A comparative study of texture measures withclassification based feature distributions," *Pattern Recognition*, Vol. 29, Issue 1, pp. 51-59, 1996.
- [10] J. Ophir, I. Cespedes, H. Ponnekanti, Y. Yazdi, and X. Li, "Elastography: a quantitative method for imaging the elasticity of biological tissues," *Ultrasonic Imaging*, Vol. 13, pp. 111-134, 1991.
- [11] Parkin, D.M., F. Bray, J. Ferlay and P. Pisani, "Global cancer statistics," *CA Cancer J. Clin.*, Vol. 55, pp. 74-108, 2005.
- [12] S. D. Pathak, P. D. Grimm, V. Chalana, and Y. Kim, "Pubic arch detection in transrectal ultrasound guided prostate cancer therapy," *IEEETrans. Med. Imag.*, Vol. 17, pp. 762-771, Oct. 1998.
- [13] S. D. Pathak, V. Chalana, D. R. Haynor, Y. Kim, "Edge-guided boundary delineation in prostate ultrasound images," *IEEE Trans. Med. Imaging*, Vol. 19, Issue 12, pp. 1211-1219, 2000.
- [14] P. Pudil, J. Novovicova, J. Kittler, "Floating search methods in feature selection," *Pattern Recognition Lett.*, Vol.15, pp.1119 -1125, 1994.
- [15] Shirley Selvan, M. Kavitha, S. Shenbagadevi, and S. Suresh, "Feature Extraction for Characterization of Breast Lesions in Ultrasound Echography and Elastography," *Journal of Computer Science*, Vol. 6, Issue 1, pp. 67-74, 2010.
- [16] H. Zhi, B. Ou, B. M. Luo et al. "Comparison of Ultrasound Elastography, Mammography, and Sonography in the Diagnosis of Solid Breast Lesions," *J Ultrasound Med*, Vol. 26, Issue 6, pp. 807-815, 2007.
- [17] R. Jain, R. Kasturi, and B. G. Schunch, *Machine Vision*, McGraw Hill, pp. 234-240, 1995.
- [18] S. Mallat, "A Wavelet Tour of Signal Processing: The sparse way," Academic Press, 1999.
- [19] D. Harwood, T. Ojala, M. Pietikainen, S. Kelman, and S. Davis, "Texture classification by center-symmetric auto-correlation, using Kullback discrimination of distributions," Technical report, Computer Vision Laboratory, Center for Automation Research, University of Maryland, CAR-TR-678, 1993.

Sindhuja obtained her B.Sc. (Computer Science) degree from Manonmaniam Sundaranar University, Tirunelveli, Tamilnadu, India in 2001 and M.C.A. degree from Madurai Kamaraj University, Madurai, Tamilnadu, India in 2004. Completed her M.Phil.(Computer Science) degree from Madurai KamarajUniversity, Madurai, Tamilnadu, India in 2006. Currently pursuing research in the field of image processing in Manonmaniam Sundaranar University, Tirunelveli, Tamilnadu, India. Her areas of interests are Image processing, Remote Sensing.

V. Sadasivam did his B.E. in Electrical and Electronics Engineering in 1973 in Thiagarajar College of Engineering, Madurai, Tamilnadu, India. He completed his M.Sc (Power Systems) in 1975 from Coimbatore Institute of Technology, Coimbatore, Tamilnadu, India. He obtained his Ph.D in 1993 from Anna University. Currently he is the Principal of PSN Institute of Technology, Tirunelveli, Tamilnadu, India. He is a retired Professor and Head in the Department of Computer Science and Engineering from ManonmaniamSundaranar University, Tirunelveli, Tamilnadu, India. His areas of interest are Artificial Intelligence, Image Processing, and Neural networks.