

Automatic Detection and Classification of Diabetic Retinopathy Using Retinal Fundus Images

A. Biran, P. Sobhe Bidari, A. Almazroo V. Lakshminarayanan, K. Raahemifar

Abstract—Diabetic Retinopathy (DR) is a severe retinal disease which is caused by diabetes mellitus. It leads to blindness when it progress to proliferative level. Early indications of DR are the appearance of microaneurysms, hemorrhages and hard exudates. In this paper, an automatic algorithm for detection of DR has been proposed. The algorithm is based on combination of several image processing techniques including Circular Hough Transform (CHT), Contrast Limited Adaptive Histogram Equalization (CLAHE), Gabor filter and thresholding. Also, Support Vector Machine (SVM) Classifier is used to classify retinal images to normal or abnormal cases including non-proliferative or proliferative DR. The proposed method has been tested on images selected from Structured Analysis of the Retinal (STARE) database using MATLAB code. The method is perfectly able to detect DR. The sensitivity specificity and accuracy of this approach are 90%, 87.5%, and 91.4% respectively.

Keywords—Diabetic retinopathy, fundus images, STARE, Gabor filter, SVM.

I. INTRODUCTION

DR is one of the most common causes of blindness for patients who suffer from diabetes mellitus which damages retinal capillaries and blood vessels. This damage results in formation of microaneurysms (MA) and hemorrhages inside the retina, the light sensitive tissue at the back of the eye. Another indication of DR is the existence of hard exudates within the retina. Fig. 1 shows the various abnormalities found in retinal images. As the disease progress, new abnormal blood vessels grow in the retina. This mechanism is called neovascularization. DR falls into two main categories of non-proliferative diabetic retinopathy (NPDR) and proliferative diabetic retinopathy (PDR). PDR falls into categories of mild, moderate and severe. When abnormal blood vessel grows in the eye, the disease is proliferative. When the disease lacks of abnormal blood vessels growth, it is non-proliferative. The PDR has serious visual problems that lead to blindness [3]. In fact, patients with diabetes mellitus do not suffer from any vision problems in the early stages. Therefore, they should undergo an annual eye exam because early diagnose of this disease is very important to prevent them from blindness.

A. Biran and P. Sobhe Bidari are with the Electrical and Commuter Engineering Department, Ryerson University, Canada (e-mail: abiran@ryerson.ca, pooya.sobhebidari@ryerson.ca).

A. Almazroo is with the Optometry and Vision Science Department, University of Waterloo, Canada (e-mail: aalmzro@uwaterloo.ca).

V. Lakshminarayanan is a professor at the Optometry and Vision Science Department, University of Waterloo, Canada (e-mail: vengu@uwaterloo.ca).

K. Raahemifar is a Professor at the Electrical and Commuter Engineering Department, Ryerson University, Canada (e-mail: kraahemi@ee.ryerson.ca).

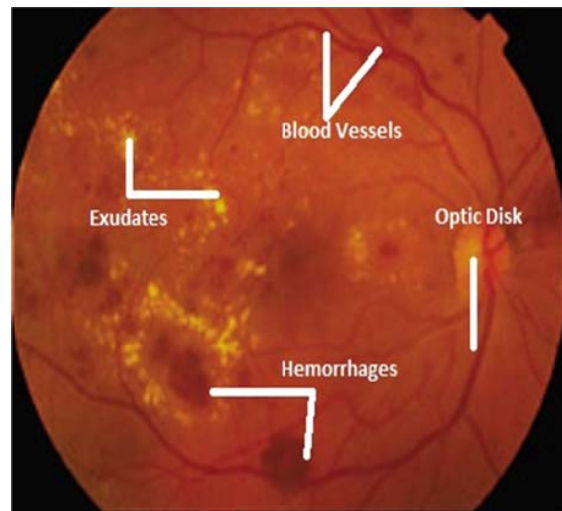


Fig. 1 Fundus image with lesions

II. RELATED WORK

Several image processing techniques have been used to detect and classify DR. In [1], authors have developed a method to detect MA, which are the first clinical sign of DR using morphological operations. Then, SVM is used to classify the image to normal retina, mild PDR or severe PDR. On the other hand, another automatic algorithm for detecting MA has been proposed by using different image processing techniques including adaptive histogram equalization and thresholding [2]. The used algorithm classifies the input image to normal retina or NPDR. The NPDR is also classified into mild, moderate or severe based on the number of detected MA.

Tjandrasa et al. focused to classify NPDR based on segmented exudates using K-Means clustering [4]. In order to have better accuracy, three various classifiers were used including SVM, Multilayer Perceptron and Radial Basis Function Network. Multilayer Perceptron classifier has shown the best accuracy. Kleawsirikul et al. [5] presented an automated algorithm based on morphological Top Hat transform for extracting hemorrhages which were classified using rule based classification. In addition, an automatic detection of NPDR has been proposed [3]. It is based on contrast enhancement, histogram equalization color normalization, thresholding, median filter and morphological erosion techniques. Moreover, Sundhar and Archana [6] proposed automatic screening of fundus images in order to detect DR. Their developed method perfectly detects the size of exudates and MA. The used images were classified by artificial

neural networks.

III. PROPOSED ALGORITHM

In this paper, an automatic algorithm for detection and classification of DR has been proposed. The inputs of the proposed method are colored RGB images from STARE database. First, the algorithm starts with preprocessing stage which is based on several image processing techniques including green channel extraction, CHT, CLAHE and thresholding. Then, hemorrhages and exudates are extracted using Gabor filter, thresholding and CHT. After that, six features are defined as the input for the last stage which is classification of the INPUT image into normal retina, NPDR or PDR. The classification process is done by using SVM. Fig. 2 shows the block diagram of this approach. Following is the explanation of the proposed method.

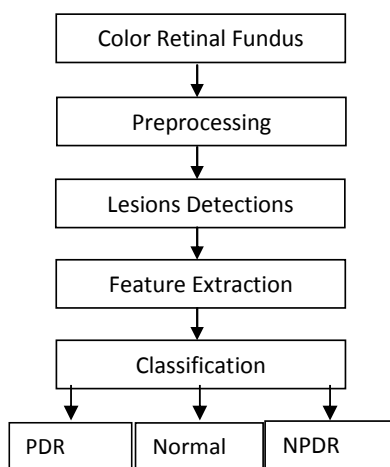


Fig. 2 Block Diagram of the proposed method

A. Fundus Images

Fundus images contain information about the internal structures of the human eye including the retina, OD, macula, fovea and blood vessels [7]. In this project, images from STARE database are used. This database has 400 retinal images of different types of DR and other eye disorders. In this project, the best 33 DR images are selected.

B. Preprocessing

Preprocessing is the primary step in any retinal fundus images. It usually focuses on removing central light reflex, background homogenization and image enhancement. The advantages of enhancing the image include better display, easier analysis and noise reduction. Additionally, image preprocessing aims to clarify the image and to simplify the feature extraction process. Moreover, image enhancement eliminates the effect of the optic disc, and it increases the image contrast from the background. A green channel is usually used for image preprocessing because the green channel has the best contrast between image and its background. In this stage, first green channel image is extracted. Then, the eye is detected using CHT. The main goal

of eye extraction is to eliminate the background and its distractive noise. The optic disc (OD) and exudates are similar in color; however, they are different in size. Therefore, the optic disc is also detected and eliminated using CHT. Lastly, the green channel image and the OD eliminated image are combined using CLAHE for the purpose of image enhancement.

C. Lesions Detection

DR has three main signs which are MA, hemorrhages and hard exudates. MA is a small swelling that forms on the side of tiny blood vessels [8]. They are the first clinical signs of DR. Hemorrhages is a bleeding that occurs inside the retina. It is a retinal disorder that could cause severe vision problems [9]. Exudates are a yellowish fluid rich in protein that oozes out of the blood vessels as a result of inflammation [10]. They are the main causes of blindness in NPDR types.

In this project, the two dimensional Gabor filter is used to extract blood vessels and exudates from the preprocessed image. Then, thresholding method is used to detect DR lesions. Hemorrhages and blood vessels are very similar in intensity. Therefore, an optimized threshold was determined to extract them from the preprocessed image. However, hemorrhages and blood vessels have different shapes. The former ones are usually appear in circular or semicircular shapes. Therefore, CHT is used to detect hemorrhages.

Since exudates are the brightest parts of the image, an optimized threshold was obtained to extract them from the Gabor filter image.

D. Feature Extraction

The resulted image out of the previous stage is used for feature extraction. The total number of extracted features is 31. However, only six effective features are selected for the SVM classifier. These features are the images of green channel, CLAHE, Gabor filter and preprocessing stage. Also images of extracted hemorrhages and hard exudates are defined as inputs for SVM.

E. Classification

SVM is a method used for data classification. It constructs a hyperplane to separate the input data linearly into different classes. The classification parameters are defined based on the calculated features. In the cases of nonlinear data, the training data are mapped into high dimensional feature space using a nonlinear kernel function. Then, the data can be classified linearly.

In this stage, SVM is used to classify the input DR images to classes named as normal retina, NPDR or PDR. SVM is a supervised learning algorithm that analyzes the selected images from STARE database. 23 DR images are selected for training the SVM. The remaining 10 images are used to measure the performance of the proposed method.

IV. RESULTS

The performance of the proposed method is measured in terms of sensitivity, specificity and accuracy. While sensitivity

is the ratio of abnormal images classified correctly, specificity is the ratio of normal images classified correctly. Accuracy is the ratio of the total number of correctly classified images to the total number of images. Table I shows the results of the performance measurements with a comparison to the other algorithms. The equations used for performance measurements are:

$$\text{Accuracy} = \frac{TP+TN}{TP+FP+TN+FN} \tag{1}$$

$$\text{Sensitivity} = \frac{TP}{TP+FN} \tag{2}$$


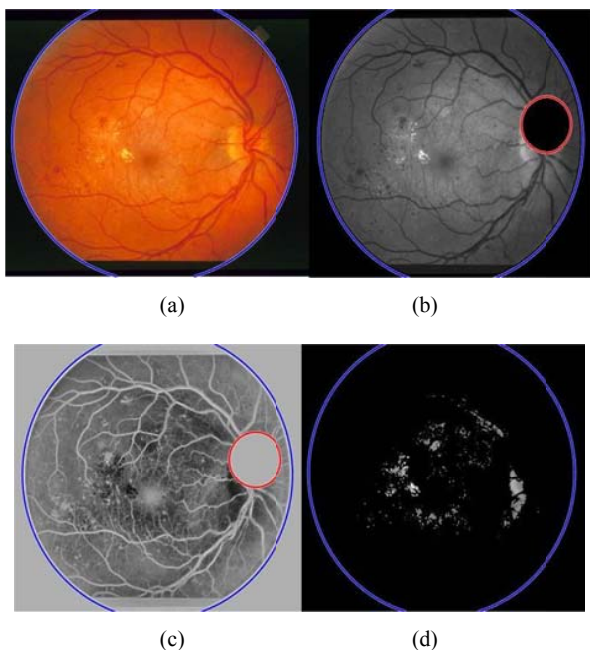
$$\text{Specificity} = \frac{TN}{TN+FP} \tag{3}$$

where, TP is the abnormal image is correctly classified as abnormal, TN is the normal image is correctly classified as normal, FP is the normal image is incorrectly classified as abnormal, FN is the abnormal image is incorrectly classified as normal.

Figs. 3 and 4 show the process of detecting NPDR and PDR respectively using the proposed method. Fig. 5 shows the resulted images out of applying the proposed method on normal retinal image.

TABLE I
RESULTS OF THE PERFORMANCE MEASUREMENTS

Method	Sensitivity	Specificity	Accuracy
Aravind et al [1]	92%	80%	90%
Latha et al [3]	97.2%	94%	96.2%
Proposed method	93.2%	87.5%	94.4%



(e)

Fig. 3 The process of detecting NPDR (a) Retinal Image with NPDR, (b) Preprocessed Image, (c), Gabor Filter Image, (d) Extracted Exudates Image, (e) Extracted MA and Hemorrhages Image.

V.DISCUSSION AND CONCLUSION

Early detection of DR prevents patients from blindness. In the past years, many papers have developed algorithms to detect DR. In this project, an automatic method for DR detection and classification has been proposed. It is based on a combination of several image processing techniques including CHT, CLAHE, thresholding, Gabor filter and SVM. The developed method perfectly detects DR. it is also cable of classifying DR to NPDR or PDR. The proposed method has shown good performance measurements. The sensitivity, specificity and accuracy of the proposed method are 93.4%, 87.5% and 94.4% respectively. In future works, the proposed algorithm can be used for automatic DR diagnosis purposes.

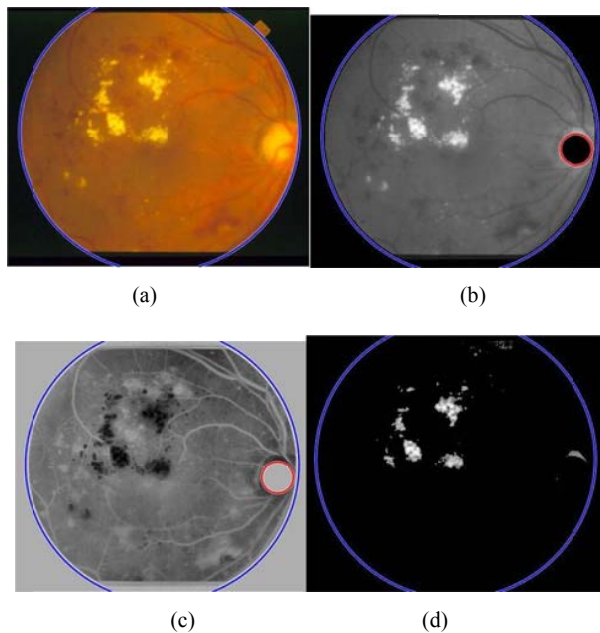
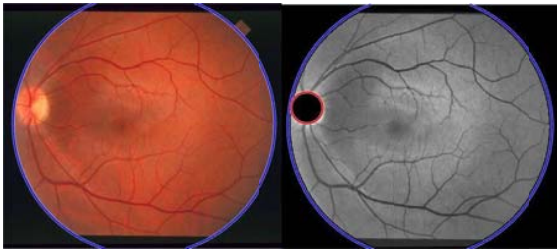
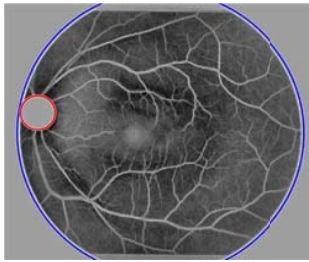


Fig. 4 The process of detecting PDR (a) Retinal Image with PDR, (b) Preprocessed Image, (c), Gabor Filter Image, (d) Extracted Exudates Image



(a)



(b)

Fig. 5 Results of applying the proposed method on normal image (a) Retinal Image and Preprocessed Image, (b), Gabor Filter Image

ACKNOWLEDGMENT

The Saudi Arabian Cultural Bureau in Ottawa is the main sponsor of this research paper. The authors are thankful to the bureau.

REFERENCES

- [1] C. Aravind, M.PonniBala and S.Vijayachitra, "Automatic Detection of Microaneurysms and Classifications of Diabetic Retinopathy Images using SVM Technique," *International Journal of Computer Applications*, pp. 18-22.
- [2] S. SujithKumar and S. Vipula, "Automatic Detection of Diabetic Retinopathy in non-detailed RGB Retinal Fundus Images," *International Journal of Computer Applications*, vol. 47, pp. 26-32, June 2012.
- [3] K. sangramsing, M. Raju, B. Suvarnsing and K. Charansing, "Non-proliferative Diabetic Retinopathy detection using automatic image processing technique," *Journal of Pharmacy and Biological Sciences*, vol. 10, pp. 33-38, December 2015.
- [4] T. Handayani and A. Ayse, "Classification of Non-Proliferative Diabetic Retinopathy Based on Segmented Exudates using K-Means Clustering," *International Journal Image, Graphics and Signal Processing*, pp. 1-8.
- [5] N. Kleawsirikul, S. Gulati and B. Uyyanonvara, "Automated Retinal Hemorrhage Detection using Morphological Top Hat and Rule-based Classification," *3rd International Conference on Intelligent Computational Systems*, April 2013.
- [6] C. Sundhar and D. Archana, "Automatic Screening of Fundus Images for Detection of Diabetic Retinopathy," *International Journal of Communication and Computer Technologies*, vol. 2, April 2014.
- [7] H. Li, and O. Chutatape, "Fundus image features extraction," *22nd Annual EMBS International Conference*, "Chicago, vol. 4, pp. 3071-3073, July 2000.
- [8] R A Simandjuntak, A B Suksmo, T L R Mengkoand and I Sovani "Development of computer-aided diagnosis system for early diabetic retinopathy based on microaneurysms detection from retinal images", *7th International workshop on Enterprise networking and Computing in Health Care Industry*, pp.364-367, 2005.
- [9] A. Usman , S. Khalid, and S. Khan "Identification and classification of microaneurysms for early detection of diabetic retinopathy", *The Journal of the Pattern Recognition Society*, pp.1-11, 2012.
- [10] W. Thomas, M. Pascal, E Ali, O. Ricahrd, J.Clotilde and K. Jean-Claude "Automatic detection of microaneurysms in color fundus images" *International Journal of Medical Image Analysis*, pp.555-566, 2007.