

Termination of the Brachial Artery in the Arm and Its Clinical Significance

Ramya Rathan, Miral N. F. Salama

Abstract—The variations in the arteries have been drawing attention of anatomists for a long time because of their clinical significance. The brachial artery is the principal artery of the arm which is the continuation of the axillary artery from the lower border of the Teres Major. It terminates into the radial and ulnar arteries below the elbow joint at the neck radius. The present study aims at exploring the clinical significance of the high termination of the brachial artery. During the routine cadaveric dissection of the arm, for the undergraduate students of medicine at our university, we observed a high bifurcation of the radial and the ulnar artery at the midshaft of the humerus. The median nerve was seen passing between these two junctions. Further, the course and the relations of this artery were studied. The accurate knowledge regarding these kinds of variation in the blood vessels is mandatory for planning of designing. General physicians, surgeons and radiologists should keep in mind the variations in the branching pattern of the arteries in their daily medical, diagnostic and therapeutic procedures to avoid complications in diagnostic and surgical procedures.

Keywords—Brachial artery, high termination, radial artery, ulnar artery.

I. INTRODUCTION

THE brachial artery is the artery which supplies the arm. It is the continuation of the axillary artery from the distal border of the Teres Major and ends at the level of the radius in the cubital fossa just medial to the bicipital aponeurosis. At its origin, the brachial artery lies medial to the humerus but then spirals anterior to it until it lies midway between the humeral epicondyles. The brachial artery is easily palpable as it is covered by the skin, superficial and deep fasciae [1]. At the neck of the radius, the artery terminates into the radial and ulnar arteries (Fig. 1 (A)). Other branches taking origin from the brachial artery are profunda brachii artery, superior ulnar collateral artery, inferior ulnar collateral artery, muscular branches and nutrient artery to humerus. The median nerve is closely related to the brachial artery. It crosses the artery anteriorly from lateral to medial side in the middle of the arm [2].

A detailed knowledge of the vascular pattern of upper limbs especially the variations in their origin, course and branching pattern is of most importance anatomically and clinically. These variations have drawn attention of various clinicians and interventionists due to the advanced surgical procedures practiced in vascular surgeries, plastic (reconstructive) surgeries and also for diagnostic and therapeutic approaches. So, a detailed study of brachial artery and its branching pattern

in upper limbs would be of use to anatomists, surgeons and radiologists to identify abnormalities through invasive and noninvasive methods [3], [4]. The aim of this study is to report the termination of the brachial artery in the arm and to signify its importance in various clinical procedures.

II. CASE REPORT

During the routine cadaveric dissection of the arm, for the undergraduate students of medicine at our University, we observed a high origin of bifurcation of the brachial artery. The skin and the fascia of the axilla was carefully dissected and the neurovascular bundle was studied. The brachial artery immediately at the mid shaft of the humerus divided into radial and ulnar artery (Figs. 1 (B) and 2). The other branches in the brachial artery appeared normal. Both the radial and the ulnar arteries ran superficially in the arm along the medial side of the biceps brachii. The median nerve was seen crossing the radial artery from lateral to the medial side as it was going towards the cubital fossa (Fig. 3). The radial artery passed through the apex of the cubital fossa and then was seen to continue superficially in the forearm while the ulnar artery passed deep to the pronator teres muscle (Fig. 4). The photograph of the variation of the brachial artery was taken for proper documentation and there was no other neuromuscular variation seen in the specimen.

III. DISCUSSION

Variations of arteries in the upper extremities are quite common and were first noted by Von Haller in 1813 [5], [6]. Variations can be found at different regions along the axillary, brachial, radial, ulnar and also the palmar arches of the hand [7]. These variations can be explained on the basis of embryogenic development of the limb buds. Defects in the growth of the vascular plexus during the embryonic development can cause variations in the blood vessels [8]. Every anomaly which is seen in the peripheral vascular anatomy is related to genesis, regression or persistence of one or other segment of the embryologic axial artery [9], [10]. During intra-embryonic life, the 7th cervical intersegmental artery of the dorsal aorta gave a lateral branch for the upper limb bud which is called the primary axis artery. The proximal part of the axis artery gives rise to axillary and brachial arteries respectively, while the distal part becomes anterior interosseous artery. The anterior interosseous gives rise to median artery which will disappear later. Moreover, before the elbow region, the primary axis artery gives rise to radial and ulnar arteries. The axis artery ends in the hand region as capillary plexus which will ultimately give rise to the digital

Ramya Rathan is Gulf Medical University, United Arab Emirates (e-mail: drramyasoans@gmail.com).

arteries [11].

The highest percentage of variations of brachial artery is seen with the high origin of radial and ulnar artery. High origin of radial artery occurrence is 3 to 15 %, as reported by different authors [12]-[16]. Gupta et al. reported about an unusually short segment BA with bifurcation proximal at the level of insertion of coracobrachialis in 2 out of 20 cadavers [17]. The uneven course of artery in relation to the median nerve which was seen in this case can also lead to compression of the median nerve in the lower part of the anterior

compartment of the arm [18], [19]. In the present case, the radial artery had a high origin and also could be called as superficial brachioradial artery since it was seen having a course superficial to the flexors. This could be explained by the haemodynamic mechanism between the superficial and the deep arteries in the forearm. Normally, the superficial terminal branches of radial artery undergo developmental arrest and deep part persists as normal radial artery [20]. In our case, the deep part of the artery underwent regression and the superficial part persisted.

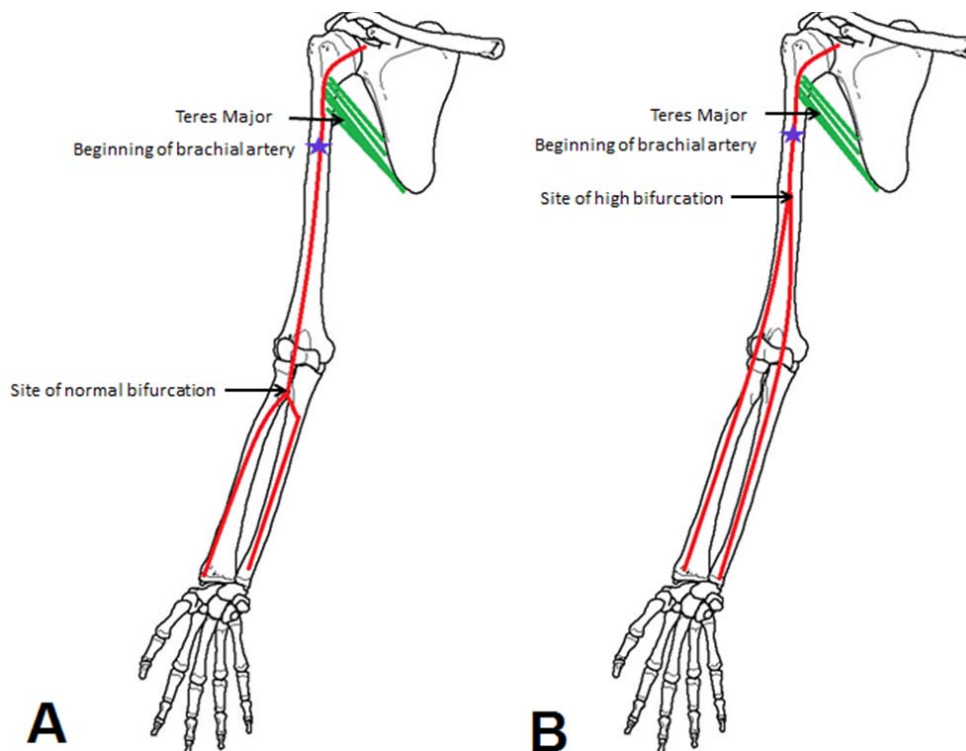


Fig. 1 Diagrammatic Representation of the normal (A) and the highly bifurcated Brachial Artery (B)

Brachial artery can also bifurcate proximally and can reunite to form a single trunk. It trifurcates proximally into radial, ulnar and common interosseus arteries. Sometimes slender vasa aberrantia connect the brachial artery to the axillary artery or to one of the forearm arteries usually the radial [21].

IV. CLINICAL SIGNIFICANCE

The recognition and documentation of expansion variation in the course, distribution and branching pattern of the arteries of upper limb is highly considerable in the angiographic and surgical practice [22]. Many cases that suffer from chronic renal failure are encountered every day. High percentage of those cases is treated with blood dialysis which is mainly dependent on creation of AV fistula. The fistula preferably is done between cephalic vein and radial artery and if there is a problem like calcification or narrowing of radial artery; a fistula between brachial artery and cephalic vein is created as

second choice [23].

The higher division of the brachial artery seeks a greater clinical significance. Variations in the arteries of this region may be encountered during arteriography test, percutaneous brachial catheterization, and skin flap elevations from the arm or forearm. Accidental intra-arterial injections into the brachial artery may lead to bleeding, thrombosis, and also the loss of the upper limb. The bifurcation of the brachial artery is also the commonest site for embolism and a higher bifurcation would result in a larger area of ischemia than expected.

V. CONCLUSION

Variations in the branching pattern of the arteries can affect routine clinical procedures. The micro-vascular reconstructive surgeries use various advanced techniques to get better results. In congenital and inflammatory diseases, the study of the basic gross anatomy is important for understanding the circulation of the blood flow in the extremities. The variations in the

brachial artery can cause difficulty while measuring the blood pressure. Also due to the superficial course of the radial artery, it can be mistaken as a vein and can also be injured easily by trauma. Doppler ultrasound imaging and angiographic images are of considerable importance during invasive and noninvasive investigative procedures due to these kind of variations [24]. It is never feasible for a clinician to have a full image of the branching pattern for every patient who visits the clinic and therefore it is clinically very important to have an accurate knowledge and a documentation of these kinds of patterns of variations before initiating any procedure so as to reduce mortality and morbidity.

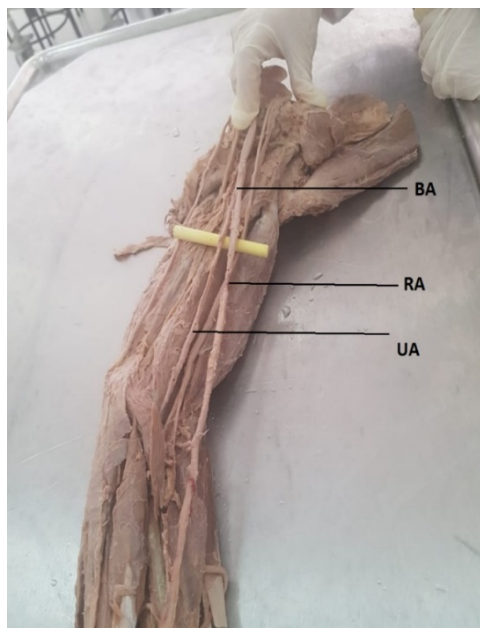


Fig. 2 Dissection of the Left Upper limb showing high termination of the Brachial artery into radial and Ulnar (BA: Brachial Artery, UA: Ulnar artery, RA: Radial Artery, MN: Median Nerve)

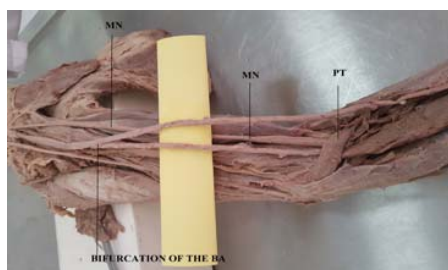


Fig. 3 Course of the Median nerve crossing the radial artery from lateral to medial side (MN: Median Nerve, BA: Brachial Artery, PT: Pronator Teres)

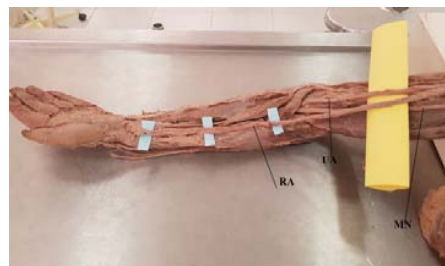

Fig. 4 Superficial course of the Radial artery (UA: Ulnar artery, RA: Radial Artery, MN: Median Nerve)

ACKNOWLEDGMENT

Author acknowledges the help received from the scholars whose articles are cited and included in references of this manuscript. The author is also grateful to authors / editors / publishers of all those articles, journals and books from where the literature for this article has been reviewed and discussed.

REFERENCES

- [1] Standring S. Gray S (2008) Anatomy (40th Edn) Spain, Churchill Livingstone, Elsevier pp: 830-835.
- [2] Williams PL. Gray's anatomy. 38th ed. Philadelphia: Elsevier Churchill Livingstone; 1995.
- [3] Chummy S, Sinnatamby. Vessels and Nerves of Arm: Brachial Artery in Last's Anatomy regional and applied. Churchill Livingstone. 2006; 11: 61.
- [4] Hollinshead WH. Anatomy for Surgeons. New York: Harper and Row Publishers; 1969; 2: 150-152.
- [5] Bidarkotimath S, Avadhani R, Kumar A. Primary pattern of arteries of upper limb with relevance to their variations. Int. J. Morphol. 2011; 29(4). p. 1422-1428.
- [6] Bidarkotimath S, Avadhani R, Kumar A. An anatomical study of primary pattern of arteries of upper limb with relevance to their variations. NUJHS. 2012; 2(1) p. 08-14.
- [7] Dong Zhan, Yi Zhao, Jun Sun, Eng-Ang Ling, George W Yip (2010) High origin of radial arteries: a report of two rare cases. The Scientific World Journal 10: 1999-2002.
- [8] Sikka A, Jain A. Bilateral variation in the origin and course of the vertebral artery. Anatomy Research International. 2012; 2012:1-3. (DOI:10.1155/2012/580765).
- [9] Baeza AR, Nebot J, Ferreira B et al. An anatomical study and ontogenic explanation of 23 cases with variations in the main pattern of the human brachio-antebrachial arteries. J Anat 1995; 187:473-39.
- [10] Anuradha L, Prabhu LV, Kumar A. Report on an anomalous pattern in the upper limb with its anatomical and clinical implication. J Anat Soc India, 2001; 50 (1):69-98.
- [11] Keith L Moore, Persaud T V N, Mark G Torchia. Before we are born: Essentials of embryology and birth defects. 8th Edition. Saunders; 2012. ISBN: 978-1437720013.
- [12] Anson, B. J: Morris. Human Anatomy in; The cardiovascular system- Arteries and veins. Thoms, M. Edr. Mc Grow Hill Book c. New York. pp708-724(1966).
- [13] De Garis CF, Swartley WB. The axillary artery in white and Negro stocks. Am J Anat. 1928; 41: 353-97.
- [14] Muller E (1903) Beitrage zur Morphologie des Gefaßsystems. I. Die Armarterien des Menschen. Anatomische Hefte 22,377-575.
- [15] Karlsson S, Niechajev I A (1982) Arterial anatomy of the upper extremity. Acta Radiologica 23, 115-121.
- [16] Kian K, Shapiro JA, Salman L, et al. High brachial artery bifurcation: clinical considerations and practical implications for an arteriovenous access. (Semin Dial. 2012; 25(2):244-247.
- [17] Gupta J, Jain R, Patil M. A study of brachial artery with high up division and its clinical significance. Int J Bioassays 2012; 1: 116-8.
- [18] Chakravarthi KK. Gantzer's muscle an accessory muscle of the forearm -Its Anatomical Variations and Clinical Insight. Int J Chemical and Life Sciences. 2013; 02: 1199-1203.

- [19] Fuss FK, Matula CW, Tschabitscher M. Die Arteria brachialis superficialis. *Anatomischer Anzeiger* 1985; 160: 285-94.
- [20] Singer E. Embryological pattern persisting in the arteries of the arm. *Anat Record* 1933;55:403-9.
- [21] Williams PL, Bannister LH, Berry M. N, Collins P, Dyson M, Dussek JE, Ferguson MWJ. *Gray's Anatomy*. 38th Ed. New York: Churchill Livingstone, 1995. 1538-15407.
- [22] Adib A Aughsteen, Hasan M Hawamdeh, Muzahim Al-KHAYAT (2011) Bilateral variations in the branching pattern of brachial artery. *International Journal of Anatomical Variation* 4:167-170.
- [23] Clinical practice guidelines for vascular access. *Am J Kidney Dis*. 2006;48 Suppl 1: S176-247.
- [24] Okoro IO, Jiburum BC, Rare high origin of the radial artery: A bilateral, symmetrical case. *Niger J Surg Res* 2003; 5: 70-2.