

Thermalytix: An Advanced Artificial Intelligence Based Solution for Non-Contact Breast Screening

S. Sudhakar, Geetha Manjunath, Siva Teja Kakileti, Himanshu Madhu

Abstract—Diagnosis of breast cancer at early stages has seen better clinical and survival outcomes. Survival rates in developing countries like India are very low due to accessibility and affordability issues of screening tests such as Mammography. In addition, Mammography is not much effective in younger women with dense breasts. This leaves a gap in current screening methods. Thermalytix is a new technique for detecting breast abnormality in a non-contact, non-invasive way. It is an AI-enabled computer-aided diagnosis solution that automates interpretation of high resolution thermal images and identifies potential malignant lesions. The solution is low cost, easy to use, portable and is effective in all age groups. This paper presents the results of a retrospective comparative analysis of Thermalytix over Mammography and Clinical Breast Examination for breast cancer screening. Thermalytix was found to have better sensitivity than both the tests, with good specificity as well. In addition, Thermalytix identified all malignant patients without palpable lumps.

Keywords—Breast Cancer Screening, Radiology, Thermalytix, Artificial Intelligence, Thermography.

I. INTRODUCTION

DIAGNOSIS of breast cancer at initial stages has better clinical and survival outcomes. Thermography is a method of measuring the temperature distribution on the surface of a body using an infrared camera. Earlier studies [1], [2] have shown that an abnormal thermogram is the earliest sign of breast cancer. FDA has also classified Non-Contact Thermographic systems (Tele-thermography) as a Class 1 (low risk) device with general controls with an intended use as an adjunctive diagnostic screening for detection of breast cancer under Section 21 CFR 884.2980(a).

A. What is Thermography?

Infrared thermography is the recording of temperature distribution of a human body by measuring the infrared radiation emitted by the surface of that body at wavelengths between 0.8 μm and 1.0 μm . A visual heat map of the temperature distribution on the surface of an object being imaged (for example human body) is called a thermogram. The sensitivity in the temperature variations of upto 0.025°C can also be detected using thermal cameras or infrared

cameras [6], due to which even minor variations in metabolism of the body can also be detected.

Particularly for breast cancer screening, the activity in the blood vessels surrounding a developing cancer is almost always higher than the rest of the normal breast tissue. This higher activity results in temperature changes on the surface of the breast. Since breast tissue is part of the skin, these temperature changes and vascular changes are visible in an infrared image of the chest region. Moreover, an abnormal thermogram is amongst the earliest signs of a pre-cancerous or cancerous lesion of the breast [1].

Thermal imaging is also non-contact, non-invasive and extremely privacy aware, making it comfortable for the lady. Breast cancer screening solutions based on thermal cameras are very amenable for screening in rural and remote areas, as the device itself is portable.

B. Earlier Work

There are over 500 clinicians with an ability to interpret these thermal images to identify patients with likely malignant lesions [7]. There are also many studies that show the efficacy of thermography. However, thermography is still not as widely used in clinical practice as much as mammography or sono-mammography. One reason that is attributed to this decline in usage is an erroneously conducted comparative trial called Breast Cancer Detection Demonstration project (BCDDP) [3] which apparently showed low efficacy of thermography. This trial did not use any trained thermographer or thermologist to interpret the images, while other modalities employed were interpreted by trained Radiologists in their respective modalities. Nevertheless, we believe another major reason for non-adoption is the sheer complexity and difficulty of interpreting these colored heat maps without much computational support from software.

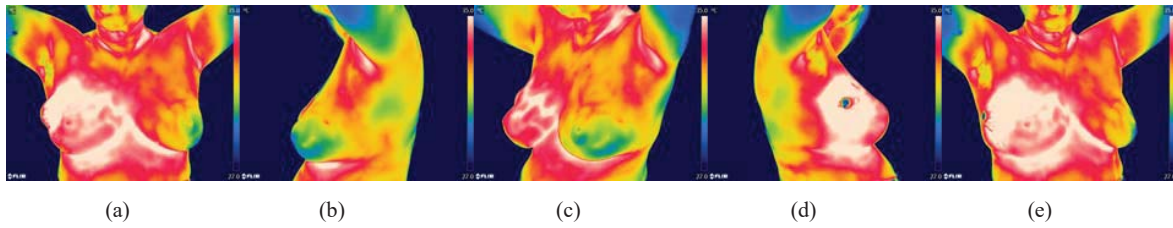
In the recent years, thermal cameras that can detect even a minute temperature variation of 0.01°C, research on breast thermography is emerging. Using high resolution thermal cameras, one can capture upto 400,000 temperature values in 32000 color shades. With the advent of hardware technology that can generate big data and advances in the use of artificial intelligence(AI) for healthcare, thermography has started emerging again. In 2010, even with a simple software analysis, NoTouchBreastScan [4] reported a sensitivity of 78% and a specificity of 75%. This paper presents the much better results of an AI-enabled thermal analysis solution from NIRAMAI.

Dr S Sudhakar is a Senior Radiologist and Head of Department, Radiology at Health Care Global Institute of Oncology Speciality Centre, Bangalore, India (email: dr_sudhakar79@yahoo.com).

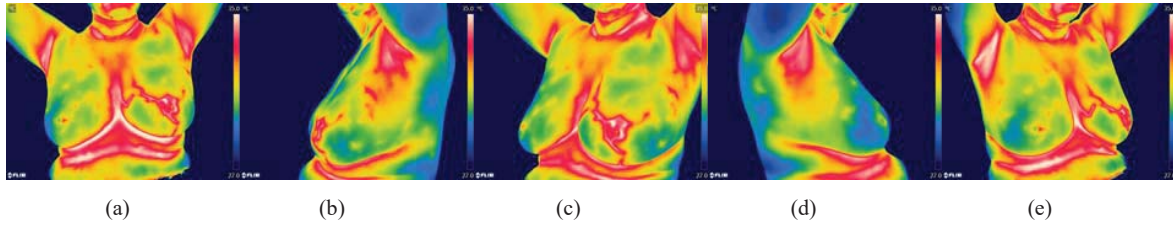
Dr. Geetha Manjunath is the CEO and CTO of NIRAMAI Health Analytix Pvt Ltd, India (email geetha@niramai.com).

Mr Siva Teja Kakileti is a Budding Scientist at Niramai Health Analytix Pvt. Ltd, India (email: sivateja@niramai.com).

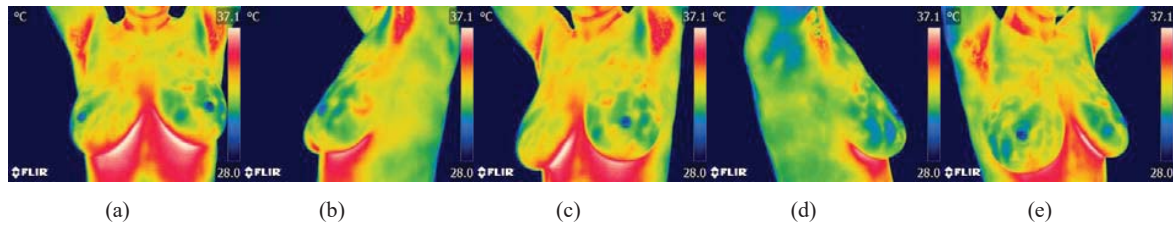
Mr Himanshu J. Madhu is a Senior Research Engineer at Niramai Health Analytix Pvt. Ltd, India (email: himanshu@niramai.com).



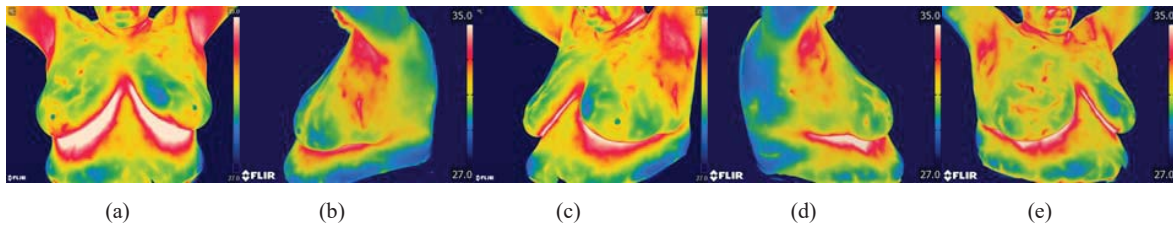
I. Thermal images of a subject with BIRADS V Malignancy in the right breast.



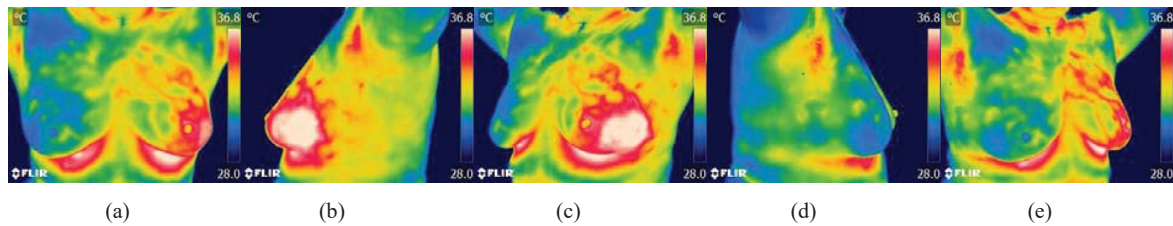
II. Thermal images of a subject with BIRADS V Malignancy in central and outer quadrants of left breast.



III. Thermal images of a normal subject with BIRADS II simple Benign cysts in both breasts



IV. Thermal images of a subject with BIRADS II Benign (Fibroadenoma) tumor in the right breast.



V. Thermal images of a subject with BIRADS II breast abscess in the left breast (Benign)

Fig. 1 Images from (I)-(V) show thermal images of subjects with different breast conditions

C. Thermalytix

NIRAMAI, has developed a new technique called Thermalytix©, a novel computer-aided diagnosis solution to automate detection of potential malignancy from thermal images. The core of NIRAMAI software consists of novel computer algorithms based on Artificial Intelligence and machine learning that analyze thermal images and generate quantitative interpretation. The software enables a low cost,

easy to use, portable solution for detecting breast cancer which is effective in all ages of women and does not require expert skills to operate the system. More details of the machine algorithm are described in [5]. Niramai solution uses an FDA 510(k) cleared FLIR A and E Series thermal cameras and inhouse developed Thermalytix software to generate a Thermal Analysis report and interpretation result

automatically, that a radiologist can review before making a final observation on the patient.

This paper presents the results of a retrospective analysis of breast screening using Mammography, Clinical Breast Examination(CBE) and NIRAMAI Thermalytix® performed on patients who walk into a reputed cancer hospital in Bangalore.

II. RESEARCH OBJECTIVES

To evaluate the efficacy of Thermalytix as a Breast Cancer screening modality in comparison with Clinical Breast Examination and Mammography.

III. METHODOLOGY

This comparative study was performed on 147 patients who walked into a reputed cancer hospital in Bangalore either for preventive screening or with a breast complaint. 42 of the 147 enrolled were found to be malignant after performing Mammography and Sono-mammography. 30 of those malignant patients were biopsy proven.

Among the enrolled patients, 14% were under 40 years. 93% of the patients had some symptoms for breast cancer (pain or lump) and other subjects had come for routine preventive screening. Follow-up or post surgery subjects were not included in this set. All subjects had either opted for or were prescribed a mammography test by their gynaecologist. In the protocol for this study, prior to performing Mammography, Thermalytix and Clinical Breast Examination tests were performed taking the consent of the patients. So, results of three tests were analyzed for every subject – Clinical Breast Examination that found palpable lumps, Thermalytix that analyzed thermal images and Mammography. All tests were required to give one of the three results: (a) Malignant/follow-up needed (b) Non-Malignant or Benign (c) Inconclusive (due to heterogeneously dense breast or the test could not be done).

IV. PROTOCOL

The protocol for thermal image capture was as follows.

- The patient is made to relax and cool in an Air Conditioned (AC) room with approximately 22-24 deg C
- The subject should be cooled for a minimum of 10 minutes with all clothes removed from upper body with hands sideways on her waist and with her hair tied above
- The patient should sit straight, not slouch, take back support or touch the upper part of the body during cooling or imaging.
- Patient should face the source of air flow during cooling such that there is direct and uniform blow of cold air on both breasts.
- Five images of the subject are captured for (a) frontal (b) left-lateral (c) left-oblique (d) Right-lateral and (e) Right-oblique views

Fig. 1 gives some sample subject images for diverse types of breast abnormalities.

V. RESULTS

Data from a total of 147 patients were included in the 3-test analysis of the CBE, Thermalytix and Mammography tests. Fig. 2 shows the comparison of sensitivity and specificity of CBE, Thermalytix and Mammography for the subjects. The ground truth (control for comparison) was taken to be mammography followed by sonomammography and histopathology when applicable. The dataset consisted of 42 positive malignant cases and 105 were benign or normal patients.

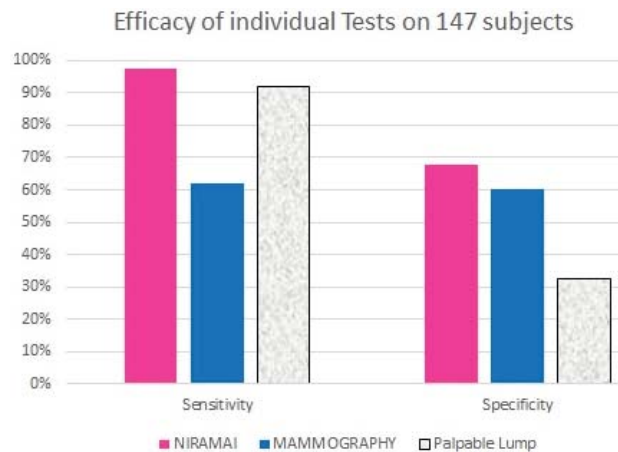


Fig. 2 Comparing NIRAMAI with Mammography and CBE on hospital walk-ins

32% of the cases were inconclusive by Mammography. Sensitivity of Mammography computed excluding those heterogeneous dense breast patients (on a subset of 99 subjects out of 147) was found to be 96%. However, analyzing the performance of mammography on full dataset resulted in sensitivity of 62% and specificity of 60%. In comparison, **Thermalytix showed 98% sensitivity** and specificity of over 68% on the whole dataset, with no breast density issues. Thermalytix was also able to detect all malignant cases except 1, but that case did not have an associated biopsy report.

Fig. 3 shows the distribution of FP and FN across different tests. 48 cases out of 147 were with heterogeneous dense breasts and Mammography was inconclusive on those cases.

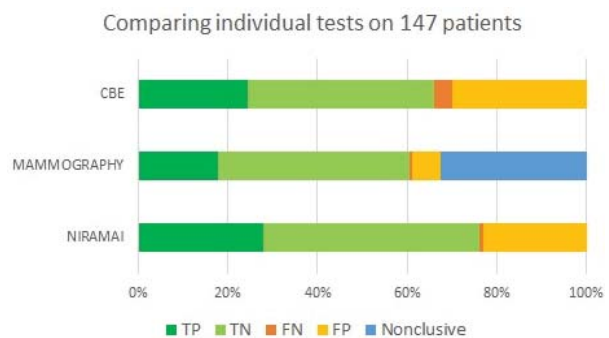


Fig. 3 Comparing number of FN, FP, TN and TP

These cases formed 32.6% of the full dataset. Both Figs. 2 and 3 show that THERMALYTIX-based screening has better efficacy than both clinical breast examination and Mammography.

In order to find the efficacy of NIRAMAI to perform population screening alongside Clinical Breast Examination, a further analysis of the subjects to check if they had a palpable lump was done. Fig. 4 gives an analysis of the malignant subjects with or without palpable lumps. **NIRAMAI detected all malignant patients without lumps.**

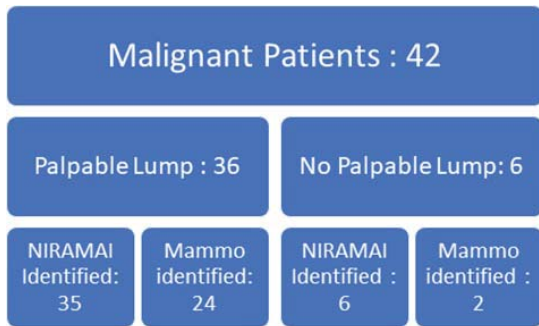


Fig. 4 Effectiveness of Mammography and NIRAMAI as a screening test (Hospital walk-ins)

NIRAMAI Thermalytix uses the physiological and thermal changes in the tissue as a signal. Hence, NIRAMAI screening can detect malignancy in very small tumours or even when there is no palpable lump. NIRAMAI Thermalytix is clearly more effective than Mammography and CBE for breast screening. Unlike Mammography, it works well even on younger women and does not have issues with breast density. Thermalytix also has lower false positives and reduces unnecessary follow-ups of benign subjects both with lumps and without.

VI. CONCLUSION:

Early detection of breast cancer is very important to decrease treatment cost and increase treatment effectiveness. In developing world, most breast cancers are detected by self examination with a palpable lump. This study reveals that NIRAMAI Thermalytix screening is more effective than self examination as well as mammography in screening for breast cancer. All palpable and non-palpable malignant conditions were effectively detected by NIRAMAI, with reduced number of follow-ups. This study concludes that Thermalytix screening solution is a promising test to screen women of all age groups for breast cancer.

ACKNOWLEDGEMENT

We acknowledge the help of Dr H V Ramprakash of Vaidehi Hospital for his advice in thermal interpretation. We would like to thank Dr Raghavendra Rao of HCG Hospital and Dr. Mukta Mahajan of CyteCare hospital for their valuable suggestions on the structure of this clinical trial.

REFERENCES

- [1] Gautherie, Michel, and Charles M. Gros. "Breast thermography and cancer risk prediction." *Cancer* 45.1 (1980): 51-56.
- [2] Spitalier, H., Giraud, D., et al: Does Infrared Thermography Truly Have a Role in Present-Day Breast Cancer Management? *Biomedical Thermology*, Alan R. Liss New York, NY. pp. 269-278, 1982
- [3] Report of the working group to review the national cancer institute breast cancer detection demonstration projects. *J Natl Cancer Inst* 62 (1979):641-709.
- [4] Wishart, G. C., et al. "The accuracy of digital infrared imaging for breast cancer detection in women undergoing breast biopsy." *European Journal of Surgical Oncology (EJSO)* 36.6 (2010):
- [5] Himanshu Madhu, Siva Teja Kakileti, Krithika Venkataramani, Sushmija Jabireddy, "Extraction of Medically Interpretable Features for Classification of Malignancy in Breast Thermography". 38th Annual International Conference of the IEEE Engineering in Medicine and Biology Society, Orlando, USA, on August 17 - 20, 2016.
- [6] Siva Teja Kakileti, Geetha Manjunath, Himanshu Madhu and H.V. Ramprakash, *Advances in Breast Thermography*, Book Chapter in the book "New Perspectives in Breast Imaging" edited by Arshad M. Malik, ISBN 978-953-51-3558-6, Print ISBN 978-953-51-3557-9, InTech, October 10, 2017.
- [7] Links to Qualified Thermography Centres, International Academy of Clinical Thermology, <http://www.iact-org.org/links.html>