

Histopathological Alterations in Liver of Mice Exposed to Different Doses of Diclofenac Sodium

Deepak Mohan, Sushma Sharma

Abstract—Diclofenac sodium, a member of the acetic acid family of non-steroidal anti-inflammatory drugs, is used to retard inflammation, arthritis pain and ankylosing spondylitis. The drug is known to cause severe injury in different tissues due to formation of reactive oxygen species. The present study is focused on the effect of different doses of diclofenac (4 mg/kg/body weight and 14 mg/kg/body weight) on histoarchitecture of the liver from 7-28 days of the investigation. Diclofenac administration resulted in distorted hepatic degeneration and formation of wide areas in the form of sinusoidal gaps. Hepatic fibrosis noticed in different stages of investigation could be attributed to chronic inflammation and reactive oxygen species which results in deposition of extracellular matrix proteins. The abrupt degenerative changes observed during later stages of the experiment showed maximum damage to the liver, and there was enlargement of sinusoidal gaps accompanied by maximum necrosis in the tissues.

Keywords—Arthritis, diclofenac, histoarchitecture, sinusoidal.

I. INTRODUCTION

ALMOST all drugs are identified as foreign substances by the human body and these are subjected to different type of chemical reactions to make them suitable for elimination. All the tissues in the body can metabolize chemicals, but the smooth endoplasmic reticulum in the liver is the principal metabolic clearing house for both endogenous and exogenous substances.

Diclofenac sodium is one of the drugs of the non-steroidal anti-inflammatory class, commonly being used for the treatment of various types of inflammatory reactions in the body and other forms of rheumatic conditions in the body. The drug has been found to be the main cause of disappearance of vultures from the Indian subcontinent about a decade ago. Since cattle were administered the drug to treat different types of injuries and other painful inflammatory conditions, the death of animals allowed the vultures to feed upon the carcasses leading to the entry of drug into the vulture's body. Diclofenac resulted in the death of vultures due to renal failure [1]. The liver is mainly involved in conversion of drugs into forms which can be easily eliminated out of the body. The mechanism responsible for the hepatic toxicity has been found to be formation of toxic metabolites and covalent binding of the drugs to the hepatic proteins. Substantial progress has been made in understanding diclofenac induced mechanism of

organ toxicity and it has been revealed that variety of immune and non-immune mechanisms contribute towards development of toxicity.

The present investigation is focused on the direct effect of these agents on the liver resulting in significant morphological changes, mainly degeneration of hepatic tissues. Although ample studies have addressed the effect of diclofenac on the liver, the present study was designed to investigate the effect of moderate and high dose on the morphology of hepatic tissue.

II. MATERIALS & METHOD

The protocol of the present investigation was approved by the Institutional Animals Ethics Committee (IAEC approval no. IAEC/Bio/5/2011-H.P.U.), Himachal Pradesh University, Shimla. Healthy, pathogen-free Swiss albino mice of Balb C strain weighing 22-25 g were procured from the Central Research Institute (CRI) Kasauli, Himachal Pradesh. These were maintained in the animal house of the department of Biosciences, H.P. University, Shimla under suitable hygienic conditions. The animals were caged in polypropylene cages on soft chip bedding and provided with commercial feed (Hindustan Lever Ltd. New Delhi, India) and were given water *ad libitum*.

III. DRUG ADMINISTRATION

Canular feeding was preferred for oral administration of the drug. The treated group was administered with doses at the rate of 4 mg/kg body weight (Low dose group) and 14 mg/kg/body weight (High dose group). The control animals were given saline water.

IV. EXPERIMENTAL DESIGN

The animals were divided into three groups, as:

1. In the first group, the mice were given normal saline water and were the control group.
2. In the second group, a daily dose of 4mg/kg body weight was given to the mice designated as the low dose group.
3. In the third group, a daily dose of 14mg/kg body weight was administered to the mice designated as the high dose group.

The animals were sacrificed at seven days, 14 days, 21 days, and 28 days of the experiment by cervical dislocation. The liver was taken out of the body in normal saline and weighed. For histopathological studies, the tissue was fixed in Bouin's fluid for 24 hours and hematoxylin eosin staining was employed to study various histopathological changes in the

Deepak Mohan is working as Associate Professor in Zoology, R.G. M. Govt. College, Joginder Nagar, Distt. Mandi, Himachal Pradesh, India (phone: 919418106658; e-mail dpk222191@gmail.com).

Sushma Sharma is working as Professor in Department of Biosciences, Himachal Pradesh University, Shimla Himachal Pradesh, India (e-mail Sushma_bio_sci@rediffmail.com).

liver. The tissue was also proceeded for biochemical studies discussed in separate a paper [2]. The slides were studied under research binocular microscope, scanned and subsequently photomicrographed.

V. RESULTS

A. Normal Liver

Light microscopic examination of the control liver showed the normal architecture of the hepatic lobules with hepatocytes radiating from the central vein to the periphery of the lobules that contain the portal area. The hepatocytes are polygonal in shape and showed granular cytoplasm with central vesicular nuclei, separated by narrow sinusoids lined by irregular shaped cells with oval nucleus and prominent cytoplasmic processes known as kupffer cells. These cells are intensely phagocytic. Hepatocytes are usually uninucleate but at times binucleate as well. Hepatic artery is also observed in the cross section, as shown in Fig. 1.

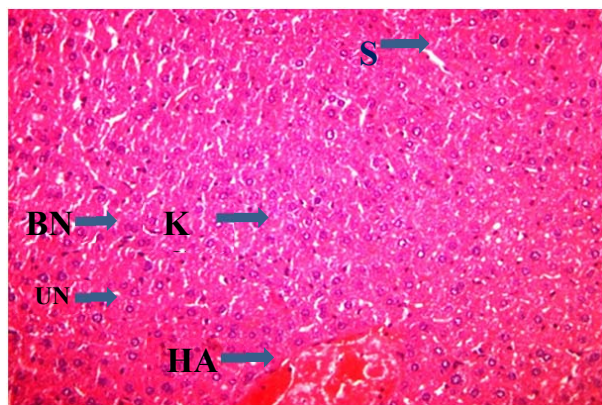


Fig. 1 t. s. of control mice liver showing polygonal hepatocytes having sinusoids (S), uninucleate cells (un) binucleate cells (bn) kupffer cells (kc) and hepatic artery (ha) X 200

B. Diclofenac Treated Mice Liver

Diclofenac administration (4 mg/kg body weight) after seven days resulted in slight changes in the histoarchitecture of the liver, as shown in Fig. 2. The hepatocytes were in close association at most of the places and sinusoids were not clearly demonstrated. The hepatic degeneration of the tissue resulted in the formation of wide sinusoidal gaps in the form of sinusoidal streaks. There were no structural changes observed in relation to the portal vessels, kupffer cells and size of the nuclei.

Prolongation of drug treatment for 21 days resulted in the appearance of enucleated areas and necrosis in the parenchyma indicating tissue damage. Prominent damage of the central lobular region appeared in the liver. The further degeneration of the hepatic cells led to the widening of the sinusoidal gaps in the form of sinusoidal canals, as in Fig. 3.

Diclofenac treatment for 14 days showed more pronounced changes in the liver. There was extensive enlargement in the size of the nuclei. There was complete loss of chromatin material in some nuclei and considerable increase in the

number of macrophages. Complete loss of polygonal shape of the hepatocytes and prominent vascular spaces are visible.

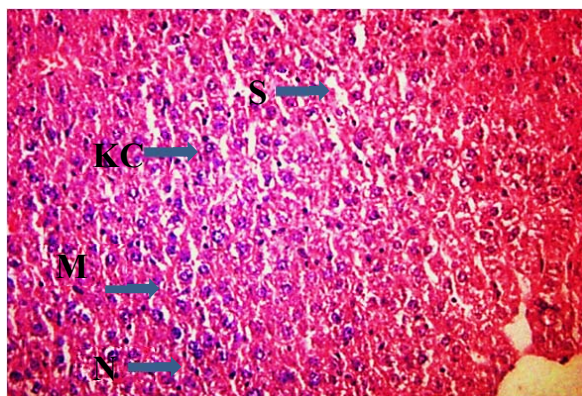


Fig. 2 t. s. of liver from 4 mg/kg body weight diclofenac treated mouse after 7 days showing sinusoidal streaks (s) kupffer cells (KC), macrophages (m) and fragmented nuclei (N) X 400

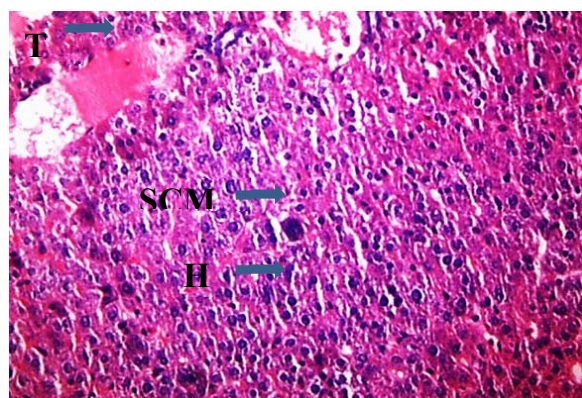


Fig. 3 t. s. of 4 mg/kg body weight diclofenac treated mouse liver after 14 days showing hypertrophied nuclei (h), some nuclei with scattered chromatin material (scn) and portal vessel obliterated with thrombus (t) X 400

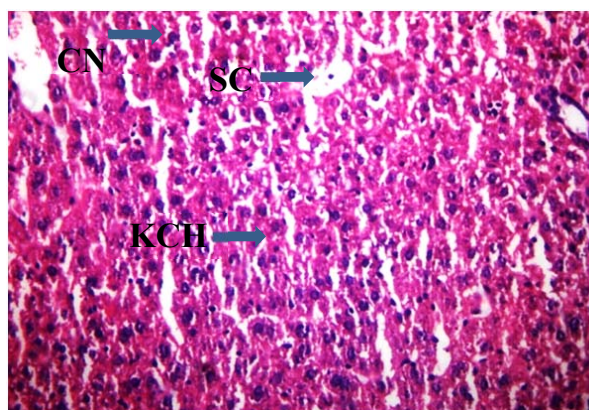


Fig. 4 t. s. of 4 mg/kg body weight diclofenac treated mouse liver after 28 days of treatment revealing condensed nuclei (cn), sinusoidal canals (sc) and kupffer cell hyperplasia (kch) X 400

After 28 days of diclofenac treatment in the low dose group,

more degeneration of nuclei was noticed. At certain places there was aggregation of Kupffer cells across sinusoidal spaces. Hepatocytes close to portal areas in some lobules appeared with empty cytoplasm and darkly stained nuclei, as seen in Fig. 4.

Heavy infiltration of inflammatory cells was observed after 14 days of treatment. There was massive degeneration of hepatocytes and degenerated areas were marked by the presence of fragmented cellular masses.

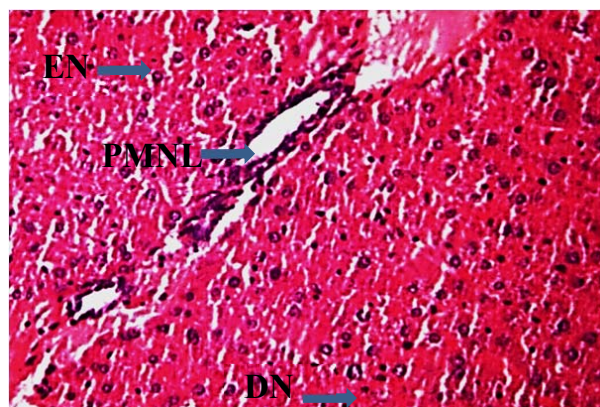


Fig. 5 t. s. of liver from diclofenac treated mouse at dose rate of 14 mg/kg body weight after 7 days of treatment showing degenerated areas without nuclei (en), distorted nuclei (dn). some hepatocytes are occupied by polymorphonuclear lymphocytes (pmnl) X 400

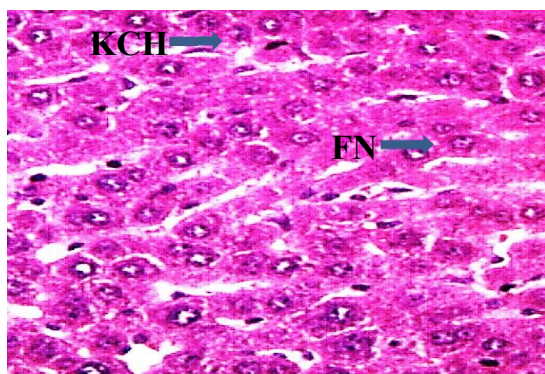


Fig. 6 t. s. of liver from 14 mg/kg body weight diclofenac treated mouse after 7 days demonstrating fragmented nuclei (fn) and kupffer cell hyperplasia (kch) X 400

High dose diclofenac administered liver (14 mg/kg body weight) showed extensive infiltration of polymorphonuclear lymphocytes (PMNL) in dilated hepatic sinuses. Large number of enucleated areas and necrosis in the parenchyma was also noticed. Some of the common changes observed were fragmented nuclei and Kupffer cell hyperplasia, as in Figs. 5 and 6.

The extent of damage increased tremendously after 21 days and 28 days of treatment in the high dose group. There were present extensively pycnotic uninucleate and binucleate hepatocytes at certain regions. Most of the nuclei showed granulated chromatin material. Obliteration of portal vessels

and veins with thrombus was also noticed. The parenchymal necrosis reached its peak after 28 days of treatment. Many enucleated areas, necrotic areas and cells with impaired nuclear organization were easily discernible. There were multiple necrotic gaps due to severe necrosis and there was extensive fibrosis as a result of degeneration, see Figs. 7-9.

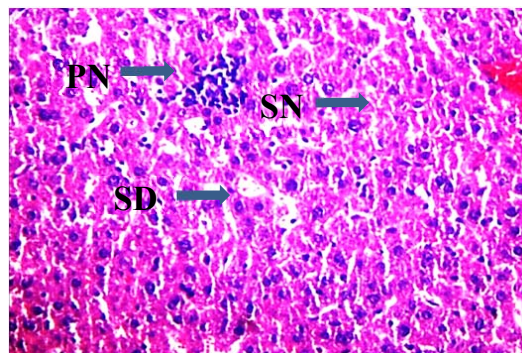


Fig. 7 t. s. of liver from 14mg/kg body weight diclofenac treated mouse after 14 days depicting heavy infiltration of inflammatory cells seen clumped together with other pycnotic nuclei (pn) denoting area of severe necrosis (sn). sinusoidal dilations (sd) are also seen X 400

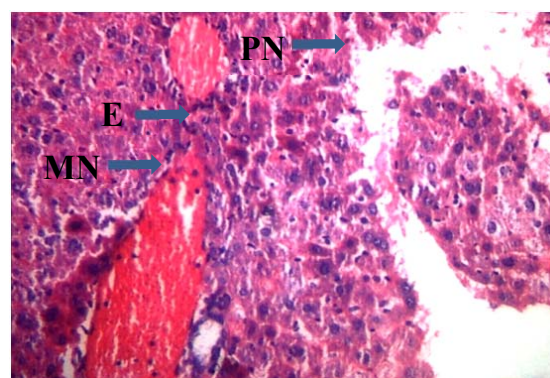


Fig. 8 t. s. of liver from 14 mg/kg body weight diclofenac treated mouse after 21 days demonstrating extensive parenchymal necrosis (pn), increased eosinophilia (E) and mononuclear infiltrate can be seen in the thrombus (mn) X 400

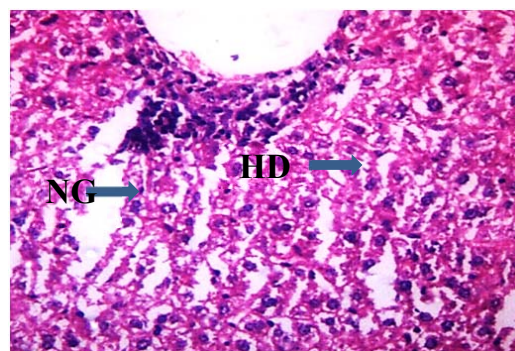


Fig. 9 t. s. from liver of 14 mg/kg body weight diclofenac treated mouse after 28 days showing wide necrotic gaps (ng) and severe hepatocellular damage (hd) X 400

V. DISCUSSION

Some studies have suggested that the toxic effects of diclofenac may be caused by mitochondrial impairment with the futile consumption of nicotinamide adenine dinucleotide phosphate [3]. There were significant histopathological differences between the low dose and high dose group, which suggested that the hepatic changes were always dose dependent. Acute hepatitis and irreversible cell changes have also been observed as a consequence of high dose treatment [4].

Histological observation in the present investigation of liver of mice pointed towards massive tissue damage after diclofenac administration in both low and high dose groups. Normal mice liver histology revealed structurally organized and intact cellular architecture. Polygonal hepatocytes were relatively uniform in size with equal sized nuclei and were in close association with each other. Blood vessels and lymph vessels presented a normal feature.

The administration of the drug in mice resulted in distorted hepatic cellular architecture due to hepatic degeneration and formation of wide areas in the form of sinusoidal gaps. In certain individuals the diclofenac administration causes fatal hepatotoxicity associated with the formation of reactive metabolites [5], [6]. Present findings indicated that changes in both dose groups were more aggressive and irreversible during the later stages of the experiment. There were hepatic necrosis, mild fibrous tissue proliferation and interstitial and periportal inflammation indicating acute hepatitis. All these changes became more pronounced with increase in the duration of the treatment. Similar findings were observed in some other studies [4]. The changes like congested portal and central veins with widened blood sinusoids and infiltration in the portal areas were some of the histopathological changes also revealed in other studies [7], [8]. The hepatic fibrosis observed in the present studies could be attributed to chronic inflammation and reactive oxygen species, which activates hepatic stellate cells with excessive deposition of extracellular matrix proteins (ECM). This excessive deposition of ECM disrupts the normal architecture of the liver resulting in the pathophysiological damage to the organ [9]. The appearance of periportal hepatocytes as vacuolated cells with pycnotic nuclei may be due to excessive lipid peroxidation. Furthermore, lipid peroxidation should occur at faster rates in periportal region of liver due to higher oxygen concentration in this region [10].

The histopathological studies go side by side with the biochemical alterations. The degenerative changes in the liver are correlated with the changes in the enzymatic activities of various liver enzymes. Histopathological changes like diffuse hydropic degeneration, vacuolation and necrosis were reported in hepatic tissue of rats treated with diclofenac sodium at a dose of 13.5 mg/kg body weight [11]. Several investigators have attempted to clarify the mechanism of diclofenac sodium induced hepatotoxicity and it has been reported to be associated with idiosyncratic reaction [12]. However, the pathological changes in different tissues like liver, kidney and spleen in adjuvant induced arthritic rats have been associated

with lysosomal enzymes [13], [14]. The abrupt degenerative changes observed during the later stages of the experiment showed maximum damage to the liver. There was enlargement of sinusoidal gaps and tissues showed massive PMNL infiltration. There is enhancement in the activity of 5-nucleotidase due to diclofenac sodium, suggesting a possible role of this enzyme in the catabolism of nucleic acids in the cells [15]. Due to severe hemolysis in liver sections there was infiltration of blood cells into sinusoidal dilations. There are other studies suggesting the effect of mefenamic acid and diclofenac sodium on the liver resulting in hepatocyte degeneration with scattered areas of the necrosis, pycnotic nuclei and dose dependent tissue proliferation [3], [16].

ACKNOWLEDGMENT

The author thanks the Department of Higher Education, Govt. of Himachal Pradesh for granting permission to carry out the research work. The lab facilities provided by the Department of Biosciences for conducting the studies are duly acknowledged.

REFERENCES

- [1] J. L. Oaks, M. Gilbert, M. Z. Virani, R. T. Watson, C. U. Meteyer, B. A. Rideout, H. L. Shivaprasad, S. Ahmad, M. J. Chaudhary, M. Arshad, S. Mahmood, A. Ali and A. A. Khan, "Diclofenac residues as the cause of vulture population decline in Pakistan" *Nature*. 427(6975): 2004 pp 596-598.
- [2] D. Mohan and S. Sharma, "Biochemical changes in liver of mice after exposure to different doses of diclofenac sodium" *International Journal of Biological, Biomolecular, Agricultural, Food and Biotechnological Engineering* 2(5): 2017.
- [3] R. Bort, X. Pondosa, R. Jover, M. J. Gomez-Lechon and J. V. Castell "Diclofenac toxicity to hepatocytes: A role for drug metabolism in cell toxicity" *J. Pharmacol. Exp. Ther.* 288: 1999 pp 65-72.
- [4] G. Aydin, A. Gokcimen, M. Oncu, E. Cicek, N. Karahan and O. Gokalp. "Histopathologic changes in liver and renal tissues induced by different doses of Diclofenac sodium in rats." *Turk. J. Vet. Anim. Sci.* 27:2003 pp 1131-1140.
- [5] G. S. Ouellette, B. E. Slitzky J. A. Gates, S. Lagarde, S and A.B. West, "Reversible hepatitis associated with diclofenac." *J. Clin. Gastroenterol.* 13(2): 1991 pp. 205-210.
- [6] W. Tang, R. A. Stearns, S. M. Bandiera, Y. Zhang, C. Rabb, M. P. Braun, D. C. Dean, J. Rang, K. H. Leung, G. A. Doss, J. Strauss, G. Kwei, T. Rushmore, S. Chiu, and T. Baillie, "Studies on cytochrome P-450 mediated bio-activation of Diclofenac in rats and in human hepatocytes: identification of glutathione conjugated metabolites". *Drug Metab. Dispos.* 27(3):1999 pp. 365-372.
- [7] Z. Tomic, B. Miliasevic, A. Sabo, L. Dusan, V. Jakovljevic, M. Mikov, S. Majda, and V. Vasovic. "Diclofenac and ketoprofen liver toxicity in rat." *Eur. J. drug Metab. Pharmacokinet.* 33(4): 2008 pp. 253-260.
- [8] M. Moorthy, S. Fakura and H. Ithnin, "The histomorphological analysis of liver following administration of low doses of diclofenac and ibuprofen" *J. Biol. Sci.* 9(7): 2009 pp. 676-681.
- [9] A. H. Alaaeldin, "Ameliorative effects of Moringa oleifera Lam seed extract on liver fibrosis in rats". *Food Chem. Toxicol.* 48(1): 2010 pp. 345-355.
- [10] F. Sigala, G. Kostopanagiotou, I. Andreadou, N. Kavatzas, E. Felekouras, P. Sigalas, E. Bastounis, and E. Papalambros, "Histological and lipid peroxidation changes after administration of 2-acetylaminofluorene in a rat liver injury model following selective periportal and pericentral damage." *Toxicol.* 1196(1-2):2004 pp. 155-163
- [11] Z. K. El-Maddawy, and M. I. El- Ashmawy, "Hepato-renal and haematological effects of diclofenac sodium to rats" *Global J. Pharmacol.* 7(2): 2013 pp. 123-132.
- [12] D. A. Kertz-Romell, and U. A. Boelsterli, "Diclofenac covalent protein binding is dependent on acyl glucuronide formation and is inversely

- related to P 450 mediated acute cell injury in cultured rat hepatocytes".
Toxicol. Appl. Pharmacol. 120: 1993 pp. 155-161.
- [13] K. P. Rao, "Recent developments of collagen based materials for medical applications and drug delivery systems". J.Biomater. Sci. Polym.. 7(7): 1995 pp. 623-645.
- [14] K. Ramalingam, and S. Subramanian, "Sex differences in delayed hypersensitivity response in Wistar rats *Rattus norvegicus* to CFA" Utter Pradesh J. Zool. 22(1): 2002 pp. 85-88.
- [15] N. T. Taib, and B. M. Jarrar "Histochemical alterations in the spleen of rabbits induced by diclofenac sodium (Voltaren)" J. King Saud. Univ. Sci. 19(1): 2006 pp. 21-29.
- [16] N. Somchit, F. Sanat, E. H. Gan, I. A. W. Saharin, and A. Zuraini. "Liver injury induced by the non-steroidal anti-inflammatory drug mefenamic acid" Singapore Med. J. 45(11):2004 pp. 530-532.