

Hepatoprotective Effect of Oleuropein against Cisplatin-Induced Liver Damage in Rat

Salim Cerig, Fatime Geyikoglu, Murat Bakir, Suat Colak, Merve Sonmez, Kubra Koc

Abstract—Cisplatin (CIS) is one of the most effective anticancer drug and also toxic to cells by activating oxidative stress. Oleuropein (OLE) has key role against oxidative stress in mammalian cells, but the role of this antioxidant in the toxicity of CIS remains unknown. The aim of the present study was to investigate the efficacy of OLE on CIS-induced liver damages in male rats. With this aim, male Sprague Dawley rats were randomly assigned to one of eight groups: Control group; the group treated with 7 mg/kg/day CIS; the groups treated with 50, 100 and 200 mg/kg/day OLE (i.p.); and the groups treated with OLE for three days starting at 24 h following CIS injection. After 4 days of injections, serum was provided to assess the blood AST, ALT and LDH values. The liver tissues were removed for histological, biochemical (TAC, TOS and MDA) and genotoxic evaluations. In the CIS treated group, the whole liver tissue showed significant histological changes. Also, CIS significantly increased both the incidence of oxidative stress and the induction of 8-hydroxydeoxyguanosine (8-OH-dG). Moreover, the rats taking CIS have abnormal results on liver function tests. However, these parameters reached to the normal range after administration of OLE for 3 days. Finally, OLE demonstrated an acceptable high potential and was effective in attenuating CIS-induced liver injury. In this trial, the 200 mg/kg dose of OLE firstly appeared to induce the most optimal protective response.

Keywords—Antioxidant response, cisplatin, histology, liver, oleuropein, 8-OHdG.

I. INTRODUCTION

CISPLATIN-based chemotherapy is widely used for the treatment of tumors including head, neck, breast, lung ovarian, testicular and bladder cancers [1]. However, the prevalence of CIS toxicity is high and liver toxicity is the most prominent side-effect of CIS [2]. The drug induces pathological signs [3], [4] and acute liver failure in laboratory animals [5], [6]. Olive leaf contains large amounts of potentially useful phytochemicals, many of the same phenolics as the olive oil but in much higher concentration. The polyphenols exhibit a range of beneficial effects including antioxidant, anti-inflammatory, antiatherogenic and anticarcinogenic properties [7]. The antioxidant activity of olive phenols has been demonstrated in several *in vitro*

Fatime Geyikoglu, Salim Cerig, Murat Bakir and Kubra Koc are with the Department of Biology, Atatürk University Faculty of Science, Erzurum, Turkey.

Suat Colak is with the Department of Plant and Animal Production, Erzurum University, Üzümlü Vocational, Erzurum, Turkey.

Merve Sonmez is with the Department of Biology, Faculty of Art and Science, Erzurum University, Erzurum, Turkey.

Salim Cerig is with the Department of Biology, Atatürk University, Erzurum, Turkey (corresponding author, phone: 0 (446) 231 43 33 Fax: 0 (442) 231 41 09, e-mail: salimcerig@atauni.edu.tr)

systems and some intervention studies have investigated the DNA protective potential of phenolic compounds [8]. OLE is the major bio-phenol component in olive leaf and fruit and the most promising bioactive natural product. OLE is commercially available as food supplement in Mediterranean countries. OLE protects against a number of pathologies, including Alzheimer's disease, type 2 diabetes, obesity, non-alcoholic hepatitis, and other natural or experimentally-induced pathological conditions. Such a protection could result, at least in part, in a remarkable improvement of the pathological signs arising from stress conditions including oxidative stress, an excessive inflammatory response, and the presence of cytotoxic aggregated material [9], [10].

The conventional chemotherapy is not adequately effective against cancer and has severe side effects. Many natural compounds isolated from plants have been found to inhibit cancer growth and to decrease adverse effects of chemotherapeutic drugs. CIS-induced liver toxicity involves the formation of reactive oxygen species (ROS) and decrease in antioxidant enzymes [11], [12]. Because OLE has been used to improve liver function in various regions of the world [7], the present study has been conducted to find the effects of OLE on CIS-induced liver toxicity in rat. In this regards, histopathological and biochemical evaluations of the liver tissue were performed. Additionally, the objective of this study was to evaluate the genotoxicity of CIS and to investigate antigenotoxic potential of OLE against CIS-induced oxidative DNA damage in rat liver.

II. MATERIALS AND METHODS

A. Animals

Fifty-six adult male Sprague-Dawley rats (weighing 200-250 g) obtained from Medical Experimental Application and Research Center, Atatürk University were used. Animals were housed inside polycarbonate cages in an air-conditioned room (22±2 °C) with 12-h light-dark cycle. Standard rat feed and water were provided ad libitum. The rats were allowed to acclimatize to the laboratory environment for 7 days before the start of the experiment. All procedures were performed in conformity with the Institutional Ethical Committee for Animal Care and Use at Atatürk University (protocol number: B.30.2.ATA.0.23.85-11) and the Guide for the Care and Use of Laboratory Animals (National Research Council, 1996).

B. Experimental Protocols

The rats were weighed and randomly allocated into eight experimental groups (n=7, each): (a) Control: the animals received 1 mL of distilled water as vehicle; (b) CIS (Sigma

Chemical Co., St. Louis, MO): the animals received 7 mg CIS/kg b.w., diluted in distilled water (1 mL); c) OLE (HPLC grade $\geq 98\%$; Sigma Chemical Co., St. Louis, MO): the animals received 1 mL of OLE solution; and (d) CIS/OLE the animals received 1 mL of preparations of OLE following CIS administration.

The injections of CIS were given using a single dose, via i.p. route for 24 hours. The OLE groups received i.p. injections with a daily single dose of OLE (50, 100 and 200 mg/kg/day) for a total period of 3 days. On day 4 after injections, the rats were anesthetized with isoflurane and blood samples were collected for biochemical studies. After cervical dislocation under anesthesia, the liver specimens were gathered for further analyses. These investigations stem from the works of the researchers [13], [14].

C. Biochemical Methods

Fresh liver tissues were rinsed with ice-cold saline and immediately stored at -80°C . The tissue specimens were weighed and then homogenized in a 50-mM phosphate buffered saline (PBS) at pH 7.0. Homogenized liver tissues were then centrifuged at 10,000 rpm at 4°C over 15 minutes to isolate the supernatant for subsequent analysis.

D. Determination of Lipid Peroxidation

Lipid peroxidation was determined by quantifying malondialdehyde (MDA) content in the tissue supernatant, which was spectrophotometrically measured by the absorbance of a red-colored product with thiobarbituric acid [15]. This reaction results in the production of a MDA-TBA₂ compound that has a measurable absorbance at 532 nm [16].

E. Measurement of TAC and TOS

Total antioxidant capacity (TAC) and total oxidant status (TOS) were measured via colorimetric methods from rat liver tissue. TAC units are mmol Trolox equivalents per gram of tissue, and TOS units are mmol H₂O₂ equivalents per gram of tissue. The oxidative stress index (OSI) was calculated according to the following formula: $\text{OSI} = \text{TOS}/\text{TAC}$ [17].

F. Liver Function Assessment

Blood samples were collected into serum separator tubes (Microtainer; Becton Dickinson, Franklin Lakes, NJ, USA), allowed to stand (75-90 min), centrifuged (11,000 g, 5 min),

serum harvested, and stored at -20°C . The following parameters for liver injury were measured by an automated biochemical analyzer (Olympus AU 2700) with commercially available testing kits (Bioclinica): alanine aminotransferase (ALT), aspartate aminotransferase (AST) and lactate dehydrogenase (LDH) [18].

G. Determination of 8-OH-dG Level

8-hydroxy-2'-deoxyguanosine assay kits were purchased from Cayman Chemical for determining 8-OH-dG levels in the liver samples. Since it is a competitive assay that can be used for the quantification of 8-OHdG in homogenates and recognizes both free 8-OH-dG and DNA-incorporated 8-OH-dG, many researches are being performed to use this protocol. This assay depends on the competition between 8-OH-dG and 8-OHd-G-acetylcholinesterase (AChE) conjugate (8-OH-dGTracer) for a limited amount of 8-OHd-G monoclonal antibody [19]. All procedures were carried out in accordance with the provider manual.

H. Histopathological Examination

The livers of rats were fixed in buffered 10% formalin solution for 72 h and embedded in a paraffin wax. Then tissue specimens were cut into five-micron sized pieces and stained with hematoxylin and eosin for routine histology (H&E). Reticulin stain was used for the evaluation of fibrosis [20]. In addition, glycogen storage ability of hepatocytes was assessed through periodic acid-Schiff (PAS) [21]. A semi-quantitative evaluation of liver tissue was accomplished by scoring the degree of severity according to the formerly published criteria [22]-[24]. Light microscope (X200) was used for histopathologic examination. The degree of the inflammation, hemorrhage, fibrosis, congestion, hepatocyte damage and glycogen content were scored for each group.

I. Statistical Analysis

For statistical analysis, we used SPSS for Windows 13.0 (SPSS Inc., Chicago, USA). The experimental data were analysed using one-way analysis of variance (ANOVA) followed by Tukey post hoc test for multiple comparisons. Results are presented as mean \pm standard error (SE) and values $p < 0.05$ were regarded as statistically significant.

TABLE I
THE EFFECTS OF OLE ON LIVER AST, ALT, LDH, MDA, TOS, AND TAC LEVELS AFTER TREATED WITH CIS

Groups	AST(U/L) Mean \pm SE	ALT(U/L) Mean \pm SE	LDH (U/L) Mean \pm SE	MDA Mean \pm SE	TOS Mean \pm SE	TAC Mean \pm SE
Control	185.14 \pm 15.3 ^a	56.70 \pm 11.10 ^a	4110.33 \pm 296.53 ^a	3.90 \pm 0.92 ^a	15.31 \pm 4.06 ^a	2.14 \pm 0.88 ^a
CIS	537.23 \pm 67.73 ^{*d}	159.80 \pm 20.05 ^{*d}	21695.13 \pm 965.15 ^{*d}	15.61 \pm 3.73 ^{*c}	77.85 \pm 17.21 ^{*c}	8.09 \pm 2.16 ^{*d}
OLE 50 mg/kg	176.41 \pm 20.24 ^a	58.13 \pm 18.10 ^a	4096.17 \pm 231.25 ^a	3.75 \pm 10.14 ^a	16.27 \pm 3.44 ^a	2.11 \pm 0.76 ^a
OLE 100 mg/kg	184.47 \pm 21.23 ^a	53.32 \pm 29.11 ^a	4122.18 \pm 251.21 ^a	3.88 \pm 0.82 ^a	15.55 \pm 5.23 ^a	2.24 \pm 0.53 ^a
OLE 200 mg/kg	182.61 \pm 30.09 ^a	55.20 \pm 23.06 ^a	4165.36 \pm 210.30 ^a	3.95 \pm 0.56 ^a	17.48 \pm 6.38 ^a	2.48 \pm 0.55 ^a
CIS+OLE 50 mg/kg	522.24 \pm 40.03 ^{*c,d}	145.23 \pm 20.15 ^{*c}	21186.79 \pm 867.34 ^{*c,d}	14.32 \pm 2.69 ^{*c}	73.19 \pm 20.11 ^{*c}	7.85 \pm 3.24 ^{*c,d}
CIS+OLE100 mg/kg	415.52 \pm 37.21 ^{*b}	128.76 \pm 2.07 ^{*b}	18568.46 \pm 763.46 ^{*b}	10.54 \pm 2.64 ^{*b}	59.79 \pm 21.09 ^{*b}	6.15 \pm 2.69 ^{*b}
CIS+OLE200 mg/kg	185.14 \pm 15.3 ^a	61.03 \pm 12.27 ^a	4189.76 \pm 242.22 ^a	4.01 \pm 0.86 ^a	17.19 \pm 3.79 ^a	2.54 \pm 0.69 ^a

Notes: Data are presented as means \pm SD (n=7). *Symbol < 0.05 represents significant difference among the groups compared to controls. ^{a,b,c,d}The groups in the same column with different letters are statistically significant (p0.05). For abbreviations see legend in Table I. Abbreviations used: CIS: Cisplatin; OLE: Oleuropein

III. RESULTS

CIS group displayed remarkable elevation in the levels of liver enzymes, MDA and TOS (Table I). On the other hand, a significant decrease was found in TAC level with CIS administration. Whereas, supplementation of rat with OLE resulted in reversal of biochemical indicators. And these effects were associated with the increasing dose of OLE therapy. Notably, all parameters were reached statistical significance in the high-dose OLE group when compared to the CIS group ($p < 0.05$).

As presented in Table II, the 8-OH-dG levels, a hallmark of oxidative stress-DNA base damage, were markedly increased in rat liver after CIS administration. On the contrary, there were no significant difference between the levels of 8-OH-dG in the control and all OLE treated groups. Moreover, levels of 8-OHdG caused by CIS were normalized by dose of 200 mg/kg OLE.

demonstrated significant differences between the groups ($p < 0.05$, Table III).

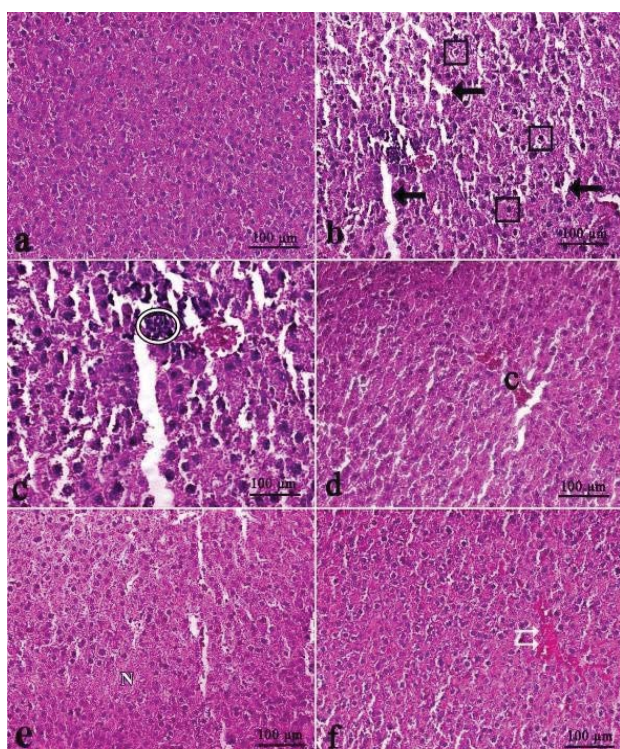


Fig. 1 Light microscopic appearance of liver from control rats (a), liver in CIS group rats (b)-(e) (b) Sinusoidal dilatation (arrows), Hepatocyte necrosis (inside of square symbols), (c) Inflammation (inside of circle symbol), (d) Congestion (C), (e) Diffuse hepatic necrosis (N), (f) Hemorrhage (double arrow) (H&E)

As compared with control group, CIS group showed significant hepatopathologic changes; hepatic necrosis, inflammation, hemorrhage, fibrosis, congestion, sinusoidal dilatations, the activation of Kupffer cells and decreased glycogen content. On the other hand, the administration of OLE was able to reduce the liver injury. Furthermore, this positive impact was notably correlated with increased OLE doses (Figs. 1-9). And the analysis of histopathological data

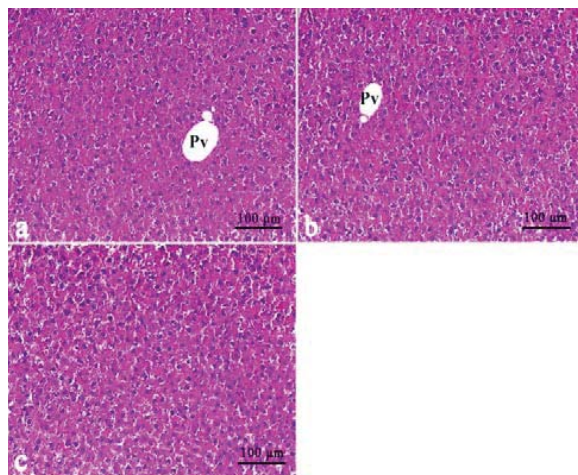


Fig. 2 Liver in OLE group rats a) 50 mg/kg OLE group, b) 100 mg/kg OLE group. Portal vein (Pv), c) 200 mg/kg OLE group, (H&E)

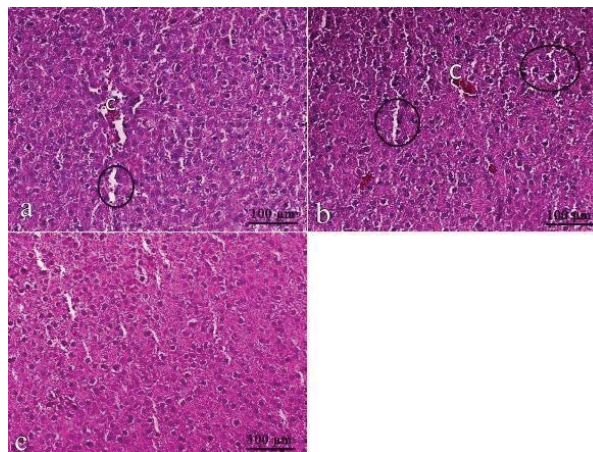


Fig. 3 (a) Decreased dilations in CIS+50 mg/kg OLE group (inside of circle symbol), and congestion (C), (b) Decreased congestion (C) and sinusoidal dilatations as compared CIS+100 mg/kg OLE group. (c) Normal histological structure of liver in CIS+200 mg/kg OLE group, (H&E)

TABLE II
THE EFFECT OF OLE ON LIVER 8-OH-dG LEVELS AFTER TREATED WITH CIS

Groups	8-OH-dG level (as pg/ml); Mean±SE
Control	1.07 ± 0.9a
CIS	3.87 ± 0.31*d
OLE 50 mg/kg	0.93 ± 0.11a
OLE 100 mg/kg	0.98 ± 0.12a
OLE 200 mg/kg	1.04 ± 0.16a
CIS+OLE 50 mg/kg	2.18 ± 0.42b
CIS+OLE 100 mg/kg	1.49 ± 0.14c
CIS+OLE 200 mg/kg	1.08 ± 0.18a

Notes: Data are presented as means ± SD (n=7). *Symbol < 0,05 represents significant difference among the groups compared to controls. The groups in the same column with different letters are statistically significant ($p < 0.05$). For abbreviations see legend in Table I.

TABLE III
HISTOPATHOLOGICAL SCORES OF LIVER PATHOLOGY AFTER TREATED WITH CIS

Groups	Scores for hepatic damage (maximum score of 18) Mean±SD	Scores for hepatic glycogen content (maximum score of 3) Mean±SD	Scores for fibrous (maximum score of 3) Mean±SD	Scores for inflammation (maximum score of 18) Mean±SD	Scores for hemorrhage (maximum score of 3) Mean±SD	Scores for congestion (maximum score of 3) Mean±SD
Control	0,58±0,14 ^a	3,04±0,42 ^a	0,43±0,09 ^a	0,12±0,03 ^a	0,15±0,10 ^a	0,23±0,27 ^a
CIS	9,45±0,40 ^{*c}	0,48±0,11 ^{*c}	2,50±0,12 ^{*c}	3,01±0,42 ^{*d}	4,03±0,83 ^{*c}	4,65±1,01 ^{*d}
OLE 50 mg/kg	0,59±0,13 ^a	2,91±0,33 ^a	0,55±0,11 ^a	0,15±0,05 ^a	0,14±0,11 ^a	0,22±0,33 ^a
OLE 100 mg/kg	0,62±0,04 ^a	2,89±0,45 ^a	0,46±0,10 ^a	0,13±0,04 ^a	0,17±0,12 ^a	0,26±0,32 ^a
OLE 200 mg/kg	0,58±0,11 ^a	2,93 ±0,28 ^a	0,52±0,09 ^a	0,12±0,08 ^a	0,13 ±0,18 ^a	0,21±0,28 ^a
CIS+OLE 50 mg/kg	9,05±0,22 ^{*c}	0,92±0,14 ^{*b,c}	2,12±0,21 ^b	2,45±0,44 ^{*c,d}	3,97±0,61 ^{*c}	3,60±0,10 ^{*c}
CIS+OLE 100 mg/kg	7,80±0,46 ^{*b}	1,39±0,15 ^{*b}	1,73±0,14 ^{*b}	1,14±0,37 ^{*b}	2,73±0,76 ^{*b}	1,62±0,88 ^{*b}
CIS+OLE 200 mg/kg	0,95±0,24 ^a	2,90±0,27 ^a	0,66±0,09 ^a	0,25±0,09 ^a	0,19±0,24 ^a	0,31±0,25 ^a

Notes: Data are presented as means ± SD (n=7). *Symbol < 0,05 represents significant difference among the groups compared to controls. ^{a,b,c,d}The groups in the same column with different letters are statistically significant (p<0.05) by Tukey's multiple range tests. For abbreviations see legend in Table I.

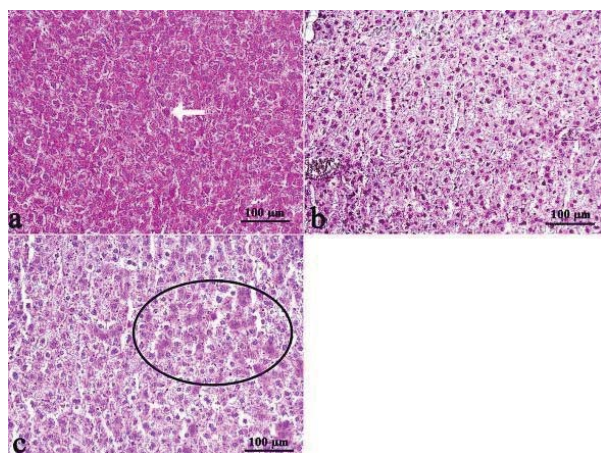


Fig. 4 Liver in control and CIS group rats; (a) Kupffer cells in control group liver (arrow) and darkly stained hepatocytes, (b) The glycogen depletion in hepatocytes of CIS group, (c) The increasing Kupffer cell activation in CIS group (inside of circle symbol), (PAS)

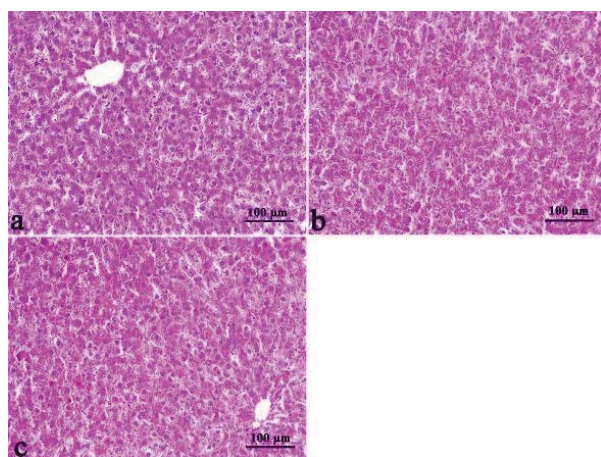


Fig. 5 The normal glycogen storage in liver of OLE group rats: (a) 50 mg/kg OLE group, (b) 100 mg/kg OLE group and (c) 200 mg/kg OLE group (PAS)

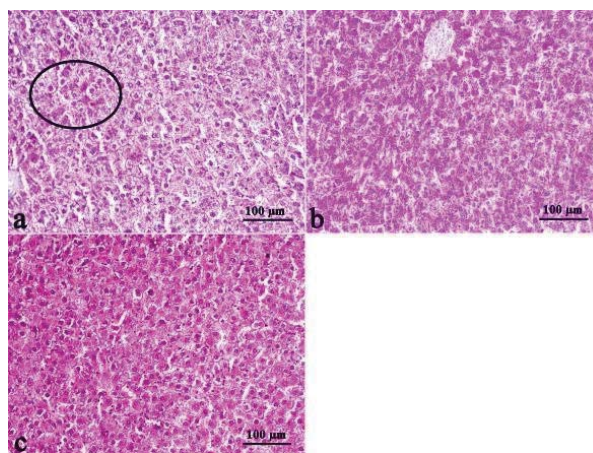


Fig. 6 The liver tissue following OLE exposure in CIS rats: (a) CIS+50 mg/kg OLE group, decreased Kupffer cell activation (inside of circle symbol), (b) The glycogen accumulation in liver of CIS+100 mg/kg OLE group, (c) Liver histology similar to controls in CIS+200 mg/kg OLE group (PAS)

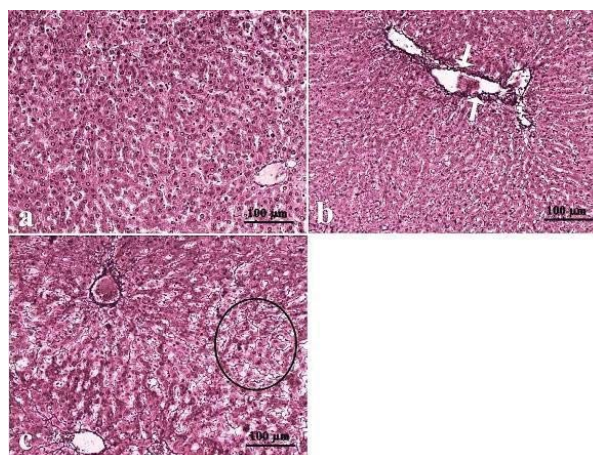


Fig. 7 Liver in control and CIS group rats: (a) The normal architecture of liver from control rats, (b) Increased intensity of fibrosis in portal veins of CIS group rat liver (arrows), (c) Increased fibrosis in intercellular space (inside of circle symbol), (Reticulin)

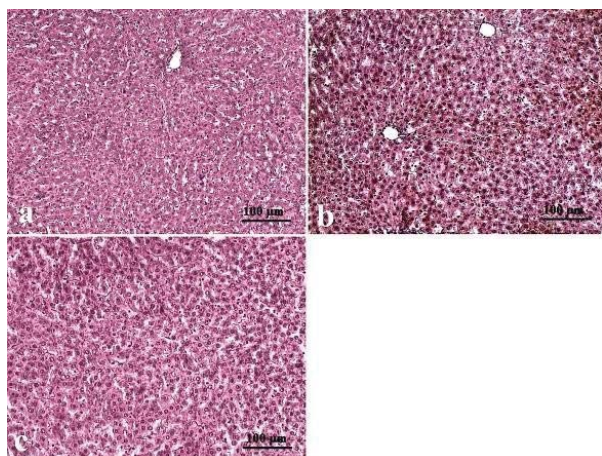


Fig. 8 The liver tissue in OLE group rats: a) CIS+50 mg/kg OLE group, b) CIS+100 mg/kg OLE group, c) CIS+200 mg/kg OLE group, (Reticulin)

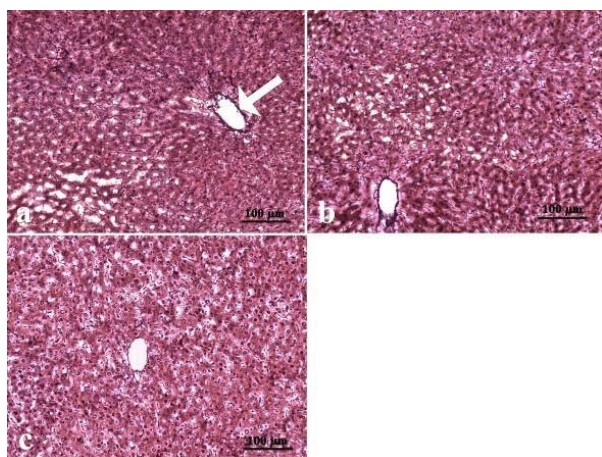


Fig. 9 a) and b) The decreased fibrosis in liver tissue following 50 mg/kg and 100 mg/kg OLE exposure in CIS rats, slightly fibrosis in portal veins (arrow) and c) The normal architecture similar to controls in CIS+200 mg/kg OLE group, (Reticulin)

IV. DISCUSSION

Hepatotoxicity is one of the most common liver problems and occurs when a body is exposed to chemotherapy drugs [25]. Many studies have focused on the alternative approach to protect CIS-induced hepatotoxicity using natural products-derived antioxidants [26]. Our study produced two observations with important implications. CIS treatment is harmful to liver and OLE treatment is beneficial in protecting against CIS-induced hepatic injury.

Although CIS-caused nephrotoxicity has been very well documented, hepatotoxicity has been rarely characterized and is less studied. Whereas, CIS is significantly taken up in human liver and that the drug produces hepatic damages [27]. In our study, the balance between oxidant and antioxidant system seemed to be disturbed due to CIS treatment. In the present study, significant increases in MDA concentration were observed in the liver, indicating increased lipid

peroxidation. The main breakdown product of oxidized lipids is the MDA and determining the concentration of MDA is one of the most popular methods for studying oxidative stress magnitude [28]. Recent studies have shown that oxidative stress and its responses are relevant to the physiological function of the liver and the development of liver injury [29]. Functional oxidative modifications of cellular proteins, both reversible and irreversible, are a causal step in cellular dysfunction. Redox-sensitive proteins with important cellular functions are important to defense in liver cells [30]. Changes in antioxidant enzymes and their protective mechanisms are early indicators of cellular susceptibility to oxidant injury caused by ROS. Modulation of oxidative stress plays an important role in the resistance to anticancer therapies [31].

Antioxidants can eliminate free oxygen radicals that appear in the body after radiation or chemotherapeutic agent exposure [32]. According to our findings, OLE could prevent membrane lipid peroxidation caused by MDA in liver and it could protect tissue from the harmful effects of CIS by increasing the level of reduced TAC. The previous studies have reported the beneficial physiological and pharmacological properties of OLE. One of its most prominent properties is its strong antioxidant activity, mainly due to the presence of hydroxyl groups in its chemical structure which could donate hydrogen to prevent oxidation [33]. The high antioxidative potential of the OLE was presented in different experimental models: in ethanol and cold stress-induced gastric ulcers [34], [35], in cerebral ischemia and reperfusion [36] and in hypertensive rats [37]. Additionally, OLE caused a significant increase of antioxidant status in erythrocytes [38], [39]. Moreover, the treatment with OLE decreased tissue MDA in aged rats [40]. Nevertheless, these comments are not based on full dose-response studies, and a more accurate investigation of the relative properties of these olive oil phenolics as biological antioxidants will be worthwhile [41], [42]. At this point, our study is one of studies contributing to dose-response studies. We established that OLE administration dose dependently increased antioxidant capacity (50 and 100 mg/kg). Especially, 200 mg/kg OLE exhibited powerful antioxidant activity in liver against CIS exposure.

A wide range of studies focus especially on substances causing oxidative DNA damage. CIS-induced oxidative DNA damage, specifically 8-OHdG lesions, has been demonstrated in both animal models and in humans [43]. Our study revealed that the highest concentration of the OLE exhibited the highest decrease in the number of cells with DNA damage in the liver samples treated with CIS. Efficiency of treatment with the OLE against CIS-induced DNA damage might be explained by the mechanisms reported by some authors that OLE increased the cells' antioxidant capacity by stimulating the synthesis of antioxidant enzymes and helped maintain their activity during oxidative stress [44]. It was shown that phenolic components such OLE had a higher antioxidant activity than vitamin C and vitamin E [45]. The olive phenolics prevented the H₂O₂-induced and phorbol myristate acetate-induced DNA damage [46]. Recently, the protective effects of OLE on sister chromatid exchange (SCE) and

chromosome aberration (CA) were found in cultured human blood cells treated with permethrin [47]. Additionally, OLE influenced the structure and stability of the DNA helix [48]. Our positive results showed that OLE dose-dependently has genoprotective feature on CIS-induced 8-OHdG lesions and altered DNA repair was a consequence of OLE exposure in liver cells. Moreover, these results were paralleled by increased anti-oxidant defense capacity and decreased TOS response in liver.

To assess the functional aspects, biochemical alterations in our study included elevated levels of AST, ALT and LDH in the blood after CIS treatment. AST and ALT are often associated with an increased release oxidative insult of CIS lead to damage in hepatocytes [49]. Cell necrosis leads to a rise in the concentration of the LDH enzyme in serum and tissue. The LDH released into the medium provides an index of cell death and membrane permeability to LDH, and an increase in LDH activity in the medium occurs as a result of cell membrane disintegration and enzyme leakage [50]. Thus, the increased activities of serum enzymes is mainly due to the leakage of these enzymes largely from the liver cytosol into the blood stream [51], which gives an indication of the abnormal function of liver. ROS can act as a molecular trigger of CIS and can attack the biological membranes directly [52]. Our results are in agreement with the commonly accepted view that serum level of transaminase returns to normal with healing of hepatic parenchyma and the regeneration of hepatocytes [53]. OLE appears to be effective in reducing the injurious effect of CIS observed in the present study. OLE is an indication of stabilization of plasma membrane, as well as repair of hepatic tissue damage caused by CIS. OLE is shown to be the effective antioxidant in protecting the 2,2'-azo-bis(2-amidinopropane) dihydrochloride-induced lipid peroxidation of the erythrocytes membranes [54]. Besides, scavenging of aqueous peroxy radicals at the surface of membranes, as well as scavenging of lipid peroxy radicals within the membranes, seems to play a considerable part in antioxidant activity of lipophilic antioxidants as OLE [55].

Our histopathological manifestations confirmed the biochemical changes in liver. The common findings in CIS-treated rats were fibrosis, inflammation, sinusoidal dilatations, congestion, hemorrhage, diminished glycogen content, focal necrosis and also diffuse hepatic necrosis. CIS caused an important histological sign by increasing fibrosis content in liver [56]. Current knowledge suggest that the inflammatory mediators and oxidative stress are actively involved in hepatic fibrogenesis [57], [58]. In agreement with our histological findings, CIS has been shown to activate inflammatory cells [59]. The administration of OLE decreased lymphocyte infiltration and activation of Kupffer cells in a dose-dependent manner. Thus, the suppression of them with OLE might contribute to deactivation of fibrogenic potential in our study. Because, OLE presented significant immunomodulatory properties in the liver by oxidative stress regulation. On the other hand, CIS has another critical side-effect as hemorrhage [60]. Moreover, CIS was considered in high risk for vascular disorders [61]. In present study, the OLE could save the liver

from congestion, sinusoidal dilatations and also hemorrhage. It was reported that OLE reduced microvascular leakage as well as leukocyte adhesion and ROS formation, while capillary perfusion was protected [62]. Again, CIS altered the activities of gluconeogenesis enzymes in hepatocytes [63]. Our present data indicated that OLE resulted in the overall improvement of glycogenesis as evident by higher of glycogen deposits as compared to CIS group. In addition, consistent with the findings of this study, in liver of the animals treated with CIS was recorded diffuse degenerative changes and necrosis [64]. Whereas, 200 mg/kg OLE could decrease the degree and severity of necrosis after CIS therapy. Studies have suggested that oxidative stress might a causative agent of cell death in many different pathological states and in various models of toxic hepatic failure including CIS [65]. In the present study, disappearance of such morphological changes in the liver tissues of CIS-treated rats given evidence of antioxidant and anti-inflammatory properties of OLE.

In this study, OLE was tested for the first time for reducing the toxicity of anticancer drug. Our results showed that OLE dose-dependently has protective feature in the CIS-induced liver damages and might be considered a potential candidate to protect hepatocytes against the deleterious effects of cancer chemotherapy.

REFERENCES

- [1] Rasouljan B, Kaeidi A, Pourkhodad S, Dezfoulian O, Rezaei M, Wahhabaghai H, Alirezaei M (2014) Effects of pretreatment with single-dose or intermittent oxygen on Cisplatin-induced nephrotoxicity in rats *Nephro-urology monthly* 6:e19680 doi:10.5812/numonthly.19680.
- [2] Uozumi J, Ueda T, Yasumasu T, Koikawa Y, Naito S, Kumazawa J, Sueishi K (1992) Platinum accumulation in the kidney and liver following chemotherapy with cisplatin in humans, *International urology and nephrology* 25:215-220.
- [3] Cozzaglio L, Doci R, Colella G, Zunino F, Casciarri G, Gennari L, Colla G (1990) A feasibility study of high-dose cisplatin and 5-fluorouracil with glutathione protection in the treatment of advanced colorectal cancer *Tumori* 76:590-594.
- [4] Wang Y et al. (2010) Specific hemosiderin deposition in spleen induced by a low dose of cisplatin: altered iron metabolism and its implication as an acute hemosiderin formation model *Current drug metabolism* 11:507
- [5] Dong Z, Atherton S (2007) Tumor necrosis factor- α in cisplatin nephrotoxicity: A homebred foe? *Kidney international* 72:5-7.
- [6] Rao M, Rao M (1998) Protective effects of cystone, a polyherbal ayurvedic preparation, on cisplatin-induced renal toxicity in rats *Journal of ethnopharmacology* 62:1-6.
- [7] Barbaro B, Toietta G, Maggio R, Arciello M, Tarocchi M, Galli A, Balsano C (2014) Effects of the olive-derived polyphenol oleuropein on human health *International journal of molecular sciences* 15:18508-18524 doi:10.3390/ijms151018508.
- [8] Fabiani R, Rosignoli P, De Bartolomeo A, Fuccelli R, Servili M, Montedoro GF, Morozzi G (2008) Oxidative DNA damage is prevented by extracts of olive oil, hydroxytyrosol, and other olive phenolic compounds in human blood mononuclear cells and HL60 cells *The Journal of nutrition* 138:1411-1416.
- [9] Casamenti F, Grossi C, Rigacci S, Pantano D, Luccarini I, Stefani M (2015) Oleuropein Aglycone: A Possible Drug against Degenerative Conditions. In Vivo Evidence of its Effectiveness against Alzheimer's Disease *Journal of Alzheimer's disease*: JAD 45:679-688.
- [10] Quirantes-Piné R, Lozano-Sánchez J, Herrero M, Ibáñez E, Segura-Carretero A, Fernández-Gutiérrez A (2013) HPLC-ESI-QTOF-MS as a Powerful Analytical Tool for Characterising Phenolic Compounds in Olive-leaf Extracts *Phytochemical Analysis* 24:213-223.
- [11] Srivastava R, Farookh A, Ahmad N, Misra M, Hasan S, Husain M (1996) Evidence for the involvement of nitric oxide in cisplatin-induced toxicity in rats *Biometals* 9:139-142.

- [12] Waseem M, Bhardwaj M, Tabassum H, Raisuddin S, Parvez S (2015) Cisplatin hepatotoxicity mediated by mitochondrial stress Drug and chemical toxicology:1-8 doi:10.3109/01480545.2014.992437.
- [13] Ademiluyi AO, Obogh G, Agbebi OJ, Boligon AA, Athayde ML (2014) Sorghum (Sorghum bicolor (L.) Moench) Leaf Sheath Dye Protects Against Cisplatin-Induced Hepatotoxicity and Oxidative Stress in Rats Journal of medicinal food 17:1332-1338.
- [14] Andreadou I et al. (2009) Metabonomic identification of novel biomarkers in doxorubicin cardiotoxicity and protective effect of the natural antioxidant oleuropein NMR in Biomedicine 22:585-592.
- [15] Yagi K (1984) Assay for blood plasma or serum Methods Enzymol 105:328-331.
- [16] Gil H-W, Seok S-J, Jeong D-S, Yang J-O, Lee E-Y, Hong S-Y (2010) Plasma level of malondialdehyde in the cases of acute paraquat intoxication Clinical toxicology 48:149-152.
- [17] Bolukbas C, Bolukbas FF, Horoz M, Aslan M, Celik H, Erel O (2005) Increased oxidative stress associated with the severity of the liver disease in various forms of hepatitis B virus infection BMC infectious diseases 5:95.
- [18] Li D et al. (2014) Exercises in Hot and Humid Environment Caused Liver Injury in a Rat Model PLoS One 9:e111741.
- [19] Abdel-Wahab B, Metwally M (2011) Ginkgo biloba enhances the anticonvulsant and neuroprotective effects of sodium valproate against kainic acid-induced seizures in mice J Pharmacol Toxicol 6:679-690.
- [20] Zubair A, Jamal S, Mubarik A (2009) Morphometric analysis of hepatic steatosis in chronic hepatitis C infection Saudi journal of gastroenterology: official journal of the Saudi Gastroenterology Association 15:11.
- [21] Cheong HH, Masilamani J, Chan CYE, Chan SY, Phan TT (2013) Metabolically functional hepatocyte-like cells from human umbilical cord lining epithelial cells Assay and drug development technologies 11:130-138.
- [22] Teixeira RB, Kelley J, Alpert H, Pardo V, Vaamonde CA (1982) Complete protection from gentamicin-induced acute renal failure in the diabetes mellitus rat Kidney international 21:600-612.
- [23] Cure E, Kirbas A, Tumkaya L, Cure MC, Kalkan Y, Yilmaz A, Yuce S (2015) Protective effect of infliximab on methotrexate-induced liver injury in rats: Unexpected drug interaction Journal of cancer research and therapeutics 11:164.
- [24] Du F et al. (2015) Morphology and Molecular Mechanisms of Hepatic Injury in Rats under Simulated Weightlessness and the Protective Effects of Resistance Training PLoS One 10.
- [25] Brackett J, Schafer ES, Leung DH, Bernhardt MB (2014) Use of allopurinol in children with acute lymphoblastic leukemia to reduce skewed thiopurine metabolism Pediatric blood & cancer 61:1114-1117.
- [26] Palipoch S, Punsawad C, Koomhin P, Suwannalert P (2014) Hepatoprotective effect of curcumin and alpha-tocopherol against cisplatin-induced oxidative stress BMC complementary and alternative medicine 14:111.
- [27] Heskeith M, Twaddell T, Finn A A possible role for cisplatin (DDP) in the transient hepatic enzyme elevation noted after ondansetron administration. In: Proc Am Assoc Clin Oncol, 1990. vol 323. p b28.
- [28] Oleszko A et al. (2015) Application of FTIR-ATR Spectroscopy to Determine the Extent of Lipid Peroxidation in Plasma during Haemodialysis BioMed research international 2015.
- [29] Rahman K (2007) Studies on free radicals, antioxidants, and co-factors Clinical interventions in aging 2:219.
- [30] Attia SM (2010) Deleterious effects of reactive metabolites Oxidative medicine and cellular longevity 3:238-253.
- [31] Pons DG, Nadal-Serrano M, Torrens-Mas M, Valle A, Oliver J, Roca P (2015) UCP2 inhibition sensitizes breast Cancer cells to therapeutic agents by increasing oxidative stress Free Radical Biology and Medicine 92:117-126 doi:10.1016/j.jphs.2014.11.009.
- [32] Kim HJ et al. (2015) Glutamine protects against cisplatin-induced nephrotoxicity by decreasing cisplatin accumulation Journal of pharmacological sciences 127:117-126 doi:10.1016/j.jphs.2014.11.009.
- [33] Hassen I, Casabianca H, Hosni K (2014) Biological activities of the natural antioxidant oleuropein: Exceeding the expectation—A mini-review Journal of Functional Foods.
- [34] Dekanski D, Janicijevic-Hudomal S, Ristic S, Radonjic NV, Petronijevic ND, Piperski V, Mitrovic DM (2009a) Attenuation of cold restraint stress-induced gastric lesions by an olive leaf extract Gen Physiol Biophys 28:135-142.
- [35] Dekanski D, Ristić S, Mitrović D (2009b) Antioxidant effect of dry olive (Olea europaea L.) leaf extract on ethanol-induced gastric lesions in rats Mediterranean Journal of Nutrition and Metabolism 2:205-211.
- [36] Dekanski D, Selaković V, Piperski V, Radulović Ž, Korenić A, Radenović L (2011) Protective effect of olive leaf extract on hippocampal injury induced by transient global cerebral ischemia and reperfusion in Mongolian gerbils Phytomedicine 18:1137-1143.
- [37] Dekanski D, Mihailović-Stanojević N, Milanović GJ, Jovović Đ, Miloradović Z (2014) Effects of high dose olive leaf extract on haemodynamic and oxidative stress parameters in normotensive and spontaneously hypertensive rats Journal of the Serbian Chemical Society 79:1085-1097.
- [38] Kim Y, Choi Y, Park T (2010) Hepatoprotective effect of oleuropein in mice: mechanisms uncovered by gene expression profiling Biotechnology journal 5:950-960.
- [39] Oliveras-López M-J, Molina JJM, Mir MV, Rey EF, Martín F, de la Serrana HL-G (2013) Extra virgin olive oil (EVOO) consumption and antioxidant status in healthy institutionalized elderly humans Archives of gerontology and geriatrics 57:234-242.
- [40] Çoban J, Öztezcan S, Doğru-Abbassoğlu S, Bingül I, Yeşil-Mızrak K, Uysal M (2014) Olive leaf extract decreases age-induced oxidative stress in major organs of aged rats Geriatrics & gerontology international 14:996-1002.
- [41] de la Puerta R, Ruiz Gutierrez V, Hoult JR (1999) Inhibition of leukocyte 5-lipoxygenase by phenolics from virgin olive oil Biochemical pharmacology 57:445-449.
- [42] Zbidi H, Salido S, Altarejos J, Perez-Bonilla M, Bartegi A, Rosado JA, Salido GM (2009) Olive tree wood phenolic compounds with human platelet antiaggregant properties Blood cells, molecules & diseases 42:279-285 doi:10.1016/j.bcmd.2009.01.001.
- [43] Kodama A et al. (2014) Albumin fusion renders thioredoxin an effective anti-oxidative and anti-inflammatory agent for preventing cisplatin-induced nephrotoxicity Biochimica et Biophysica Acta (BBA)-General Subjects 1840:1152-1162.
- [44] Ghanema IA, Sadek KM (2012) Olive leaves extract restored the antioxidant perturbations in red blood cells hemolysate in streptozotocin induced diabetic rats World Academy of Science, Engineering & Technology 64:159-165.
- [45] Benavente-Garcia O, Castillo J, Lorente J, Ortuno A, Del Rio J (2000) Antioxidant activity of phenolics extracted from Olea europaea L. leaves Food Chemistry 68:457-462.
- [46] Roberto Fabiani, Patrizia Rosignoli, Angelo De Bartolomeo, Raffaella Fuccelli, Maurizio Servili, Gian Francesco Montedoro and Guido Morozi (2008) Oxidative DNA Damage Is Prevented by Extracts of Olive Oil, Hydroxytyrosol, and Other Olive Phenolic Compounds in Human Blood Mononuclear Cells and HL60 Cells, The Journal of Nutrition 138(8):1411-1416.
- [47] Turkez H, Togar B (2011) Olive (Olea europaea L.) leaf extract counteracts genotoxicity and oxidative stress of permethrin in human lymphocytes The Journal of toxicological sciences 36:531-537.
- [48] Mohamadi M, Afzali D, Esmaili-Mahani S, Mostafavi A, Torzkadeh-Mahani M (2015) Spectroscopic and electrochemical studies of the interaction between oleuropein, the major bio-phenol in olives, and salmon sperm DNA Spectrochimica Acta Part A: Molecular and Biomolecular Spectroscopy 148:260-265.
- [49] Zheng X-N et al. (2013) Pu-erh Tea Powder Preventive Effects on Cisplatin-Induced Liver Oxidative Damage in Wistar Rats Asian Pacific journal of cancer prevention: APJCP 15:7389-7394.
- [50] Xu Y, Li J, Wang R (2012) Change in gastrocnemius dystrophin and metabolic enzymes and increase in high-speed exhaustive time induced by hypoxic training in rats, Sheng li xue bao:(Acta physiologica Sinica) 64:455-462.
- [51] El-Demerdash F, Yousef M, El-Naga NA (2005) Biochemical study on the hypoglycemic effects of onion and garlic in alloxan-induced diabetic rats Food and Chemical Toxicology 43:57-63.
- [52] Kaminsky VO, Piskunova T, Zborovskaya IB, Tchevkina EM, Zhivotovsky B (2012) Suppression of basal autophagy reduces lung cancer cell proliferation and enhances caspase-dependent and-independent apoptosis by stimulating ROS formation Autophagy 8:1032-1044.
- [53] Fouraschen SM et al. (2013) mTOR signaling in liver regeneration: Rapamycin combined with growth factor treatment World journal of transplantation 3:36.
- [54] Paiva-Martins F et al. (2009) Effects of olive oil polyphenols on erythrocyte oxidative damage Molecular nutrition & food research 53:609-616.

- [55] Paiva-Martins F, Gordon MH, Gameiro P (2003) Activity and location of olive oil phenolic antioxidants in liposomes Chemistry and physics of lipids 124:23-36.
- [56] Nasr AY (2013) Morphological, biochemical, histological, and ultrastructural protective effects of misoprostol on cisplatin induced-hepatotoxicity in adult male rats Saudi medical journal 34:1237-1247.
- [57] Dhoub IE-B, Lasram MM, Annabi A, Gharbi N, El-Fazaa S (2015) A comparative study on toxicity induced by carbosulfan and malathion in Wistar rat liver and spleen Pesticide Biochemistry and Physiology.
- [58] Domitrović R, Jakovac H, Marchesi VV, Šain I, Romić Ž, Rahelić D (2012) Preventive and therapeutic effects of oleuropein against carbon tetrachloride-induced liver damage in mice Pharmacological Research 65:451-464.
- [59] Narayana K (2012) Effects of l-ascorbic acid on two cycles of cisplatin-induced DNA double-strand breaks and phosphorylation of p53 in the liver Experimental and Toxicologic Pathology 64:495-502.
- [60] Kobatake K, Kato M, Mita K (2015) Advanced testicular cancer associated with life-threatening tumour lysis syndrome and choriocarcinoma syndrome Canadian Urological Association Journal 9:62.
- [61] Jiang Y et al. (2014) Effects of cisplatin on the contractile function of thoracic aorta of Sprague-Dawley rats, Biomedical reports 2:893-897.
- [62] Lapi D, Di Maro M, Mastantuono T, Battiloro L, Sabatino L, Muscariello E, Colantuoni A (2015) Effects of Oleuropein and Pinoreosinol on Microvascular Damage Induced by Hypoperfusion and Reperfusion in Rat Pial Circulation Microcirculation 22:79-90.
- [63] Naqshbandi A, Khan W, Rizwan S, Khan F (2012) Studies on the protective effect of flaxseed oil on cisplatin-induced hepatotoxicity Human & experimental toxicology 31:364-375.
- [64] Adejuwon A, Femi-Akinlosotu O, Omirinde J, Owolabi O, Afodun A (2014) Launaea taraxacifolia ameliorates cisplatin-induced hepato-renal injury Eur J Medicinal Plants 4:528-541.
- [65] Waseem M, Pandey P, Tomar B, Raisuddin S, Parvez S (2014) Ameliorative Action of Curcumin in Cisplatin-mediated Hepatotoxicity: An *in vivo* Study in Wistar Rats Archives of medical research 45:462-468.