

Gel-Based Autologous Chondrocyte Implantation (GACI) in the Knee: Multicentric Short Term Study

Shaival Dalal, Nilesh Shah, Dinshaw Pardiwala, David Rajan, Satyen Sanghavi, Charul Bhanji

Abstract—Autologous Chondrocyte Implantation (ACI) is used worldwide since 1998 to treat cartilage defect. GEL based ACI is a new tissue-engineering technique to treat full thickness cartilage defect with fibrin and thrombin as scaffold for chondrocytes. Purpose of this study is to see safety and efficacy of gel based ACI for knee cartilage defect in multiple centres with different surgeons. Gel-based Autologous Chondrocyte Implantation (GACI) has shown effectiveness in treating isolated cartilage defect of knee joint. Long term results are still needed to be studied. This study was followed-up up to two years and showed benefit to patients. All enrolled patients with a mean age of 28.5 years had an average defect size of 3 square centimeters, and were grade IV as per ICRS grading. All patients were followed up several times and at several intervals at 6th week, 8th week, 11th week, 17th week, 29th week, 57th week after surgery. The outcomes were measured based on the IKDC (subjective and objective) and MOCART scores.

Keywords—Knee, chondrocyte, autologous chondrocyte implantation, gel.

I. INTRODUCTION

DAMAGE to the knee joint cartilage never heals on its own. It heals giving poor quality of fibrous tissue which can lead to early arthritis restricting joint movement. Articular cartilage is a white, shiny, moisture tissue comprising less than 5% cells, about 35% extracellular matrix of mostly collagen type II and proteoglycans and about 60% water, and provides outstanding biomechanics. Hence the tissue looks simple in its structure; the biomechanical properties are linked to the complex nanostructured architecture of the tissue, which partly relates to the high water content bound to macromolecules. As articular cartilage has only limited ability to regenerate, many treatment modalities have been developed during the past several decades to treat symptomatic articular cartilage injuries. Microfracture or marrow stimulation, an older procedure used to treat cartilage defect gives slightly better quality of fibrous tissue. Autologous chondrocyte implantation (ACI) is a well-established procedure and known to regenerate hyaline or hyaline like cartilage. Autologous chondrocyte transplantation has changed the paradigm of the treatment of cartilage defects from repair to regeneration. Autologous chondrocyte implantation is a technique in which cells are delivered in debrided cartilage defect and covered with periosteal flap harvested from tibia. Drawbacks in this technique are leakage of cells, harvesting of periosteal flap, hypertrophy of cartilage, difficulty in treating irregular defect, difficulty in suturing on cartilage. To resolve these problems,

Dr. Shaival Dalal is with the Civil Hospital, India (e-mail: shaival_dalal@yahoo.co.in).

Gel based autologous chondrocyte implantation fibrin is used as scaffold for implanting chondrocyte cells onto cartilage defect. As fibrin and cell mixture is semi viscous, it has a lot of advantages. It covers irregular defect easily, does not require periosteal flap thus eliminating the chance of cell leakage and also improving cell distribution [1]-[3]. Moreover, due to viscosity, the surgeon has control over cell implantation in defect region and surgical time is also reduced. This two year follow up study showed good results. Thus, this technique can be used as an effective technique to treat cartilage defect [4], [5].

II. MATERIALS AND METHODS

Ten patients treated with gel based autologous chondrocyte implantation from 2011 to 2013, every patient informed consent was obtained, and each hospital ethics committee approval was taken.

We have selected total 10 patients between age group of 26 years to 51 years in which 7 male and 3 female patients were enrolled.

Defect size was ranging from smallest 17 x 5 square centimeter to largest 22 x 25 square centimeters. All defects were ICRS grade IV size. 5 cases had defect on lateral femoral condyle and 5 had defect of medial femoral condyle.

Graft was harvested by arthroscopy from non-weight bearing zone with 6 mm harvester. Graft was collected in tissue harvesting bottle provided by laboratory CRM KIT TM. Using cold chain harvested graft send to GMP, GCP, and GMP Certified Regenerative Medical Services PVT LTD laboratory at Lonavala, Pune.

At laboratory after receipt of cartilage biopsy specimen, isolation of cells was done through enzymatic digestion using collagenase solution in CRM Kit TM. In 25 cm² tissue culture flask containing DMEM medium with fetal bovine serum in CRM Kit TM, these isolated cells were seeded and were then cultured for 14 days as primary culture. At interval of every 3 days medium was changed in the tissue culture flask throughout entire culture period. These cells were then sub-cultured by trypsinizing, harvesting and plating to fresh tissue culture flasks with a larger surface area, once confluency was reached at specific culture passage.

Culture process was of 4 to 5 weeks when a sufficient number of cells were cultured; the cells were harvested and transferred into vials including approximately 12 million cells per vial. After cell culture process is completed, cells are shipped to respected hospital with cold chain with data logger to monitor temperature.

Second stage surgery is performed with small arthrotomy, defect is visualized and debrided up to normal cartilage and edges are made sharp and undermined with knife to hold gel. Drill holes made with using 2mm drill bit, drilling done up to 2 mm depth. Holes made for graft anchoring purpose and bone wax is used to achieve hemostasis. After achieving homeostasis, saline wash was given to clean defect and surrounding area. Once defect is prepared defect brought in gravity dependent position and tested with 2ml saline for gravity dependency and volume requirement. Once defect is ready for implantation Regenerative Medical Services PVT LTD trained staff prepares cell-gel with mixing chondrocyte cells with fibrin it takes 5 to 7 minutes. After preparation, Duplojet syringe is provided loaded with fibrin, thrombin and chondrocyte.



Fig. 1 Gel-based chondrocyte cells with fibrin implanted at involved site

Implantation is done gradually drop by drop spreading gel over defect from periphery to centre. Implantation has to be done in one flow and there should not be lamination of gel. Finally, we have to maintain contour. While putting gel there will be threads formation which can be easily cut by scissors. Once implantation is completed, same position is maintained for 6 to 8 minutes to solidify gel.

Once gel is solidified knee gradually fully flexed and extended for 3 to 4 times to check stability of graft. Once graft is stable, incision is closed in layers.

Post surgery knee brace is given to immobilize knee for 48 - 72 hours (as per defect size).

After 48 -72 hours rehabilitation is started as per protocol. Upto 6 weeks, non-weight bearing with crutches assisted walk is allowed and after 6 to 8 weeks, partial weight bearing is allowed. At 8 weeks, full weight bearing is permitted.

The efficacy analysis was performed on Per-Protocol (PP) Population. Per-Protocol Population: All patients who completed the study visit per protocol without any major protocol deviations. MOCART Score as per MRI were

summarized in terms of frequency count (n) and percentages (%) at Visit 7 and Visit 10 for all categories (Degree of defect repair and filling of the defect, integration to border zone, surface of the repair tissue, structure of the repair tissue, signal intensity of the repair tissue, subchondral lamina, subchondral bone, adhesion and effusion). Descriptive statistics (n, Mean, SD, Median and Range) were provided for IKDC subjective knee evaluation score at Visit 1, Visit 9 and Visit 10. Change in IKDC Subjective Knee Evaluation Score from Visit 1 to Visit 9 and from Visit 1 to Visit 10 was also summarized [6], [7], [17].

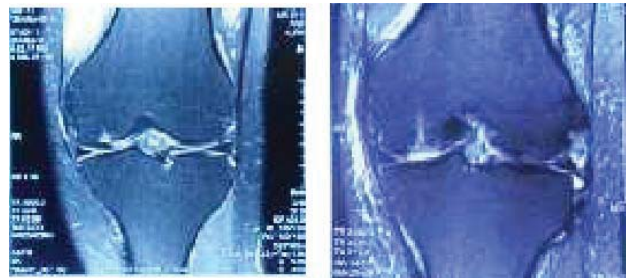


Fig. 2 Pre-operative and post-operative MRI antero-posterior views

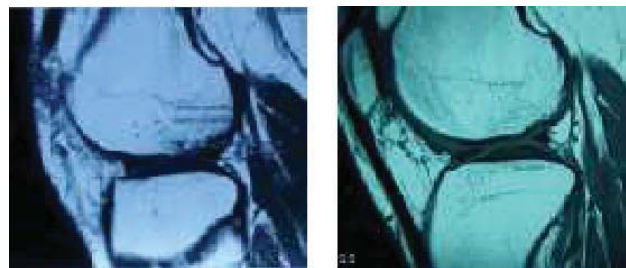


Fig. 3 Pre-operative and post-operative MRI lateral views

III. STATISTICAL ANALYSIS

A. Efficacy Results

1) MOCART Evaluation

All the MOCART parameters were evaluated at Visit 7 and Visit 10. At Visit 7, a total of 6 patients had MOCART score of 20, however at visit 10, 4 patients had the same score and 1 patient each had the score 15 and 10, respectively.

At Visit 7, a total of 2 patients had MOCART score as 15; however, at Visit 10, 1 patient each had the score as 15 and 20, respectively. There was no change in MOCART score for 1 patient who had the same score as 5 at both Visit 7 and Visit 10. At Visit 7, 1 patient who had MOCART score as 0 had the score as 5 at Visit 10.

2) IKDC Knee Evaluation Subjective Knee Evaluation

A subjective IKDC knee evaluation was performed at Visit 1, Visit 9, and Visit 10. The mean (SD) subjective IKDC scores at Visit 1, Visit 9 and Visit 10 were 43.76 (14.214), 76.66 (12.784), and 81.01 (12.123), respectively. The mean (SD) change in subjective IKDC score from Visit 1 to Visit 10 was higher (37.25 [15.621]) than the mean (SD) change from

Visit 1 to Visit 9 (32.90 [18.013]).

IKDC SCORE (subjective and objective) increased from 42.92 to 72.50 in 1 year 1 month and improvement maintained at 24 months. No changes were observed in majority of the patients for MOCART evaluation score across variables at visit 10 (57th week) compared to visit 7 (11th week)

IV. RESULTS

We have treated total 10 patients for period of 24 months and all patients showed very good results. None of the patients have shown any severe adverse effect. All patients are symptomatically doing well, as well as IKDC score increased from 42.92 to 72.50 in 1 year 1 month follow up. MOCART evaluation score done on 11th week and 57th week showed no changes in majority of patients.

TABLE I
RESULTS OF 10 PATIENTS TREATED BY GEL BASED CHONDROCYTE IMPLANTATION

No.	Patient Initial	Age	Sex	Knee	Defect Size(mm)	ICRS Grading	IKDC Score		Mocart Score	
							Pre-op	Post-op	At visit 7	At visit 10
1	NMM	28	M	Left	25*22*4	Grade IV	70	78.1	60	70
2	PK	26	M	Right	32*5	Grade IV	36.7	79.3	80	70
3	PC	51	M	Left	22*20	Grade IV	45.9	60.9	80	65
4	RV	28	M	Left	14*20*3	Grade IV	40.2	56.3	50	50
5	PR	24	F	Left	24*21*5	Grade IV	26.4	78.2	45	25
6	AAK	22	M	Right	22-*16*7	Grade IV	22.9	79.3	60	95
7	RRS	31	F	Left	22*4	Grade IV	41.4	60.9	85	75
8	MB	44	M	Left	20*20	Grade IV	60.9	86	85	80
9	PMP	27	F	Right	17*5	Grade IV	44.8	85	85	80
10	RV	28	M	Left	14*20*3.3	Grade IV	40.2	56.3	50	50

V. DISCUSSION

The surgical procedure of conventional ACI can be summarized as consisting of debridement of the cartilage defect, harvesting of periosteum, suturing the periosteum, and chondrocyte implantation. Among these procedures, periosteum suturing is a difficult and time-consuming procedure for the surgeon, and periosteal harvesting and periosteum suturing procedures have some risk of patient morbidity. Conventional ACI is not preferred because of the periosteal grafting component which requires an additional operation to harvest the periosteum. In addition, for water-tight suturing of the periosteal graft to the surrounding cartilage, a large surgical incision is required, thus presenting the potential problem of subsequent leakage of injected cells from the defect as well as graft detachment.

The collagen-membrane technique eliminates the need for a second incision for periosteal harvest as well as reducing the long surgical time and extensive suturing. However, there are potential problems associated with this method also which include loss of critical chondrocytes due to repeated manipulation of the seeded membrane and the possibility of detachment of the membrane from the cartilage defect.

Gel based autologous chondrocyte implantation is a very effective treatment for cartilage defect. As it has a gel based scaffold, it is viscous in consistency, thus covering irregular defects well. Moreover, it has better cell distribution due to liquid scaffold.

As gel gets solidified in 6 to 7 minutes, periosteal flap is not required. In addition, it reduces surgical time and skill too. It is a very simple and a faster surgical technique [8]. The efficacy of the ACI techniques in which cells are combined with bioactive resorbable biomaterials, such as a Bilayer type I/III collagen membranes, Hyaluronan polymer, copolymers of

polylactin and polyglactin, collagen gel, and fibrin glue, depends on their biocompatibilities, cytotoxicities, and biodegradability as well as their ability to offer adequate fixation to Subchondral bone and host cartilage [9]. Optimal delivery combines an appropriate rate of biodegradability with an ability to allow cells to multiply and produce matrix components. Fibrin glue is used to provide tissue adhesion for graft fixation during ACI. However, the effect of fibrin glue on transplanted chondrocytes remains controversial [10], [11]. In an *in vivo* study of chondrocyte transplantation in fibrin glue by Itay et al, cartilage lesion repair was limited [12], and in a later study, Brittberg et al. concluded that fibrin glue is unsuitable for use as a scaffold for treating osteochondral defects [3]. Other studies also gave similar results [13]-[15].

In the surgical procedures, in order to prevent both the formation of fibrocartilaginous tissue and detachment of the injected cell and fibrin mixture, bleeding control is very important. Fortunately, fibrin sealants are biological adhesives that mimic the final step of the coagulation cascade and therefore help with the bone bleeding control.

In a study by Myung Ku Kim et al, all patients achieved clinical and functional improvements up to 24 months following surgery. The mean scores of Henderson classification (MRI evaluation) significantly improved from 14.4 to 7(P=0.001) and no graft associated complications were noted. Arthroscopic assessments performed 12 months postoperatively produced nearly normal (grade II) International Cartilage Repair Society scores in 8 of the 10 patients [16].

The study by Nam Yong Choi et al showed an improvement of tKSS-A (telephone Knee Society Score-A) from 43.5 to 89.7 and an improvement of tKSS-B (TELEPHONE Knee Society Score- B) from 50.6 to 89.38. The total improvement was from 94.18 ± 31.43 to 179.10 ± 24.69 ($P < 0.05$). [17].

VI. CONCLUSIONS

Gel based Autologous Chondrocyte Implantation is a tolerable, safe, and effective treatment in most patients. IKDC score showed marked improvement in preoperative and post-operative visits. The MOCART score result is also good. This study adds clinical evidence on the GACI procedure; it gives detail about highlights of GACI procedure's usefulness and surgical approach to the treatment for knee OCD. However, further studies with long term follow-up are needed [18].

VII. LEVEL OF EVIDENCE

Prospective case control study with no control group, Level III.

REFERENCES

- [1] Messner K, Maletius W (1996) The long-term prognosis for severe damage to weight-bearing cartilage in the knee: a 14-year clinical and radiographic follow-up in 28 young athletes. *ActaOrthopScand* 67:165–168.
- [2] Gilbert JE (1998) Current treatment options for the restoration of articular cartilage. *Am J Knee Surg* 11:42–46.
- [3] Brittberg M (1999) Autologous chondrocyte transplantation. *ClinOrthopRelat Res* 367(Suppl): S147–S155.
- [4] Erggelet C, Sittinger M, Lahm A (2003) The arthroscopic implantation of autologous chondrocytes for the treatment of full thickness cartilage defects of the knee joint. *J Arthroscopy* 19:108–110
- [5] Brittberg M, Lindahl A, Nilsson A, Ohlsson C, Isaksson O, Peterson L (1994) Treatment of deep cartilage defects in the knee with autologous chondrocyte transplantation. *N Engl J Med* 331:889–895.
- [6] Henderson IJ, Tuy B, Connell D, Oakes B, Hettwer WH (2003) Prospective clinical study of autologous chondrocyte implantation and correlation with MRI at three and 12 months. *J Bone Joint Surg Br* 85:1060–1066.
- [7] Hendrickson DA, Nixon AJ, Grande DA et al (1994) Chondrocyte-fibrin matrix transplants for resurfacing extensive articular cartilage defects. *J Orthop Res* 12:485–497.
- [8] Kirilak Y, Pavlos NJ, Willers CR et al (2006) Fibrin sealant promotes migration and proliferation of human articular chondrocytes: possible involvement of thrombin and protease-activated receptors. *Int J Mol Med* 17:551–558.
- [9] Marlovits S, Hombauer M, Truppe M, Vecsei V, Schlegel W(2004) Changes in the ratio of type-I and type-II collagen expression during monolayer culture of human chondrocytes. *J Bone Joint Surg Br* 86:286–295.
- [10] Micheli LJ, Browne JE, Erggelet C et al (2001) Autologous chondrocyte implantation of the knee: multicenter experience and minimum 3-year follow-up. *Clin J Sport Med* 11:223–228.
- [11] Minas T, Peterson L (1999) Advanced techniques in autologous chondrocyte transplantation. *Clin Sports Med* 18:13–44.
- [12] Itay S, Abramovici A, Nevo Z (1987) Use of cultured embryonal chick epiphyseal chondrocytes as grafts for defects in chick articular cartilage. *ClinOrthopRelat Res* 220:284–303.
- [13] Munirah S, Samsudin OC, Chen HC, Salmah SH, Aminuddin BS, Ruszymah BH (2007) Articular cartilage restoration in loadbearing osteochondral defects by implantation of autologous chondrocyte-fibrin constructs: an experimental study in sheep. *J Bone Joint Surg Br* 89:1099–1109.
- [14] Peterson L, Brittberg M, Kiviranta I, Akerlund EL, Lindahl A (2002) Autologous chondrocyte transplantation. Biomechanics and long-term durability. *Am J Sports Med* 30:2–12.
- [15] Peterson L, Minas T, Brittberg M, Nilsson A, Sjogren-Jansson E, Lindahl A (2000) Two-to 9-year outcome after autologous chondrocyte transplantation of the knee. *ClinOrthopRelat Res* 374:212–234.
- [16] Myung Ku Kim, Sungwook Choi, Sanag Rim Kim, In Suk Oh, Man Hee Won (2009) Autologous Chondrocyte Implantation in the Knee Using Fibrin. *Knee Surgery Sports Traumatology Arthroscopy* 09/2009; 18(4): 528-34.
- [17] Nam-Yong Choi et al (2010) Gel-type autologous chondrocyte implantation for treatment of articular defects of the knee. *BMC Musculoskelet Disord* 2010; 11-103
- [18] Tegner Y, Lysholm J (1985) Rating systems in the evaluation of knee ligament injuries. *ClinOrthopRelat Res* 198:43–49.
- [19] Wakitani S, Kimura T, Hirooka A et al (1989) Repair of rabbit articular surfaces with allograft chondrocytes embedded in collagen gel. *J Bone Joint Surg Br* 71:74–80 *Knee Surg Sports TraumatolArthrosc.*