

Histopathological Changes in Liver and Muscle of Tilapia Fish from QIRE Exposed to Concentrations of Heavy Metals

Justina I. R. Udotong

Abstract—Toxicity of copper (Cu), lead (Pb) and iron (Fe) to *Tilapia guineensis* was carried out for 4 days with a view to determining their effects on the liver and muscle tissues. *Tilapia guineensis* samples of about 10 - 14cm length and 0.2 – 0.4kg weight each were obtained from University of Calabar fish ponds and acclimated for three (3) days before the experimental set up. Survivors after the 96-hr LC₅₀ test period were selected from test solutions of the heavy metals for the histopathological studies. Histological preparations of liver and muscle tissues were randomly examined for histopathological lesions. Results of the histological examinations showed gross abnormalities in the liver tissues due to pathological and degenerative changes compared to liver and muscle tissues from control samples (tilapia fishes from aquaria without heavy metals). Extensive hepatocyte necrosis with chronic inflammatory changes was observed in the liver of fishes exposed to Cu solution. Similar but less damaging effects were observed in the liver of fishes exposed to Pb and Fe. The extent of lesion observed was therefore heavy metal-related. However, no pathologic changes occurred in the muscle tissues.

Keywords—Degenerative changes, heavy metal, hepatocyte necrosis, histopathology, toxicity.

I. INTRODUCTION

AT the mouth of Qua Iboe River estuary (QIRE) is located the Mobil Producing Nigeria Unlimited (MPNU), a subsidiary of Exxon Mobil, the largest crude oil and condensate producer in Nigeria. MPNU started crude oil production and processing at Qua Iboe Terminal (QIT) since 1970, discharging their wastewater through Douglas creek into the estuary which empties into the Atlantic Ocean. Crude oil production and processing wastewater has been shown to contain pollutants such as heavy metals amongst others [1], [2]. The major sources of the heavy metals in the Qua Iboe River estuary include the drilling mud and drill cuttings disposed of in the offshore environment of the Atlantic Ocean. Other sources include waste disposal from crude oil storage tanks bottom sediment and water. Qua Iboe river is a major river system in Akwa Ibom State. Residents depend on it for their fish, crayfish, periwinkle, oyster and other aquatic resources requirements.

According to [3], among the aquatic fauna, fish is the most susceptible to toxicants and are more vulnerable to metal contamination than any other aquatic fauna. Their work

covered determination of heavy metals in fish samples from river Kaduna, Nigeria. Of the over 54 elements that are known to affect fish, their work covered seven of them including lead and iron. Fish is found all over the world in several aquatic environments and are consumed in various forms.

A heavy metal exposure can produce a health effect directly at the site of contact or elsewhere in the body and the effect can be either immediate or delayed. The delayed health effect may take months or years to appear with cancer being a good example of a delayed health effect. Overtime, some chemicals such as heavy metals can build up in the body and cause long-term health effects. Chronic effects can also occur at home through chronic consumption of sublethal doses of the heavy metals through the food chain. Sometimes a human population can be exposed to a toxic substance from an experimental source. If the exposed population shows an increase in a certain health effect, that effect may be related to the toxic substance exposure. Many toxic effects tests are carried out on animals. Animal tests however are often good indicators of chemical toxicity and results are usually extrapolated to humans even though animals may differ in their reactivity as compared to humans. Also animal like fishes are smaller in size and their mechanisms for handling chemicals may be slightly different from that of humans. It is also noteworthy that some chemicals affect only certain target organs or target systems. Impairment of enzyme activity or defective formation of enzymes associated with heavy metal poisoning also results in reduction of hepatic xenobiotic metabolism. This may result in accumulation and consequent pathology of the liver. There has been a drop in fish catch in the recent past and it has resulted in growing level of worry among the fisherfolks whose means of livelihood has been threatened [2], [3].

Histopathology is one of the scientific tools that have been used as an endpoint in the assessment of toxic effect of substances [4]. The strategy of histopathological evaluations is that interactions between pollutants and biochemical and physiological functions in fish detected at sub-cellular, cellular or organ disturbances may indicate or lead to vital disturbances in reproduction success, growth and/or survival of the fish. Changes at such low levels of biological organization may irreversibly affect fish population sizes and quantities [2]. Although every tissue has some ability to metabolize chemicals, the liver is the major organ of metabolism or transformation of toxins. The kidneys lungs,

J. I. R. Udotong is with the Department of Biochemistry, Faculty of Basic Medical Sciences, University of Uyo, P. M. B. 1017, Uyo, Akwa Ibom State, Nigeria. (phone: 234-802-300-8643; e-mail: justinaudotong@uniuyo.edu.ng).

skin and gastrointestinal tract can also be involved in detoxification.

There is paucity of information in the literature on the concentrations of heavy metals pollutants in Qua Iboe River estuary and aquatic resources obtained from the estuary. It is feared that the Qua Iboe River estuary has recently undergone an enhanced trace metals influx due to recent incessant oil spills in the area [5], [6]. This work was therefore undertaken to evaluate the toxicity of some heavy metals (Cu, Fe and Pb) to tilapia fish as well as demonstrate the histopathological changes caused by these heavy metals to tilapia fish.

II. MATERIALS AND METHODS

A. Research Design Rationale

It is common knowledge that aquatic resources are constantly being bombarded with myriad of pollutants especially heavy metals toxicants in their ecosystem. An earlier survey of the heavy metal input into the brackish QIRE water showed that various concentrations of heavy metal are present in the water, sediment and aquatic resources like *Tilapia guineensis*. Four locations were selected for this survey. Both point and non-point sources of the heavy metals were identified in this survey [7]. *Tilapia guineensis* were selected for the study as they are abundant and cheap sources of protein within the study area besides their being generally accepted in the scientific world for research purposes. They are also consumed by members of all socioeconomic classes in the study area.

In order to narrow the toxic effect on tilapia to heavy metals, it was necessary to carry out heavy metal toxicity study using tilapia fish from a freshwater fish pond in a static study to simulate the conditions in the estuary. Tilapia fish from a fish pond (University of Calabar fishpond) were obtained and exposed to various concentrations of three heavy metals (Pb, Cu, Fe) to represent various levels of heavy metal pollution in the Qua Iboe river estuary. Liver and muscle tissues of the survivors of the toxicity studies were then used for the histopathological assessment.

B. Toxicity Studies

Aerated aquaria used in this toxicity studies were similar to those described by [8]. All tests were static and were conducted in accordance with the recommendations of [9]. In each experiment, a control (distilled water), and graded concentrations of the test metal were used. Preliminary tests to determine the survivability of tilapia fish in various concentrations of heavy metals were carried out. Ten tilapia fishes were exposed to the various heavy metal concentrations for 96 hours in eight different aquaria. This was repeated for each of the heavy metals. From the observations made on fish survivability, it was possible to select the heavy metal concentrations that will be suitable for the toxicity tests. Four different heavy metal concentrations were selected from this spread for each heavy metal. The control did not contain any trace of the heavy metals. For toxicity of each metal, 50 fishes

were used, ten each in four aquaria. The control aquarium also contained 10 fishes.

Percentage mortality with time was determined for each of the four different heavy metal concentrations and the control. A curve of percentage mortality against concentration was plotted for Pb, Fe, and Cu. The LC₅₀ values were determined from these curves.

C. Histopathological Studies of Fish Tissues

Histopathological studies of the fish tissues were carried out according to standard methodology [10]. The tissues of the liver and muscle were selected for this study.

1. Fixation

The tissues were excised, rinsed with deionised water. Care was taken to preserve shape, structure, relationship and chemical constituents of the cells and tissue even after death. Preservation was carried out using 10% neutral buffered formalin as the compound fixative for histological processing.

2. Tissue Processing

An automatic tissue processor was employed. The selected tissues were dehydrated, cleared, impregnated and embedded in paraffin wax following standard procedures. Dehydration involved passing the tissues through increasing strengths of alcohol starting from 70% through 90% to absolute 1 and absolute 11 for one hour in each case. Clearing was carried out to achieve de-alcoholization. The tissues were passed through two changes of chloroform for an hour in each change. During impregnation, the clearing agent was eliminated from the tissues while molten paraffin wax replaced it. This was achieved by passing of the cleared tissue through changes of paraffin wax molten at 54°C for an hour in each case. The final processing stage was the embedding of tissues in paraffin wax. This was necessary to hold the tissue in position and ensure that tissues were not crumbled during sectioning. The tissues so processed were rendered stiff enough for sectioning.

3. Tissue Sectioning

The Tissue blocks were sectioned using a microtome. Care was taken to ensure that the gauge controlling the thickness of sections was properly set. The thickness of sections was set at 15µm. The microtome was set to produce a cutting rhythm that formed a ribbon of about 1.5cm long. The sections were spread out in a water bath at 45°C. The sections were successfully attached to the slide using bovine albumen adhesive. Prepared slides were incubated at 50°C to dry and fix the sections. The slides were ready for staining after three hours.

4. Staining of Sections

The sectioned tissues were stained with Ehrlich's Haematoxylin and Eosin (H & E) stains. The stained slides were then examined for histopathological lesions.

III. RESULTS AND DISCUSSION

A. Histopathological Studies

The control (unimpacted fish from fish pond) and Tilapia

fish from 96h toxicity test solutions which simulated the natural conditions in the estuary were subjected to histopathological studies. Histological evaluations of the liver and muscle tissue of tilapia fish were carried out. The results / observation are presented in Figs. 1-4. The histopathological examination revealed marked alterations in the hepatocytes as compared with tissues from the control fishes. The fishes showed gross abnormalities and degenerative changes in the liver tissues. Several pathologic changes were diagnosed for the different heavy metals which include:

1. Control Group: Liver

Normal liver tissue, with hepatocytes arranged in cords in between which are the liver sinusoids. The portal tracts are intact and the central vein showed no abnormality. Occasional kupfer and sinusoidal lymphocytes are seen (Fig. 1). Liver tissue architecture is intact.

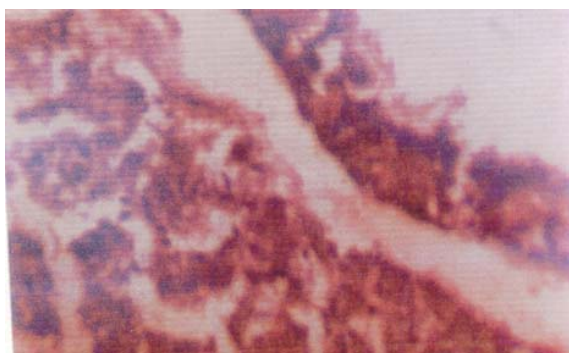


Fig. 1 Liver Tissue of Tilapia Fish (Control) Exposed to Distilled Water for 96hr (Mag. X40)

2. Lead Group: Liver

Histological sections of tilapia fish liver from the Pb test solutions showed intact architecture with occasional foci of mature lymphocytes and hyperpigmentation as well as pigment laden macrophages (Fig. 2).

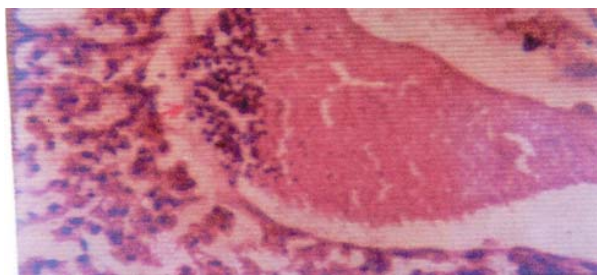


Fig. 2 Histopathological Studies of Liver of Tilapia Fish Exposed to Solution of Lead for 96 hr (Mag. X40)

3. Iron Group: Liver

Histopathological sections of tilapia fish liver from Fe test solutions showed periportal hemosiderosis with hepatocyte necrosis and early fibrosis. There were also few foci of chronic inflammatory infiltration (mainly lymphocytic) (Fig. 3).

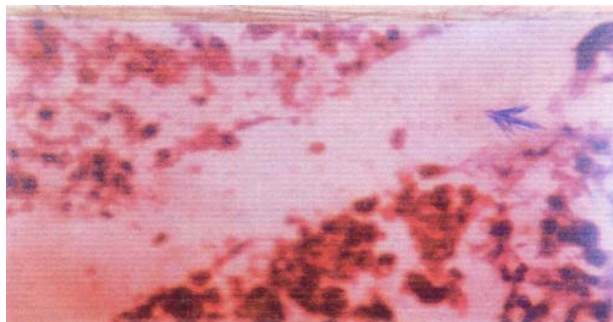


Fig. 3 Liver Tissue Exposed to Solution of Iron for 96hr Showing Hepatic Necrosis and Foci of Inflammatory Infiltration (Mag. X40)

4. Copper Group: Liver

Histopathological sections of tilapia fish liver from Cu test solutions showed diffuse hepatocyte necrosis. In some areas the necrosis is extensive leaving a ghost outline of hepatocytes. Foci of diffused lymphocyte infiltration can be seen. There is however no fibrosis (Fig. 4).

5. Control, Pb, Cu and Fe Groups: Muscle

No pathological changes occurred in the muscle tissues of tilapia fishes from any of the solutions compared to the control.

In summary, Fe induced periportal chronic inflammation in liver tissues with evident periportal fibrosis. In the case of liver tissues with Cu test solutions, there were extensive hepatocyte necrosis with chronic inflammatory changes; there were however, no fibrosis. The sections in the lead group showed no distinct degenerative changes in the liver tissues.

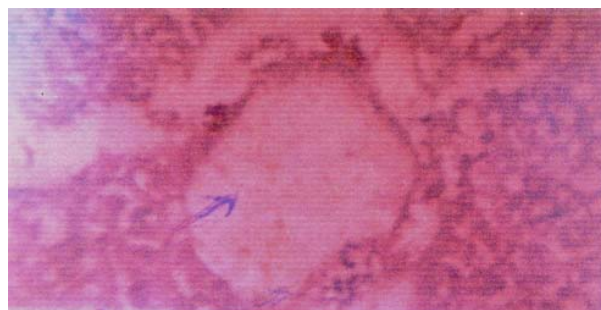


Fig. 4 Section of Liver Exposed to Copper for 96 hr Showing Diffused Extensive Hepatocyte Necrosis and Ghost Outline (Mag. X40)

Histopathological abnormalities such as proliferative lesions in several organs are characteristic of fish residing in an aquatic environment polluted with toxic compounds. These chemicals have been demonstrated to give rise to testicular abnormalities as well as reduced fecundity of mature fish [11]. Cell necrosis includes those changes in the cell beyond which point cell death results. Necrotic cells are shrunken and their intercellular attachments are broken. When cells are damaged, the content diffuses out and finds its way into the general blood circulation. It is worth noting that inflammatory fibrotic liver changes can also be a manifestation of a hepatic

nematode parasite [11].

In the present study, histopathological study was carried out on the liver and muscle tissues of fish exposed to copper, lead and iron solutions. The result obtained revealed marked alterations in the hepatocytes as compared with the architecture of liver tissues from the control fishes. Since histopathological alterations are the net result of adverse biochemical and physiological changes in an organism, the cellular changes observed in the experimental fish liver might have been caused by the heavy metal exposure. There were variations in the degree of damaging effect of the different heavy metals on the liver tissues. Gross necrosis was observed in the case of copper while the pathologic changes were slight in the case of iron and lead exposures. The exposed muscle tissues however did not suffer pathologic changes. This is probably due to the fact that the muscle tissues may not be involved in the early activities related to cellular response to the presence of foreign substances, chemicals, pathogens and other environmental pollutants like heavy metals.

Heavy metals occur naturally in the earth crust. They are stable and cannot be degraded or destroyed, and therefore they tend to accumulate. For some heavy metals, toxic levels can be just above the background concentrations that occur naturally. The association of symptoms indicative of acute toxicity is not difficult to recognize because the symptoms are usually severe, rapid in onset and associated with a known exposure or ingestion [12]. Lead for instance, is found everywhere in the environment. So are iron and copper. Acute exposure to lead is more likely to occur where batteries are manufactured. Even printing ink, gasoline and fertilizers contain lead. Symptoms associated with lead poisoning include hypertension, renal dysfunction, fatigue, sleeplessness, convulsions, abdominal pain, loss of appetite, headache, numbness, arthritis, and hallucination. In chronic situations, birth defect, autism, allergies, muscular weakness, paralysis (beginning in the forearms), mental retardation, psychosis, hyperactivity, lack of concentration, weight loss, mood swings, nausea and seizures are experienced. Most of the symptoms of lead poisoning are seen in children who take in good doses of lead-based products that are not meant for human consumption such as paints, hair colorings and cosmetics. The tragic Minimata Bay occurrence in Japan demonstrated the danger of heavy metal in the environment and called attention to an insidious microbial process; the methylation of mercury in anaerobic sediments. In the early 1950s, numerous inhabitants of a small fishing village at Minimata Bay, Japan, came down with severe disturbances of the central nervous system, which included tremors and impairment of vision, speech and co-ordination. Most severely affected were the families that consumed as a major part of their diet the fish and shellfish taken from the Bay [7], which were contaminated by the methylated form of the heavy metal mercury. To avoid a repeat of this kind of health effect at the Qua Iboe River estuary, a regular histopathological screening of the fishes in this environment is recommended.

IV. CONCLUSION

To reliably distinguish toxicant – induced lesions from cellular changes caused by natural stressors, e.g. seasonal variation or infectious diseases, histopathological screening of fish should be conducted on a regular basis as part of the environmental quality and control of the estuary. This work will therefore increase the research awareness in environmental / toxicological studies of the area.

REFERENCES

- [1] J. C. Reis. Coping with the waste stream from Drilling for oil. Proceedings, Ecoworld'92 Conference, June, 14-17 in Washington D. C., 1992
- [2] G. B. Sangalang, H. C. Freeman and R. Crowell. Testicular abnormalities in cod (*Gadus morhua*) fed arochlor 1254. *Arch. Environ. Contam. Toxicol.* Vol. 10, Pp. 617 – 626, 1981.
- [3] J. M. Nwaedozie. The determination of heavy metal pollutants in fish samples from river Kaduna. *J. Chem. Soc. Nigeria*, 23, 21-23, 1998.
- [4] K. Koponen, M. S. Myers, O. Ritola, S. E. Huuskonen & P. Lindström-seppä. Histopathology of feral fish from a PCB-contaminated freshwater lake. *Ambio*, 30, 122 – 126, 2001.
- [5] I. R. Udotong and J. I. R. Udotong. Health Risk Assessment in the Oil and Gas industries in Nigeria. In: *Environmental Pollution and Management in the Tropics* (E. N. Adinna, O. B. Ekop, and V. I. Attah; Eds.) SNAAP Press Ltd, Enugu, Nigeria, 205-229, 2003.
- [6] O. U. Eka and I. R. Udotong. A case study of effects of Incessant Oil Spills from Mobil producing Nigeria Unlimited on Human Health in Akwa Ibom State. In: *Environmental Pollution and Management in the Tropics* (E. N. Adinna, O. B. Ekop, and V. I. Attah; Eds.) SNAAP Press Ltd, Enugu, Nigeria, 205-229, 2003.
- [7] J. I. R. Udotong. Bioaccumulation and biotoxicity of heavy metals, polychlorinated biphenyls and hydrocarbons in tilapia, periwinkle and oysters from Qua Iboe River estuary. Ph. D thesis, University of Calabar, Calabar, Nigeria, P. 95, 2004.
- [8] M. Ahsannullah. Acute toxicity of Zinc and Cadmium to seven invertebrate species from Western Port, Victoria. *Aust. J. Mar. Freshwat. Res.*, 27, 187 – 196, 1976.
- [9] J. B. Sprague. The ABC's of pollutant bioassay using fish. In: *Biological methods for the assessment of water quality. ASTM Special Technical Publication*, 528, .6–30, 1973.
- [10] K. A. Ochei. *Medical laboratory Science: Theory and Practice*; 9th, Tata McGraw-Hill Publishing Company Limited. Pp. 396–482, 2008.
- [11] J. Schwaiger, R. Wanke, S. Adam, M. Pawert, W. Honnen and R. Triebkorn. The Use of histopathological indicators to evaluate contaminated – related stress in fish. *J. Aquat. Ecosystem. Stress Recov.* Vol. 6, Pp. 75 – 86, 1997.
- [12] D. J. Ferner. Toxicity, Heavy metals. *eMed. J.* 2(5), 2001.

Justina I. R. Udotong was born in Ifuho in Ikot Ekpene LGA, Akwa Ibom State, Nigeria on 12 September 1960. She holds a Bachelor of Science (Hons) degree in Biochemistry from the University of Calabar, Calabar, Nigeria in 1985; Doctor of Philosophy (Biochemical Toxicology) from the same University in 2004.

She was promoted a Senior Lecturer on October 1st 2010. She has published 10 articles in reputable local and International journals, 1 book chapter and 15 local and international conference papers to her credit. Some of her published work include: Health Risk Assessment in the Oil and Gas industries in Nigeria In: *Environmental pollution and management in the Tropics* (E. N. Adinna, O. B. Ekop and V. I. Attah; Eds), Enugu, Nigeria, SN AAP Press Ltd, 2003; Occupational Health risks (OHRs) at Five Sites in Uyo metropolis, Southern Nigeria, *World journal of Applied Science and Technology* 2 (1): 98-109, 2010 and A Comparative Indoor and Outdoor Air Quality in Uyo Metropolis, Niger Delta, Nigeria, *Int. J. Chem., Environ, Pharm. Res.* 1 (3): 51-62. Her current research interests include management of hospital waste occupational and public health survey as well as nutritional toxicology. She has done some work on indoor air quality; heavy metal pollution of aquatic environment as well as public health surveys.

Dr Udotong is a member of Nutrition Society of Nigeria and Organization for women in Science for the Developing World (OWSD).