

Grape Seed Extract in Prevention and Treatment of Liver Toxic Cirrhosis in Rats

S. Buloyan, V. Mamikonyan, H. Hakobyan, H. Harutyunyan, H. Gasparyan

Abstract—The liver is the strongest regenerating organ of the organism, and even with 2/3 surgically removed, it can regenerate completely. Hence liver cirrhosis may only develop when the regenerating system is off.

We present the results of a comparative study of structural and functional characteristics of rat liver tissue under the conditions of toxic liver cirrhosis development, induced by carbon tetrachloride, and its prevention/treatment by natural compounds with antioxidant and immune stimulating action. Studies were made on Wister rats, weighing 120–140 g. Grape seeds extracts, separately and in combination with well-known anticirrhotic drug ursodeoxycholic acid (Urdoxa), have demonstrated effectiveness in prevention of liver cirrhosis development and its treatment.

Keywords—Carbon tetrachloride, GSE, liver cirrhosis, prevention, treatment.

I. INTRODUCTION

ACCORDING to WHO, liver cirrhosis (LC) is the fourth common cause of death among people between 30 and 50, and the eighth most common killer overall.

The LC genesis is ascribed to chronic hepatitis, other inflammatory diseases, and toxins (alcohol, drugs etc.). Depending on its origin, the emphasis in treatment is on relevant medicine, but in all cases preparations with immunostimulating and antioxidant activities are widely used [1], [2].

Cirrhosis related fibrosis involves encapsulation or replacement of injured tissue by collagenous scar. It is the effect of perpetuation of normal wound healing response, leading to abnormal continuation of fibrogenesis. It progresses at variable rates depending on the etiology of liver disease, environmental and host factors [3].

Within recent years grape seeds and their extracts gained special attention as highly effective antioxidants [4].

The aim of this work is to study the anticirrhotic effect of grape seed extract (GSE) and its synergy with a well-known anticirrhotic drug. As demonstrated in our previous work the seeds of grape variety Vitis Vinifera Satira Hayreniq are one of

the most active among those cultivated in Armenia, therefore we used its seeds in the study [5].

Grape seed extracts, rich in flavonoids and especially proanthocyanidin, have demonstrated potent antioxidant effects. Experimental studies have demonstrated that orally administered GSE lowers ROS generation, and protects plasma protein carbonyl groups, while enhancing the activity of the endogenous antioxidant system. Clinical trials have confirmed the antioxidant effect of GSE [6]. In our previous study, TEM ultrastructural observation has shown that the GSE possess cytoprotective and antitoxic effects in hepatocytes during CCl₄ intoxication [7].

Ursodeoxycholic acid (Urdoxa) was used as a comparative drug, well known in medical practice: it is a non-toxic, hydrophilic bile acid, used to treat predominantly cholestatic liver disorders [8]. Mechanisms of action of this acid include direct cytoprotection, detergent action on dysfunctional microtubules, immunomodulation and induction of hypercholeresis. Its efficacy in primary biliary cirrhosis and primary sclerosing cholangitis, as an adjunct to medical therapy, is well established [9].

Despite broad coverage in biological and medical studies, LC is still considered to not be fully curable and the drugs used are usually associated with side effects. So, the search for new remedies and improvements to known methods of treatment are very important. From this point of view new natural preparations, devoid of side effects, may be more effective.

II. MATERIALS AND METHODS

A. Design of Animal Experiments

Studies were performed on Wistar rats, weighing 120–140 g. They were housed in a room at 22±2°C and 12 hours light/dark cycle and given food and water ad libitum. All animal experimental procedures performed according to Directive 2001/20/EC.

The animals were divided into 8 groups of six. The control group comprised 4 animals.

Group 1: Control group: intact animals

Group 2: CCl₄-intoxication (during 12 weeks)

The animals of groups 3-5 were treated long-term (8 weeks) with immunostimulating and antioxidant preparations after the LC model genesis lead by CCl₄-intoxication during 12 weeks.

Group 3: Treatment with ursodeoxycholic acid after CCl₄ intoxication,

Group 4: Treatment with GSE after CCl₄-intoxication,

Group 5: Treatment with ursodeoxycholic acid and GSE after CCl₄-intoxication.

S.B. is with the Scientific Technological Center of Organic and Pharmaceutical Chemistry NAS RA, Yerevan, Armenia (corresponding author to provide phone: 37498-484474; e-mail: sonabuloyan@gmail.com).

V.M. and H.H. are with the Institute of Biochemistry NAS RA, Yerevan, Armenia (e-mail: vkhmamikonyan@gmail.com, hayk@web.am).

H.H. is with Technological Center of Organic and Pharmaceutical Chemistry NAS RA, Yerevan, Armenia (e-mail: hasmik.hakobyan.92@mail.ru).

H.G. is with the Scientific Technological Center of Organic and Pharmaceutical Chemistry NAS RA, Yerevan, Armenia (e-mail: hrachikgasparyan@mail.ru).

Parallel to the intoxication process, during 12 weeks, animals of 6-8 groups were treated with immunostimulating and antioxidant preparations to prevent the genesis of LC.

Group 6: Treatment with ursodeoxycholic acid during CCl₄ intoxication,

Group 7: Treatment with GSE during CCl₄-intoxication,

Group 8: Treatment with ursodeoxycholic acid and GSE during CCl₄-intoxication.

B. Preparation of GSE and Ursodeoxycholic Acid

GSE is derived from the Vitis Vinifer Satira Hayreniq grape seeds, were given three times a week, through intragastric tube (gavage needle) at dose level of 200mg/kg.

Ursodeoxycholic acid was dissolved in olive oil and was administered three times a week through intragastric tube at dose level of 90mg/kg. [10].

C. Modeling of CCl₄-Intoxication

The toxic model of LC was induced by I/P injection of 1.0 ml/kg body weight of 10% CCl₄ in olive oil as a vehicle, three times a week for 12 weeks [11].

After which the animals were deprived of food overnight, anesthetized by Nembutal and then sacrificed. The liver tissue was dissected out and weighed. Tissue sample was taken from hepatic lobes and stored in 96° alcohol for histopathological

examination. Samples were routinely embedded in paraffin blocks, sectioned at 4 µm and stained with Hematoxylin and Eosin for microscopic examination according to Van Gieson [12].

The samples were studied by GENEVAL light microscope with a CANON® digital camera, connected to a computer.

Liver sections were graded numerically to assess the degree of histological features in acute hepatic injury. Hepatocyte necrosis, fatty change, hyaline degeneration, ballooning degeneration, and infiltration of Kupffer cells and lymphocytes were prominent in histological findings [13]. The liver pathology was scored by Metavir scoring system

Score 0 = no visible cell damage;

Score 1 = focal hepatocyte damage on less than 25% of the tissue;

Score 2 = focal hepatocyte damage on 25-50% of the tissue;

Score 3 = extensive, but focal, hepatocyte lesions;

Score 4 = global hepatocyte necrosis. [14], [15]

III. RESULTS

A. Body and Liver Weight

Initial and final body weight, liver weight and relative liver weight of groups are presented in Table I.

TABLE I
BODY AND LIVER WEIGHT OF ANIMALS TREATED WITH GSE AND URSODEOXYCHOLIC ACID AFTER AND DURING CCl₄ INTOXICATION

Groups	Initial Body Weight (g)	Final Body Weight (g)	Weight Gain (g)	Liver Weight (g)	Relative Liver Weight (g liver/100 g body)
1. Control group	143.75±1.32	300.75±5.62	157±4.36	12.17±0.17	4.05±0.05
2. CCl ₄ -intoxication	140.67±3.74	250.33±5.12 +++	109.67±4.47 +++	14.09±0.56 +	5.63±0.18 +++
3. Treatment with ursodeoxycholic acid after CCl ₄ intoxication	142.0±2.74	209.25±4.33 ***	67.25±1.18 ***	9.46±0.22 **	4.53±0.20 **
4. Treatment with GSE after CCl ₄ -intoxication	136.33±5.35	253.75±12.81 ns	117.42±12.81 ns	13.21±0.42 ns	5.25±0.32 ns
5. Treatment with ursodeoxycholic acid and GSE after CCl ₄ -intoxication	125.83±0.94	200.75±7.71 ***	74.92±7.84 **	10.14±0.35 **	5.05±0.20 ns
6. Treatment with ursodeoxycholic acid during CCl ₄ intoxication	138.25±4.03	193.25±3.12 ***	55±3.11 ***	8.63±0.66 ***	4.46±0.28 **
7. Treatment with GSE during CCl ₄ -intoxication	115.33±12.38	197.67±12.99 ***	76.67±1.76 ***	11.09±1.01**	5.61±0.39 *
8. Treatment with ursodeoxycholic acid and GSE during CCl ₄ -intoxication	131.75±13.06	190.75±8.87 ***	59±10.98 ***	9.35±0.28 ***	4.90±0.22 *

Values are mean ± S.E.M. of 6 rats;

*** P<0.001 significantly different from the group of CCl₄-intoxication

**P<0.01 significantly different from the group of CCl₄-intoxication

*P<0.05 significantly different from the group of CCl₄-intoxication

ns P>0.05 not significantly different from the group of CCl₄-intoxication

+++ P<0.001 significantly different from the control

+ P<0.05 significantly different from the control

Group 2 with CCl₄ –intoxication demonstrated a significant decrease in body weight, compared with control rats. Also, in all groups treated with GSE and ursodeoxycholic acid, after and during CCl₄-intoxication, decrease in body weight was observed, compared with control group.

Liver weights and relative liver weight ratios were higher in CCl₄ –intoxication group relative to control animals. In groups 4 and 7, treated with GSE, liver weight and relative liver weight was almost the same as in the control group. Groups 3, 5, 6 and 8, treated with ursodeoxycholic acid and

GSE, show reduction in liver weight compared with CCl₄ –intoxication and control groups.

B. Histopathological Observation

The severity of liver morphological changes and fibrosis during and after CCl₄ intoxication was scored and summarized in Table II.

The livers of rats from the control group had no noticeable histological changes (Fig. 1).

Severe histopathological changes were observed in CCl₄ intoxication group. There were extensive liver injuries,

characterized by fatty degeneration, necrosis and infiltration of inflammatory cells around the central vein and the portal tracts, severe hepatocellular degeneration, and congestion. Hepatocytes in the degenerative and necrotic regions had pyknotic nuclei. Pseudo lobules were formed actively and macrovesicular droplets were detected (Fig. 2).

Improvement was observed in the group treated with ursodeoxycholic acid after CCl₄-intoxication. There was focal infiltration and lesion. The architecture of liver was almost recovered. Pseudo lobules were few, with slender fibrous bands and less salient than in the CCl₄-intoxication group (Fig. 3).

The group treated with GSE after CCl₄-intoxication demonstrated slow regeneration compared with the one treated with ursodeoxycholic acid after CCl₄-intoxication. The histopathological hepatic lesions induced by the CCl₄-intoxication were remarkably improved by treatment with GSE. Necrosis was also observed in this group, as well as infiltration of inflammatory cells around the portal tracts, and focal hepatocellular fatty degeneration. However, the state of liver was much better than in the CCl₄-intoxication group (Fig. 4).

Recovery of liver architecture was observed in the group treated with ursodeoxycholic acid and GSE after CCl₄-intoxication. Small focal lesions and karyolysis were observed. However, the architecture of lobules was almost recovered, pseudo lobules were few and subdivided into smaller lobules and the hepatocytes mostly had normal appearance (Fig. 5).

The stats of livers treated with ursodeoxycholic acid and GSE during CCl₄-intoxication together and separately were relatively better, than groups treated with these drugs after CCl₄-intoxication, except for the group treated with ursodeoxycholic acid after CCl₄-intoxication.

In the livers of group treated with ursodeoxycholic acid during CCl₄-intoxication was observed focal necrosis and infiltration close to the portal tract, small lipid accumulation, granulation, karyolysis, the beginning of formation of fibrous bands and pseudo lobules. The state of the livers was much better in this group than in CCl₄-intoxication group, but not better than in the group treated with ursodeoxycholic acid after CCl₄-intoxication (Fig. 6).

The group treated with GSE during CCl₄-intoxication developed moderate inflammation and necrosis, small amount of collagen formation around central veins and portal tracts. The state of the liver was better than in the group treated with GSE after CCl₄-intoxication and the group treated with ursodeoxycholic acid during CCl₄-intoxication. GSE has demonstrated prevention effect in LC genesis (Fig. 7).

The group treated with ursodeoxycholic acid and GSE during CCl₄-intoxication developed few cirrhotic changes, with small amount collagen formation around central veins and portal tracts. The architecture of liver was almost not disrupted, hepatocytes had mostly normal appearance. However, several instances of lipid accumulation in hepatocytes and focal necrosis were observed. The state of the liver was better than in the CCl₄-intoxication group (Fig. 8)

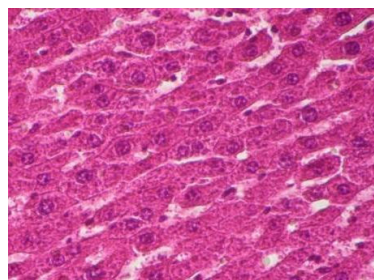


Fig. 1 Intact animals

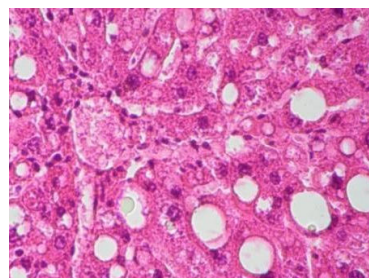


Fig. 2 CCl₄-intoxication

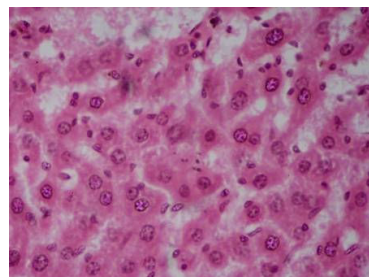


Fig. 3 Treatment with ursodeoxycholic acid after CCl₄ intoxication

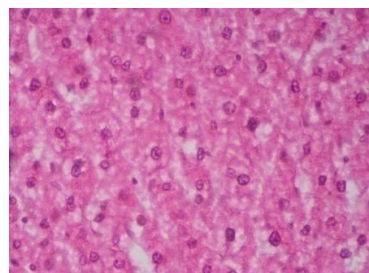


Fig. 4 Treatment with GSE after CCl₄-intoxication

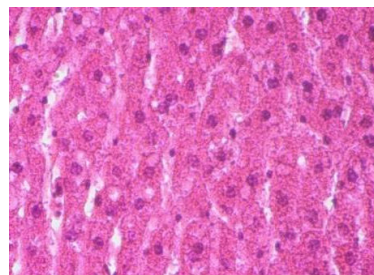


Fig. 5 Treatment with ursodeoxycholic acid and GSE after CCl₄-intoxication

TABLE II
HISTOLOGICAL INJURY SCORE OF LIVER TREATED WITH GSE AND URSODEOXYCHOLIC ACID AFTER AND DURING CCL₄ INTOXICATION

Groups	Injury of score ^a					
	Fatty degeneration	Necrosis	Cell swelling	Inflammation	Fibrosis	Total scores
1. Control group	0	0	0	0	0	0
2. CCL ₄ -intoxication	4	4	3	3	4	18
3. Treatment with ursodeoxycholic acid after CCL ₄ intoxication	2	2	2	2	1	9
4. Treatment with GSE after CCL ₄ -intoxication	3	2	2	2	2	11
5. Treatment with ursodeoxycholic acid and GSE after CCL ₄ -intoxication	2	2	2	2	2	10
6. Treatment with ursodeoxycholic acid during CCL ₄ intoxication	2	3	2	2	3	12
7. Treatment with GSE during CCL ₄ -intoxication	2	2	1	1	1	7
8. Treatment with ursodeoxycholic acid and GSE during CCL ₄ -intoxication	3	2	2	2	1	10

^aLivers were scored for hepatic injury via light microscopy with score 0 =no visible cell damage; score 1=focal hepatocyte damage on less than 25% of the tissue; score 2=focal hepatocyte damage on 25–50% of the tissue; score 3=extensive, but focal, hepatocyte lesions; score 4=global hepatocyte necrosis

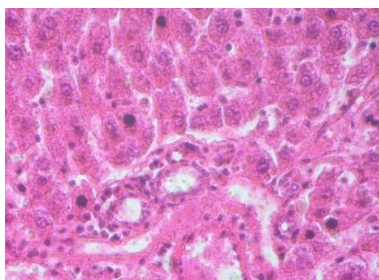


Fig. 6 Treatment with ursodeoxycholic acid during CCL₄ intoxication

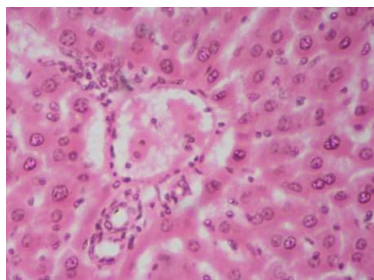


Fig. 7 Treatment with GSE during CCL₄-intoxication

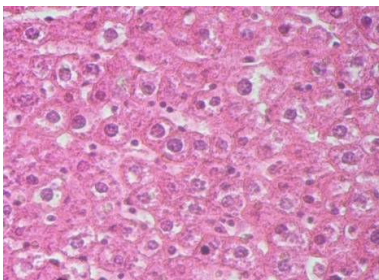


Fig. 8 Treatment with ursodeoxycholic acid and GSE during CCL₄-intoxication Figs. 1-8: Liver, staining with H&E, magnification=10x25

IV. CONCLUSION

This study demonstrated that GSEs possess low activity in the treatment of toxic liver cirrhosis after 12 week intoxication with CCL₄, but during intoxication GSE displayed preventive effects in the genesis of liver cirrhosis. That is why GSE can

be recommended for prophylaxis of liver cirrhosis. GSE demonstrated moderate synergies with the ursodeoxycholic acid. However, the study of GSE is to continue, the plan is to conduct a comparative study of the structural and functional characteristics of rat liver tissue and hematopoietic stem cells under the conditions of toxic LC development, and its prevention/treatment by natural compounds with antioxidant and immunostimulating action. Another objective would be to determine the GSE dosage that will have more expressed effect for prevention and treatment of LC.

REFERENCES

- [1] Day C. P. "Treatment of alcoholic liver disease" *Liv. Transplant*, 2007, v. 13, p. 69-75.
- [2] Emanuel A. "Role of adaptive immunity in alcoholic liver disease" *International Journal of Hepatology*, v 2012, Article ID 893026, 7 pages.
- [3] Detlef Schuppan and Nezam H. Afdal "Liver Cirrhosis" *The Lancet Vol. 371*. Issue 9615, Pages 838 - 851, 8 March 2008
- [4] Badavi M., Mehrgardi F.Z., Sarkaki A., Naseri M.K., Dianat M. "Effect of Grape Seed Extract on Lead Induced Hypertension and Heart Rate in Rats." *J. Biol. Sci.*, 2008, v. 11(6), p. 882-887.
- [5] Mamikonyan V. "Antioxidant influence of Vitis Vinifera Satira Hayreniq" grape seeds *Horizons in Molecular Biology 5th International PhD Student Symposium*, Gottingen, Germany, 2008, p. 84.
- [6] Vivian Molina Cuevas, Yazmin Ravelo Calzado, Yohani Pérez Guerra, Ambar Oyarzábal Yera, Sonia Jiménez Despaigne, Rosa Mas Ferreira, and Daisy Carbajal Quintana "Effects of Grape Seed Extract, Vitamin C, and Vitamin E on Ethanol- and Aspirin-Induced Ulcers" *Advances in Pharmacological Sciences*, Volume 2011 (2011), Article ID 740687, 6 pages.
- [7] Karlen Hovnanyan, Vardan Mamikonyan, Anahit Margaryan, Kristine Sargsyan, Margarita Hovnanyan, Maria Karagoyzyan, Konstantin Karageuzyan "Antioxidants as effective remedies at hepatotoxic action of carbon tetrachloride" *Journal of Biophysical Chemistry*, Vol.5, No.1, 1-4 (2014)
- [8] Trauner M, Graziadei IW. "Mechanisms of action and therapeutic applications of ursodeoxycholic acid in chronic liver diseases" *Aliment Pharmacol Ther.* 1999 Aug;13(8):979-96.
- [9] S. Saksena, R.K. Tandon "Ursodeoxycholic acid in treatment of liver diseases" *Postgrad Med J.* Feb 1997; 73(856): 75–80.
- [10] Patrick Sharp, Jason S. Villano "The laboratory rat" second edition p 220-222
- [11] Gi-Ppeum Lee, Won-Il Jeong, Da-Hee Jong, Sun-Hee Do, Tae-Hwan Kim and Kyu-shik Jeong, "Diagnostic evaluation of carbon tetrachloride-induced rat hepatic cirrhosis model" *Anticancer Research* 25, p. 1029-1038, (2005).
- [12] МЕРКУЛОВ Г.А., 1969, 406 стр. (Merkulov G. A., 406 pp).
- [13] Valeer JD. Liver tissue examination. *J Hepatol* 2003;39:S43-9.
- [14] Akram Eidi, Pejman Mortazavi, Masoud Ebrahim Tehrani, Ali Haeri Rohani, Shahabaldin Safi "Hepatoprotective Effects of Pantothenic acid

on Carbon Tetrachloride-induced Toxicity in rats” EXCLI Journal
2012;11:748-759 – ISSN 1611-2156 .

- [15] Zachary D. Goodman “Grading and staging systems for inflammation
and fibrosis in chronic liver diseases” Journal of Hepatology, Volume
47, Issue 4, Pages 598–607, October 2007