

Epidemiology of Bone Hydatidosis in Eastern Libya from 1995 to 2013

Sadek Makhoulf, Hassan M. Nouh

Abstract—Bone hydatidosis is an infection in worldwide distribution. Although there is no evidence in literature on Bone Hydatid disease in Libya, we tried to present the first Epidemiological study of this disease in Eastern Libya through retrospective study from 1995 to 2013. Our data were collected from 3 hospitals in Eastern Libya particularly the sheep-raising areas with total number of musculoskeletal infection cases of two thousand one hundred ninety four (2,194). There were five (5) five cases of bone infection, four (4) of it have been diagnosed after more than three (3) months. Our study is comparable to other international study but this type of bone infection need further studies for effective control strategies for all dogs to avoid serious complications that might happened from the delay in diagnosing this type of disease.

Keywords—Bone infection, Hydatidosis, Eastern Libya, Sheep-raising areas.

I. INTRODUCTION

HYDATID disease is caused by parasitic tapeworm *Echinococcus*: *E. granulosus*: species most responsible, *E. multilocularis* and *E. oligactes*.

Bone haydatidosis is infection worldwide distribution, serious health problem in sheep-raising areas of Mediterranean countries, U.K., Australia, South America and Central Asia. Usually diagnosed late and can be confused with Tuberculosis, Chondrosarcoma, Malignant fibrous histiocytoma, Myeloma, Metastatic disease, Giant cell tumor, a neurysmal bone cyst and Fibrous dysplasia. There is no evidence in literature on Bone haydatid disease in Libya; although there are several Authors have described some studies on prevalence of human haydatid disease in different regions of Libya [1], [3], [4], [7], [10].

II. AIM

Present the first national clinical study on the Epidemiology of Bone Haydatidosis in Eastern Libya from 1995 to 2013.

III. MATERIALS AND METHOD

We conducted a retrospective study to evaluate the epidemiology of Haydatid Bone Disease in Eastern Libya from January 1, 1995 to June 30, 2013, 3 Hospitals were included in our study:

1. TUBROK HOSPITAL (nearest to Libya-Egypt limits)

Prof. Sadek Mahklouf is with the Al Jalla Hospital, Benghazi, Libya (phone: 00218926984487; e-mail: sadek_makhoulf@yahoo.com).

Dr. Hassan M. Nouh is with the Hawari General Hospital Consultant head of the Orthopedics Department (phone: 00218928865258; e-mail: hassanlibo@yahoo.com.uk).

2. ALBEDA HOSPITAL (Green mountain region of Libya)
3. AL JALLA HOSPITAL (Referred trauma hospital, Benghazi)

We depend only on the information contained in the file of each patient due to the absence of data like their home address.

The following information was reviewed: sex of the patient, age, address, job, symptoms presented, time of the diagnosis, and site of infection.

IV. RESULTS

In spite of absence of proper documentation system, lack of current information on our patients after admission to the hospitals or after diagnosis of the cases, we observed five (5) cases as following:

- No case was documented in TUBROK hospital ,
- One (1) case admitted to ALBEDA Hospital
- Four (4) cases were admitted to AL JALLA hospital

TABLE I
NUMBER OF HYDATID BONE DISEASE CASES IN 3 HOSPITALS FROM 1995 TO 2013

Name of Hospital	Total No. of Muskuloskeletal Infection	Bone Hydatid Infection
TUBROK Hospital	382	0
ALBEDA Hospital	491	1
ALJALLA Hospital	1321	4

Four (4) of them were male, One (1) was female whose ages from 35 to 52 years. All of them are farmers in sheep and goat yard with at least 4 sheep dogs and 2 owned dog which has direct contact with each patient. Two (2) from Al Marj City the other two (2) was from Albeda (sheep-raising areas), and one (1) from Benghazi.

In all cases, presenting symptom was pain, whereas swelling in three (3) cases, and paraplegia in one (1) case were noted.

The time disease was diagnosed was one case after three (3) weeks while two (2) cases were treated as tuberculosis for 6 months and the remaining two (2) cases treated as non-specific infection for 3 months. CT Scan was the best radiological method for diagnosis. Diagnosis was confirmed by histopathology where three (3) cases in Libya and two (2) cases in Italy. There was a case of one (1) mortality because of lung pathology.

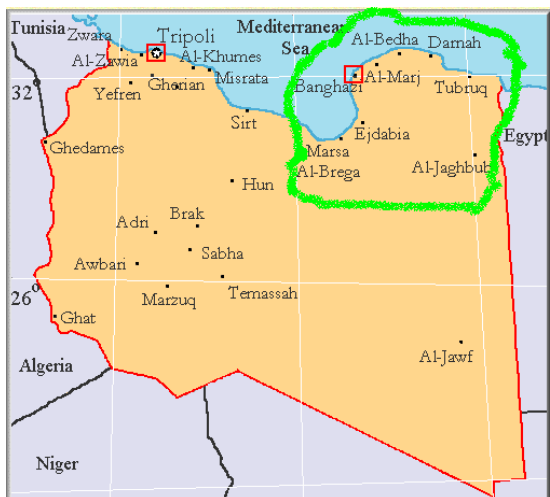

Fig. 1 Map of Libya Showing Eastern Libya Illustrated by Green Circle

TABLE II
COMMON SITE OF INFECTION

Site of infection	Number of the cases	Percent
Long Bones	1	20%
Spine	2	40%
Pelvis and Hips	2	40%

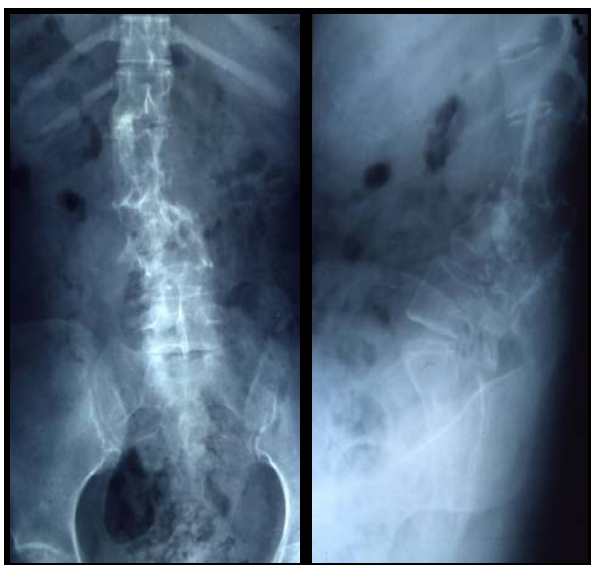


Fig. 2 Case No. 1: Spine Involvement

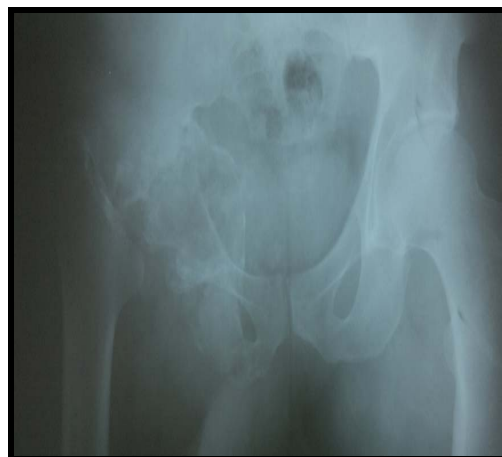

Fig. 3 Case No. 2: Long Bone Involvement (Left Humerus)

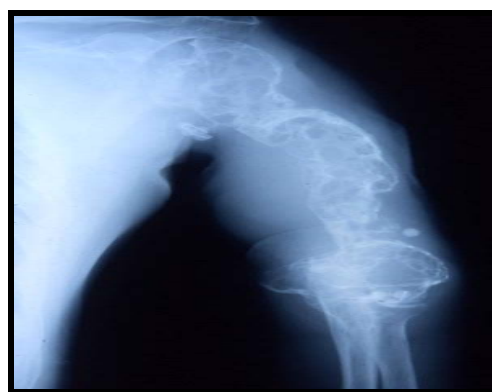

Fig. 4 Case No. 3: Hip and Pelvis Involvement

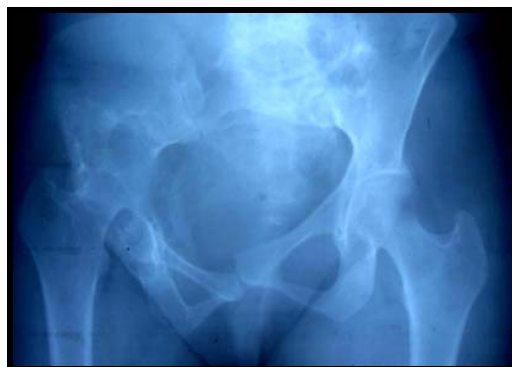

Fig. 5 Case No. 4: Hip and Pelvis Involvement

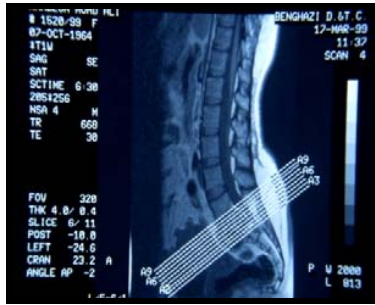

Fig. 6 (a) - Case No. 5: Sacro-Iliac Cut Section

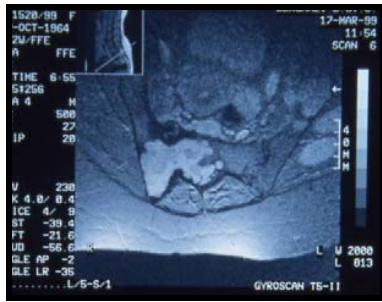

Fig. 6 (b) - Case No. 5: Sacro-Iliac Intra-osseous

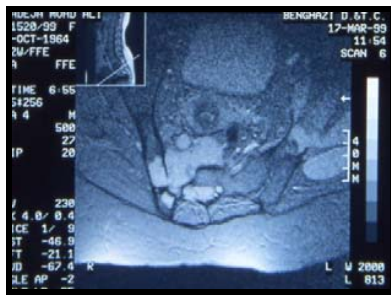

Fig. 6 (c) - Case No. 5: Sacro-Iliac Extra-osseous

V. DISCUSSION

Even the statistical evidence from Northern African countries suggests that Hydatid Disease in certain regions is extremely high endemic [1].

With review of related literature, we observed that there is no statistical study on the prevalence of Hydatid Bone Disease in Libya.

Our study reconfirm that the prevalence of Hydatid Bone Disease is high in sheep-raising areas (Albeda zone and Al Marj Zone) [5]-[8].

This agreed (Duran H. and co-authors) regarding the most infected sites are the spine, hips and pelvis and the late diagnosis of Bone Hydatid disease in almost all our cases [2], [5], [6], [8], [9].

In our study we did not concentrate on the methods of treatment: Anthelmintic drugs but radical surgery remains the most effective treatment [11].

VI. CONCLUSION

This study provides data about the status of Hydatid Bone Disease in Libya that need further research and studies to enable a more precise planning for effective control strategies for the proper care of dogs (stray, owned, sheep, guard and household dogs). Restraining of dogs that did not receive any de-worming could be an alternative solution.

Lack of knowledge about *E. granulosus* transmission is also significant risk factors for transmission of the disease. By educating owners of these animals measures to avoid the serious complication that might happen from delay of diagnosis of this bone disease will be achieved.

ACKNOWLEDGMENT

The help of Dr. Fawzi Rajab Ismail, orthopedic specialist, AL JALLA Hospital is gratefully acknowledged for providing us some of radiological materials. We also thank Dr. Ramzy Alhasy, orthopedic specialist from ALBEDA Hospital and Dr. Awad Algassi, orthopedic doctor from TUBROK Hospital for statistical help. Lastly, the authors gratefully acknowledge the financial support of Benghazi Medical University.

REFERENCES

- [1] A. Elhamei; B.S. Murthy: British Journal Of surgery: Hepatic hydatid disease in Libya. Vol. 73 issue 2, 125-127.
- [2] Agarwal S, Shah A, Kadhi SKM, Rooney. RJ. Hydatid bone disease of pelvis. Clin.Orthop.1992; 280: 251-5.
- [3] Anderson F.L., Ouhelli H. and Kachani M (eds) (1997) – Compendium on cystic echinococcosis in Africa and in Middle Eastern Countries with special reference to Morocco. Brigham Young University, Print Services. Povo, Utah, 1-345.
- [4] Dar FK; Taquri S: Human hydatid disease in Eastern libya. Trans R. soc. Trop. Med. Hyg. 1978; 72(3): 313-4.
- [5] Duran H; Ferrandez L; Gomez-Castresana F; Lopez-Duran L; Mata P; Brandau D; Sanchez-Barba A : Osseous Hydatidosis. JBJS Am. 1978; 60: 685-90.
- [6] Herrera; Antonio; Angel A; Martinez: Extraspinal Bone Hydatidosis. JBJS (Am, 2003;85-A;1790-4).
- [7] Kalani BP, Opha SN, Bhargava RK, Broadhead RL; Hydatid disease in children in Libya. Ann Trop Paediatric. 1994 Sep; 4(3): 195-9.
- [8] M. Turgut; Infection J. 25 (1997) No. 4; 221-29.
- [9] Sami A; Elzahari A; Ouboukhlik A; Elkamar A; Jiddane M; Boucetta M; Hydatid cyst of spine and spinal cord. Neurochirurgie 1996; 42: 281-7 French.
- [10] Shambesh MK; Macpherson CN; Beesley WN; Gusbi A; Elsonosi T. Prevalence of human hydatid disease in north western: a cross-sectional ultrasound study; Ann Trop Med Parasitol. 1992 Aug; 86(4): 381-6.
- [11] Yildiz Y; Bayrakci; Altay; Saglik: The use of PMMA in the management of Hydatid disease of bone. JBJS Br. 2001; 83-B; 1005-8.