

A Review of Pharmacological Prevention of Peri-and Post-Procedural Myocardial Injury after Percutaneous Coronary Intervention

Syed Dawood Md. Taimur, Md. Hasanur Rahman, Syeda Fahmida Afrin, Farzana Islam

Abstract—The concept of myocardial injury, although first recognized from animal studies, is now recognized as a clinical phenomenon that may result in microvascular damage, no-reflow phenomenon, myocardial stunning, myocardial hibernation and ischemic preconditioning. The final consequence of this event is left ventricular (LV) systolic dysfunction leading to increased morbidity and mortality. The typical clinical case of reperfusion injury occurs in acute myocardial infarction (MI) with ST segment elevation in which an occlusion of a major epicardial coronary artery is followed by recanalization of the artery. This may occur spontaneously or by means of thrombolysis and/or by primary percutaneous coronary intervention (PCI) with efficient platelet inhibition by aspirin (acetylsalicylic acid), clopidogrel and glycoprotein IIb/IIIa inhibitors. In recent years, percutaneous coronary intervention (PCI) has become a well-established technique for the treatment of coronary artery disease. PCI improves symptoms in patients with coronary artery disease and it has been increasing safety of procedures. However, peri- and post-procedural myocardial injury, including angiographical slow coronary flow, microvascular embolization, and elevated levels of cardiac enzyme, such as creatine kinase and troponin-T and -I, has also been reported even in elective cases. Furthermore, myocardial reperfusion injury at the beginning of myocardial reperfusion, which causes tissue damage and cardiac dysfunction, may occur in cases of acute coronary syndrome. Because patients with myocardial injury is related to larger myocardial infarction and have a worse long-term prognosis than those without myocardial injury, it is important to prevent myocardial injury during and/or after PCI in patients with coronary artery disease. To date, many studies have demonstrated that adjunctive pharmacological treatment suppresses myocardial injury and increases coronary blood flow during PCI procedures. In this review, we highlight the usefulness of pharmacological treatment in combination with PCI in attenuating myocardial injury in patients with coronary artery disease.

Keywords—Coronary artery disease, Percutaneous coronary intervention, Myocardial injury, Pharmacology.

I. INTRODUCTION

CORONARY ARTERY DISEASE (CAD) is a chronic disease in which blood flow is obstructed through the coronary arteries that supply the heart with oxygen-rich blood.

Dr. Syed Dawood Md. Taimur is with the Department of Cardiology, Ibrahim Cardiac Hospital & Research Institute, Dhaka, Bangladesh (Mobile: +8801712801515; e-mail: sdmtaimur@gmail.com).

Dr. Md. Hasanur Rahman is with the Department of Cardiology, Ibrahim Cardiac Hospital & Research Institute, Dhaka (Mobile: +88 017- 46439656).

Dr. Syeda Fahmida Rahman is with the Department of Biochemistry, Ibne Sina Medical College, Dhaka.

Dr. Farzana Islam is with the Department of Pediatrics, BangaBandhu Sheikh Mujib Medical University (BSMMU) (Mobile: +8801718011237; e-mail: dr.farzanaislamsilvi@yahoo.com).

A disease known as atherosclerosis, which is sometimes called “hardening of the arteries”, causes this obstruction. An estimated 13.2 million Americans suffer from CAD. Also referred to as coronary heart disease, CAD is the most common form of cardiovascular disease in the United States today.

Percutaneous coronary intervention (PCI) relieves cardiac ischemia, resulting in improvement of symptoms in patients with coronary artery disease (CAD). Although PCI has been widely performed in the management of CAD, non-Q wave myocardial infarction (MI) can occur in 10-40% of patients after elective PCI [1], [2]. This phenomenon can be detected by changes of electrocardiography (ECG) and elevation of cardiac enzymes such as troponin-I and T, creatine kinase (CK), creatine kinase-myocardial band isoenzyme fraction (CK-MB), and so on. There are many reports that myocardial damage during PCI is associated with increase in risk of major in-hospital complications and major adverse clinical events, even if it is small [3]-[5]. In many cases, cardiac enzyme elevation results from various procedural events including side branch closure and distal thromboembolism, which can be confirmed by coronary angiography [6]. However, in some cases, cardiac enzyme elevations occur even without discernible complications. Dilatation of plaque and vessel wall, which include lipid, matrix, endothelial cells and platelet thrombus, may induce microcirculatory embolism after angioplasty [7], [8]. Therefore, coronary dilation and reduction of oxidative stress, inflammation, and platelet activation triggered by medications may thus attenuate minor cardiac necrosis during and after PCI, and reduce cardiac enzyme marker release. Recently, coronary stent implantation, which features a lower rate of restenosis during follow-up period than balloon angioplasty alone, has become a popular procedure [9], [10]. However, it is associated with a higher incidence of cardiac enzyme elevation than balloon angioplasty, and use of intracoronary metallic stent increases platelet activation [11], [12]. Therefore, preventing cardiac enzyme elevations is now becoming of much greater importance.

In patients with acute coronary syndrome, including unstable angina and acute myocardial infarction (AMI), myocardial reperfusion injury at the beginning of myocardial reperfusion may occur, resulting in myocardial tissue damage and cardiac dysfunction. In such situations, ECG, myocardial contrast echocardiographical and angiographical findings after

successful PCI can detect myocardial reperfusion at the microcirculatory level and myocardial damage [13], [14].

Combined use of pharmacological intervention in addition to PCI may moderate microcirculatory impairment and eventually reduce the incidence and/or severity of infarction, resulting in better clinical outcomes after PCI. In this review, the usefulness of pharmacological treatment in combination with PCI in attenuating myocardial injury in patients with CAD is highlighted.

II. GLYCOPROTEIN IIb/IIIa INHIBITORS

The platelet surface glycoprotein IIb/IIIa receptors play an important role in the final common pathway leading to platelet aggregation [15], [16]. Platelet deposition and aggregation are activated during PCI, particularly coronary stent implantation [7], [8], [17]. This phenomenon may induce platelet aggregation, which is related to acute coronary closure after procedures. Glycoprotein IIb/IIIa inhibitors disperse platelet deposition and also protect coronary microcirculation from embolization of platelet thrombi, which is sometimes induced by coronary balloon inflation and stent implantation. Therefore glycoprotein IIb/IIIa inhibitors have beneficial effects on preventing myocardial injury in these contexts.

In many large trials, some glycoprotein IIb/IIIa inhibitors have been reported to be effective in reducing ischemic complications in patients treated with PCI [18]-[21]. Of various glycoprotein IIb/IIIa inhibitors, abciximab has been most often used in trials for evaluation of clinical outcomes in patients undergoing PCI. In the EPIC trial, abciximab reduced the incidence of acute ischemic events by 35% in patients undergoing PCI [18]. However, it increased the incidence of major bleeding complications. In that study, concurrent administration of high doses of heparin was used. In the EPILOG trial [19], abciximab also had beneficial effects in reducing the risk of acute ischemic complications after PCI procedures. In bleeding complications, there were no significant differences among the group assigned to placebo with standard-dose heparin, the group assigned abciximab with low-dose, weight-adjusted heparin, and the group assigned abciximab with standard-dose, weight-adjusted heparin, though minor bleeding events were more frequently seen in the group assigned abciximab with standard-dose heparin. In a sub-analysis of the EPISTENT trial [20], abciximab significantly reduced angiographic complications including major and minor dissections, distal embolization, thrombus postprocedure, side branch or other vessel occlusion, residual stenosis >50%, transient coronary occlusion, and Thrombolysis In Myocardial Infarction (TIMI) final flow <3 during coronary stenting, compared with placebo [21]. In that study, abciximab also significantly reduced the incidence of CK-MB elevation in patients without angiographic complications.

According to AMI patients undergoing PCI, it has been reported that administration of glycoprotein IIb/IIIa inhibitors improves myocardial reperfusion [22], [23]. In the ADMIRAL trial, early administration of abciximab (a 0.25 mg/kg abciximab bolus before catheterization followed by a 12-hour

infusion of 0.125 µg/kg/min) significantly improved coronary patency before and after stenting in patients with AMI, compared to placebo administration. A meta-analysis of six randomized trials showed that early administration of glycoprotein IIb/IIIa inhibitors in patients with ST-elevation-AMI improved coronary patency after PCI with favorable trends for clinical outcomes [23].

III. BIVALIRUDIN

Bivalirudin is a direct thrombin inhibitor. Some studies found that bivalirudin use to be noninferior to treatment with heparin plus glycoprotein IIb/IIIa inhibitors [24],[25]. Furthermore, bleeding complications were less frequently seen in patients with periprocedural bivalirudin therapy than in patients with heparin plus glycoprotein IIb/IIIa inhibitors [25]. Thus, in this context, bivalirudin has a beneficial effect.

IV. THIENOPYRIDINE

Thienopyridine compounds such as ticlopidine and clopidogrel inhibit the platelet adenosine diphosphate receptor, resulting in blocking platelet aggregation. Dual antiplatelet therapy with aspirin and thienopyridine compound is widely used to prevent stent thrombosis and ischemic complication after PCI procedure [26], [27]. However, there are few studies focusing on the effect of pre-treatment with thienopyridine on preventing procedural related myocardial injury in patients undergoing PCI.

One retrospective report suggests that beginning ticlopidine therapy several days prior to elective stent implantation was associated with a reduced risk of procedural non-Q-wave myocardial infarction [28]. On the other hand, a prospective study reported that pretreatment with clopidogrel failed to decrease post-procedural elevation of troponin I and CK-MB [29]. It is also controversial whether there is an additive antiplatelet effect of ticlopidine in combination with glycoprotein IIb/IIIa inhibitors.

V. ADENOSINE

It is well known that brief episodes of ischemia in patients with repetitive balloon inflation during elective PCI relieve angina attack and ST elevation in ECG and that effects of transient episodes of angina protect myocardium from ischemic damage in patients with acute coronary syndrome [30], [31]. These cardioprotective effects are called preconditioning phenomenon. Adenosine plays a key role in preconditioning of myocardium [32], and thus might therefore have a beneficial effect in preventing myocardial necrosis following PCI, in addition to its vasodilator effect.

A small clinical trial consisting of 28 patients (16 in the control group and 12 in the adenosine group) showed that the intracoronary administration of adenosine (1 mg/min in the right coronary artery or 2 mg/min in the left coronary artery) over a 10-minute period during PCI reduced release of serum CK-MB 24 hours after PCI [33].

Hanna et al. reported that intracoronary administration of adenosine prevented no reflow phenomenon during rotational

atherectomy [34]. This report is very important because that slow flow and no reflow phenomenon is a common complication of rotational atherectomy [35].

It has been reported that in AMI patients treated with PCI, intracoronary administration of 4mg adenosine in 2ml saline into the distal bed of a totally occluded vessel prevented no-reflow phenomenon, and improved LV function a week after PCI [36].

VI. NITRIC OXIDE

Nitric oxide has been used for the relief of attacks of angina. Nitrates improve the myocardial oxygen supply-to-demand ratio in ischemic zones and relax coronary smooth muscle cells, resulting in suppression of coronary vasospasms [37].

Kurz et al. examined whether the intravenous administration of nitroglycerin for 12 hours after elective coronary stenting would decrease the incidence of angina and minor myocardial necrosis, as detected by cardiac troponin I increase, in a prospective, single center study including 100 patients [38]. Although the incidence of post-procedural chest pain did not differ between the two groups, the rate of occurrence of minor myocardial necrosis was significantly reduced in the nitroglycerin group.

Amit et al. reported that the intracoronary administration of nitroprusside (60µg), selectively injected into distal to the occlusion of the infarct-related artery, did not prevent the no-reflow phenomenon in patients with AMI, treated with primary PCI, although nitroprusside improved clinical outcomes at 6 months after PCI [39].

VII. NICORANDIL

Pharmacological treatment with ATP-sensitive potassium channel openers has similar cardioprotective effects like ischemic preconditioning [31], [40]. As mentioned above, ischemic preconditioning effects can help avoid complications during PCI and have important therapeutic implications.

Nicorandil, a hybrid of adenosine triphosphate-sensitive K channel opener and nitrates, has vasodilatory effects and thus increases coronary blood flow particularly in small vessels, prevents vasospasms and improves microvascular circulation [41], and cardiac sympathetic nerve activity, and thereby prevents slow flow in patients with ischemic heart disease [42]. For these reasons, nicorandil is now used as a pharmacological adjunct to PCI. Murakami et al. investigated whether intravenous 6-hour nicorandil infusion (a dose of 2µg/kg/min starting just before PCI) would reduce the incidence of minor cardiac marker elevation in 192 patients undergoing elective coronary stenting [43]. Nicorandil treatment reduced the incidence of elevation of cardiac markers and decreased the levels of such markers in serum after PCI with stent implantation. Kuwabara et al. found that in 48 patients treated with elective PCI, intracoronary and intravenous nicorandil during PCI improved the recovery of myocardial fatty acid utilization on evaluation by iodine-123-beta-methyl-p-iodophenyl-pentadecanoic acid single photon

emission computed tomography (I-123 BMIPP SPECT), and that this improvement was related to better left ventricular systolic function [44]. Iwasaki et al. showed that preventive effect on the incidence of slow or no reflow during rotational atherectomy was much more seen in patients treated with intracoronary nicorandil, compared with verapamil [45].

Ito et al. performed a prospective, single-center study including 81 patients with a first anterior AMI who received successful PCI and showed effectiveness of intravenous nicorandil (6mg for 24 hours after bolus injection at a dose of 4mg) on preventing no-reflow phenomenon microvascular function as assessed by intracoronary myocardial contrast echocardiography [46]. We reported that the addition of 12mg of nicorandil intravenously just before direct

PCI accelerated ST-segment resolution and improved epicardial flow in patients with ST-elevation AMI [47].

Nicorandil dose-dependently increases coronary artery blood flow and improves other physiological parameters [48], although administration of it, particularly in intracoronary fashion, may induce ventricular arrhythmia [49]. Further study is thus needed to determine optimal methods of administration and doses of this agent.

Diazoxide is also known as an ATP-sensitive potassium channel opener. Although experimental studies have shown cardioprotective effects of diazoxide, there are limited clinical data in PCI cases.

VIII. BETA-BLOCKERS

Beta-blocker therapy in patients with ischemic heart disease has been widely reported. Some studies examined whether beta-blocker reduced clinical complications in patients treated with PCI. Some experimental studies have shown that intravenous administration of beta-blockers prior to coronary artery occlusion favorably reduced electrocardiographic and enzymatic parameters [50].

Sharma et al. performed a prospective observational but non-randomized study including 1675 consecutive patients undergoing PCI, and showed that prior administration of beta-blockers before PCI had a cardioprotective effect in limiting CK-MB release after PCI [51]. On the other hand, Ellis et al. reported that there appeared to be no relationship between prior beta-blockers use and rise in CK-MB in a large and consecutive cohort of 6200 patients undergoing PCI [52]. There were important differences between these two studies in the statistical methods used to adjust differences between patients treated with or without beta-blockers. However, neither was a randomized study with assignment of beta-blockers or placebo to patients.

A recent double-blind clinical trial showed that the intracoronary administration of propranolol (15µg/kg), selectively delivered before first balloon inflation via an intracoronary catheter with the tip distal to the coronary lesion, significantly reduced the incidence of CK-MB elevation and troponin-T elevation after PCI and improve short-term clinical outcomes, compared to placebo [53]. Further study is needed to assess the efficacy of beta-blockers in the prevention of myocardial injury.

IX. ANGIOTENSIN CONVERTING ENZYME INHIBITORS

Treatment with angiotensin converting enzyme (ACE) inhibitors induces accumulation of bradykinin, reduces plasma angiotensin II levels and decreases plasma plasminogen activator inhibitor-1 (PAI-1), a risk factor for myocardial infarction [54]. These mechanisms are expected to be potentially beneficial in patients undergoing PCI. Particularly increasing bradykinin has been experimentally found to trigger preconditioning effects experimentally [55].

Recently, it has been reported that enalapril at increased coronary blood flow, and that pretreatment with enalapril at resulted in less ST-segment shift and less chest pain during the first balloon inflation in a prospective randomized study including 22 patients undergoing elective PCI [56].

X. 3-HYDROXY-3-METHYLGLUTARYL CO-ENZYME A (HMG-COA) REDUCTASE INHIBITORS: STATINS

3-hydroxy-3-methylglutaryl co-enzyme A (HMG-CoA) reductase inhibitors (statins) are widely used for treatment with hypercholesterolemia and/or coronary artery disease [57]. It is well known that statins have non-lipid-lowering pleiotropic effects including anti-thrombotic effects, improvement of vascular endothelial function, and reduction of oxidative stress and inflammation [58].

In nonrandomized observational studies, preoperative treatment with statins before elective PCI was associated with lower levels of periprocedural CK and CK-MB elevation [59]. Furthermore, randomized trials have indicated that statin administration before elective PCI reduces the rate of myocardial injury after PCI. In the Atorvastatin for Reduction of Myocardial Damage during Angioplasty (ARMYDA)

study, 153 patients scheduled for elective PCI were randomized to receive atorvastatin (40 mg/day) or placebo 7 days before the procedure [60]. Atorvastatin treatment significantly reduced post-procedural release of several markers of myocardial damage, including myoglobin, troponin I, and CK-MB, compared with the control. Briguori et al. investigated whether pre-procedural statin administration started at least 3 days before elective PCI was effective in preventing elevation of myocardial injury after the procedure and found that the incidence of CK-MB elevation >5 times the upper limit of normal was approximately 50% lower in patients treated with pre-procedural statin administration [61].

In AMI cases, we recently reported that ST segment resolution >50% on electrocardiography after direct PCI was much more observed in patients receiving chronic statin treatment before the onset of AMI than in patients without statin and that patients treated with statins had a lower peak CK levels [62]. Iwakura et al. demonstrated the effectiveness of chronic statin pretreatment before AMI in decreasing the incidence of the no-reflow phenomenon as assessed by intracoronary myocardial contrast echocardiography [63].

Many trials have demonstrated decreases in the incidence of myocardial injury after PCI for coronary artery disease in patients treated with pre-procedural statins. However, because these trials consisted of small study samples, larger multi-center studies are warranted to corroborate their findings.

XI. CONCLUSIONS

From various mechanisms, pharmacological intervention increases coronary blood flow, suppresses myocardial damage, and prevents complications during and after PCI procedures.

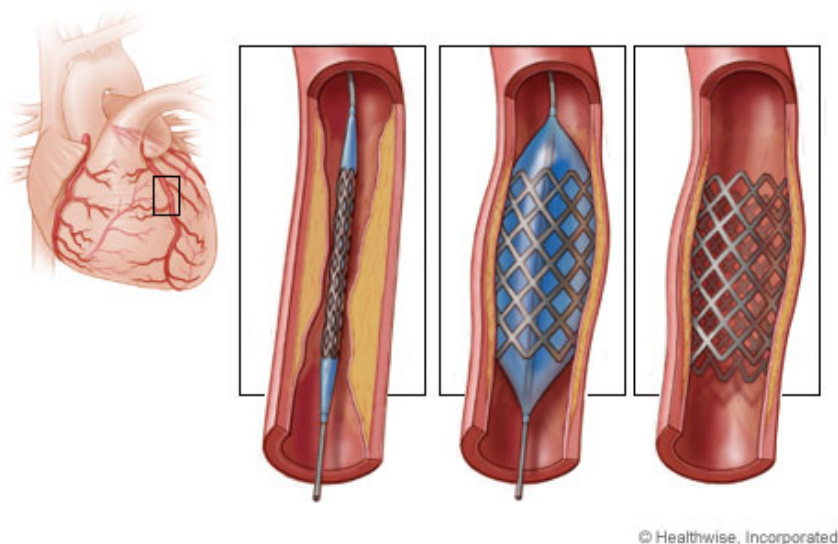


Fig. 1 Coronary Artery: Stent Procedure [64]

PCI may induce thromboembolism and/or atheroembolism in the distal coronary bed. The effect of treatment with glycoprotein IIb/IIIa inhibitors, bivalirudin, and thienopyridine

compounds is thought to block platelet aggregation and thus better prevention of procedural thrombus formation. Pre-treatment with statins may prevent microvascular plugging

due to atheroembolism. PCI may also induce microvascular spasms and/or edema. For these mechanisms, adenosine, nitric

oxide, and nicorandil play key roles.

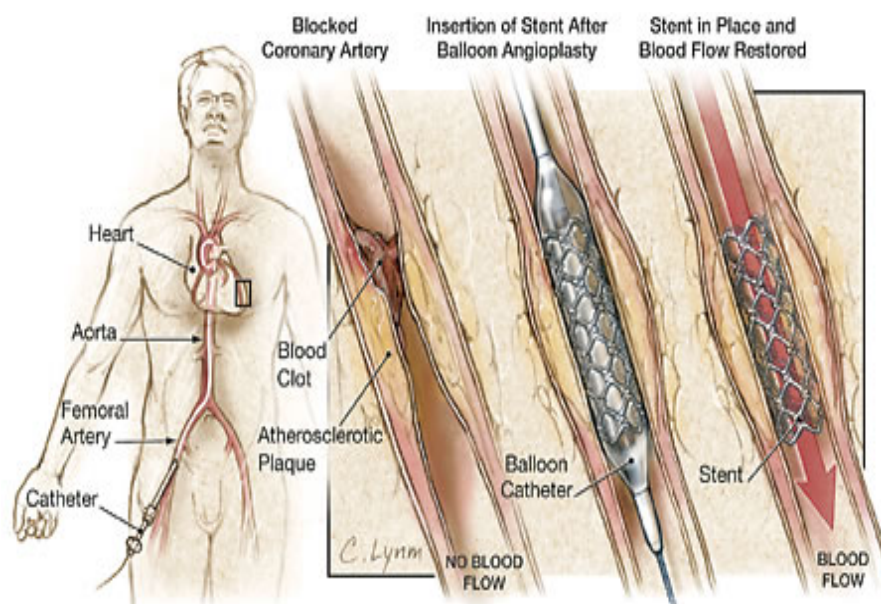


Fig. 2 Technique of Percutaneous Coronary Intervention [65]

Cardio protective effects mimicking preconditioning effects may decrease myocardial injury. From this point, adenosine, ATP-sensitive potassium channel openers, and ACE inhibitors may be useful. It is also important that oxygen free-radical production is prevented and endothelial functions are preserved by some medications. The ability of pharmacological treatment to prevent peri-and post-procedural myocardial injury when added to PCI, thus has important therapeutic implications.

REFERENCES

- [1] Ravkilde J, Nissen H, Mickley H, Andersen PE, Thayssen P, Horder M. Cardiac troponin T and CK-MB mass release after visually successful percutaneous transluminal coronary angioplasty in stable angina pectoris. *Am Heart J*. 1994;127:13–20.
- [2] Califf RM, Abdelmeguid AE, Kuntz RE, et al. Myonecrosis after revascularization procedures. *J Am Coll Cardiol*. 1998;31:241–251.
- [3] Kugelmass AD, Cohen DJ, Moscucci M, et al. Elevation of the creatine kinase myocardial isoform following otherwise successful directional coronary atherectomy and stenting. *Am J Cardiol*. 1994;74:748–754.
- [4] Tardiff BE, Califf RM, Tchong JE, et al. Clinical outcomes after detection of elevated enzymes in patients undergoing percutaneous intervention. *J Am Coll Cardiol*. 1999;33:88–96.
- [5] Simoons ML, van den Brand M, Lincoff M, et al. Minimal myocardial damage during coronary intervention is associated with impaired outcome. *Eur Heart J*. 1999;20:1112–1119.
- [6] Ramírez-Moreno A, Cardenal R, Pera C, et al. Predictors and prognostic value of myocardial injury following stent implantation. *Int J Cardiol*. 2004;97:193–198.
- [7] Badimon L, Badimon JJ, Galvez A, Chesebro JH, Fuster V. Influence of arterial wall damage and wall shear rate on platelet deposition: Ex vivo study in a swine model. *Arteriosclerosis*. 1986;6:312–320.
- [8] Wilentz JR, Sanborn TA, Haudenschild CC, Valeri CR, Ryan TJ, Faxon DP. Platelet accumulation in experimental angioplasty: Time course in relation to cardiovascular injury. *Circulation*. 1987;75:636–642.
- [9] Serruys PW, de Jaegere P, Kiemeneij F, et al. A comparison of balloon expandable-stent implantation with balloon angioplasty in patients with coronary artery disease. *N Engl J Med*. 1994;331:489–495.
- [10] Fischman DL, Leon MB, Baim DS, et al. A randomized comparison of coronary stent placement and balloon angioplasty in the treatment of coronary artery disease. *N Engl J Med*. 1994;331:496–501.
- [11] Gawaz M, Neumann FJ, Ott I, May A, Rudiger S, Schomig A. Changes in membrane glycoproteins of circulating platelets after coronary stent implantation. *Heart*. 1996;76:166–172.
- [12] Gawaz M, Neumann FJ, Ott I, May A, Schomig A. Platelet activation and coronary stent implantation. Effect of antithrombotic therapy. *Circulation*. 1996;94:279–285.
- [13] van't Hof AWJ, Liem A, de Boer MJ, Zijlstra F. For the Zwolle Myocardial Infarction Study Group. Clinical value of 12-lead electrocardiogram after successful reperfusion therapy for acute myocardial infarction. *Lancet*. 1997;350:615–619.
- [14] Claeys MJ, Bosmans J, Veenstra L, Jorens P, Raedt HD, Vrints CJ. Determinants and prognostic of persistent ST-segment elevation after primary angioplasty for acute myocardial infarction. *Circulation*. 1999;99:1972–1977.
- [15] Phillips DR, Charo IF, Parise LV, Fitzgerald LA. The platelet membrane glycoprotein IIb/IIIa complex. *Blood*. 1988;71:831–843.
- [16] Collier BS. Platelets and thrombolytic therapy. *N Engl J Med*. 1990;322:33–42.
- [17] Gawaz M, Neumann FJ, Ott I, Schiessler A, Schömig A. Platelet function in acute myocardial infarction treated with direct angioplasty. *Circulation*. 1996;93:229–237.
- [18] The EPIC Investigators. Use of a monoclonal antibody directed against the platelet glycoprotein IIb/IIIa receptor in high-risk coronary angioplasty. *N Engl J Med*. 1994;330:956–961.
- [19] EPILOG Investigators. Effect of the platelet glycoprotein IIb/IIIa receptor inhibitor abciximab with low-dose heparin on ischemic complications of the percutaneous coronary revascularization. *N Engl J Med*. 1997;336:1689–696.
- [20] The EPISTENT Investigators. Randomised placebo-controlled and balloon-angioplasty-controlled trial to assess safety of coronary stenting with use of platelet glycoprotein-IIb/IIIa blockade. *Lancet*. 1998;352:87–92.
- [21] Islam MA, Blankenship JC, Balog C, et al. Effect of abciximab on angiographic complications during percutaneous coronary stenting in the Evaluation of Platelet IIb/IIIa Inhibition in Stenting trial (EPISTENT). *Am J Cardiol*. 2002;90:916–921.
- [22] Montalescot G, Barragan P, Wittenberg O, et al. Platelet glycoprotein IIb/IIIa inhibition with coronary stenting for acute myocardial infarction. *N Engl J Med*. 2001;344:1895–1903.

- [23] Montalescot G, Borentain M, Payot L, Collet JP, Thomas D. Early vs late administration of glycoprotein IIb/IIIa inhibitors in primary percutaneous coronary intervention of acute ST-segment elevation myocardial infarction. *JAMA*. 2004;292:362–366.
- [24] Ebrahimi R, Lincoff AM, Bittl JA, et al. Bivalirudin vs heparin in percutaneous coronary intervention: a pooled analysis. *J Cardiovasc Pharmacol Ther*. 2005;10:209–216.
- [25] Feldman DN, Wong SC, Gade CL, Gidseg DS, Bergman G, Minutello RM. Impact of bivalirudin on outcomes after percutaneous coronary revascularization with drug-eluting stents. *Am Heart J*. 2007;154:695–701.
- [26] Schömig A, Neumann FJ, Kastrati A, et al. A randomized comparison of antiplatelet and anticoagulant therapy after the placement of coronary-artery stent. *N Engl J Med*. 1996;334:1084–1089.
- [27] Berg JM, Kelder JC, Suttrop MJ, et al. Effect of coumarins started before coronary angioplasty on acute complications and long-term follow-up, a randomized trial. *Circulation*. 2000;102:386–391.
- [28] Steinhilbl SR, Lauer MS, Mukherjee DP, et al. The duration of pretreatment with ticlopidine prior to stenting is associated with the risk of procedure-related non-Q-wave myocardial infarctions. *J Am Coll Cardiol*. 1998;32:1366–1370.
- [29] van der Heijden DJ, Westendorp ICD, Riezebos RK, et al. Lack of efficacy of clopidogrel pre-treatment in the prevention of myocardial damage after elective stent implantation. *J Am Coll Cardiol*. 2004;44:20–24.
- [30] Laskey WK. Beneficial impact of preconditioning during PTCA on creatine kinase release. *Circulation*. 1999;99:2085–2089.
- [31] Nakagawa Y, Ito H, Kitakaze M, et al. Effect of angina pectoris on myocardial protection in patients with reperfused anterior wall myocardial infarction: retrospective clinical evidence of “preconditioning” *J Am Coll Cardiol*. 1995;25:1076–1083.
- [32] Liu GS, Thornton J, Van Winkle DM, Stanley AW, Olsson RA, Downey JM. Protection against infarction afforded by preconditioning is mediated by A1 adenosine receptors in rabbit heart. *Circulation*. 1991;84:350–356.
- [33] Desmet WJR, Dens J, Coussement P, van de Werf F. Does adenosine prevent myocardial micronecrosis following percutaneous coronary intervention? The ADELIN pilot trial. *Heart*. 2002;88:293–295.
- [34] Hanna GP, Yhip P, Fujise K, et al. Intracoronary adenosine administered during rotational atherectomy of complex lesions in native coronary arteries reduces the incidence of no-reflow phenomenon. *Catheter Cardiovasc Interv*. 1999;48:275–278.
- [35] Ellis SG, Popma JJ, Buchbinder M, et al. Relation of clinical presentation, stenosis morphology, and operator technique to the procedural results of rotational atherectomy and rotational atherectomy-facilitated angioplasty. *Circulation*. 1994;89:882–892.
- [36] Marzilli M, Orsini E, Marraccini P, Testa R. Beneficial effects of intracoronary adenosine as an adjunct to primary angioplasty in acute myocardial infarction. *Circulation*. 2000;101:2154–2159.
- [37] Fallen EL, Nahmias C, Scheffel A, Coates G, Beanlands R, Garnett ES. Redistribution of myocardial blood flow with topical nitroglycerin in patients with coronary artery disease. *Circulation*. 1995;91:1381–1388.
- [38] Kurz DJ, Naegeli B, Bertel O. A double-blind, randomized study of the effect of immediate intravenous nitroglycerin on the incidence of postprocedural chest pain and minor myocardial necrosis after elective coronary stenting. *Am Heart J*. 2000;139:35–43.
- [39] Amit G, Cafri C, Yaroslavtsev S, et al. Intracoronary nitroprusside for the prevention of the no-reflow phenomenon after primary percutaneous coronary intervention in acute myocardial infarction. A randomized, double-blind, placebo-controlled clinical trial. *Am Heart J*. 2006;152:887 e9–e14.
- [40] Akai K, Wang Y, Sato K, et al. Vasodilatory effect of nicorandil on coronary arterial microvessels: its dependency on vessel size and the involvement of the ATP-sensitive potassium channels. *J Cardiovasc Pharmacol*. 1995;26:541–547.
- [41] The IONA Study Group. Effect of nicorandil on coronary events in patients with stable angina: the Impact Of Nicorandil in Angina (IONA) randomised trial. *Lancet*. 2002;359:1269–1275.
- [42] Kasama S, Toyama T, Hatori T, et al. Comparative effects of nicorandil with isosorbide mononitrate on cardiac sympathetic nerve activity and left ventricular function in patients with ischemic cardiomyopathy. *Am Heart J*. 2005;150:477 e1–e8.
- [43] Murakami M, Iwasaki K, Kusachi S, et al. Nicorandil reduces the incidence of minor cardiac marker elevation after coronary stenting. *Int J Cardiol*. 2006;107:48–53.
- [44] Kuwabara Y, Watanabe S, Nakaya J, et al. Postrevascularization recovery of fatty acid utilization in ischemic myocardium: a randomized clinical trial of potassium channel opener. *J Nucl Cardiol*. 2000;7:320–327.
- [45] Iwasaki K, Samukawa M, Furukawa H. Comparison of the effects of nicorandil versus verapamil on the incidence of slow flow/no reflow during rotational atherectomy. *Am J Cardiol*. 2006;98:1354–1356.
- [46] Ito H, Taniyama Y, Iwakura K, et al. Intravenous nicorandil can preserve microvascular integrity and myocardial viability in patients with reperfused anterior wall myocardial infarction. *J Am Coll Cardiol*. 1999;33:654–660.
- [47] Ishii H, Ichimiya S, Kanashiro M, et al. Impact of a single intravenous administration of nicorandil before reperfusion in patients with ST-segment elevation myocardial infarction. *Circulation*. 2005;112:1284–1288.
- [48] Kato K. Haemodynamic and clinical effects of an intravenous potassium channel opener—a review. *Eur Heart J*. 1993;14(Suppl. B):40–47.
- [49] Kojima S, Ishikawa S, Ohsawa K, Mori H. Determination of effective and safe dose for intracoronary administration of nicorandil in dogs. *Cardiovasc Res*. 1990;24:727–732.
- [50] Reimer KA, Rasmussen MM, Jennings RB. Reduction by propranolol of myocardial necrosis following temporary coronary occlusion in dogs. *Circ Res*. 1973;33:353–363.
- [51] Sharma SK, Kini A, Marmur JD, Fuster V. Cardioprotective effect of prior β -blocker therapy in reducing creatine kinase-MB elevation after coronary intervention: benefit is extended to improvement in intermediate-term survival. *Circulation*. 2000;102:166–172.
- [52] Ellis SG, Brener SJ, Lincoff M, et al. β -blockers before percutaneous coronary intervention do not attenuate postprocedural creatine kinase isoenzyme rise. *Circulation*. 2001;104:2685–2688.
- [53] Wang FW, Osman A, Otero J, et al. Distal myocardial protection during percutaneous coronary intervention with an intracoronary β -blocker. *Circulation*. 2003;107:2914–2919.
- [54] Brown NJ, Agirbasli MA, Williams GH, Litchfield WR, Vaughan DE. Effect of activation and inhibition of the rennin angiotensin system on plasma PAI-1 in humans. *Hypertension*. 1998;32:965–971.
- [55] Schulz R, Post H, Vahlhaus C, Heusch G. Ischemic preconditioning in pigs: a graded phenomenon: its relation to adenosine and bradykinin. *Circulation*. 1998;98:1022–1029.
- [56] Leesar MA, Jneid H, Tang XL, Bolli R. Pretreatment with intracoronary enalaprilat protects human myocardium during percutaneous coronary angioplasty. *J Am Coll Cardiol*. 2007;49:1607–1610.
- [57] Serruys PW, de Feyter P, Macaya C, et al. Fluvastatin for prevention of cardiac events following successful first percutaneous coronary intervention: a randomized controlled trial. *JAMA*. 2002;287:3215–3122.
- [58] Takemoto M, Liao JK. Pleiotropic effects of 3-hydroxy-3-methylglutaryl coenzyme A reductase inhibitors. *Arterioscler Thromb Vasc Biol*. 2001;21:1712–1719.
- [59] Herrmann J, Lerman A, Baumgart D, et al. Preprocedural statin medication reduces the extent of periprocedural non-Q-wave myocardial infarction. *Circulation*. 2002;106:2180–2183.
- [60] Pasceri V, Patti G, Nusca A, Pristipino C, Richichi G, Di Sciascio G. Randomized trial of atorvastatin for reduction of myocardial damage during coronary intervention: results from the ARMYDA (Atorvastatin for Reduction of Myocardial Damage during Angioplasty) study. *Circulation*. 2004;110:674–678.
- [61] Briguori C, Colombo A, Airolidi F, et al. Statin administration before percutaneous coronary intervention: impact on periprocedural myocardial infarction. *Eur Heart J*. 2004;25:1822–828.
- [62] Ishii H, Ichimiya S, Kanashiro M, et al. Effects of receipt of chronic statin therapy before the onset of acute myocardial infarction: a retrospective study in patients undergoing primary percutaneous coronary intervention. *Clin Ther*. 2006;28:1812–819.
- [63] Iwakura K, Ito H, Kawano S, et al. Chronic pre-treatment of statins is associated with the reduction of the no-reflow phenomenon in the patients with reperfused acute myocardial infarction. *Eur Heart J*. 2006;27:534–539.
- [64] www.Health-beliefnet.com. Coronary Stenting (Copy right by Nucleus Medical Art, Inc. 2008) Last reviewed November 2007 by J.Peter Oettgen MD.
- [65] Janet M. Torpy MD, Cassio Lynn MA et al. Percutaneous Coronary Intervention. *JAMA*. Feb 11, 2004;291(6):778.