

Gastroprotective Activity of *Swietenia Mahagoni* Seed Extract on Ethanol-Induced Gastric Mucosal Injury in Rats

Salma Saleh Alrdahe, Mahmood Ameen Abdulla, Shaharudin Abul Razak, Farkaad Abdul Kadir, Pouya Hassandarvish

Abstract—*Swietenia mahagoni* have been used in traditional medicine for treatment of different diseases. Present study was performed to evaluate anti-ulcerogenic activity of ethanol seed extract against ethanol induced gastric mucosal injury in rats. Six groups of rats were orally pre-treated respectively with carboxymethyl cellulose, omeprazole 20 mg/kg, 50, 100, 200 and 400 mg/kg plant extract one hour before oral administration of absolute ethanol to generate gastric mucosal injury. After additional hour, rats were sacrificed and ulcer areas of gastric walls were determined. Grossly, carboxymethyl cellulose group exhibited severe mucosal injury, whereas pre-treatment with plant extract exhibited significant protection of gastric mucosa. Histology, carboxymethyl cellulose group exhibited severe damage of gastric mucosa; edema and leucocytes infiltration of sub mucosa compared to plant extract which showed gastric protection. Acute toxicity study did not manifest any toxicological signs in rats. Conclusions, results suggest that *S. mahagoni* promotes ulcer protection as ascertained grossly and histologically.

Keywords—Cytoprotection, Gastric ulcer, Histology, *Swietenia mahagoni* seed.

I. INTRODUCTION

Swietenia mahagoni (Linn.) Jacq. (Meliaceae) is a large, deciduous, and economically important timber tree native to the West Indies. This tree is mainly cultivated at tropical zones, such as India, Malaysia, and Southern China [1]. This plant has various types of medicinal values like anti-malarial and anti-diarrhoeal effects [2]-[3]. The plant extracts have been accounted to possess antibacterial and antifungal activities [4]. Limonoids obtained from *S. mahagoni* have antifungal activity [5] and diabetes therapy [6]. *S. mahagoni* seeds have been used as folk medicine for the treatment of

hypertension, diabetes, and malaria [7], and they have also been reported to have medicinal value for treatment of cancer, amoebiasis, coughs, chest pains and intestinal parasitism. The biologically active ingredients, tetranortriterpenoids and fatty acids, are considered to be responsible for these therapeutic effects [8]. *Swietenia mahagoni* may have potent antioxidant and antimicrobial activity [9]-[10]. Thus far, there is no data available on gastro-protective activity of *S. mahagoni* crude extract. The present study was undertaken to evaluate anti-ulcerogenic properties of ethanol crude extract of *S. mahagoni* seeds in rats.

II. MATERIALS AND METHOD

A. Omeprazole

Omeprazole is a proton pump inhibitor has been widely used as acid inhibitor agents for the treatment of disorders related to gastric acid secretion for about 15 years [11]. Omeprazole is substituted benzimidazoles and it inhibits acid secretion by acting on the hydrogen-potassium exchanger (H^+ : K^+ -ATPase) for the apical plasma membrane of the gastric mucosa [12]. Omeprazole is highly selective for the proton pump and undergo catalyzed conversion into active form within the acid forming space. The active inhibitors react with SH (thiol) group of the proton pump, resulting in inhibition of acid formation [13]. In this study, omeprazole was used as the reference anti-ulcer drug, and was obtained from the University Malaya Medical Centre (UMMC) Pharmacy. The drug was dissolved in carboxymethyl cellulose (CMC) and administered orally to the rats in concentrations of 20 mg/kg body (5 ml/kg) [14].

B. Plant specimen and extract preparation

Swietenia mahagoni seed were obtained from Ethno Resources Sdn Bhd, Selangor Malaysia, and identified by comparison with the Voucher specimen deposited at the Herbarium of Rimba Ilmu, Institute of Science Biology, University of Malaya, Kuala Lumpur. The seeds were shade-dried for 7-10 days and was then finely powdered using electrical blender. One hundred grams of fine powder was soaked in 500 ml of 95% ethanol in conical flask for 3 days. After 3 days, the mixture was filtered using a fine muslin cloth followed by filter paper (Whatman No. 1) and distilled under reduced pressure in an Eyela rotary evaporator (Sigma-Aldrich, USA). The dry extract was then dissolved in

Salma. S. Alrdahe, a student in master of Biotechnology, Institute of Biological Science, Faculty of Science, University of Malaya. (Phone No:0060342563832. Mobile No: 0060133533832; e-mail: salma_alrdahe@hotmail.com).

Assos. Prof. DR. Mahmood. A. A. Department of Molecular Medicine, Faculty of Medicine, University of Malaya, 50603, Kuala Lumpur, Malaysia. (Mobil No: 0060102737089; e-mail: mahmood955@yahoo.com).

DR. Shaharudin Abdul Razak. Institute of Biological Science, Faculty of science, Universirt of Malaya, 50603, Kuala Lumpur, Malaysia.

Farkaad Abdul Kadir. Master student- Anatomy UKM.

Pouya Hassandarvish. Department of Molecular Medicine, Faculty of Medicine, University of Malaya, 50603, Kuala Lumpur, Malaysia

carboxymethyl cellulose (CMC, 0.25% w/v) and administered orally to rats in concentrations of 50, 100, 200, 400 and 800 mg/kg body weight (5 ml/kg body weight) [15].

C. Acute toxicity test

Experimental animals

Adult healthy male and female *Sprague Dawley* rats (6-8 weeks old) were obtained from the Animal House, Faculty of Medicine, University of Malaya, Kuala Lumpur (Ethics No. PM 07/05/2008 MAA (a) (R)). The rats weighed between 150 – 180 g. The animals were given standard rat pellets and tap water. The acute toxic study was used to determine a safe dose for the rhizome extract. Thirty six *Sprague Dawley* rats (18 males and 18 females) were assigned equally each into 3 groups labelled as vehicle (CMC, 0.25% w/v, 5 ml/kg); 2 g/kg and 5 g/kg of *Swietenia mahagoni* seed extract preparation, respectively. The animals were fasted overnight (food but not water) prior to dosing. Food was withheld for a further 3 to 4 hours after dosing. The animals were observed for 30 min and 2, 4, 8, 24 and 48 h after the administration for the onset of clinical or toxicological symptoms. Mortality, if any was observed over a period of 2 weeks. The acute toxicity LD₅₀ was calculated as the geometric mean of the dose that resulted in 100% lethality and that which caused no lethality at all. The animals were sacrificed on the 15th day. Histology, haematological and serum biochemical parameters were determined following standard methods [16]-[17]. The study was approved by the ethics Committee for animal experimentation, Faculty of Medicine, University of Malaya, Malaysia. All animals received human care according to the criteria outlined in the "Guide for the Care and Use of laboratory Animals" prepared by the National Academy of Sciences and published by the national Institute of health.

D. Anti-ulcer activity

Experimental animals

Sprague Dawley healthy adult male rats were obtained from the Experimental Animal House, Faculty of Medicine, University of Malaya, and Ethic No. PM/27/07/2009/MAA (R). The rats were divided randomly into 6 groups of 6 rats each. Each rat that weighted between 200 - 225 g was placed individually in separate cage (one rat per cage) with wide-mesh wire bottoms to prevent coprophagia during the experiment. The animals were maintained on standard pellet diet and tap water. The study was approved by the Ethics Committee for Animal Experimentation, Faculty of Medicine, University of Malaya, Malaysia. Throughout the experiments, all animals received human care according to the criteria outlined in the "Guide for the Care and Use of laboratory Animals" prepared by the National Academy of Sciences and published by the national Institute of health.

E. Gastric ulcer-induction by ethanol and tissue sample collection

The rats were fasted for 48 hours before the experiment [18], but were allowed free access drinking water up till 2 hours before the experiment. Gastric ulcer in *Sprague Dawley*

was induced by orogastric intubation of absolute ethanol (5 ml/kg) according to the method described by [15] with slight modification. Ulcer control group was orally administered with vehicle (CMC, 0.25% w/v, 5ml/kg). The reference group was received oral doses of 20 mg/kg omeprazole in CMC (5 ml/kg) as positive controls. Experimental groups were orally administered with. 50, 100, 200 and 400 mg/kg of crude ethanol extract of *S. mahagoni* seed in CMC solution (5 ml/kg) each, respectively. One hour after this pre-treatment; all groups of rats were administered with absolute ethanol (5 ml/kg) in order to induce gastric ulcers except normal control group which administered CMC (5 ml/kg) [19]. The rats were euthanized by cervical dislocation 60 minutes later [20] under over dose of diethyl ether anaesthesia and their stomachs were immediately excised.

F. Gross gastric lesions evaluation

Any ulcers would be found in the gastric mucosa, appearing as elongated bands of hemorrhagic lesions parallel to the long axis of the stomach. Each gastric mucosa was thus examined for damage. The length (mm) and width (mm) of the ulcer on the gastric mucosa were measured by a planimeter ($10 \times 10 \text{ mm}^2$ = ulcer area) under dissecting microscope (1.8x). The area of each ulcer lesion was measured by counting the number of small squares, $2 \text{ mm} \times 2 \text{ mm}$, covering the length and width of each ulcer band. The sum of the areas of all lesions for each stomach was applied in the calculation of the ulcer area (UA) wherein the sum of small squares $\times 4 \times 1.8$ = UA mm^2) as described by [21] with slight modification. The inhibition percentage (I%) was calculated by the following formula as described by [22] with slight modification.

$$(I\%) = [(UA_{\text{control}} - UA_{\text{treated}}) \div UA_{\text{control}}] \times 100\%.$$

G. Histological evaluation of gastric lesions

Specimens of the gastric walls from each rat were fixed in 10% buffered formalin and processed in a paraffin tissue processing machine. Sections of the stomach were made at a thickness of 5 μ and stained with haematoxylin and eosin for histological evaluation.

H. Statistical analysis

All values were reported as mean \pm S.E.M. The statistical significance of differences between groups was assessed using one-way ANOVA. A value of $p < 0.05$ was considered significant.

III. RESULT

A. Acute toxicity study

Acute toxicity study in which the animals treated with the rhizome extract at a dose of 2 g/kg and 5 g/kg of *Swietenia mahagoni* seed extracts were kept under observation for 14 days. All the animals remain alive and did not manifest any significant visible of toxicity at these doses. There were no abnormal signs, behavioural changes, body weight changes, or macroscopic finding at any time of observation. There was no mortality in the above-mentioned doses at the end of 14 days of observation. Histology of liver and kidney, haematology

and serum biochemistry revealed no significant differences between groups. From these results it is concluded that the extract is quite safe even at these higher doses and has no acute toxicity and the oral lethal dose (LD₅₀) for the male and female rats were greater than their 5 g/kg body weight.

B. Gross evaluation of gastric lesions

The anti-ulcer activity of *S. mahagoni* seed extract in ethanol-induced gastric lesion model is reported in Table 1. Results showed that rats pre-treated with *S. mahagoni* seed extracts before being given absolute alcohol had significantly reduced areas of gastric ulcer formation compared to rats pre-treated with only CMC (ulcer control group) (Figure 1 a, b and c). Moreover, the seed extract significantly suppressed the formation of the ulcers and it was interesting to note the flattening of gastric mucosal folds in rats pre-treated with *S. mahagoni* seed extract. It was also observed that protection of gastric mucosa was more prominent in rats pre-treated with 400 mg/kg rhizome extract (Table 1). Beside, ethanol-induced mucosal damage was significantly reduced in size and severity by pre-treatment of the animals with *S. mahagoni* seed extract. The significant inhibition of gastric ulcer in pre-treatment with rhizome extract was compared with omeprazole which is a standard drug used for curing gastric ulcer.

TABLE I
OBSERVED ULCER AREA AND INHIBITION PERCENTAGE IN RATS

Animal Group	Pre-Treatment (5ml/kg dose)	Ulcer Area (mm) ² (Mean±S.E.M)	Inhibition (%)
1	CMC (Ulcer control)	920±11.76	-
2	Omeprazole (20mg/kg)	213.0±11.25	76.85%
3	<i>S.mahagoni</i> (50mg/kg)	405.60±7.30	55.91%
4	<i>S.mahagoni</i> (100mg/kg)	280.00±7.07	69.57%
5	<i>S.mahagoni</i> (200mg/kg)	125.80±6.98	86.33%
6	<i>S.mahagoni</i> (400mg/kg)	45.20±2.89	95.09%

All values are expressed as mean ± standard error mean. Means with different superscripts are significantly different. The mean difference is significant at the 0.05 level.

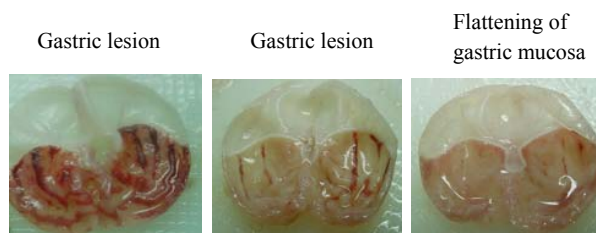


Fig.1 Gross appearance of the gastric mucosa in a rat “(a)” pre-treated with 5 ml/kg of CMC (ulcer control). Severe injuries are seen in the gastric mucosa. “(b)” Pre-treated with 5 ml/kg of omeprazole (20 mg/kg). Injuries to the gastric mucosa are milder compared to the injuries seen in the ulcer control rat. “(c)” pre-treated with 5 ml/kg of *Swietenia mahagoni* seed extract (400 mg/kg). Very mild injuries to the gastric mucosa are seen, and showed flattening of gastric mucosa.

C. Histological evaluation of gastric lesions

Histological observation of ethanol induced gastric lesions in ulcer control group pre-treated with only CMC, showed comparatively extensive damage to the gastric mucosa, and oedema and leucocytes infiltration of the sub-mucosal layer (Figure 2a). Rats that received pre-treatment with *S. mahagoni* seed extract had comparatively better protection of the gastric mucosa as seen by reduction in ulcer area, reduced or absence of sub-mucosal oedema and leucocytes infiltration (Figure 2b and c). The *S. mahagoni* seed extract has been shown to exert the cytoprotective effects in a dose-dependent manner.

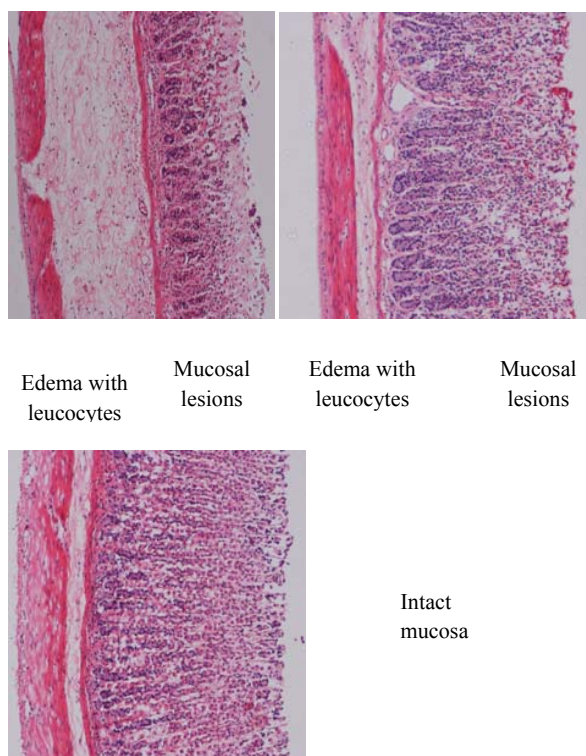


Fig. 2 Histological section of gastric mucosa in a rat “(a)” pre-treated with 5 ml/kg of CMC only. There is severe disruption to the surface epithelium, and oedema of the sub-mucosa layer with leucocytes infiltration. “(b)” pre-treated with 5 ml/kg of omeprazole (20 mg/kg). There is mild disruption to the surface epithelium with

mild oedema and leucocytes infiltration of the sub-mucosal layer. "(c)" pre-treated with 5 ml/kg of *Swietenia mahagoni* seed extract (400 mg/kg). There is very mild disruption to the surface epithelium with no oedema and no leucocytes infiltration of the sub-mucosal layer (H&E stain 10x).

IV. DISCUSSION

Peptic ulcers are caused when the natural balances between the aggressive factors of acid and pepsin and defensive mechanisms of mucus, bicarbonate, mucosal turnover and blood supply (mucosal barrier) are disturbed [23]. Reference [24] have suggested that acid and pepsin are relatively less important as causative agents and that a defect in the defensive mechanism of gastric mucosa is the first step toward ulcer formation. Although in most cases the aetiology of ulcer is unknown, it is generally accepted that it is the result of an imbalance between aggressive factors and maintenance of the mucosal integrity through the endogenous defence mechanism [23]. It is known that gastric lesions produced by ethanol administration appeared as multiple-hemorrhagic red bands of different size along the glandular stomach. Ethanol is commonly used for inducing ulcer in experimental rats and lead to intense gastric mucosal damage. Studies suggest that the ethanol damage to the gastrointestinal mucosa starts with micro-vascular injury, namely disruption of the vascular endothelium resulting in increased vascular permeability, oedema formation and epithelial lifting [25]. Ethanol produces necrotic lesions in the gastric mucosa by its direct toxic effect, reducing the secretion of bicarbonates and production of mucus [26]. Exposure to ethanol increases the extension of cellular damage in a dose-dependent way [27]. Oxidative stress plays an important role in the pathogenesis of various diseases including gastric ulcer, with antioxidants being reported to play a significant role in the protection of gastric mucosa against various necrotic agents [28]. Antioxidants could help to protect cells from damage caused by oxidative stress while enhancing the body's defence systems against degenerative diseases. Administration of antioxidants inhibits ethanol-induced gastric injury in rat [29]. *Swietenia mahagoni* seed crude extract possess a broad spectrum of biological activities and the plant extract have been shown to contain relatively large quantity antioxidant compounds [9] and it is speculated that the gastroprotective exerted by *Swietenia mahagoni* seed extract could be attributed to its antioxidant property. The result of the present study also revealed protection of gastric mucosa and inhibition of leucocytes infiltration of gastric wall in rats pre-treated with *Swietenia mahagoni* seed extract. Similarly, [30] reported that teprenone exerts a protective effect against mucosal lesions through inhibition of neutrophil infiltration in the ulcerated gastric tissue and [31] demonstrated that the reduction of neutrophil infiltration into ulcerated gastric tissue promotes the healing of gastric ulcers in rats. Reference [32] showed that oral administration of plant extract before ethanol administration significantly decreased neutrophil infiltration of gastric mucosa and [33] observed that an increase in neutrophil infiltration into ulcerated gastric tissue delayed the healing of

gastric ulcers in rats. Absolute alcohol would extensively damage the gastric mucosa leading to increased neutrophil infiltration into the gastric mucosa. Oxygen free radicals derived from infiltrated neutrophils in ulcerated gastric tissues have inhibitory effect on gastric ulcers healing in rats [34]. Neutrophils mediate lipid peroxidation through the production of superoxide anions [35]. In the present study, we observed flattening of the mucosal folds which suggests that gastroprotective effect of *Swietenia mahagoni* seed extract might be due to a decrease in gastric motility. It is reported that the changes in the gastric motility may play a role in the development and prevention of experimental gastric lesions [36]-[37]. Relaxation of circular muscles may protect the gastric mucosa through flattening of the folds. This will increase the mucosal area exposed to necrotizing agents and reduce the volume of the gastric irritants on fugal crest [38]. Ethanol produces a marked contraction of the circular muscles of rat fundic strip. Such a contraction can lead to mucosal compression at the site of the greatest mechanical stress, at the crests of mucosal folds leading to necrosis and ulceration [39]. The acute toxicity profile of *B. rotunda* rhizome extract could be considered favourable judging from the absence of adverse clinical manifestations in experimental animals after 14 days of observation. It is concluded that the extract has no acute toxicity and that the oral lethal dose for male and female rats is in excess of 5 g/kg. In conclusion, *Swietenia mahagoni* seed extracts could significantly protect the gastric mucosa against ethanol-induced injury. Such protection was shown to be dose dependent as ascertained by the reduction of ulcer areas in the gastric wall as well as the reduction or inhibition of oedema and leucocytes infiltration of sub-mucosal layers, and protection was most prominent at a dose of 400 mg/kg rhizome extract. Further studies are required to determine the active ingredients responsible for the mechanism of antiulcer of *Swietenia mahagoni* seed extracts.

ACKNOWLEDGMENT

The authors express gratitude to the staff of the Faculty of Medicine Animal House for the care and supply of rats, and to the University of Malaya for the financial support (P0102/2009 C).

REFERENCES

- [1] Mulholland, D., B. Parel, and P. Coombes. The chemistry of the Meliaceae and Ptaeroxylaceae of southern and eastern Africa and Madagascar. *Current Organic Chemistry*, 2000, 4(10): p. 1011-1054.
- [2] Munoz, V., Sauvain, M., Bourdy, G., Callapa, J., Rojas, I., Vargas, L., Tae A., and Deharo, E. The search for natural bioactive compounds through a multidisciplinary approach in Bolivia. Part II. Antimalarial activity of some plants used by Mosekene Indians. *Journal of ethnopharmacology*, 2000, 69(2): 139-155.
- [3] Maiti, A., S. Dewanjee, and S. Mandal. In vivo evaluation of antidiarrhoeal activity of the seed of *Swietenia macrophylla* King (Meliaceae). *Tropical Journal of Pharmaceutical Research*, 2007, 6(2): 711-716.
- [4] Majid, M., Rahman, I.M.M.; Shipar, M.A.H.; Uddin, M.H.; Chowdhury, R.. Physico-chemical characterization, antimicrobial activity and toxicity analysis of *Swietenia mahagoni* seed oil. *International Journal of Agriculture and Biology* (Pakistan), 2004, 6(2),350-354.

- [5] Govindachari, T.; Suresh G.; Banumathy B.; Masilamani S.; Gopalakrishnan G.; KrishnaKumari G.N. Antifungal activity of some B, D-seco limonoids from two meliaceae plants. *Journal of Chemical Ecology*, 1999, 25(4): 923-933.
- [6] Li, D., Chen, J.H., Chen, Q., Li, G.W., Chen, J., Yue, J.M., Chen, M.L., Wang, X.P., Shen, J.H., Shen, X., Jiang, H.L. Swietenia mahagony extract shows agonistic activity to PPAR and gives ameliorative effects on diabetic db/db mice. *Acta Pharmacologica Sinica*, 2005, 26(2): 220-222.
- [7] Nagalakshmi, M.; Thangadurai, D.; Muralidara, D.; Pullaiah, R.T. Phytochemical and antimicrobial study of Chukrasia tabularis leaves. *Fitoterapia*, 2001, 72(1): 62-64.
- [8] Bacsal, K.; Havez, L.; Diaz, I.; Espina, S.; Javillo, J.; Manzanilla, H.; Motalban, J.; Panganiban, C.; Rodriguez, A.; Sumpaico, C.; Talip, B.; Yap, S. The effect of Swietenia mahagony (mahogany) seed extract on indomethacin-induced gastric ulcers in female Sprague-Dawley rats. *Acta Medica Philippina*, 1997, 3:127-139.
- [9] Sahgal, G., Ramanathan S, Sasidharan S, Mordi MN, Ismail S, Mansor SM. In Vitro Antioxidant and Xanthine Oxidase Inhibitory Activities of Methanolic Swietenia mahagoni Seed Extracts. *Molecules* (Basel, Switzerland), 2009, 14(11): 4476-85.
- [10] Sahgal, G., Ramanathan, S., Sasidharan, S., Mordi, M.N., Ismail, S. and Mansor, S.M. Phytochemical and antimicrobial activity of Swietenia mahagoni crude methanolic seed extract. *Tropical Biomedicine*, 2009, 26(3): 274-279.
- [11] Li, X., Andersson, T.B., Ahlstrom, M., Weidolf, L. Comparison of inhibitory effects of the proton pump-inhibiting drugs omeprazole, esomeprazole, lansoprazole, pantoprazole, and rabeprazole on human cytochrome P450 activities. *Drug metabolism and disposition*, 2004, 32(8): 821-827.
- [12] Satoh, H., Inatomi, N., Nagaya, H., Ianda, I., Nohara, A., Nakamura, H. Antisecretory and antiulcer activities of a novel proton pump inhibitor AG-1749 in dogs and rats. *Journal of Pharmacology and Experimental Therapeutics*, 1989, 248(2): 806-815.
- [13] Nagaya, H., Inatomi, N., Ohara, A., Satoh, H. (1991). Effects of the enantiomers of lansoprazole (AG-1749) on (H⁺ K⁺)-ATPase activity in canine gastric microsomes and acid formation in isolated canine parietal cells. *Biochemical pharmacology*, 42(10): 1875-1878.
- [14] Pedernera, A.M., Guardia, T., Caleron, C.G., Rotelli, A.F., de la Rocha, N.F., di Genaro, S., Pelze, L.F. Anti-ulcerogenic and anti-inflammatory activity of the methanolic extract of Larrea divaricata Cav. in rat. *Journal of ethnopharmacology*, 2006, 105(3): 415-420.
- [15] De Pasquale, R., Germano, M.P., Keita, A., Sanogo, R., Lauk, L. Antiulcer activity of Pteleopsis suberosa. *Journal of ethnopharmacology*, 1995, 47(1): 55-58.
- [16] Bergmeyer, H. and M. Horder. IFCC methods for the measurement of catalytic concentration of enzymes, Part 3. IFCC method for alanine aminotransferase. *J Clin Chem Clin Biochem*, 1980, 18: 521-534.
- [17] Tietz, N.W., Rinker, A.D., Shaw, L.M. (1983). IFCC methods for the measurement of catalytic concentration of enzymes, Part 5. IFCC method for alkaline phosphatase. *J Clin Chem Clin Biochem*, 1983, 21(11): 731-748.
- [18] Garg, G.P., Nigam, S.K., Ogle, C.W. The gastric antiulcer effects of the leaves of the neem tree. *Planta medica*, 1993, 59: 215-215.
- [19] Hollander, D., Taranawski, A., Krause, W.J., Gergely, H. Protective effect of sucralfate against alcohol-induced gastric mucosal injury in the rat. Macroscopic, histologic, ultrastructural, and functional time sequence analysis. *Gastroenterology*, 1985, 88(1 Pt 2): 366-374.
- [20] Paiva, L.A.F., Rao, V.S.N., Gramosa, N.V., Silveira, F.R. Gastroprotective effect of Copaifera langsdorffii oleo-resin on experimental gastric ulcer models in rats. *Journal of ethnopharmacology*, 1998, 62(1): 73-78.
- [21] Kauffman, G. L., Grossman, M. I. Prostaglandin and cimetidine inhibit the formation of ulcers produced by parenteral salicylates. *Gastroenterology*, 1978, 75(6): 1099-2102.
- [22] Njar V. C. O., Adesanwo J. K., Raji Y. Methyl Angolenate: The Antiulcer Agent from the Stem Bark of Entandrophragma angolense. *Planta medica*, 1995, 61: 91-92.
- [23] Piper, D.W. and Stiel, D. (1986). Pathogenesis of chronic peptic ulcer, current thinking and clinical implications. *Med Prog*, 2: 7-10.
- [24] Baron, T.H., Langman, M.T.S. and Wastell, C. Stomach and duodenum. Recent advances in gastroenterology. Churchill Livingstone, Edinburgh, 1980, p. 23-86.
- [25] Szabo, S., Kusstatscher, S., Sakoulas, G., Sandor, Z., Vincze, A. & Jadus, M. Growth factors: new 'endogenous drugs' for ulcer healing. *Scandinavian Journal of Gastroenterology*, 1995, 30: p. 15-18.
- [26] Marhuenda, E., Martin, M.J. and Alarcon de la Lastra, C. Antitumorogenic activity of aescine in different experimental models. *Phytotherapy Research*, 2006, 7(1): 13-16.
- [27] Mutoh, H., Hiraishi, H., Ota, S., Ivey, K.J. Terano, A. Sugimoto, T. Role of oxygen radicals in ethanol-induced damage to cultured gastric mucosal cells. *American Journal of Physiology- Gastrointestinal and Liver Physiology*, 1990, 258(4): G603-G609.
- [28] Trivedi, N.P., Rawal, U.M. Hepatoprotective and antioxidant property of Andrographis paniculata (Nees) in BHC induced liver damage in mice. *Indian Journal of Experimental Biology*, 2001, 39(1): 41-46.
- [29] Ligumsky, M., Sestieri, M., Okon, F., Ginsburg, I. Antioxidants inhibit ethanol-induced gastric injury in the rat: role of manganese, glycine, and carotene. *Scandinavian Journal of Gastroenterology*, 1995, 30(9): 854-860.
- [30] Kobayashi, T., Ohta, Y., Yoshino, J., Nakazawa, S. Teprenone promotes the healing of acetic acid-induced chronic gastric ulcers in rats by inhibiting neutrophil infiltration and lipid peroxidation in ulcerated gastric tissues. *Pharmacological Research*, 2001, 43(1): 23-30.
- [31] Shimizu, N., Watanabe T, Arakawa T, Fujiwara Y, Higuchi K, Kuroki T. Pentoxifylline accelerates gastric ulcer healing in rats: roles of tumor necrosis factor alpha and neutrophils during the early phase of ulcer healing. *Digestion*, 2000, 61(3): 157-164.
- [32] Cheng CL, Koo MWL. Effects of Centella asiatica on ethanol induced gastric mucosal lesions in rats. *Life sciences*, 2000, 67(21): 2647-2653.
- [33] Fujita, H, Takahashi, S., Okabe, S. Mechanism by which indomethacin delays the healing of acetic acid-induced ulcers in rats. Role of neutrophil antichemotactic and chemotactic activities. *Journal of physiology and pharmacology: an official journal of the Polish Physiological Society*, 1998, 49(1): 71-82.
- [34] Suzuki, Y., Ishihara M, Ito M. Anti-ulcer effects of antioxidants, quercetin, -tocopherol, nifedipine and tetracycline in rats. *The Japanese Journal of Pharmacology*, 1998, 78(4): p. 435-441.
- [35] Zimmerman, J.J. Ciesielski, W., Lewandoski, J. Neutrophil-mediated phospholipid peroxidation assessed by gas chromatography-mass spectroscopy. *American Journal of Physiology- Cell Physiology*, 1997, 273(2): C653-661.
- [36] Garrick, T., Buack, S., Bass, P. Gastric motility is a major factor in cold restraint-induced lesion formation in rats. *American Journal of Physiology- Gastrointestinal and Liver Physiology*, 1986, 250(2):191-199.
- [37] Takeuchi, K., Nishiwaki, K., Okabe, S. Effects of dopamine on gastric mucosal lesions induced by ethanol in rats. *Digestive Diseases and Sciences*, 1988, 33(12): 1560-1568.
- [38] Takeuch, K. and Nobuhara, Y. Inhibition of gastric motor activity by 16, 16-dimethyl prostaglandin E 2. *Digestive Diseases and Sciences*, 1985, 30(12): 1181-1188.
- [39] Mersereau, A.W. and Hinchey, E.J. Role of gastric mucosal folds in formation of focal ulcers in the rat. *Surgery*, 1982, 91(2):150-155.