

# The Biomechanical Properties of the Different Modalities of Surgically Corrected Coarctation of the Aorta in Neonates and Infants

Elina Ligere, Valts Ozolins, Lauris Smits, Normunds Sikora, Ivars Melderis, Laila Feldmane, Aris Lacis, Vladimir Kasyanov

**Abstract**—Biomechanical properties of infantile aorta *in vitro* in cases of different standard anastomoses: *end-to-end* (ETE), *extended anastomosis end-to-end* (EETE) and *subclavian flap aortoplasty* (SFA) used for surgical correction of coarctation were analyzed to detect the influence of the method on the biomechanics of infantile aorta and possible changes in haemodynamics. 10 specimens of native aorta, 3 specimens with ETE, 4 EETE and 3 SFA were investigated. The experiments showed a non-linear relationship between stress and strain in the infantile aorta, the modulus of elasticity of the aortic wall increased with the increase of inner pressure. In the case of anastomosis *end-to-end* the modulus was almost constant, relevant to the modulus of elasticity of the aorta with the inner pressure 100-120 mmHg. The anastomoses EETE and SFA showed elastic properties closer to native aorta, the stiffness of ETE did not change with the changes in inner pressure.

**Keywords**—biomechanics, coarctation, mechanical properties, neonatal aorta

## I. INTRODUCTION

THE incidence of congenital heart diseases (CHD) is 8-12 per 1000 live born infants and approximately one quarter of these children are affected by critical CHD which requires surgical or catheter intervention within the first year of life [1]. Aortic coarctation (narrowing of the descending aorta usually just distal to the origin of the left subclavian artery) accounts for 6-10% of CHD with the prevalence approximately 36 (29-49)/100 000 newborn infants [2], [3]. The data from literature confirm surgical treatment to be the gold standard for the treatment of the coarctation in neonates and small infants due to less complications and lower incidence of recoarctation in comparison to balloon angioplasty in this particular age group.

The method of choice for the surgical treatment varies between different centers and surgeons with extended anastomosis end-to-end (EETE) mostly preferred [7]-[11].

Elina Ligere is a Doctoral Researcher with Riga Stradins University, Latvia (phone: +371 29507146, e-mail: eteivane@inbox.lv)

Valts Ozolins ( e-mail: dr\_ozolins@inbox.lv), Lauris Smits ( e-mail: smits@bkus.lv ), Normunds Sikora (e-mail: normundssikora@inbox.lv), Aris Lacis ( e-mail: aris.lacis@apollo.lv) are with University Hospital for Children, Clinic for Pediatric Cardiology and Cardiac Surgery, Vienibas Street 45

Vladimirs Kasyanovs is with the Biomechanical Laboratory of Riga Stradins University, Riga, Latvia (e-mail: kasyanov@latnet.lv).

Ivars Melderis is with University Hospital for Children, Department of Pathology, Vienibas Street 45, Riga, LATVIA (e-mail: ivars.melderis@bkus.lv).

Laila Feldmane is with The Institute of Pathology, Pauls Stradins Clinical University Hospital, Riga, Latvia (e-mail: feldmane@stradini.lv)

Subclavian flap aortoplasty is also used [12]-[14] in the cases of infantile coarctation with *isthmus* hypoplasia and/or hypoplasia of the transverse arch, but anastomosis end-to-end performed in isolated coarctations in older infants[15], [16]. Such complications as recoarctation and secondary arterial hypertension frequently occur even after successful surgical repair probably related to the loss of the arterial elasticity. There are still discussions according the choice of treatment [17].

## II. AIM OF THE STUDY

To investigate the biomechanical properties of the aorta in neonates and infants and to compare the biomechanical properties of the aorta in case of different techniques of anastomoses.

## III. MATERIALS AND METHODS

The study was approved by ethics committee of The University Hospital for Children.

### A. Material preparation

During the period of time from April 2009 till December 2011, 20 specimens (40 mm in length) of the upper part of the descending aorta during autopsies of neonates and infants (patients without the diagnosis of coarctation) were acquired. The age of the patients was 1 day to 5 months (mean age 31.94 ± 49.29 days, mean weight 3.86 ± 1.252 kg, minimum weight 2kg and maximum weight 6.7 kg). The vessels were marked before resetting to identify the *in situ* axial length. The anastomoses were made by the cardiac surgeon performing the kind of operations in the clinic using suture techniques identical to operation *in vivo* with uninterrupted sutures with Prolen 6.0-7.0 in the posterior and several interrupted sutures on the front wall. The specimens were preserved in Custodiol Perfusion Solution (Custodiol® HTK Solution for perfusion and flushing donor organs) not longer than 24 hours at temperature 2-4° C.

### B. Experimental Procedure

A special experimental set up with video camera connected to the laptop was used to measure the internal pressure, axial force, longitudinal and circumferential deformation of the aorta as in Fig. 1.

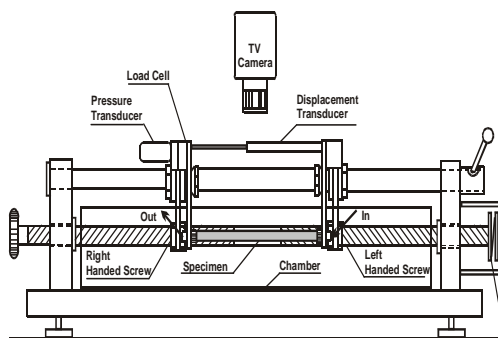


Fig. 1 The common view of the experimental set-up: camera, computer, pressure transducer, specimen (aorta)

An aortic sample was gradually loaded by internal pressure from 0 to 220 mmHg while maintaining the length of the sample constant at  $L_0$ , the length *in situ*. The pressure was elevated in 20 mmHg steps with pressure held constant in each step for 1 minute. The initial external diameter at inner pressure  $p = 0$  mmHg and at *in situ* axial length  $L_0$  was noted as  $D_0$ . The diameter  $D$  was recorded at each pressure level. The value of the wall thickness  $h$  was calculated as follows:

$$h = h_0 \times \lambda_3, \tag{1}$$

$$\text{where } \lambda_3 = 1/(\lambda_1 \lambda_2), \tag{2}$$

$$\lambda_2 = (D/D_0), \tag{3}$$

The circumferential stress was calculated as:

$$\sigma = (pR) / h, \tag{4}$$

where  $p$  - inner pressure,  $R$  - radius.

$$\lambda_1 = (L/L_0) = 1.0 \tag{5}$$

In these equations,  $h_0$  is the initial thickness of the specimen wall and  $\lambda_1$ ,  $\lambda_2$  and  $\lambda_3$  are, respectively, the stretch ratios in the axial, circumferential, and radial directions. Because the length of the artery was maintained constant at  $L_0$ , the value of  $\lambda_1 (= L/L_0)$  was one. The initial wall thickness  $h_0$  was measured with a cathetometer with  $\pm 0.001$  mm accuracy. The artery was preconditioned before tests by subjecting it to cyclic loading to bring it to a stable state to give more reproducible mechanical response. During this process, the vessel was pressurized from 0 to 220 mmHg in 20 steps five times with pressure held constant for 1 minute at each step. The initial curves were markedly hysteric, but the third or fourth cycle gave reproducible curves with minimal hysteresis. A modulus of elasticity  $E$  was calculated as incremental modulus between two values of internal pressure as in Fig.2.

The histological examination (light microscopy) of the aortic wall was performed before and following the experiments.

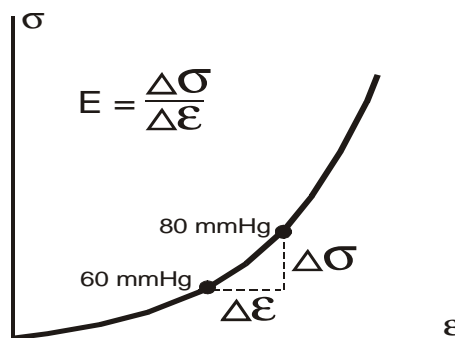


Fig. 2 The calculation of the incremental modulus of elasticity- schematic picture

IV. RESULTS

Our data show non-linear relationship between stress and strain in neonatal and infantile aorta. The wall thickness of the samples was  $1.1 \pm 0.0934$  mm (minimum 0.91 mm, maximum 1.26 mm, median 1.125 mm, mode 1.06 mm). The strain of the aorta at inner pressure 60 was  $25.12 \pm 9.37\%$ , at 80 mmHg was  $29.37 \pm 11.62\%$ , but at 100 mmHg was  $32.62 \pm 13.37\%$  (Table I).

TABLE I  
THE STRAIN IN THE WALL OF NATIVE AORTA, ETE, EETE AND SFA ANASTOMOSES AT DIFFERENT LEVELS OF THE INNER PRESSURE

	$\epsilon$ (%)	$\epsilon$ (%)	$\epsilon$ (%)	$\epsilon$ (%)
	60 mmHg	80 mmHg	100 mmHg	120 mmHg
Native aorta	25.12	29.37	32.62	34.93
	$\pm 9.37$	$\pm 11.62$	$\pm 13.37$	$\pm 14.43$
SFA	26.41	28.87	30.62	31.91
	$\pm 67.25$	$\pm 6.29$	$\pm 6.26$	$\pm 6.2$
EETE	10.01	12.25	14.06	15.77
	$\pm 1.59$	$\pm 1.73$	$\pm 2.05$	$\pm 2.38$
ETE	4.83	6.33	7.63	8.9
	$\pm 1.22$	$\pm 1.29$	$\pm 1.22$	$\pm 1.40$

Maximum strain at inner pressure 220 mmHg was  $47.65 \pm 15.41\%$ . The stress of the native aorta at inner pressure 60 mmHg was  $45.32 \pm 15.29$  kPa, at 80 mmHg it was  $65.36 \pm 24.2$  kPa, at 100 mmHg it was  $86.31 \pm 33.54$  kPa (Table II). At inner pressure 220 mmHg the stress was  $253.41 \pm 95.94$  kPa. In cases with anastomosis *end-to-end* (ETE) the relationship between stress and strain was practically linear (Fig. 3). The strain in ETE decreased and at 60 mmHg it was  $4.83 \pm 1.22\%$ , at 80 mmHg was  $6.33 \pm 1.29\%$  and at 100 mmHg was  $7.63 \pm 1.22\%$ . Maximum strain at the suture sight at the inner pressure 220 mmHg reached only  $15.78 \pm 3.09\%$ . Comparing the strain of native aorta with anastomoses, we came to conclusion that the strain of the anastomosis ETE was much smaller but at the inner pressure 220 mmHg it was twice smaller than in the native aorta.

TABLE II  
THE STRESS IN THE WALL OF NATIVE AORTA, ETE, EETE AND SFA ANASTOMOSES AT DIFFERENT LEVELS OF THE INNER PRESSURE

	$\sigma$ (kPa)	$\sigma$ (kPa)	$\sigma$ (kPa)	$\sigma$ (kPa)
	60 mmHg	80 mmHg	100 mmHg	120 mmHg
Native aorta	45.32	65.36	86.31	108.04
	$\pm 15.29$	$\pm 24.2$	$\pm 33.54$	$\pm 42.72$
SFA	35.99	51.10	65.09	78.35
	$\pm 7.58$	$\pm 1.79$	$\pm 2.91$	$\pm 6.81$
EETE	39.32	54.44	70.11	86.66
	$\pm 3.49$	$\pm 4.74$	$\pm 6.28$	$\pm 7.93$
ETE	36.15	49.52	63.41	78.35
	$\pm 2.85$	$\pm 4.01$	$\pm 7.28$	$\pm 6.81$

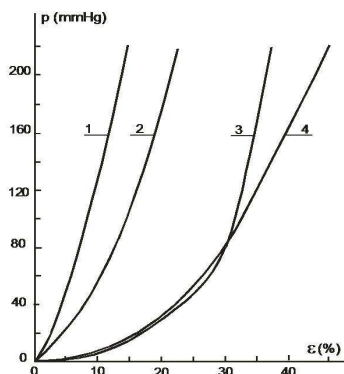


Fig. 3 The relationship between the pressure and strain; 1- anastomosis *end-to-end* (ETE), 2 – extended anastomosis *end-to-end* (EETE), 3 –subclavian flap aortoplasty (SFA), 4 –native aorta

In the cases of subclavian flap aortoplasty the strain at inner pressure 60 mmHg was  $26.41 \pm 6.75$  %, at 80 mmHg was  $28.87 \pm 6.29$  %, but at 100 mmHg was  $30.62 \pm 6.26$  %. Maximum strain at inner pressure 220 mmHg reached  $37.73 \pm 7.86$  %, which is the closest to the strain of the native aorta. In the cases of EETE the strain at inner pressure 60 mmHg was  $10.01 \pm 1.59$  %, at 80 mmHg was  $12.25 \pm 1.73$  %, and at 100 mmHg was  $14.06 \pm 2.05$  %. Maximum strain at inner pressure 220 mmHg was  $22.57 \pm 2.85$  %, which exceeds the strain in the cases of ETE twice, but drops back in comparison with SFA and native aorta.

The modulus of elasticity (Table III) of the wall of native aorta increases with the increase of the inner pressure. At the inner pressure 60-80 mmHg modulus of elasticity was  $516.08 \pm 126.21$  kPa, but at 100-120 mmHg it increased up to  $967.45 \pm 164.60$  kPa ( more than twice).

In the ETE the modulus of elasticity was almost constant and at the pressure 60-80 mmHg it was  $1138.16 \pm 216.23$  kPa, but at the pressure 100-120 mmHg the modulus of elasticity was  $1261.35 \pm 235.76$  kPa. The modulus of elasticity at the pressure 60-80 mmHg was closer to the modulus of elasticity of the native aorta at the inner pressure 100-120 mmHg.

The results showed that in the cases of ETE stiffness practically does not change with the changes of inner pressure that might affect haemodynamics. In the cases of EETE

modulus of elasticity at inner pressure 60-80 mmHg was  $683.29 \pm 65.87$  kPa, but at 100-120 mmHg  $1232.79 \pm 586.79$  kPa. In the cases of SFA modulus of elasticity at the inner pressure 60-80 mmHg was  $615.95 \pm 50.88$  kPa, but at the pressure 100-120 mmHg was  $1158.35 \pm 127.52$  kPa, which is closer to the modulus of elasticity of the native vessel.

TABLE III  
THE MODULUS OF ELASTICITY OF THE WALL OF NATIVE AORTA, ETE, EETE AND SFA ANASTOMOSES AT DIFFERENT LEVELS OF THE INNER PRESSURE

	E (kPa)	E (kPa)	E (kPa)
	60-80mmHg	80-100mmHg	100-120mmHg
Native aorta	516.08	704.02	967.45
	$\pm 126.21$	$\pm 170.67$	$\pm 164.60$
SFA	615.95	798.46	1158.35
	$\pm 50.88$	$\pm 25.26$	$\pm 127.52$
EETE	683.29	932.63	1232.79
	$\pm 65.87$	$\pm 257.18$	$\pm 586.79$
ETE	902.39	1138.16	1261.35
	$\pm 86.49$	$\pm 216.23$	$\pm 235.76$

The light microscopy after hematoxylin-eosin staining of the aortic wall following the pressurizing up to 220 mmHg in the experimental stand showed oedema, dislocation and disorientation of the elastic fibres.

## V. DISCUSSION

Despite successful surgical correction and/or balloon angioplasty of the aortic coarctation complications such as development of hypertension and recoarctation are common. Aorta becomes enclosed in a scar tissue and elastic properties of the aortic wall in these segments are not preserved. Besides that this may be also related to further extension of the ductal tissue into the aortic wall and the loss of natural aortic elasticity which are responsible for blood pressure abnormalities [17]-[19]. Arterial stiffness persists despite satisfactory correction of the coarctation and it is shown to be the risk factor of such cardio-vascular events as primary coronary events, stroke and mortality. Clinical trials have shown that even normotensive patients after coarctation repair have markedly increased left ventricle mass as a sequel of increased aortic stiffness and pulse wave velocities, decreased central aortic dispensability and compliance [20], [21]. Our data show significant difference between the biomechanical properties of the native aorta and different anastomoses used for the surgical correction of coarctation with the strain of the surgically corrected aorta much smaller. The modulus of elasticity of the native aorta increases with the increase of the inner pressure but this increase is most limited in the cases of ETE anastomosis. The data are acquired from *in vitro* study, so the limitation is the difference between experimental results and real patients. We compared these data to the clinical outcomes of the patients operated due to coarctation in The Clinic for Pediatric Cardiology and Cardiac Surgery of University Hospital for Children Riga, Latvia within the first year of life in the period of time from January 1, 2000 to

December 31, 2010 and followed-up to December 31, 2011 (n=60, follow-up period 18-112 months) [22]. Our experimental data showed the biomechanical properties of SFA the closest to the native aorta. These clinical data are consistent with the outcomes of these experimental results and showed the relieve of the maximum pressure gradient in descending aorta detected by echocardiography early post operation in ETE 25.53 $\pm$ 9.4 mmHg(95% CI 11-37), EETE 17.64 $\pm$ 4.5 mmHg(95% CI 13-22) and SFA 15.95 $\pm$ 6.6 mmHg (95% CI 6-34). Long term follow-up data showed no statistically significant recoarctation rate differences between the groups of different techniques: 18% in ETE group, 26% in SFA and 25% in EETE group (p>0.05). The priority of SFA might be less tension on the suture lines, no circular scars and the use of autologous tissue with the growth potential but the drawback is the need to scarify the left subclavian artery, therefore most centres prefer EETE in cases of infantile coarctation with *isthmus* and sometimes transverse aortic arch hypoplasia [5], [7]-[9]. The choice of a surgical approach is usually made by the surgeon on the basis of individual abnormalities in the shape of the arch. In the age group included in our study physiological blood pressure limits up to 90<sup>th</sup> percentile according to the age specific percentile table are up to 74/50 mmHg in infants 1-3 days old, 89/58 mmHg at the age 2-3 weeks, but 106/71 mmHg at the age 1-5 months [23]. The differences between the biomechanical properties of the native aorta and the aorta following surgical correction were less prominent within the range of physiological arterial pressure for the age and more obvious with the increase of inner pressure above the physiological limits. That is consistent with the findings of elevated arterial pressure during physical activities in otherwise normotensive patients following successful coarctation repair.

## VI. CONCLUSION

The results of the experiments showed that neonatal and infantile aorta has significant strain of the wall which provide physiologic hemodynamics. Even successful surgical correction means a significant loss of elastic properties and the increasing of stiffness of the arterial wall which is less evident within the range of physiological pressures for the age. The anastomoses EETE and SFA showed elastic properties closer to native aorta in comparison with ETE.

## REFERENCES

- [1] G. J. I. E. Hofman and S. Kaplan, "The incidence of congenital heart disease," *J Am Coll Cardiol*, vol. 39, pp. 1890-1900, 2002.
- [2] A. Lindinger, G. Schwedler and H.W. Hense, "Results of PAN Study: Congenital heart defects in newborns in Germany-prevalence and association with demographic, genetic and peripartal parameters," *Cardiol Young*, vol. 20 (SuppS2), pp. S3, 2010.
- [3] "European surveillance of congenital anomalies," [www.eurocat-network.eu/prevdata/results](http://www.eurocat-network.eu/prevdata/results) (accessed 10.03.2012.).
- [4] S. Fruh, W. Knorsh, A. Dodge-Khatami, H. Dave, R. Petre and O. Kretschmar, "Comparison of surgical and interventional therapy of native and recurrent aortic coarctation regarding different age groups during childhood," *Eur J Cardiothorac Surg*, vol. 39, pp. 989-904, 2011.
- [5] A. Peres, J. D. Martins, F. Parames, R. Gil, C. Matias, J. Franco, I. Freitas, C. Trigo, J. Fragata and F. F. Pinto, "Isolated coarctation : experience in 100 consecutive patients," *Rev Port Cardiol*, vol. 29(1), pp. 23-35, 2010.
- [6] R. J. Walhout, J. C. Lekkerkerker, G.H. Oron, G.B. Bennink and E. J. Meijboom, "Compariso of surgical repair with balloon angioplasty for native coarctation in patients from 3 months to 16 years of age ," *Eur J Cardiothorac Surg*, vol. 25, pp. 722-727, 2004.
- [7] R. H. Beekman, "Coarctation of the aorta , Moss and Adams, Heart Disease in Infants, Children and Adolescents Including the Fetus and Young Adult," Hugh Allen, Lippincott Williams& Wilkins, Seventh edition, vol. 49, pp. 987-1005, 2008.
- [8] E. Rosenthal, "Coarctation of the aorta from fetus to adult: curable condition or life long disease process?" *Heart*; vol. 91(11), pp.1495-1502, 2005.
- [9] R.A. Jonas, "Coarctation of the aorta, Comprehensive Surgical management of Congenital Heart Disease," Hodder Arnold Publication, pp. 207-223, 2004.
- [10] A. E. Wood, H. Javadpour, D. Duff, P. Oslizlok and K. Walsh, " Is extended arch aortoplasty the operation of choice for infant aortic coarctation? Results of 15 years` experience in 181 patients," *Ann Thorac Surg*, vol. 77, pp. 1353-1358, 2004.
- [11] J. D. R. Thomson, A. Mulpur, R. Guerrero, Z. Nagy, J. L. Gibbs and K. G. Watterson, "Outcome after extended arch repair for aortic coarctation," *Heart*, vol. 92, pp. 90-94, 2006.
- [12] C. J. Barreiro, T. A. Ellison, J. A. Williams, M. L. Durr, D. E. Cameron and L. A. Vricella, "Subclavian flap aortoplasty: still a safe, reproducible and effective treatment for infant coarctation," *Eur J Cardiothorac Surg*, vol. 31(4), pp. 649-53, 2007.
- [13] A. Cobanoglu, K. Ganeeshakrishnan, K. Thyagarajan and J. L. Dobbs, "Surgery for coarctation of the aorta in infants younger than 3 months: end-to-end repair versus subclavian flap angioplasty: is either operation better?" *Eur J Cardiothorac Surg*, vol.14, pp. 19-26, 1998.
- [14] B. Korbmacher, O. N. Krogmann, S. Rammos, E. Godehardt, T. Volk, D. Schulte and E. Gams, "Repair of critical aortic coarctation in neonatal age," *J Cardiovasc Surg*, vol. 43, pp. 1-6, 2002.
- [15] J. W. Brown, M. Ruzmetov, M. H. Hoyer, M. D. Rodefeld and M. W. Turrentine, "Recurrent Coarctation: Is Surgical Repair of Recurrent Coarctation Safe and Effective?" *Ann Thorac Surg*, vol. 88, pp. 1923-1932, 2009.
- [16] F. Burch, C. G. Cowley, R. Holubkov, D. Null, L. Lambert, P. C. Kouretas and J. A. Hawkins, "Coarctation repair in neonates and young infants: is small size or low weight a risk factor?" *J Thorac Cardiovasc Surg*, vol. 138, pp. 547-552, 2009.
- [17] P. P. Bassereo, A. R. Marras, M. E. Manai and G. Mercurio, "The influence of different surgical approaches on arterial rigidity in children after aortic coarctation repair," *Pediatr Cardiol*, vol. 30(4), pp. 414-418, 2009.
- [18] U. Giordano, S. Giannico, A. Turchetta, F. Hammand, F. Calzolari and A. Calzolari, "The influence of different surgical procedures on hypertension after repair of coarctation," *Cardiol Young*, vol. 15, pp. 477-480, 2005.
- [19] P. Guerin, M. Jimenez, M. Vallot, J. B. Thambo and P. Goose, "Arterial rigidity of patients operated successfully for coarctation of the aorta without residual hypertension," *Arch Mal Coeur Vaiss*, vol. 98, pp. 557-560, 2005.
- [20] P. Ou, D. Celermajer, O. Jolivet, F. Buyens, A. Herment, D. Sidi, D. Bonne and E. Mousseaux, "Increased central aortic stiffness and left ventricle mass in normotensive young subjects after successful coarctation repair," *Am Heart J*, vol. 155(1), pp. 187-193, 2008.
- [21] P. Ou, D. Bonnet and L. Auriacombe, "Late systemic hypertension and aortic arch geometry after successful repair of coarctation of the aorta," *Eur Heart J*, vol. 25, pp. 1853-1859, 2004.
- [22] E. Ligere, A. Laxis, L. Smits, V. Ozolins, N. Sikora, I. Bergmane, I. Lubau, I. Lace and L. Feldmane, "Aortic coarctation repaired within the first year of life: an 11 year review," *Acta Chirurgica Latviensis*, vol. 11/2, pp. 98-103, 2011.
- [23] K. M. Park and G. Troxler, "Pediatric Cardiology for Practitioners," Mosby, 4th Edition, pp. 105-590, 2008.