

# Morphology and Risk Factors for Blunt Aortic Trauma in Car Accidents - An Autopsy Study

Ticijana Prijon, Branko Ermenc

**Abstract—Background:** Blunt aortic trauma (BAT) includes various morphological changes that occur during deceleration, acceleration and/or body compression in traffic accidents. The various forms of BAT, from limited laceration of the intima to complete transection of the aorta, depends on the force acting on the vessel wall and the tolerance of the aorta to injury. The force depends on the change in velocity, the dynamics of the accident and of the seating position in the car. Tolerance to aortic injury depends on the anatomy, histological structure and pathomorphological alterations due to aging or disease of the aortic wall.

An overview of the literature and medical documentation reveals that different terms are used to describe certain forms of BAT, which can lead to misinterpretation of findings or diagnoses. We therefore, propose a classification that would enable uniform systematic screening of all forms of BAT. We have classified BAT into three morphological types: TYPE I (intramural), TYPE II (transmural) and TYPE III (multiple) aortic ruptures with appropriate subtypes.

**Methods:** All car accident casualties examined at the Institute of Forensic Medicine from 2001 to 2009 were included in this retrospective study. Autopsy reports were used to determine the occurrence of each morphological type of BAT in deceased drivers, front seat passengers and other passengers in cars and to define the morphology of BAT in relation to the accident dynamics and the age of the fatalities.

**Results:** A total of 391 fatalities in car accidents were included in the study. TYPE I, TYPE II and TYPE III BAT were observed in 10,9%, 55,6% and 33,5%, respectively. The incidence of BAT in drivers, front seat and other passengers was 36,7%, 43,1% and 28,6%, respectively. In frontal collisions, the incidence of BAT was 32,7%, in lateral collisions 54,2%, and in other traffic accidents 29,3%. The average age of fatalities with BAT was 42,8 years and of those without BAT 39,1 years.

**Conclusion:** Identification and early recognition of the risk factors of BAT following a traffic accident is crucial for successful treatment of patients with BAT. Front seat passengers over 50 years of age who have been injured in a lateral collision are the most at risk of BAT.

**Keywords—**Aorta, blunt trauma, car accidents, morphology, risk factors.

## I. INTRODUCTION

**B**LUNT AORTIC TRAUMA (BAT) includes various morphological changes that occur during sudden deceleration, acceleration and/or body compression in traffic accidents [1],[2].

The basic pathological mechanism is the injury to the aortic wall due to the force acting from the inside towards the

outside, from the tunica intima towards the tunica adventitia [3]-[5]. As a result there are several morphological forms of BAT, ranging from limited lacerations of the tunica intima to full transection of the aorta [6]-[8].

Examining the literature and medical documentation we found a variety of terms for describing a specific morphological entity (tear, laceration, dissection, rupture, pseudoaneurysm, transection), and vice versa a single term for different forms of BAT, which might lead to incorrect interpretation or misinterpretation [9], [10]. The inconsistent use of terminology to describe BAT has given rise to the need to introduce a new classification that would define BAT more precisely and enable a systematic overview of all the morphological types of BAT. We have thus classified BAT into three morphological types, with appropriate subtypes: TYPE I -intramural, TYPE II -transmural (Fig. 2) and TYPE III -multiple aortic ruptures [11]-[13].

The morphology of BAT following traffic accidents is defined by two basic factors: the force acting on the vessel wall and the tolerance of the aorta to injury. The amount of traumatic force depends on the change in the velocity of the vehicle and on the dynamics of the accident (frontal collision, lateral collision, overturning, or falling out of a vehicle) and of the seating position in the car (driver, front seat passenger, or another passenger). The tolerance to injury of the aorta depends on the anatomy, histological structure and pathomorphological changes due to aging or disease of the aortic wall.

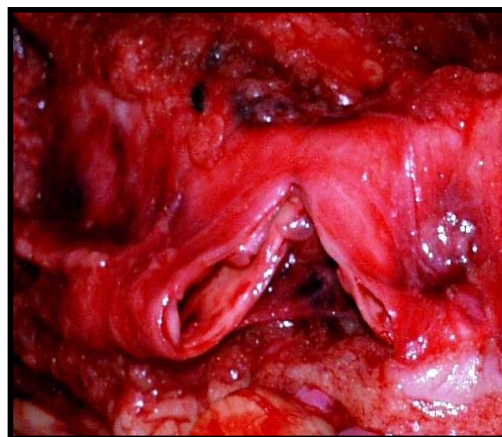


Fig. 1 TYPE II – Transmural blunt aortic trauma (BAT)

Ticijana Prijon MD, Health Insurance Institute of Slovenia, Mala ulica 3, 1000 Ljubljana, Slovenia (e-mail: ticijana.prijon@gmail.com).

Prof Branko Ermenc PHD, Institute of Forensic Medicine, Medical Faculty University of Ljubljana, Korytkova 2, 1000 Ljubljana, Slovenia (e-mail: branko.ermenc@mf.uni-lj.si).

II. MATERIALS AND METHODS

This retrospective autopsy study included all car accident fatalities, with and without aortic trauma, who were examined at the Institute of Forensic Medicine, Medical Faculty, University of Ljubljana from 2001 to 2009. The deceased with aortic injuries were determined on the basis of medical documentation (clinical and autopsy reports, expert forensic opinions) and police documentation (records of the scene of the accident investigations, photographic material, traffic expert opinions). The form, extent and number of BAT were determined and sorted according to the proposed classification into intramural (TYPE I), transmural (TYPE II) and multiple (TYPE III) aortic ruptures. The incidence of different types of BAT was determined according to the seating position of the participant of the car accident (driver, front seat passenger, or another passenger) and according to the dynamics of the accident (frontal collision, lateral collision or other forms of car accidents). The effect of the age of the injured person on the incidence and morphology of BAT was established.

All collected data was statistically analysed and evaluated according to the variables described above.

III. RESULTS

A total of 391 people with fatal injuries were included in the study: 240 drivers, 102 front seat passengers and 49 other car passengers, of whom 286 were male and 105 female.

Intramural aortic ruptures (TYPE I) were determined in 16 cases (10,9%), transmural aortic ruptures (TYPE II) in 81 cases (55,6%) and multiple aortic ruptures (TYPE III) in 49 cases (33,5%).

The incidence of BAT among drivers, front seat passengers and other passengers was 36,7% (88 cases), 43,1% (44 cases) and 28,6% (14 cases), respectively. The incidence of the different morphological types of BAT in individual fatalities is shown in Table I.

TABLE I  
NUMBERS OF THE DIFFERENT MORPHOLOGICAL TYPES OF BAT IN DECEASED CAR DRIVERS, FRONT SEAT PASSENGERS AND OTHER PASSENGERS

Participant	TYPE I	TYPE II	TYPE III	TOTAL
Driver	9	46	33	88
Front seat passenger	6	26	12	44
Other passenger	1	9	4	14
TOTAL	16	81	49	146

We examined 220 fatalities in frontal collisions, 96 fatalities in lateral collisions and 75 fatalities in other forms of car accidents. The incidence of BAT in frontal collisions was 32,7% (72 cases), in lateral collisions or side vehicle impacts the incidence was 54,2% (52 cases) and in other traffic accidents, such as cases in which the car rolled over or the passenger was thrown out of the vehicle, the incidence was 29,3% (22 cases). The incidence of various types of BAT in relation to the dynamics of the traffic accident is shown in Table II.

TABLE II  
THE NUMBER OF VARIOUS MORPHOLOGICAL TYPES OF BAT IN RELATION TO THE DYNAMICS OF THE TRAFFIC ACCIDENT

	TYPE I	TYPE II	TYPE III	TOTAL
Frontal	8	42	22	72
Lateral	8	24	20	52
Other	0	15	7	22
TOTAL	16	81	49	146

The average age of fatalities in car accidents without BAT was 39.1 years (1 to 96 years) and of those with BAT 42.8 years (16 to 89 years). Among fatalities without aortic injury 24% were over 50, and among those with aortic injury as many as 39% were over 50. With age not only the incidence but also the severity of BAT increases. A total of 57% of all fatalities with multiple BAT were older than 50, but only 25% of fatalities with intramural BAT were in this age group (Fig. 2).

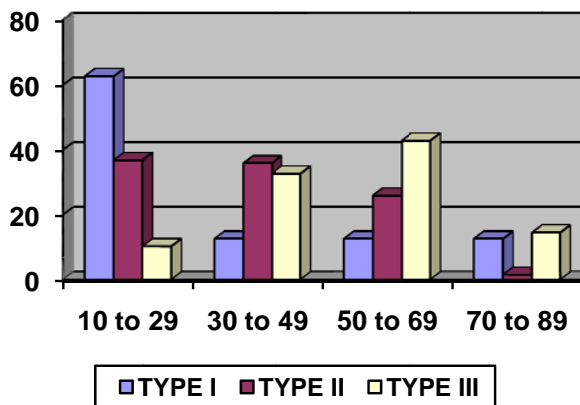


Fig. 2 The percentage of intramural (Type I), transmural (Type II) and multiple (Type III) BAT in relation to the age of fatalities

IV. DISCUSSION

The pathogenesis of BAT is the result of several mechanical and anatomical factors [1]. Etiologically, a rupture of the aortic wall is caused by a combination of tensile, shear, torsion and hydraulic forces in sudden deceleration, acceleration and/or compression of the chest [2], [3]. More than 90% of all BAT occurs in traffic accidents, with 70% of these in car accidents [4], [14]-[16].

The basic pathological mechanism is the injury to the aortic wall due to the force acting from the inside towards the outside, from the tunica intima towards the tunica adventitia. The primary injury is the rupture of the endothelium, which then spreads to other layers of the vessel wall [5]-[9].

BAT may be classified into incomplete ruptures of the vessel wall (intramural), in which the rupture only reaches a certain wall layer, and complete ruptures of the entire cell wall (transmural), in which the aortic wall is torn completely. Partial and total BAT differentiate depending on whether the ruptures extend across only a part of the vessel's circumference or the entire circumference [7]-[10].

We systematically classify BAT into three morphological types with appropriate subtypes: TYPE I (intramural), TYPE II (transmural) and TYPE III (multiple) aortic ruptures [10]-[13].

Intramural ruptures (TYPE I) are incomplete injuries affecting the thickness of the vessel wall. They have been classified into TYPE Ia ruptures (rupture of the intima), TYPE Ib ruptures (rupture of the intima and the inner layer of the media), TYPE Ic ruptures (rupture of the intima and the entire media, all the way to the adventitia) and TYPE Id ruptures (intramural haematoma or dissecting pseudoaneurysm).

In transmural ruptures (TYPE II) the entire thickness of the aortic wall is torn. They have been classified into TYPE IIa ruptures (partial transmural), TYPE IIb ruptures (total transmural or transection) and TYPE IIc ruptures (posttraumatic dissecting pseudoaneurysm ruptures). In multiple ruptures (TYPE III) — in addition to the basic intramural or transmural rupture (dominant or primary rupture) — there are two to five additional transverse injuries of the aortic wall (secondary ruptures), running parallel and spaced 5 to 25 mm apart. They have been classified into TYPE IIIa ruptures (multiple intramural), TYPE IIIb ruptures (multiple intramural and transmural) and TYPE IIIc ruptures (multiple transmural). Multiple BAT is usually a result of a simultaneous occurrence of various mechanisms of injury and/or large traumatogenic forces [10]-[13].

Car accident victims who initially survive aortic injury have an incomplete, intramural rupture with haematoma and an intact adventitia, which prevents immediate bleeding [2], [5]-[13].

A dissection can occur at the spot of the intramural ruptures, leading to an intramural haematoma or posttraumatic pseudoaneurysm. Transmural aortic ruptures can subsequently occur at these spots, which cause delayed clinical symptoms [17]-[19]. Transmural aortic ruptures are the cause of extensive haemorrhages into the pericardium, mediastinum, chest, retroperitoneal space or abdominal cavity, and therefore are usually fatal. The rupture of the isthmus and the descendent part of the thoracic aorta leads to the development of haemothorax with indications of haemorrhagic shock, and the rupture of the ascendant part of the aorta is manifested as mediastinalhaematoma, haemopericardium and cardiac tamponade [20]-[23].

The incidence of individual morphological entities of BAT depends on the tolerance of the aorta to injury and the force acting on the vessel wall.

The tolerance of the aorta to injury depends on the anatomy, histological structure and pathomorphological changes due to aging and disease of the aortic wall.

Anatomic predilection sites of BAT are in the area between the relatively mobile and the fixed part of the aorta [3]-[9]. A typical location of BAT is the proximal part of the descending thoracic aorta or the aortic isthmus, i.e. at the point of attachment of the ligamentumarteriosum, followed by the supra-avalvular part of the aorta, which is joined to the connective ring of the semilunar valve and the ascending part of the thoracic aorta proximal to the exit point of the

brachiocephalic artery. BAT is rare in the aortic arch, the distal part of the descending thoracic aorta and the abdominal aorta [21]-[23]. Pathoanatomically, BAT is visible as a transverse injury of the vessel wall with straight and smooth edges, usually located in the anterior wall of the proximal part of the descending thoracic aorta or the posterior wall of the supra-avalvular part of the ascending aorta [24], [25].

The biomechanical properties of the aortic wall depend on the histological structure, particularly on the content of elastin and collagen fibres [26]. It has been established that structures with higher collagen content are more elastic and thus have higher tolerance to injury. The outer aortic layer, the tunica adventitia, provides as much as 60% of the entire elasticity as a result the direction of action of the traumatogenic force from the intima towards the adventitia is affected by the histological structure of the vessel wall. Furthermore, the wall of the thoracic aorta contains more elastin than collagen, whereas the wall of the abdominal aorta contains more collagen than elastin [26], [27]. The thoracic aorta is therefore more susceptible to injury than the abdominal aorta. Individual segments of the thoracic aorta have different collagen and elastin contents, resulting in different elastic properties. The elasticity of the isthmus is only 2/3 of the elasticity of the ascending part and 3/4 of the elasticity of the descending part of the thoracic aorta. Due to its anatomic and histological properties, the isthmus is the most vulnerable site of predilection to blunt aortic trauma [27], [28].

Aging processes lead to a progressive loss of the elastic elements of the media, reducing the thickness of the vessel wall and dilatation of the aorta. The pathohistological changes to the aortic wall in cystic medionecrosis, atherosclerosis, arterial hypertension and diabetes mellitus are caused by degeneration and fragmentation of the elastin lamellae and the loss of smooth muscle cells. Aging and pathological changes reduce the tolerance of the aortic wall to injury and therefore increase the possibility of BAT in traffic accidents [7], [12], [13], [29].

BAT is a high-energy injury, usually occurring at speeds above 100 km/h [30]. Newman and Rastogi [31] determined the change in speed of a vehicle required for rupture of the isthmus to occur ( $56.6 \pm 23$  km/h) and the speed required for injury to the supra-avalvular part of the ascending aorta (53 km/h).

The speed at which aortic injury occurs also depends on the dynamics of the accident. There are three basic forms of car accidents: frontal collisions (60% to 80% of all accidents), lateral or side vehicle impact collisions (10% to 30%) and complex mechanisms, such as rolling over or being thrown out of the vehicle (up to 10% of all accidents) [14], [32]-[34]. In frontal collisions, the speed at which BAT occurs is 84 km/h (54–127 km/h) and in lateral collisions this is 52 km/h (31–105 km/h) [31]. The incidence of BAT in side vehicle impacts is higher, since the required force for injury to the aortic wall to occur is smaller [35]-[37].

We have also found major differences in the incidence and morphology of BAT in various participants in road traffic accidents. The most at risk of BAT are car front seat

passengers and drivers [38].

#### V. CONCLUSIONS

BAT has been classified into three morphological types, with appropriate subtypes:

TYPE I (intramural), TYPE II (transmural) and TYPE III (multiple) aortic ruptures. The new classification allows systematic overview, a better standard of treatment and, above all, better comparison of the individual morphological entities of BAT.

The morphology of BAT following a car accident depends on the change in velocity of the vehicle and the dynamics of the accident, on the seating position of the participant and on the age of the injured. Those most at risk of BAT are front seat passengers over the age of 50, who have been injured in a lateral collision.

Identification and early recognition of the risk factors of BAT following a traffic accident is crucial for the expeditious and improved standard of treatment of patients with BAT. Preventive measures to reduce the effect of risks can significantly reduce the occurrence of BAT in traffic accidents.

#### REFERENCES

- [1] Moar JJ. Traumatic rupture of the thoracic aorta. An autopsy and histopathological study. *S Afr Med J* 1985;6:383-385.
- [2] Ben-Menachem Y, Handel SF. The mechanism of injury. *Angiography in trauma. A work atlas.* London: WB Saunders, 1981.
- [3] Richens D, Field M, Neale M, Oakley C. The mechanism of injury in blunt traumatic rupture of the aorta. *Eur J CardiothoracSurg* 2002;21:288-293.
- [4] Sevitt S. The mechanisms of traumatic rupture of the thoracic aorta. *Br J Surg* 1977;64:166-173.
- [5] Pierangeli A et al. Delayed treatment of isthmic aortic rupture. *Cardiovascular Surgery*, 2000;8:280-283.
- [6] Stemper BD, Yoganandan N, Pintar FA, Brasel KJ. Multiple subfailures characterize blunt aortic injury. *J Trauma* 2007;62:1171-1174.
- [7] Parmly LF, Mattingly TW, Manion WC, Jahnke EJ Jr. Nonpenetrating traumatic injury of the aorta. *Circulation* 1958;17:1086-1101.
- [8] Feczko JD et al. An autopsy case review of 142 nonpenetrating (blunt) injuries of the aorta. *J Trauma* 1990;30:1294-1297.
- [9] Burkhart HM, Gomez GA, Jacobson LE, Pless JE, Broadie TA. Fatal blunt aortic injuries: a review of 242 autopsy cases. *J Trauma* 2001;50:113-115.
- [10] Ermenc B, Prijon T, Hočevar Z. Pathoanatomy and histology of traumatic aortic ruptures- an attempt of classification. In: International meeting on forensic medicine Alpe-Adria-Pannonia. Whiplash injury. Proceedings. Department of Forensic Medicine and Criminology School of Medicine, University of Zagreb. Croatian Medical Association. Opatija, Croatia, 23-26 May, 2001;212-218.
- [11] Prijon T, Ermenc B, Balažić J, Štefanić B, Šerko A, Kralj E. Classification of blunt injuries to the thoracic aorta. *Archive of Oncology* 2002;10:10-11.
- [12] Prijon T, Ermenc B. A systematic interpretation of aortic trauma and a proposed new classification of blunt aortic injuries. In: XXth Congress of International Academy of Legal Medicine, Budapest 23-26 August 2006. Editor Peter Sotony. Free papers proceedings; 87-91.
- [13] Prijon T, Ermenc B. Classification of blunt aortic injuries - a new systematic overview of aortic trauma. *Forensic Sci Int.* 2010;195:6-9.
- [14] Fitzharris M, Franklyn M, Frampton R, Yang K, Morris A, Fildes B. Thoracic aortic injury in motor vehicle crashes: the effect of impact direction, side of body struck, and seat belt use. *J Trauma* 2004;57:582-590.
- [15] Richens D, Kotidis K, Neale M, Oakley C, Fails A. Rupture of the aorta following road traffic accidents in the United Kingdom 1992-1999. The results of the co-operative crash injury study. *Eur J cardiothoracSurg* 2003;23:143-148.
- [16] Viano DC. Biomechanics of non-penetrating aortic trauma: a review. 27th Stapp car crash conference, 1983.
- [17] Steenburg SD, Ravenel JG, Ikonomidis JS, Schönholz C, Reeves S. Acute Traumatic Aortic Injury: Imaging Evaluation and Management. *Radiology* 2008; 248:748-762.
- [18] Nienaber CA, Eagle KA. Aortic dissection; New frontiers in diagnosis and management. Part II: Therapeutic management and follow-up. *Circulation* 2003;108:772-778.
- [19] Nienaber CA, Eagle KA. Aortic dissection; New frontiers in diagnosis and management. Part I: from etiology to diagnostic strategies. *Circulation* 2003;108:628-635.
- [20] Siegal EM. Acute aortic dissection. *J hosp Med* 2006;1:94-105.
- [21] Williams JS, Graff JA, Uku IM, Steinig JP. Aortic injury in vehicular trauma. *Ann ThoracSurg* 1994;57:762-730.
- [22] Chiesa R, Liberato de Moura MR, Lucci C, Castellano R, Civilini E, Melissano G, Tshomba Y. Blunt trauma of the thoracic aorta: mechanisms involved, diagnosis and management. *J Vasc Br* 2003;2 (3):197-210.
- [23] Isselbacher EM. Disease of the aorta. In: Libby P, Bonow RO, Mann DL, Zipes DP, eds. *Braunwald's Heart disease. A textbook of cardiovascular medicine.* 8th ed. Philadelphia: Saunders Elsevier; 2008: 1457-1490.
- [24] Dossios TJ, Salemis N, Angouras D, Nonas E. Blunt and penetrating trauma of the thoracic aorta and aortic arch branches: an autopsy study. *J Trauma.* 2000; 49: 696-703.
- [25] Greendyke RM. Traumatic rupture of aorta; special reference to automobile accidents. *JAMA* 1966;195:527-530.
- [26] Haunt RC. Biomechanics of soft tissues. In: Nahum AM, Melvin JW Editors, *Accidental injury*, Springer-Verlag, New York, 1993:224-246.
- [27] Tanak TT, Fung YC. Elastic and inelastic properties of the canine aorta and their variation along the aortic tree. *J Biomech.* 1974; 7:357-370.
- [28] Gotzen L, Flory PJ, Otte D. Biomechanics of aortic rupture at classical location in traffic accidents. *ThoracCardiovascSurg* 1980;28:64-68.
- [29] McGwin G, Reiff DA, Moran SG, Rue LW. Incidence and characteristics of motor vehicle collision - related blunt thoracic injury according to age.
- [30] Bertrand S, Cuny S, Petit P, Trosseille X, Page P, Guillemot H, et al. Traumatic rupture of thoracic aorta in real-world motor vehicle crashes. *Traffic Injury Prevention.* 2008;9:153-161.
- [31] Newman RJ, Rastogi S. Rupture of the thoracic aorta and its relationship to road traffic accident characteristics. *Injury.* 1984;15:296-299.
- [32] Fabian TC, Richardson JD, Croce MA, et al. prospective study of blunt aortic injury: multicenter trial of the American Association for the Surgery of Trauma. *J Trauma* 1997;42:374-380.
- [33] Strassman G. Traumatic rupture of the aorta. *Am Heart J*, 1947; 33: 508.
- [34] Lundervall J. The mechanism of traumatic rupture of the aorta. *ActaPatholMicrobiolScand* 1964;62:34-46.
- [35] Horton TG, Cohn SM, Heid MP, et al. Identification of trauma patients at risk of thoracic aortic tear by mechanism of injury. *J Trauma* 2000;48:1008-1013.
- [36] Schulman CI, Carvajal D, Lopez PP, Soffer D, Habib F, Augenstein J. Incidence and crash mechanisms of aortic injury during the past decade. *J Trauma* 2007;62:664-667.
- [37] Katyal D, McLellan BA, Brenneman FD, Boulanger BR, Sharkey PW, Waddell JP. Lateral impact motor vehicle collisions: significant cause of blunt traumatic rupture of the thoracic aorta. *J Trauma* 1997;42:769-772.
- [38] Nikolic S, Atanasijević T, Mihalović Z, Babić D, Popović-Lončar T. Mechanism of aortic blunt in fatally injured front-seat passengers in frontal car collisions: an autopsy study. *Am J Forensic Med Pathol* 2006; 27:292-295.