

Bridging Quantitative and Qualitative of Glaucoma Detection

Noor Elaiza Abdul Khalid, Noorhayati Mohamed Noor, Zamalia Mahmud, Saadiah Yahya, and Norharyati Md Ariff

Abstract—Glaucoma diagnosis involves extracting three features of the fundus image; optic cup, optic disc and vernacular. Present manual diagnosis is expensive, tedious and time consuming. A number of researches have been conducted to automate this process. However, the variability between the diagnostic capability of an automated system and ophthalmologist has yet to be established. This paper discusses the efficiency and variability between ophthalmologist opinion and digital technique; threshold. The efficiency and variability measures are based on image quality grading; poor, satisfactory or good. The images are separated into four channels; gray, red, green and blue. A scientific investigation was conducted on three ophthalmologists who graded the images based on the image quality. The images are threshold using multi-thresholding and graded as done by the ophthalmologist. A comparison of grade from the ophthalmologist and threshold is made. The results show there is a small variability between result of ophthalmologists and digital threshold.

Keywords—Digital Fundus Image, Glaucoma Detection, Multi-thresholding, Segmentation.

I. INTRODUCTION

GLAUCOMA is an eye disease that affects middle to elderly adults that elevates intraocular pressure which progresses to damage the optic nerve. This will lead to irreversible blindness which is preventable if discovered at an early stage [3, 4, 22]. Medically glaucoma are detected using machine such as Optical Coherence Tomography (OCT), Heidelberg Retinal¹ Tomography (HRT) and fundus camera. OCT and HRT are very expensive and not readily available in hospitals thus many glaucoma cases go undetected [5]. In the drive to find a cheaper glaucoma screening method, ophthalmologists revert to slit-lamp biomicroscopy [25]. However this method is time-consuming where the patient's pupils need to be fully dilated and a subjective cup to disk area ratio is estimated to quantify the degree of cupping. This measurement remains essentially qualitative and yield inaccurate result where some cases of glaucoma are missed [27]. Moreover, the detection of early signs and progressive

glaucomatous is extremely difficult due to poor sensitivity and high inter and intra-observer variability [26]. This motivates researchers to look into diagnostic tool such as digital fundus camera which can accommodate large-scale and repetitive screening in hospitals and clinics [3, 4, 5].

Glaucoma detection in fundus image diagnosis involves two measurements; 1. Cup-to-Disc ratio (CDR) measurement by calculating the vertical cup height divided by vertical disc height [9]; 2. ratio of blood vessels area in inferior-superior side to area of blood vessel in the nasal-temporal side. Most researcher focuses only on the CDR [8, 28, 29, 30]. The CDR measurement is validated by comparing against normal fundus images. [26] found that the diagnostic accuracy of the optometrists in detecting glaucoma is high in specificity but lower for sensitivity. In the bid to increase the sensitivity and specificity of the diagnosis, [7] developed a computer-based glaucoma screening system which combines the optic nerve defects detection, visual field examination and expert system rules. However the optic cup is difficult and challenging to segment due to the unclear boundary between optic cup and optic rim [8, 9, 21]. This is further complicated by the high density of vascular architecture surrounding the optic region.

The difficulty in segmenting the disk and cup has directed research in the area of image processing such as contrast enhancement (histogram specification [7], local contrast enhancement [24] and histogram equalization [20], image segmentation (region growing [22], thresholding [20] and deformable model [9, 22]) and edge detection (Canny edge detection [8]).

Thresholding is the simplest image segmentation technique [17] known for its high processing speed, ease in manipulation and smaller storage space [18]. Thresholding method has proved to be successful in dividing pixels into several classes to distinguish objects from background [19]. It can be categorized as bi-level or multi-level depending on the number of image segments. Bi-level thresholding, segments image into two different regions [18]. Multi-thresholding on the other hand, segments image into background and multiple objects. It is especially important in segmenting multi-colored and uneven background illumination [19, 23]. Since the fundus images are colored, the idea of separating the red, green and blue channel is intriguing due to the fact that different channel highlights different anatomy of the eyes [28, 31].

Most automated computer assisted glaucoma detection performs segmentation on fundus images, faced localization problem. Thus, this introduced error in the measurements and consequently in the diagnosis [6]. The focus of this research

This research is funded by Fundamental Research Grant Scheme (FRGS) 2/2010.

Noor Elaiza Abdul Khalid, Noorhayati Mohamed Noor, Zamalia Mahmud, Saadiah Yahya are with Faculty of Computer and Mathematical Sciences, University Technology MARA, 40450 Shah Alam, Selangor Darul Ehsan, Malaysia (email: elaiza, noorhayati, zamalia, saadiah@tmsk.uitm.edu.my) Norharyati Md Ariff is a master by research student with Faculty of Computer and Mathematical Sciences, University Technology MARA, 40450 Shah Alam, Selangor Darul Ehsan, Malaysia (e-mail: sakurayati@yahoo.com).

is to investigate the efficiency and variability image quality grading between multi-thresholding and ophthalmologists.

II. PROPOSED METHOD

Review 30 fundus images are collected from online DRIVE database for the purpose of this research.

A. Image Pre-processing

Four different image channels are used in this experiment; gray, red, green, and blue as depicted in Fig. 1.

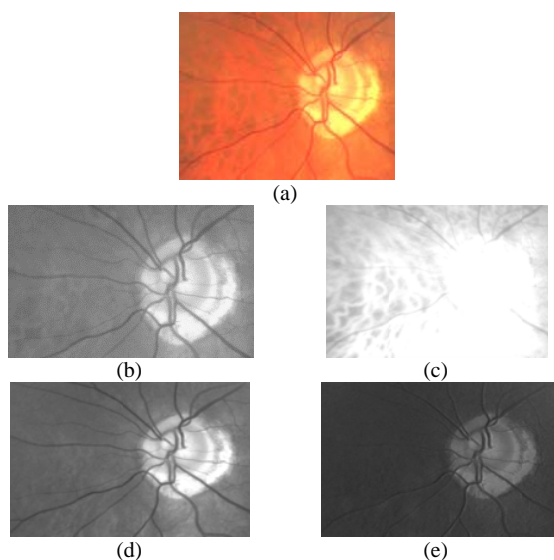


Fig. 1 a) Original Image; b) Grayscale Channel Image c) Red Channel Image d) Green Channel Image e) Blue Channel Image

B. Image Grading

The image grading is done in two phases: ophthalmologists and threshold image quality. The image quality is graded as in Table I. The grading is done subjectively by the ophthalmologists whereas the threshold image is graded subjectively based on the accuracy of the feature being extracted.

TABLE I
IMAGE QUALITY AND ITS GRADE

GRADE	IMAGE QUALITY
0	POOR
1	SATISFACTORY
2	GOOD

1) Survey Method: Ophthalmologist

All images from the preprocessing are subjected for evaluation by three ophthalmologists based on image quality in Table 1. The quality focuses on the clarity of each target features: optic disc, optic cup and vernacular for glaucoma assessment.

2) Multi Thresholding Method

Thresholding is the simplest segmentation method where image is binarized where the object is represented by black pixel whereas background as white. While thresholding selects

one threshold value, multithresholding allows multiple threshold values to segment objects. This method uses different threshold values to segment the different features. Optic cup requires only one threshold value due to its bright appearance. Optic disc requires two threshold values where an upper threshold is used to distinguish it from the cup and a lower threshold to distinguish it from the vernacular and background. Since the vernacular is darker in color, only one threshold is required. For each feature, the threshold value is selected manually during the process of segmenting the image. Fig. 2 shows a sample of segmented image of the three features.

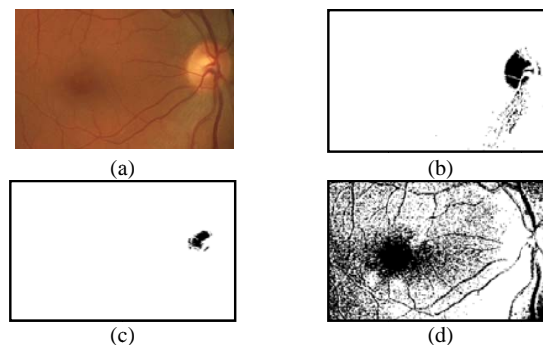


Fig. 2 a) Original Image; b) Segmented Optic Disc; c) Segmented Optic Cup; d) Segmented Vernacular

III. RESULT AND DISCUSSION

The results obtained from 30 images are recorded and analyze. The analysis is conducted into four stages: color ranges analysis; ophthalmologist’s survey; threshold; comparing ophthalmologists and threshold.

A. Color Ranges

The color ranges of gray, red, green and blue are analyzed shown in Fig. 3. The majority of pixel value of gray images falls in the upper half of color range. However, majority of the colors appears to close to 250. The box plot for gray images is skewed to the right showing bright image characteristic. The range of red image pixel values is narrow, at 250 grayscale value. This indicates that the red image is low contrast but a very bright image. The range of pixel value for green image is large and fall between 129 to 255 where majority of the pixels are in the upper range; thus the slightly skewed box plot. This indicates a good contrast and bright image. Finally, the blue image range lies in the lower pixel values implying a dark image. However, the distribution of pixel value is normal.

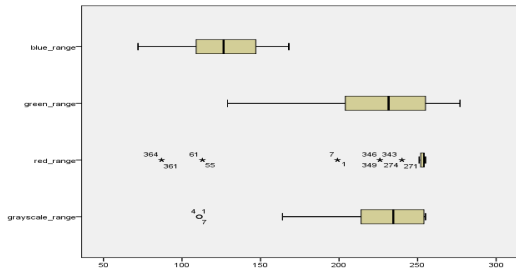


Fig. 3 Maximum and minimum Color Range

B. Ophthalmologists Survey Result

1) Comparison Between Ophthalmologist

The gray channel, all the three ophthalmologists consensually agree that most images' quality is in range from satisfactory to good as depicted in Fig. 4. However, certain amount of variability is detected among ophthalmologists for the satisfactory and good quality images. Majority of the images are considered as good quality and none of the image quality is poor.

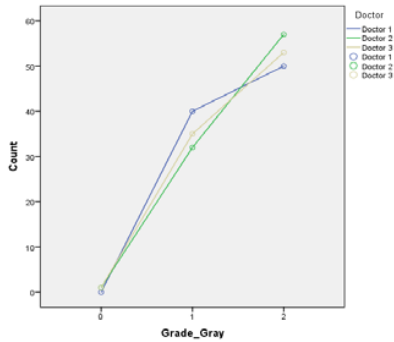


Fig. 4 Ophthalmologists Grading Distribution of Grayscale Channel Images

Fig. 5 shows that all the three ophthalmologists agree that majority of the red images are of poor quality with a few of the images are of good quality. There also exists some variability among the ophthalmologists.

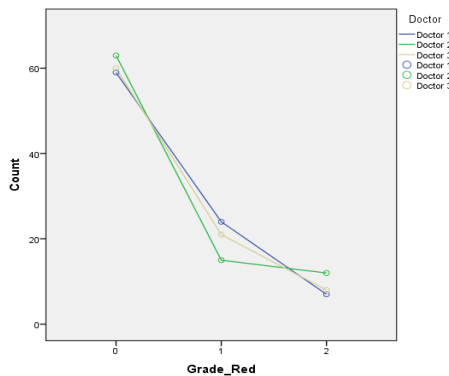


Fig. 5 Ophthalmologists Grading Distribution of Red Channel Images

Almost all the ophthalmologists have the same opinion that the green channel produces a highly graded image quality and none of the images are of poor quality as shown in Fig. 6.

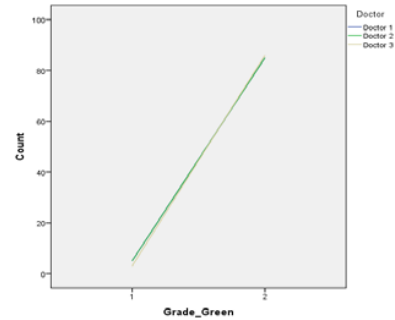


Fig. 6 Ophthalmologists Grading Distribution of Green Channel Images

Fig. 7 shows it is observed that there is a high variability among ophthalmologists evaluation of the image quality. Most of the images fall under satisfactory grade.

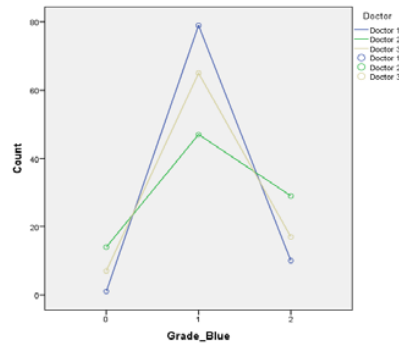


Fig. 7 Ophthalmologists Grading Distribution of Green Channel Images

2) Comparison between Frequency of Grade between Colors

Table II shows the frequency percentage of the grade given by the three ophthalmologists for gray, red, green, and blue channel. Overall it is found that the red channel has the highest percentage of the poor image quality grade whereas the percentage of gray, green and blue is almost negligible. Gray and green channels have high frequency percentage of the good image quality where the green (95.2%) outperform the gray (60.2%) channel.

TABLE II
PERCENTAGE OF GRADE GIVEN BY OPHTHALMOLOGISTS BETWEEN COLOR CHANNELS

IMAGE QUALITY	GRAY	RED	GREEN	BLUE
POOR	1.5%	67.7%	0%	8.2%
SATISFACTORY	38.3%	22.3%	4.8%	71%
GOOD	60.2%	10%	95.2%	20.8%

C. Threshold

Table III shows the frequency percentage of the grade given from observation of threshold image for gray, red, green, and blue. The red channel shows the weakest grade detection where it has the highest percentage of grade poor quality image while the other channel has very low percentage. Meanwhile, blue channel shows a high percentage of satisfactory quality images relative to other channels. The gray and green channels both have high percentage of good quality image where green supersedes gray by fifteen percent.

TABLE III
PERCENTAGE OF GRADE GIVEN AFTER MULTI-THRESHOLD

IMAGE QUALITY	GRAY	RED	GREEN	BLUE
POOR	2.2%	66.5%	2.2%	1.1%
SATISFACTORY	36.8%	17.8%	21.2%	68%
GOOD	61%	15.6%	76.6%	30.9%

D. Comparison between Ophthalmologists Survey and Threshold Result

Fig. 8 shows a comparison histogram between the opinion of the ophthalmologists and the digital outcome of thresholding.

The first cluster of histogram shows overall result from gray channel images. It is found that the difference in frequency for poor, satisfactory and good images are almost negligible with values of 0.7%, 1.5%, and 0.8% as shown in Table IV. These differences indicate the variability between ophthalmologists and thresholding can be considered as insignificant.

The second cluster in Fig. 8 shows the result from the red channel between ophthalmologists and thresholding. Both ophthalmologists and thresholding agrees that the red channel images are poor in quality. The difference in frequency between ophthalmologists and thresholding are 1.2%, 4.5% and 5.6% for poor, satisfactory and good images respectively as shown in Table IV. The variability of red images between ophthalmologists and thresholding can be considered as small.

The third cluster in Fig. 8 depicts the frequency of the green channel images. Table IV shows the difference in frequency between ophthalmologists and thresholding are 2.2%, 16.4% and 18.6% for poor, satisfactory and good images respectively. The high variability of between ophthalmologists and thresholding is due to the inconsistency of classification of satisfactory and good green channel images. More images classified as satisfactory by thresholding in contrast are classified as good by ophthalmologists. This is due to the nature of human eye (more specific and sensitive), training, knowledge and experience of the ophthalmologists. In this experiment, thresholding is used as a representative for the digitize method. It is a simple segmentation technique hence the result is less accurate.

The last histogram cluster in Fig. 8 shows overall result from blue channel images. Table IV shows the difference in frequency between ophthalmologists and thresholding are 7.1%, 3.0% and 10.1% for poor, satisfactory and good images respectively. Ophthalmologists appear not to favor this image due to its low contrast where the image appears dark.

However, the digital technique shows better results as higher number of images is classify as good quality. However, the variability between ophthalmologists and thresholding can still be considered as low.

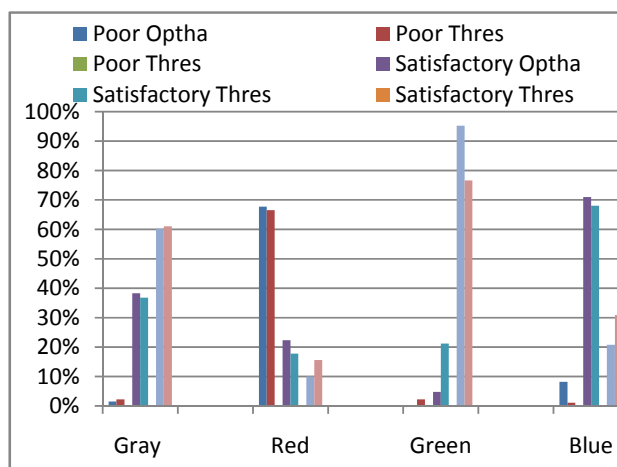


Fig. 8 Comparison histogram between the opinion of ophthalmologists and the digital outcome of thresholding

TABLE IV
PERCENTAGE DIFFERENCE BETWEEN OPHTHALMOLOGISTS OPINION AND THRESHOLDING

CHANNEL	POOR	SATISFACTORY	GOOD
GRAY	0.7%	1.5%	0.8%
RED	1.2%	4.5%	5.6%
GREEN	2.2%	16.4%	18.6%
BLUE	7.1%	3.0%	10.1%

IV. CONCLUSION

Based on the color range analysis, green is found to be a good contrast and bright image. Red is found to be the worst image as it has low contrast and bright image. The survey among the ophthalmologists shows an agreement of results in a green image analysis but the results highly varied in the blue image. It is also found that the green image segmentation has better image quality than the gray image. The red images are rated as poor quality. In the threshold analysis, the green and gray images are at par. The red channel image is considered as poor quality image. Meanwhile, the blue channel image shows the lowest percentage of poor quality image. The variability of Gray channel quality grading is the smallest among all channels, while the highest variability is recorded in the green channel. The blue channel shows a normal distribution of pixel value, but due to its low contrast, both ophthalmologists and threshold graded as low quality image.

ACKNOWLEDGMENT

The authors would like to express their sincere indebtedness to Dr. Rohana Taharin, Head of Ophthalmology Department from Hospital Daerah Bukit Mertajam, Pulau Pinang, Malaysia for her valuable advice for providing all the professional survey and clinical details.

REFERENCES

- [1] J. C. Dunn, "A Fuzzy Relative of the ISODATA Process and Its Use in Detecting Compact Well-Separated Clusters," *Journal of Cybernetics*, vol 3, pp. 32-57, 1973.
- [2] J. C. Bezdek, "Pattern Recognition with Fuzzy Objective Function Algorithms," Plenum Press, New York, 1981.
- [3] A. Murthi and M. Madheswaran, "Enhancement Of Optic Cup To Disc Ratio Detection In Glaucoma Diagnosis," *International Conference on Computer Communication and Informatics (ICCCI -2012)*, Coimbatore, INDIA, Jan 2012
- [4] S. Stacy, "Glaucoma-A Silent Thief." *Bay Area MD News*, Vol 2, No 12, 2009.
- [5] N. Jagadish , A.U. Rajendra, P. Subbanna B., S. Nakul and C.L. Teik "Automated Diagnosis of Glaucoma Using Digital Fundus Images," *J Med Syst*, 33:337-346, 2009.
- [6] L.G. Nyul, "Retinal image analysis for automated glaucoma risk evaluation," *SPIE: Medical Imaging*, vol. 7497, pp. 74 971C1-9, 2009.
- [7] X. Song X., K. Song, Y. Chen," A Computer-based Diagnosis System for Early Glaucoma Screening," *Engineering in Medicine and Biology Society*, 2005. *IEEE-EMBS 2005*. page(s): 6608 - 6611 Print ISBN: 0-7803-8741-4, 2005.
- [8] Y. Hatanaka, A. Noudo, C. Muramatsu, A. Sawada, T. Hara, T. Yamamoto, and H. Fujita, "Automatic measurement of cup to disc ratio based on line profile analysis in retinal images," *Proc. of the 33rd Annual International Conference of the IEEE Engineering in Medicine and Biology Society*, pp 3387-90, 2011.
- [9] J. Liu, F.S. Yin, D.W.K. Wong, Z. Zhang, N.M. Tan, C.Y. Cheung, M. Baskaran, T. Aung, T.Y. Wong, "Automatic Glaucoma Diagnosis from Fundus Image," *Engineering in Medicine and Biology Society, EMBC, 2011 Annual International Conference of the IEEE* Page(s): 3383 - 3386, 2011.
- [10] S. Kavitha, S. Karthikeyan, K. Duraiswamy, "Neuroretinal rim Quantification in Fundus Images to Detect Glaucoma," *IJCSNS International Journal of Computer Science and Network Security*, Vol. 10, No. 6 pp. 134-140, 2010.
- [11] M. Huang, H. Chen, and J. Huang, "Glaucoma detection using adaptive neuro-fuzzy inference system," *In Proceedings of Expert Syst. Applications*, pp. 458-468, 2007.
- [12] H. Li and O. Chutatape, 2003, "A model-based approach for automated feature extraction in fundus images," *Computer Vision Proceedings. Ninth IEEE International Conference*, page(s): 394 - 399 vol.1, Print ISBN: 0-7695-1950-4, Oct 2003.
- [13] A.F.M.Hani, N. F. Ngah, T. M. George, L.I. Izhar, N. Hermawan and A.N. Hanung, "Analysis of Foveal Avascular Zone in Colour Fundus Images for Grading of Diabetic Retinopathy Severity," *32nd Annual International Conference of the IEEE EMBS Buenos Aires, Argentina, August 31 - September 4, 2010*.
- [14] T. P. Karnowski, D. Aykac, L. Giancardo, Y.Li , T. Nichols, K.W. Tobin, E. Chaum, "Automatic Detection of Retina Disease: Robustness to Image Quality and Localization of Anatomy Structure," *33rd Annual International Conference of the IEEE EMBS Boston, Massachusetts USA, August 30 - September 3, 2011*.
- [15] K. Noronha, J. Nayak, S.N. Bhat, "Enhancement of retinal fundus Image to highlight the features for detection of abnormal eyes," *TENCON 2006. IEEE Region 10 Conference* page: 1 - 4 E-ISBN: 1-4244-0549-1 Print ISBN: 1-4244-0548-3, Nov 2006.
- [16] S. Kumar, M. Madheswaran, "Extraction of Blood Vascular Network for Development of an Automated Diabetic Retinopathy Screening System," *Computer Technology and Development, ICCTD '09. International Conference* page(s): 360 - 364, Print ISBN: 978-0-7695-3892-1, November 2009.
- [17] G. Xinbo, "Fuzzy Cluster Analysis and Application," *Sian: Xidian University Press*, pp.124-130, 2004.
- [18] S. Arora, J. Acharya, A. Verma., P. K. Panigrahi, "Multilevel Thresholding for Image Segmentation through a Fast Statistical Recursive Algorithm," *Pattern Recognition Letters*, 29(2), pp 119-125, 2008.
- [19] W.X Kang, Q.Q. Yang, R.P. Liang, "The Comparative Research on Image Segmentation Algorithms," *First International Workshop on Education Technology and Computer Science*, pp.703- 707, vol. 2, 2009.
- [20] P.G. Prageeth, J.David, A. Suresh Kumar, "Early Detection of Retinal Nerve Fiber Layer Defects using Fundus Image Processing," *Recent Advances in Intelligent Computational Systems (RAICS)*, *IEEE*, page(s): 930 - 936 , ISBN: 978-1-4244-9478-1, 2011.
- [21] J. Liu, D.W.K. Wong, J.H. Lim, X. Jia, F. Yin, H. Li, W. Xiong, T.Y. Wong, "Optic cup and disk extraction from retinal fundus images for determination of cup-to-disc ratio," *Industrial Electronics and Applications, ICIEA 2008. 3rd IEEE Conference*, page(s): 1828 - 1832, E-ISBN: 978-1-4244-1718-6 Print ISBN: 978-1-4244-1717-9, 2008.
- [22] G.D Joshi, J. Sivaswamy, S.R. Krishnadas, "Optic Disk and Cup Segmentation From Monocular Color Retinal Images for Glaucoma Assessment," *Medical Imaging, IEEE Transactions*, Volume: 30 Issue:6, On page(s): 1192 - 1205, ISSN: 0278-0062, 2011.
- [23] F. Kurugollu, B. Sankur and A.E. Harmanci, "Color Image Segmentation using Histogram Multithresholding and Fusion," *Image and Vision Computing* 19, pp 915-928, 2001
- [24] C. Sinthanayothin, J.F. Boyce, H.L. Cook, T.H. Williamson, "Automated localisation of the optic disc, fovea, and retinal blood vessels from digital colour fundus images," *Br J Ophthalmol*, 83:902-910, 1999
- [25] T. Romanay and B. Harvey, "Slit-Lamp Biomicroscopy," *Optician*, Vol 232, No 6069, September 2006.
- [26] Augusto Azuara-Blanco, Jennifer Burr, Ruth Thomas, Graeme MacLennan, Stephen McPherson, "The accuracy of accredited glaucoma optometrists in the diagnosis and treatment recommendation for glaucoma," *Br J Ophthalmol* 2007;91:1639-1643. doi: 10.1136/bjo.2007.119628
- [27] F. Topouzis and E. Anastasopoulos, "Glaucoma- The Importance of Early Detection and Early Treatment", *Touch Briefings*, 2007
- [28] Ganesh Babu T.R, Shenbagadevi, "Automatic Detection of Glaucoma Using Fundus Image", *European Journal of Scientific Research*, ISSN 1450-216X Vol.59 No.1, pp.22-32, 2011.
- [29] Narasimhan K., Vijayarekha K., "An Efficient Automated System For Glaucoma Detection Using Fundus Image", *Journal of Theoretical and Applied Information Technology*, Vol. 33 No.1, 2011.
- [30] Kavitha S., Duraiswamy K., "An Efficient Decision Support System for Detection Of Glaucoma In Fundus Images Using Anfis" *International Journal of Advances in Engineering & Technology*, Vol. 2, Issue 1, pp. 227-240, 2012.
- [31] Y. Hatanaka, A. Noudo, C. Muramatsu, A. Sawada, T. Hara, T. Yamamoto, and H. Fujita, "Vertical cup-to-disc ratio measurement for diagnosis of glaucoma on fundus images", *Proc. of SPIE Vol. 7624*, 2010.

Noor Elaiza Abdul Khalid has received BSc (Comp Sc) from USM, Malaysia in 1985, MSc (Comp Sc) in University of Wales in 1992 and PhD (Comp.Sc) from Universiti Teknologi MARA, Shah Alam in 2010. Currently hold position as senior lecturer in Faculty of Computer and Mathematical Sciences, Universiti Teknologi MARA, Shah Alam. Her current research interests are in Image Processing, Biomedical, Artificial Intelligence and Parallel Computing.

Noorhayati Mohamed Noor has received BEng (Comp and Info Eng) from IUM, Malaysia and MEng (Electronic Eng) from RMIT, Australia. Currently hold position as senior lecturer in Faculty of Computer and Mathematical Sciences, Universiti Teknologi MARA, Shah Alam. Her current research interests are in Image Processing, Parallel Computing and Embedded System.

Zamalia Mahmud has received BSc (Statistics) and MSc (Applied Statistics) from Western Michigan University, US. She has received a PhD (Statistical Education) from University of Strathclyde, UK. Currently she is an Associate Professor in Faculty of Computer and Mathematical Sciences, Universiti Teknologi MARA, Malaysia. Her research interests are in Applied Statistics, Statitistical Education and Rasch , and Research Methodology.

Saadiah Yahya has obtained her PhD in Computer Science from the University of Putra, Malaysia in 1998. She obtained both her MSc in Computer Studies and Post Graduate Diploma in Micropocessor and Application from Essex University, UK in 1987 and 1986. Her first degree is in Bachelor of Science (Education) Hon, double major (Mathematic and Chemistry) from University of Science in the year 1982. She is a Professor of Computer Science at the Faculty of Computer and Mathematical Sciences, Universiti Teknologi MARA, Shah Alam. Currently, she is a Deputy Director at Malaysia Institute of Transport. Her research interest includes Network and Information Security, Management of Information System and MANET.

Norharyati Md Ariff has recived BSc (Intelligent System) from UiTM, Malaysia in 2007. Currently, she is pursuin MSc in University Technology MARA, Shah Alam, Malaysia. Her research interest covers Image Processing, Medical Imaging, Computer Vision, Artificial Intelligence and Bio-inspired Algorithm.